



Case Report

Partial pericardial agenesis in a dog

Lorena S. Bezerra¹, Rômulo Santos A. Eloi², André L.R.M. Santos²,
Letícia B. de Oliveira², José Vanderlei Araujo³, Guilherme R. Blume^{2*}.

¹ Curso de Medicina Veterinária, Centro de Ciências da Saúde, Universidade de Fortaleza (UNIFOR), Fortaleza, Ceará, Brazil.

² HistoPato Laboratory – Veterinary Anatomopathological Analysis, Brasília, Distrito Federal, Brazil.

³ Centro de Especialidade Veterinária (CEV), Brasília, Distrito Federal, Brazil.

*Corresponding author: HistoPato Laboratory – Veterinary Anatomopathological Analysis, Brasília, Distrito Federal, Brazil.
E-mail: contato@histopato.com

Submitted January, 17th 2022, Accepted February, 22th 2022

Abstract

Pericardial defects are considered rare in animals and humans. Pericardial agenesis is characterized by partial or total pericardial sac malformation. Here is reported a case of apical partial pericardial agenesis in an adult mixed-breed male dog referred for necropsy. The pericardial sac was absent from the apical region up to the middle area of the ventricles resulting in a bilateral ventricular compression by the remaining pericardium changed the organ conformation. Microscopically, there was evidence of neutrophilic and hemorrhagic myocarditis with cardiomyocyte atrophy and interstitial fibrosis. Agenesis is often a subclinical disorder, and it is an incidental postmortem finding in most cases; however, it can cause complications in cases of cardiac structure herniation.

Key words: canine, cardiovascular, congenital defect, histopathology, pericardium.

Introduction

Agenesis is a condition that affects the development of a body structure, in which the organ can be partially or totally absent (16). The pericardium is a closed fibroelastic bag that fuses with the adventitia of major vessels at the base of the heart, containing a minimum amount of serous fluid that lubricates and enables cardiac wall movement (17). Pericardial defects described in dogs presented various sizes and locations with or without cardiac herniation, which were incidental necropsy findings. The etiology of these abnormality of the pericardial sac is unknown, but it can be congenital or acquired (especially traumatic), and those located ventral to the phrenic nerve are unlikely to be congenital (20). Traumatic pericardial tear was confirmed in 5 case reports with history of trauma (1,6,7,9,14).

Congenital cardiac anomalies are among the most frequent malformations in domestic animals (4,8). Congenital disorders involving pericardial formation, such as pericardial sac agenesis, are uncommon and represent

approximately 1% of the cardiac anomalies in dogs (15).

The most common congenital defects involving the pericardial sac are peritoneopericardial diaphragmatic hernia (PPDH) and pericardial cysts, but these are considered very infrequent malformations (10,11). The origin of congenital pericardial dysfunctions is still not well established. Some authors suggest that it derives from the premature duct of Cuvier atrophy, which is a left common cardinal vena cava, causing inadequate blood supply to the pleuropericardial membrane and resulting in failure of closure during embryogenesis (3,12).

The present study reports the anatomopathological findings of a case of partial apical pericardial agenesis in a dog.

Case Report

A male, adult, mixed-breed dog with a history of negligence was submitted for necropsy. The dog showed severe cachexia, anemia, and dehydration. External examination showed markedly pale conjunctival and

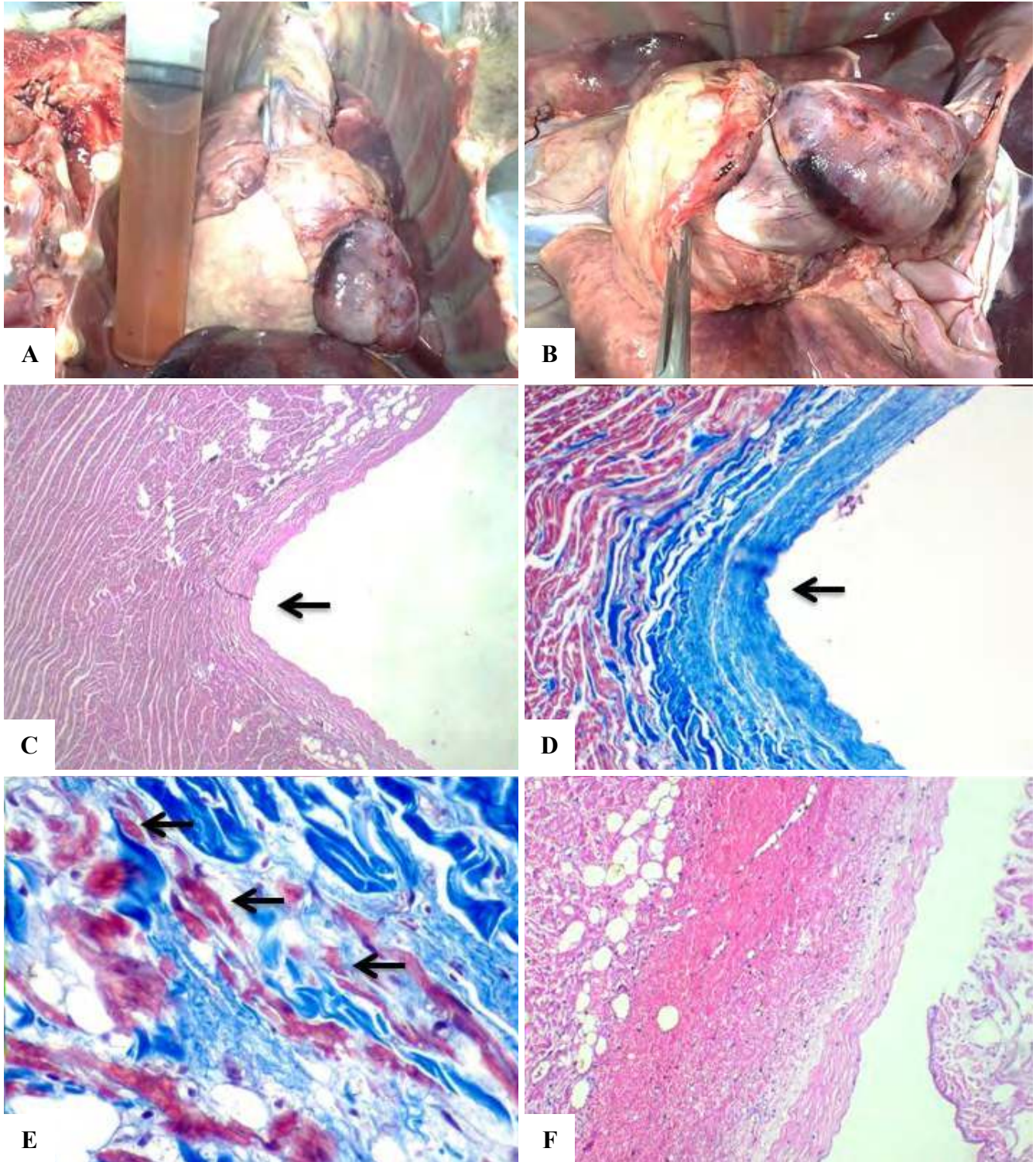


Figure 1. Heart of a dog with partial apical pericardial agenesis. **A.** Absence of the pericardial sac from the apical region to the middle region of the ventricles and hydrothorax. **B.** Circular bilateral ventricular compression area changing organ conformation. **C.** and **D.** Parenchymal retraction with interstitial fibrosis (arrow). HE, 10x (C) and Masson's Trichrome, 20x (D). **E.** Cardiomyocyte atrophy (arrow) with interstitial fibrosis. Masson's Trichrome, 40x. **F.** Hemorrhage and some neutrophils among cardiomyocytes. HE, 10x.

oral mucous membranes, severe atrophy of masticatory muscles and pelvic and thoracic girdle groups, as well as several ulcerative skin lesions on the fore- and hindlimb joints with subsequent exposure of the musculature. On internal examination, there was splenic fragmentation associated with splenosis. The thoracic cavity was filled with approximately 230 mL of serosanguinous effusion, which was indicative of hydrothorax. The pericardial sac was absent from the apical region to the middle region of the ventricles (Fig. 1A), with an increase in ventricular mass (concentric hypertrophy) of the uncovered ventricles and circular area of bilateral ventricular compression, thus changing the organ's conformation causing cardiomegaly (Fig. 1B). The ventricles also had areas of epicardial and myocardial suffusion. The right cranial and caudal lobes of the lung were atelectatic and edematous. The visceral surfaces of the right lateral and medial lobes as well as the square and left medial lobes of the liver were opaque, slightly irregular, and firm. Tissue fragments were fixed in 10% neutral buffered formalin, routinely processed for paraffin inclusion, sectioned and stained with hematoxylin and eosin (HE) and Masson's Trichrome.

Microscopically, there were areas of pericardial compression and parenchymal retraction characterized by cardiomyocyte atrophy associated with fibroblast proliferation and dense modeled connective tissue (fibrosis) (Fig. 1C, 1D and 1E). In addition to hemorrhage and some neutrophils (Fig. 1F). The lung had edema and moderate multifocal to coalescing atelectasis. The liver had fibrotic hepatopathy with mild centrilobular micro- and macrovacuolar degeneration. The kidneys showed mild multifocal lymphoplasmacytic interstitial nephritis. Striated skeletal muscle fragments from the temporal muscle showed multifocal polyphasic necrosis. Additionally, the spleen presented with extramedullary hematopoiesis and red pulp rarefaction.

Discussion

The reported animal had an apical cardiac portion which was not surrounded by the pericardial sac, pointing to a diagnosis of partial pericardial agenesis. This condition is sparsely described in veterinary literature (15). To our knowledge, the literature describes only two cases of congenital pericardial defects in species other than dogs and cats. The first case was a cow that presented with a pericardium reduced to a small thin funiculus, and the second was an orangutan with an oval opening on the left side of the pericardium (11).

The heart base was covered by the pericardial sac and has signs of compression, in addition to a demarcation line on the site of heart herniation and hemorrhage. The presence of this demarcation line was reported in another study (18). The incarceration of cardiac structures is a consequence of pericardial sac malformation, which causes

clinical signs of hypertension and heart failure and may trigger syncope or tachyarrhythmia (2). Other studies (2,18) described cardiac hypertrophy of the incarcerated and uncovered regions of the pericardial sac, which corroborates the present report.

Cases with histopathological lesions in pericardial agenesis are rarely described and, diverging with our findings, one study founded cardiac infarction lesions (18).

Thoracic effusion was reported in another case of pericardial agenesis in a dog (2). The hydrothorax and fibrotic liver lesion in this case could be secondary to chronic systemic hypertension, corroborating with a study that discusses a variety of systemic effects due to congenital heart diseases in dogs and indicates early onset of congestive heart failure as one of the most important complications resulting from cardiac malformations, which is a main cause of death (3). Histopathological findings were compatible with anemia and hypoxia. Therefore, animals affected by congenital cardiac anomalies can present with important circulatory disorders that lead to organ and tissue ischemia (19).

Agenesis is often subclinical and, in most cases and in this report, an incidental postmortem finding. However, hypertensive clinical signs related to the involved cardiac antimere can be present in cases of cardiac structure incarceration (20). There is no clinical information of this dog, but the findings of hydrothorax, pulmonary edema, concentric cardiac hypertrophy and centrilobular degeneration are described in cases of heart failure.

Pericardial defects may be classified as congenital or acquired and can vary from total or partial absence, being characterized as small orifices or large foramina, comprising all circumference (10). In humans, most cases of pericardial agenesis are located on the left side (4), but in animals, there does not seem to be a predilection for any of the antimeres, with abnormalities on the left and right as well as cases of defects in both sides, or even complete absence of the pericardium (2,18,20). In this case, it is not possible to determine the origin of the pericardial defect, since this pericardial lesion with cardiac herniation can have different sizes and locations (20). The absence of history of previous trauma or cardiothoracic surgery suggests congenital etiology, but necroscopic findings as splenosis indicate a possible trauma. So exactly etiology is unclear in this case.

There are not enough studies to establish a significant correlation between the death in animals with this condition and a certain age range. However, the literature indicates a tendency for this condition to be diagnosed in adult animals (3, 19, 20), such as in this report, which strengthens the premise that affected subjects can remain asymptomatic until adulthood without major complications, depending on the defect type and its extension. Some cases have been reported in dogs of different breeds, such as the Maltese (2), Dachshund (20), Boxer (20), and in mixed breed dogs (18), similar to the animal reported in this study. The condition has also been reported in both sexes, indicating no sex predilection.

Some studies suggest that most congenital heart defects, including those involving the pericardial sac, are found in association with other malformations (13,19). However, the animal analyzed in this report showed no other concomitant anomaly. Similarly, another partial pericardial agenesis was reported in a dog that presented with exposure of part of the atrium and right auricle without any coexistent congenital cardiac disorder (18).

Based on the anatomopathological findings, a diagnosis of partial apical pericardial agenesis was confirmed, which is a condition rarely described in animals. Thus, the present report contributes to veterinary literature on this topic.

References

1. Brunnberg L, Gal A, Kröning T, et al. Pericardial rupture with partial luxation of the heart in a dog. Case report. *Kleintierprax* 1989;34:271-4.
2. Chapel E, Russel D, Schober K. Partial pericardial defect with left auricular herniation in a dog with syncope. *J Vet Cardiol*. 2014;16(2):133-9.
3. Darke PGG. Congenital heart disease in dogs and cats. *J. Small Anim. Pract.* 1989;30(1):599-607.
4. Egenvall A, Bonnett, BN, Häggström J. Heart disease as a cause of death in insured Swedish dogs younger than 10 years of age. *Journal of veterinary internal medicine*. 2006;20(4):894-903.
5. Espino JAR, Hernández, IG. Agenesia de pericardio izquierdo: A propósito de 1 caso. *Revista Cubana de Cirugía*. 2001;40(3):235-9.
6. Farrow CSF. Have you ever, and if you have, would you? *Vet Radiol Ultrasound* 1994;35:139.
7. Grabner A, Rieger I, Haberstroh J, et al. Ventricular tachycardia due to rupture of the pericardium in a dog. *Kleintierprax* 1991;36:295–302.
8. MacDonald KA. Congenital heart diseases of puppies and kittens. *Veterinary Clinics: Small Animal Practice*. 2006;36(3):503-31.
9. Milli UH, Unsuren H. Incarceration of the heart as a result of pericardial rupture in a dog. *Veteriner Fakultesi Dergisi* 1982;29:214–8.
10. Monnet E. Congenital Pericardial Diseases. *Small Animal Soft Tissue Surgery*. 2013;1:817-9.
11. Moore TC, Shumacker Jr HB. Congenital and experimentally produced pericardial defects. *Angiology*. 1953;4(1):1-11.
12. Mulvihill JJ, Priester WA. Congenital heart disease in dogs: epidemiologic similarities to man. *Teratology*. 1973;7(1):73-7.
13. Oliveira P, Domenech O, Silva J, Vannini S, Bussadori R, Bussadori C. Retrospective review of congenital heart disease in 976 dogs. *J. Vet. Intern. Med.* 2011;25(3):477-83.
14. Pallaske G. Traumatische Perforation des Herzbeutels beim Hund. *Dtsch Tierarztl Wochenschr* 1959;66:303.
15. Patterson DF. Epidemiologic and genetic studies of congenital heart disease in the dog. *Circulation Research*. 1968;23(2):171-202.
16. Robinson WF, Robinson NA. Cardiovascular system. In: Maxie MG. (Ed.), *Jubb, Kennedy and Palmer's Pathology of Domestic Animals*. Elsevier, St Louis. 2016;6(3):14-24.
17. Sisson D. Pericardial disease and cardiac tumors. *Textbook of canine and feline cardiology*. 1999;2:679-701.
18. Teófilo TS, Martins MER, de França-Silva A, Batista JS. Agenesia Parcial Do Saco Pericárdio Em Cão—Relato De Caso. *Acta Veterinaria Brasilica*. 2008;2(2):50-2.
19. Tidholm A. Retrospective study of congenital heart defects in 151 dogs. *J. Small Anim. Pract.* 1997;38(3):94-8.
20. Van der Gaag I, Van Der Luer RJT. Eight cases of pericardial defects in the dog. *Veterinary pathology*. 1977;14(1):14-8.