



Original full paper

# Interobserver variability in the diagnosis of canine hepatoid gland tumors

Danilo Gouveia Wasques<sup>1</sup>, Juliana Mariotti Guerra<sup>1,2</sup>,  
Natália Coelho Couto de Azevedo Fernandes<sup>1,2</sup>, Máira Bonamin Martins<sup>3</sup>,  
Emerson Flávio Freitas Mota<sup>3</sup>, Bruno Cogliati<sup>1\*</sup>.

<sup>1</sup> Departamento de Patologia, Faculdade de Medicina Veterinária e Zootecnia, Universidade de São Paulo, São Paulo, SP, Brazil.

<sup>2</sup> Instituto Adolfo Lutz, Coordenadoria de Controle de Doenças, Secretaria do Estado da Saúde de São Paulo, São Paulo, SP, Brazil.

<sup>3</sup> Histopet, Laboratório de Anatomopatologia Veterinária, São Paulo, SP, Brazil.

\*Corresponding author: Departamento de Patologia, Faculdade de Medicina Veterinária e Zootecnia, Universidade de São Paulo, Av. Prof. Dr. Orlando Marques de Paiva 87, Cidade Universitária, 05508-270, São Paulo, SP, Brazil. Tel: +55 11 3091 1200. E-mail: [bcogliati@usp.br](mailto:bcogliati@usp.br)

Submitted January, 11<sup>th</sup> 2021, Accepted May, 30<sup>th</sup> 2022

## Abstract

The reported prevalence of canine hepatoid gland tumor (HGT) varies widely owing mainly to the lack of well-defined diagnostic criteria and poor interobserver agreement. The aim of the present study was to improve the level of diagnostic agreement among pathologists in canine HGT. Five pathologists diagnosed and classified morphological features in 57 cases of canine HGT and, based on their reports, diagnostic algorithms were devised using recursive partitioning analysis. The proportion of diagnoses of malignant hepatoid neoplasia among the five pathologists ranged from 26.3 to 50.9%. Interobserver diagnostic agreement was classified as fair ( $\kappa=0.54$ ) but improved to good ( $\kappa\sim 0.65$ ) following application of two novel diagnostic algorithms based on histomorphological features as sebaceous differentiation, mitotic count, atypical mitosis and cellular atypia. This study has demonstrated that interobserver agreement in the diagnosis of canine HGT could be improved using novel algorithms. Further analyses are warranted to validate the proposed classification systems applying a higher sampling of canine HGTs.

**Key words:** Dogs; hepatoid gland; reproducibility; diagnostic algorithm.

## Introduction

Hepatoid gland tumors (HGTs) constitute one of the most common types of canine skin cancer and account for 5.8 to 13.5% of all cutaneous neoplasms in the species (6, 16, 27). Although prognosis of the condition is generally good, cases of recurrence and metastases have been described (2, 14, 24, 30, 35). However, the worldwide prevalence of malignant HGT varies considerably with combined rates of carcinoma and epithelioma (considered as low-grade malignancy) ranging from 3.3 to 54.5% according to various surveys (1, 2, 5, 6, 11, 14, 16, 18, 20, 21, 24, 25, 27, 30-34).

Reproducibility is one of the essential elements of a classification scheme in anatomic pathology, and lack of agreement may preclude an accurate assessment

of the clinical value of a diagnostic test (23). A possible source of this variation could be the use of different diagnostic guidelines (12), mainly because specific histomorphological criteria predictive of poor prognosis in canine HGTs have yet to be reported. Moreover, the issue of interobserver agreement regarding the diagnosis of malignancy has received scant attention, although one study reported 82% concurrence between two pathologists in such diagnosis (7).

The main aims of the present study were to determine the degree of interobserver agreement regarding the diagnosis of malignancy in canine HGTs according to currently available criteria, and to establish the impact of novel diagnostic algorithms on the level of interobserver agreement.

**Table 1.** Signalment and clinical data of dogs included in the study.<sup>a</sup>

	<b>Benign nodules</b>	<b>Malignant tumors</b>
n tumor (animals)	28 tumors (18 dogs)	29 tumors (27 dogs)
Breed (n)	Mixed-breed (7); Lhasa Apso (3); Labrador Retriever (2); Cocker Spaniel, Belgian Shepherd, Fox Terrier, Bichon Frisé, Yorkshire Terrier, Golden Retriever (1 each)	Mixed-breed (8); Cocker Spaniel, Poodle (5 each); Beagle, Shih Tzu (2 each); Schnauzer, Labrador Retriever, English Bulldog, Teckel, West White Highland Terrier (1 each)
Location (n)	Anal/perianal (24); tail (3); anal or tail (1)	Anal/perianal (22); tail (3); prepuce, lombar region, anal or tail (1 each); N/A (1)
Age (years)	10.62 ± 2.99	12.48 ± 2.4
Male:femaleratio <sup>a</sup>	7.5:1	1,001
Size (cm)	1.82 ± 0.94	1.9 ± 0.64
Multiple nodules (%)	2 (11.1%)	8 (29.6%)

*Abbreviation: N/A, Not available. Values are represented as mean ± standard derivation.*

<sup>a</sup> *Patients presenting multiple nodules were allocated to the group corresponding to the most aggressive diagnosis based on the histopathological analysis.*

## Materials and methods

### Case selection

Cases of canine HGTs were selected from the electronic database of a private veterinary pathology laboratory in São Paulo, Brazil. The inclusion criteria were: (i) cases representing lesions with unequivocal hepatoid gland differentiation, (ii) cases without excessive tissue artifacts (i.e., autolysis), and (iii) cases in which the referring veterinarian had provided resection specimens. Cases involving undifferentiated carcinomas, poorly differentiated carcinomas with suspected hepatoid gland differentiation or those supported only by incisional biopsies were excluded. A search of the database identified 57 cases of HGTs (from 45 dogs) that satisfied the inclusion criteria. All reports and the corresponding hematoxylin and eosin (HE) stained slides were reviewed. Signalment and clinical data relating to the dogs enrolled in the study are presented in Table 1.

The study was performed with the approval of the Committee on Bioethics of the School of Veterinary Medicine and Animal Science of the University of São Paulo (protocol number 4945080716). Permission to extract and analyze data retrieved from the files of the private pathology laboratory was obtained explicitly from the owner of the database.

### Reproducibility study

Each of the five veterinary pathologists (P), identified by numbers 1 to 5, involved in the study had undergone formal residential training in veterinary anatomic pathology and were experienced in diagnostic pathology in terms of the total numbers of cases signed-out and the proportion relating to small animal surgical pathology (Table 2). The same HE-stained slides from each of the 57 HGTs were submitted to the pathologists in order to avoid field variability among analyses. In addition, pathologists were provided with diagnostic criteria encompassing the references commonly used in veterinary pathology training worldwide (8, 9, 12), on the basis of which cases were diagnosed according to a four-tiered diagnostic classification as hyperplasia, adenoma, epithelioma or carcinoma. The following morphological criteria were evaluated: grade of infiltration, cytologic atypia, cell polarity, percentage of reserve cells, percentage of tumor necrosis, sebaceous differentiation, squamous differentiation, mitotic count, presence of atypical mitosis, presence of mitotic figures in differentiated or partially differentiated hepatoid cells, and vascular invasion. Cell polarity was defined in terms of the degree of disorganization of the typical maturation pattern from reserve to mature cells. According to this definition, preserved cell polarity was characterized by reserve cells situated at

**Table 2.** Experience of the five pathologists included in the study.

<b>Pathologist (P) number</b>	<b>Experience</b>	<b>Estimated proportion of small animal surgical pathology cases from total workload</b>
P1	5.5 years	99.4%
P2	7 months	80.0%
P3	5 years	50%
P4	5.5 years	16.7%
P5	17 years	74.5%

**Table 3.** Morphological criteria for histopathological analysis.

Infiltration grade				Reserve cells		Necrosis	
1	Non infiltrative			1	0-25%	1	0
2	Rare infiltrative foci			2	25-50%	2	1-25%
3	Partially well-demarcated, partially infiltrative			3	51-75%	3	25-50%
4	Infiltrative (predominantly)			4	76-100%	4	51-75%

Sebaceous differentiation		Squamous differentiation		Mitoses in differentiated cells		Vascular invasion	
1	Absent	1	Absent	0	No	0	No
2	Rare foci	2	Rare foci	1	Yes	1	Yes
3	Moderate to marked	3	Moderate to marked	<i>Mitotic count (mitoses per 2.37 cm<sup>2</sup>)</i>			

Cellular atypia <sup>a</sup>				Loss of cell polarity <sup>a</sup>			
Grade	Absent/minimal	Moderate	Marked	Grade	None/minimal	Moderate	Marked
1	+++	-	-	1	+++	-	-
2	+++	+	-	2	+++	+	-
3	++	++	-	3	++	++	-
4	+	+++	-	4	+	+++	-
5	-	+++	-	5	-	+++	-
6	+++	-	+	6	+++	-	+
7	-	+++	+	7	-	+++	+
8	++	-	++	8	++	-	++
9	-	++	++	9	-	++	++
10	+	-	+++	10	+	-	+++
11	-	+	+++	11	-	+	+++
12	-	-	+++	12	-	-	+++

<sup>a</sup> - absent; + rare foci; ++ partial; +++ predominant/diffuse.

the periphery of tumor lobules with differentiated cells at the center, while loss of cell polarity encompassed varying degrees of deviation from this pattern with random cell distribution. Mitotic figures were counted in ten non-overlapping and contiguous high-power fields avoiding ulcerated areas and those with higher mitotic activities (hotspots). In order to improve the detection of hotspots, multiple mitotic counts were suggested for each case and the highest mitotic count reported. The field numbers of the microscopes employed by the pathologists were recorded and the results converted to mitotic count per area, as previously recommended (22). Detailed classification schemes for each of the morphological criteria are described in Table 3. The analyses were performed independently by each pathologist according to his/her availability with no time constraint set. Each pathologist was blind to previous diagnoses, and discussion of cases or consensus views was prohibited.

### Statistical analysis

Agreement between pathologists was evaluated using intraclass correlation coefficients (ICC) for ordinal or numeric variables and Cohen's  $\kappa$  for binary variables as previously described (29). Coefficients of agreement were expressed as mean and median (with interquartile range) values

and the group agreement for each variable was calculated. ICC and  $\kappa$  values were interpreted as follows: <0.4, poor; 0.4–0.59, fair; 0.6–0.74, good; 0.75–1, excellent (3).

Evaluations of morphological criteria produced by all pathologists were pooled, and several regression trees were developed via recursive partitioning. Hyperplasias and adenomas were merged into the category benign nodules while epitheliomas and carcinomas were classified as malignant tumors. Epitheliomas are considered low-grade malignancies (20). Rather than employing the final diagnosis provided by each pathologist, dependent variables for regression trees were obtained considering a two-tier (benign nodule vs. malignant tumor) diagnostic scheme. Outcomes for each tree were based on the grades of agreement between the original diagnoses of malignant tumors by the pathologists. The impact of each algorithm on interobserver diagnostic agreement was evaluated using paired t tests with calculation of Cohen's effect size  $d$  and the mean difference. The least complex trees that could engender improvements in diagnostic agreement when applied to each pathologist were selected. The impact of adopting mitotic count per area rather than count per 10 high-power fields on agreement was determined using similar statistical tests. The correlation

between mitotic count and microscope field number was assessed in terms of the Spearman correlation coefficient ( $\rho$ ), the results of which were interpreted as follows: 0-0.19, very weak; 0.20-0.39, weak; 0.40-0.59, moderate; 0.60-0.79, strong; 0.8-1, very strong.

Statistical analyses were performed using R (version 3.4.3) open-source software. Distributions of studied variables were evaluated for normality of distribution via histogram analysis and Shapiro-Wilk test and appropriate statistical tests selected accordingly. In all cases, the level of significance ( $\alpha$ ) was set at 0.05.

## Results

Fifty-seven cases of HGTs were evaluated in the reproducibility study with all five pathologists presenting diagnostic agreement with respect to 22 (38.6%) cases comprising 18 (31.6%) adenomas, 3 (5.3%) carcinomas and 1 (1.8%) nodular hyperplasia. In a further 21 (36.8%) cases, four of the pathologists agreed diagnoses of 11 (19.3%) carcinomas, 9 (15.8%) adenomas, and 1 (1.8%) nodular hyperplasia. However, only three pathologists agreed regarding the additional 13 (22.8%) cases and diagnosed 2 (3.5%) adenomas, 10 (17.5%) carcinomas, and 1 (1.8%) epithelioma. In the 1 (1.8%) remaining case, two pathologists diagnosed the tumor as adenoma, two as carcinoma, and one diagnosed a nodular hyperplasia.

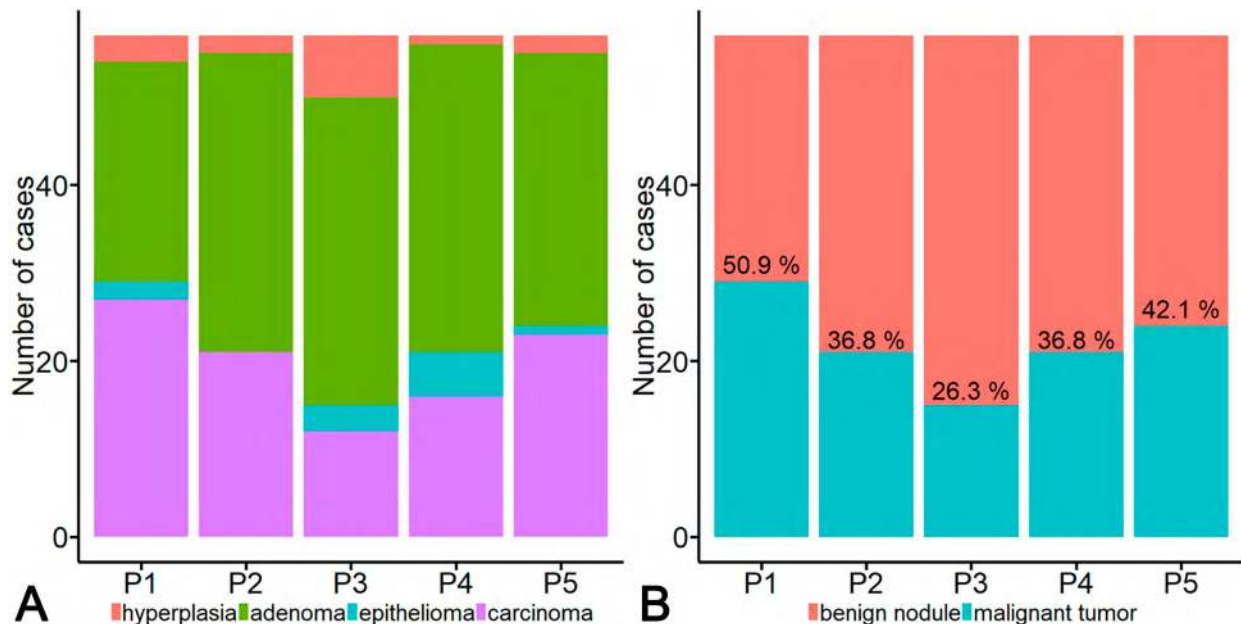
In terms of the two-tiered diagnostic classification, all pathologists agreed in respect of 32 (56.1%) cases comprising 24 (42.1%) benign nodules and 8 (14%) malignant tumors, four pathologists agreed diagnoses regarding 13 (22.8%) cases involving 5 (8.8%) benign

nodules and 8 (14%) malignant tumors, while in the remaining 12 (21.1%) cases there was agreement between only three pathologists with respect to 3 (5.3%) benign nodules and 9 (15.8%) malignant tumors.

Comparison of the frequency of diagnoses per pathologist in terms of the four-tiered diagnostic classification revealed considerable divergences, with the diagnosis of nodular hyperplasia varying from 1 (1.7%) to 7 (12.3%) cases, of adenoma from 25 (43.9%) to 35 (61.4%) cases, of epithelioma from 0 to 5 (8.8%) cases, and of carcinoma from 12 (21.1%) to 27 (47.4%) cases (Fig. 1A). Considering the two-tiered classification, diagnosis of benign nodules varied from 28 (49.1%) to 42 (73.7%) cases and malignant tumors from 15 (26.3%) to 29 (50.9%) cases (Fig. 1B).

In the interobserver analysis, diagnostic agreement with respect to the four-tiered (ICC = 0.54) and two-tiered ( $\kappa=0.54$ ) classifications were interpreted as fair (Table 4).

Of the 3420 morphological parameters to be evaluated, 3371 (98.65%) were completed correctly in the standardized questionnaires sent to the five pathologists. There were no omissions in the 'diagnosis' field, and omissions in other fields were considered random and, therefore, excluded from the agreement analyses and regression trees. The mean agreement among pathologists was interpreted as good for mitotic count (ICC=0.60), and fair for cellular atypia (ICC=0.40), loss of cell polarity (ICC=0.40), proportion of reserve cells (ICC=0.43), sebaceous differentiation (ICC=0.43) and atypical mitosis ( $\kappa=0.42$ ). Mean agreements for the remaining morphological criteria were interpreted as poor (Tables 5 and 6).



**Figure 1.** Frequency of diagnoses per pathologist in terms of the four-tiered (A) and two-tiered (B) diagnostic classifications. Percentage values in panel (B) refer to the proportion of malignant tumors diagnosed per pathologist

**Table 4.** Pairwise interobserver agreement among five pathologists regarding the diagnosis of canine hepatoid gland tumors

	Interobserver agreement			
	4-tiered classification <sup>a</sup>		2-tiered classification <sup>b</sup>	
	ICC	P	κ	P
<b>P1 x P2</b>	0.72	<0.0001	0.72	<0.0001
<b>P1 x P3</b>	0.46	0.0016	0.51	<0.0001
<b>P1 x P4</b>	0.56	<0.0001	0.58	<0.0001
<b>P1 x P5</b>	0.68	<0.0001	0.62	<0.0001
<b>P2 x P3</b>	0.49	<0.0001	0.52	<0.0001
<b>P2 x P4</b>	0.45	0.0002	0.47	0.0004
<b>P2 x P5</b>	0.66	<0.0001	0.60	<0.0001
<b>P3 x P4</b>	0.40	0.0006	0.52	<0.0001
<b>P3 x P5</b>	0.47	0.0002	0.43	0.0005
<b>P4 x P5</b>	0.50	<0.0001	0.45	0.0006
<b>Mean (σ)</b>	0.54	(0.11)	0.54	(0.09)
<b>Median (IQR)</b>	0.49	(0.46 - 0.63)	0.52	(0.48 - 0.59)

Abbreviations: ICC, intraclass correlation coefficient; κ, Cohen's kappa; IQR, interquartile range.

<sup>a</sup>Diagnoses of hyperplastic nodule, adenoma, epithelioma and carcinoma on an ordinal scale.

<sup>b</sup>Diagnoses of benign nodule (either hyperplastic nodule or adenoma) and malignant tumor (either epithelioma or carcinoma) on an ordinal scale.

**Table 5.** Mean agreement among pathologists with regard to different morphological criteria expressed as ordinal/continuous variables.

Criterion	Intraclass correlation coefficient
	ICC (mean)
Mitotic count (per 2.37 mm <sup>2</sup> )	0.60
Diagnosis (4-tiered classification)	0.54
Sebaceous differentiation	0.43
Proportion of reserve cells	0.43
Loss of cell polarity	0.40
Cellular atypia	0.40
Tumor necrosis	0.35
Infiltration grade	0.29
Squamous differentiation	0.23

**Table 6.** Mean agreement among pathologists with regard to different morphological criteria expressed as ordinal/continuous variables.

Criterion	Cohen's κ (mean)
Diagnosis (benign vs. malignant)	0.54
Mitotic atypia	0.42
Mitotic figures in differentiated cells	0.32
Vascular invasion	0.08 <sup>a</sup>

<sup>a</sup>Owing to the low prevalence of vascular invasion in this sample, most pairs of comparison did not attain statistical significance for this criterion and the mean κ value provided is not reliable.

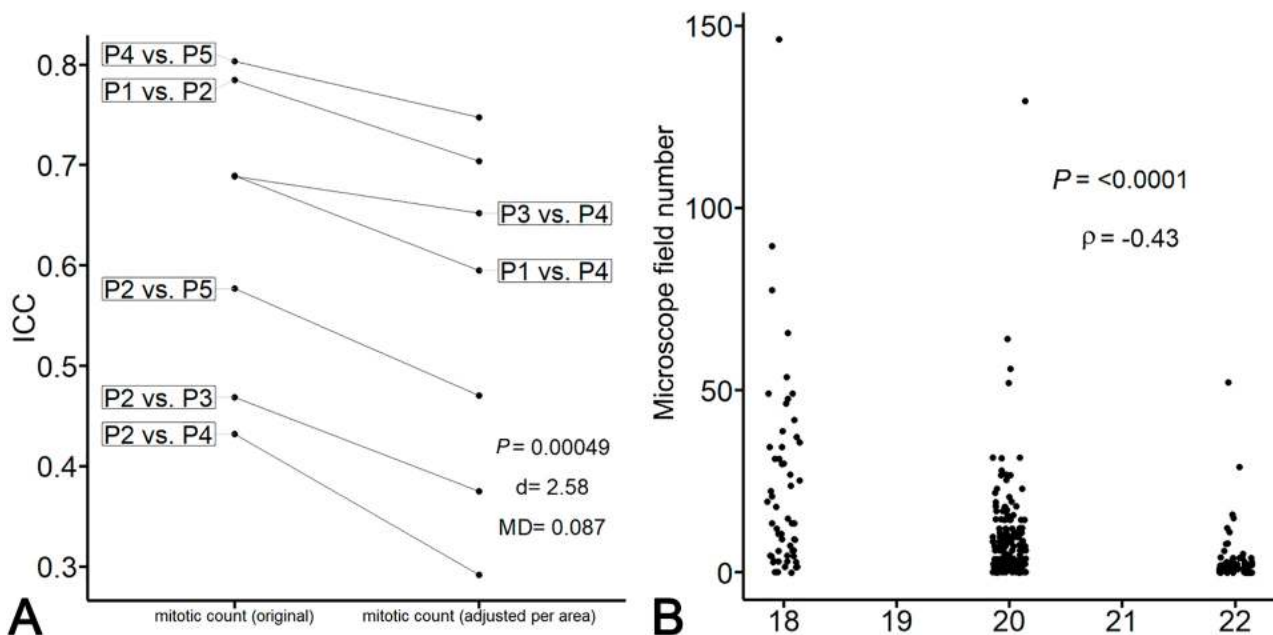
When interobserver agreement was evaluated as mitotic count per area rather than mitotic count per 10 high-power fields, there was a decrease in mean ICC from 0.63 (good agreement) to 0.55 (fair agreement)(Cohen's effect size  $d=2.58$ , paired t-test  $P = 0.00049$ ,  $n = 6$ )(Fig.2A). Moreover, a moderate negative correlation was detected between microscope field number and mitotic count (Spearman's  $\rho=-0.43$ ;  $P<0.0001$ ) (Fig.2B) indicating that the pathologists were more likely to assign a higher mitotic count when using microscopes with lower field numbers.

Based on the morphological parameters evaluated by the pathologists, two algorithms to predict outcome in terms of the two-tiered diagnostic classification were developed by regression tree analysis. In the first algorithm, outcomes were defined as malignant when diagnostic agreement between all five pathologists was at least 60% (Fig. 3A). In the second algorithm, the diagnoses of the least experienced pathologist were excluded, and outcomes were defined as malignant when diagnostic agreement between the remaining four pathologists was at least 50% (Fig. 3B). When these algorithms were applied using the morphological data evaluated by all five pathologists, there was a significant improvement in interobserver agreement from fair ( $\kappa=0.54$ ) to good ( $\kappa=0.64$ ) with algorithm 1 (Cohen's effect size  $d = 1.18$ , paired t-test  $P = 0.00461$ ,  $n = 10$ ) (Fig. 4A) and from fair ( $\kappa = 0.54$ ) to good ( $\kappa = 0.65$ ) with algorithm 2 (Cohen's effect size  $d = 1.12$ , paired t-test  $P = 0.00645$ ,  $n = 10$ ) (Fig. 4B). As showed in Fig. 4, improvements in diagnostic agreement were seen in nine out of ten pairwise comparisons between pathologists following application of either algorithm.

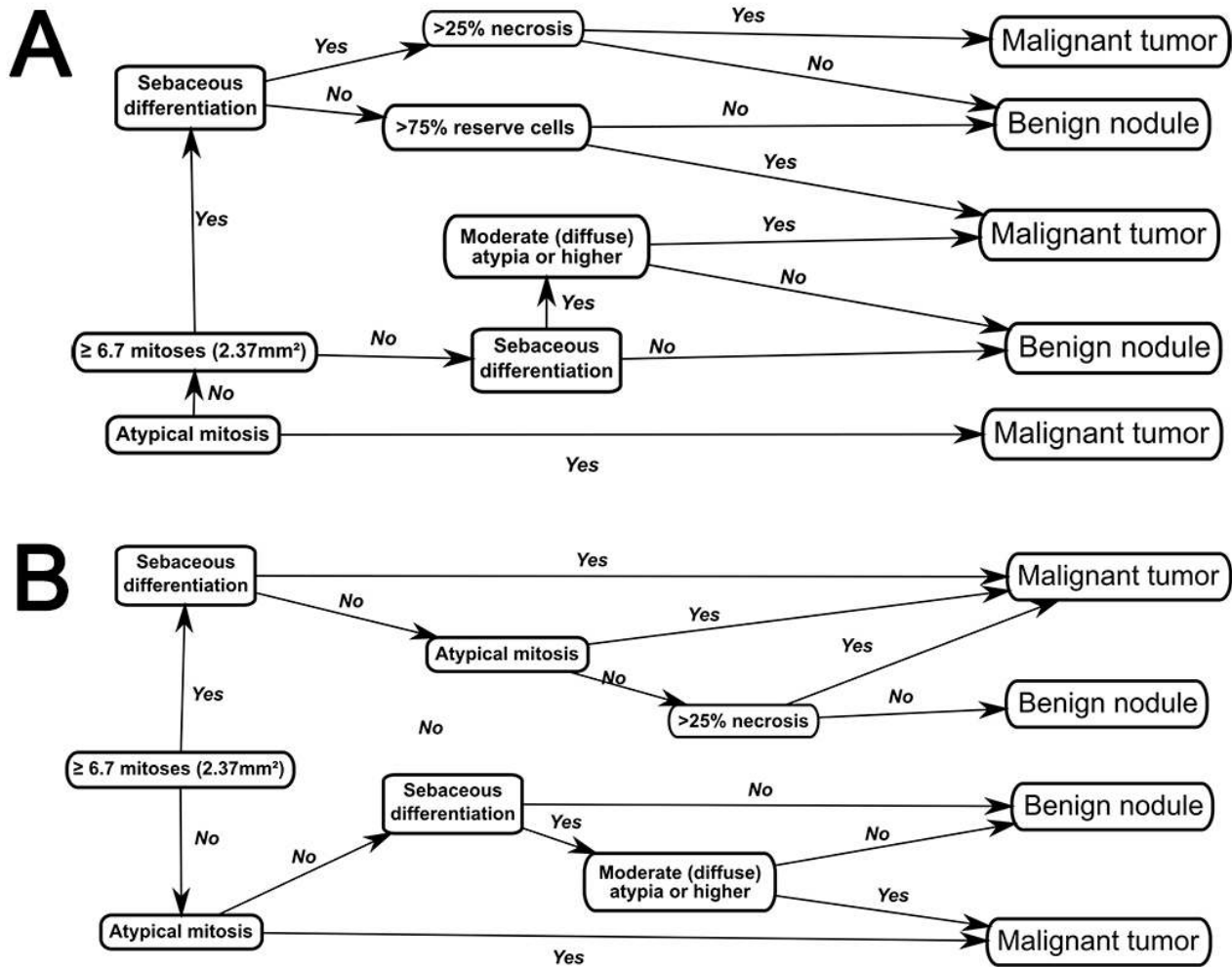
## Discussion

In the present study, the proportion of diagnoses of malignant hepatoid neoplasia among the pathologists who took part in the study ranged from 26.3 to 50.9%, suggesting that the reported variation in prevalence may be explained, at least in part, by interobserver disagreement. It is not uncommon for veterinary pathologists to encounter problem cases for which diagnoses are open to a degree of uncertainty, a situation highlighted in the present study by the finding that disagreement of diagnosis by at least one of the five pathologists occurred in 61.4% of cases. A previous study reported disagreement between two pathologists regarding the diagnosis of malignancy in 18.8% of cases of canine HGTs and argued that the discrepancy resulted from areas with high cell pleomorphism and mitotic index despite the preserved lobular architecture typical of adenomas (7).

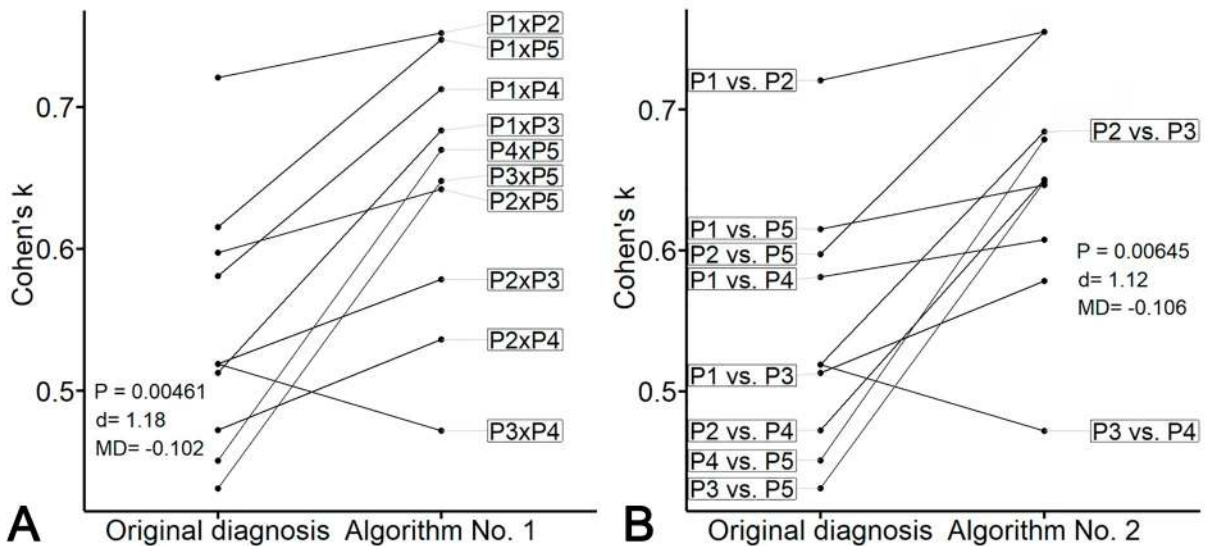
The inconsistencies outlined in the present study might also have stemmed from conflicting morphological criteria including non-infiltrative lesions with cellular atypia, equivocal stromal invasion, and presence of atypical mitoses in an otherwise benign lesion. Interestingly, stromal invasion, a criterion that has been interpreted as one of the most important for the diagnosis of malignancy by some authors (8, 10), showed only fair interobserver agreement for 3 out of the 10 pairs of pathologists. Such disparity might be explained by the difficulty that often exists in distinguishing between true stromal invasion and pseudoinvasion involving reactive fibroplastic tissue secondary to inflammation or necrosis with entrapment of pre-existent benign neoplastic cells. This difficulty has



**Figure 2.** Impact of the correction of mitotic count per 10 high-power fields to mitotic count per 2.37 mm<sup>2</sup> showing: (A) a decrease in intraclass correlation coefficient (ICC) after correction. (d, Cohen's effect size; MD, mean difference); (B) a negative correlation between microscope field number and mitotic count ( $\rho$ , Spearman correlation coefficient)



**Figure 3.** Diagnostic algorithms obtained by regression trees with recursive partitioning. (A) Algorithm 1. (B) Algorithm 2. Benign nodules comprise nodular hyperplasias and adenomas while malignant tumors comprise epitheliomas and carcinomas



**Figure 4.** Pairwise comparisons of diagnostic agreement between pathologists before (original diagnosis) and after the use of algorithm 1 (A) and algorithm 2 (B). P-values were obtained by paired t tests (d, Cohen's effect size; MD, mean difference)

been emphasized for some neoplasms, such as borderline ovarian tumors with microinvasion, in the distinction among colorectal adenomas and adenocarcinomas, and hepatocellular carcinomas (13, 17, 19).

Meuten et al. (22) recently stressed the importance of reporting mitoses per area rather than mitotic counts per field since microscopes may have different ocular field numbers. The impact of area correction on reproducibility of diagnosis was examined in the present study but interobserver agreement between pathologists worsened when mitotic counts per area were considered, with the ICC value falling from 0.63 (good agreement) to 0.55 (fair agreement). Further analysis of these results revealed a relationship between the use of microscopes with lower field numbers and pathologists who tended to ascribe higher mitotic counts, indicating that the agreement before correction had been overestimated. Although area is indeed a source of variation in reported mitotic counts, it would appear that additional factors should also be considered, including the time spent per case, the experience of the pathologist, the different lesioned areas assessed (e.g. tumoral borders, hotspots, random areas), and the specific definition of a mitotic figure employed by each pathologist (4, 36, 37).

Even after correcting for area, discrepancies of up to 5.5-fold were encountered in mean values of mitotic count between the five pathologists, with variations of up to 2.6-fold when the least experienced pathologist was excluded (data not shown). This finding may partly explain why different cut-off points for mitotic count are reported in different studies with similar designs. For example, in the case of canine mast cell tumors, Romansik et al. (26) proposed a cut-off point of 5 mitoses per 2.23mm<sup>2</sup> while Horta et al. (15) suggested 2 mitoses per 2.23mm<sup>2</sup>, even though both authors used prognostic features as endpoints. On this basis, it is important that cases with mitotic counts close to cut-off values should be considered borderline (at least where prognostic features are concerned) and ideal candidates for further assessment using more reproducible techniques such as Ki-67 immunohistochemistry (38).

The presence of mitotic figures in differentiated cells has been suggested as an important criterion for the diagnosis of malignancy in canine HGTs on the assumption that these cells are normally stable and non-proliferative and that their mitotic activity represents an aberrant replication process (10, 12). However, when this criterion was tested, interobserver agreement was found to be generally poor with fair agreement registered for only 3 out of the 10 pairs of pathologists. This finding suggests that there may be a degree of uncertainty as to which hepatoid cells should be considered differentiated or partially differentiated and which should be classified as reserve. Discrimination between cell types may be even more challenging when there is a higher level of disorganization of cell polarity, since the typical peripheral organization of reserve cells already presents varying degrees of disturbance. Hepatoid

glands, unlike sebaceous glands, contain a mix of small cells and cells with voluminous cytoplasm in the peripheral germinative component, and these could be classified as reserve cells (28).

Considering the low level of interobserver agreement between pathologists in the diagnosis of malignancy for canine HGTs, one aim of the present study was to develop diagnostic algorithms that might improve concordance. In this respect, both proposed algorithms showed evidence of improved agreement. In comparison with the conventional classification, the new systems would have a higher chance of detecting an aggressive lesion at the expense of a lower chance of detecting an indolent/benign one. It is important to emphasize that a new classification system may improve reproducibility but not necessarily clinical validity (23).

The present study was subject to some limitations that should be considered when interpreting the results. All participating pathologists were aware of the objectives of the reproducibility study and were provided with histological slides of cases but with no clinical information. It is possible, therefore, that the agreement rates obtained might not correspond exactly with the variation expected in a diagnostic setting. It is possible that pathologists use different approaches when undertaking a diagnosis in a 'real-life' setting in which they are aware of the impact of their decision on clinical management. Moreover, the availability of clinical data may have some degree of importance in decision making by suggesting one or other final diagnosis in morphological borderline cases. Thus, the agreement rates reported here should be interpreted as solely representative of the histomorphological criteria for the diagnosis of canine HGT.

In conclusion, the results presented in the current study show that interobserver agreement in the diagnosis of malignancy in HGTs was fair but could be improved to good by application of two novel diagnostic algorithms. Further analyses are warranted to validate the proposed classification systems applying other case sets of canine HGT, preferably with a higher number of clinically aggressive tumors.

#### **Acknowledgements**

The authors wish to thank the veterinary clinicians for providing the clinicopathological parameters relating to their patients.

#### **References**

1. Aleksić-Kovačević S, Kukulj V, Marinković D, Knežević MA. Retrospective study of canine epithelial and melanocytic tumors. *Acta Vet Beograd.* 2005;55:319-26.
2. Berrocal A, Vos JH, van den Ingh TS, Molenbeek RF, van Sluijs FJ. Canine perineal tumours. *J Vet Med A Physiol Pathol Clin Med.* 1989;36:739-49.

3. Cicchetti DV, Sparrow SA. Developing criteria for establishing interrater reliability of specific items: applications to assessment of adaptive behavior. *Am J MentDefic.*1981;86:127-37.
4. Clayton F. Pathologic correlates of survival in 378 lymph node-negative infiltrating ductal breast carcinomas. Mitotic count is the best single predictor. *Cancer.*1991;68:1309-17.
5. Fernandes CC, Medeiros AA, Magalhães GM, Szabó MPJ, Queiroz RP, Silva MVA, Soares NP.Frequência de neoplasias cutâneas em cães atendidos no hospital veterinário da Universidade Federal de Uberlândia durante os anos 2000 a 2010. *Biosci J.* 2015;31:541-8.
6. Finnie JW, Bostock DE. Skin neoplasia in dogs. *Australian Veterinary Journal.* 1979;55:602-4.
7. Ganguly A, Wolfe LG. Canine perianal gland carcinoma – associated antigens defined by monoclonal antibodies. *Hybridoma.* 2006;25:10-4.
8. Ginn PE, Mansell JEKL, Rakich PM. Skin and appendages. In: Maxie MG, editor.Jubb, Kennedy and Palmer’s Pathology of Domestic Animals. New York: Elsevier Saunders; 2007.p.553-781.
9. Goldschmidt MH. World Health Organization International Histologic Classification of Tumors of Domestic Animals. *Histological Classification of Tumors of the Skin of Domestic Animals.* Armed Forces Institute of Pathology, Washington; 1998.
10. Goldschmidt MH, Goldschmidt KH. Epithelial and melanocytic tumors of the skin. In: Meuten DJ, editor. *Tumors in Domestic Animals.* Hoboken:Wiley-Blackwell; 2016.p.88-141.
11. Goldschmidt MH, Shofer FS. *Skin Tumors of the Dog and Cat.* Oxford: Pergamon Press; 1992.
12. Gross TL, Ihrke PJ, Walder EJ, Affolter VK. Sebaceous tumors. In: Gross TL, Ihrke PJ, Walder EJ, Affolter VK, editors.*Skin Diseases of the Dog and Cat: Clinical and Histopathologic Diagnosis.*Oxford:Blackwell; 2005. p.641-64.
13. Hansen TP, Fenger C, Kronborg O. The expression of p53, Ki-67 and urokinase plasminogen activator receptor in colorectal adenomas with true invasion and pseudoinvasion. *Acta Pathol Microbiol Immunol Scand.* 1999;107:689-94.
14. Hayes HM, Wilson GP. Hormone-dependent neoplasms of the canine perianal gland. *Cancer Res.* 1977;37:2068-71.
15. Horta RS, Lavallo GE, Monteiro LN, Souza MCC, Cassali GD, Araújo RB. Assessment of canine mast cell tumor mortality risk based on clinical, histologic, immunohistochemical, and molecular features. *Vet Pathol.* 2018;55:212-23.
16. Kaldrymidou H, Leontides L, Koutinas AF, Saridomichelakis MN, Karayannopoulou M. Prevalence, distribution and factors associated with the presence and the potential for malignancy of cutaneous neoplasms in 174 dogs admitted to a clinic in northern Greece. *J Vet Med A PhysiolPathol Clin Med.* 2002;49:87-91.
17. Kim KR, Lee HI, Lee SK, Ro JY, Robboy SJ. Is stromal microinvasion in primary mucinous ovarian tumors with “mucin granuloma” true invasion? *Am J Surg Pathol.* 2007;31:546-54.
18. Kimura KC, Gárate AP, Dagli MLZ.Retrospective study of neoplasms in domestic animals: A survey between 1993 and 2002 of the Service of Animal Pathology, Department of Pathology, School of Veterinary Medicine and Animal Science, University of São Paulo, Southeast Brazil. *Braz J Vet Pathol.* 2002;5:60-9.
19. Kondo F. Assessment of stromal invasion for correct histological diagnosis of early hepatocellular carcinoma. *Int J Hepatol.*2011;241652.
20. Mauldin EA, Peters-Kennedy J. Integumentary System. In: Maxie MG, editor.Jubb, Kennedy and Palmer’s Pathology of Domestic Animals.New York:Elsevier Saunders; 2016. p. 509-736.
21. Meirelles AEWB, Oliveira EC, Rodrigues BA, Costa RG, Sonne L et al.Prevalência de neoplasmas cutâneos em cães da região metropolitana de Porto Alegre, RS: 1.017 casos (2002-2007). *Pesq Vet Bras.* 2010;30:968-73.
22. Meuten DJ, Moore FM, George JW. Mitotic count and the field of view area: time to standardize. *VetPathol.* 2016;53:7-9.
23. Nakhleh RE. Standardization of diagnostic terminology and criteria: A prelude for error reduction. In: Nakhleh RE, editor.*Error Reduction and Prevention in Surgical Pathology.* Berlin:Springer; 2015. p.115-26.
24. Nielson SW, Attosmis J. Canine perianal gland tumors. *J Am Vet Med Assoc.* 1964;144:127-35.
25. Pakhrin B, Kang MS, Bae IH, Park MS, JeeH, You MH, Kim JH, Yoon BI, Choi YK, Kim DY.Retrospective study of canine cutaneous tumors in Korea. *J Vet Sci.* 2007;8:229-36.
26. Romansik E, Reilly C, Kass P, Moore P, London CA. Mitotic index is predictive for survival for canine cutaneous mast cell tumors. *Vet Pathol.* 2007;44:335-41.
27. Rothwell TLW, Howlett CR, Middleton DJ, Griffiths DA, Duff BC. Skin neoplasms of dogs in Sydney. *Aust Vet J.*1987;64:161-4.
28. Shabadash SA, Zelikina TI.Once more about hepatoid circumanal glands of dogs; history of their discovery and causes of revision of their structure and function. *IzvAkadNauk Ser Biol.* 2002;29:176-85.
29. Shrout PE, Fleiss JL. Intraclass correlations: uses in assessing rater reliability. *Psychol Bull.* 1979;86:420-8.
30. Silva J. Um caso de adenocarcinoma das glândulas hepatóides com metastatização extensa. *RevPortCienc Vet.* 2002;118:31-2.
31. Silva JF, Peleteiro MC, Correia JJ. Hiperplasia e tumores das glândulas hepatóides: Estudo retrospectivo (1995 - 2001). *Rev Port Cienc Vet.* 2002;118:32.

32. Simeonov R, Dinev I, Simeonova G, Goranov N, Paskalev M, Krastev S, Todorova I, Chaprazov T, Roidev R, Borissov I, Hubenov H, Dinev D, Simeonov S, Chaprazov T. Prevalence of canine epithelial, melanocytic and mesenchymal tumours of the skin and soft tissues: A 10-year study. *Bulg J Vet Med.* 2011;14:171-8.
33. Souza TM, Figuera RA, Irigoyen LF, Barros CSL. Estudo retrospectivo de 761 tumores cutâneos em cães. *Cienc Rural.* 2006;36:555-60.
34. Tostes RA, Branco A, Cestari FK, Caleffo T, Viott ADM. Retrospective study of canine cutaneous neoplasia. *Arch Vet Sci.* 2017;22:71-80.
35. Tunc AS, Alcigir ME, Atalay Vural S. Concurrent metastatic hepatoid gland carcinoma and eosophagogastric leiomyosarcoma in a dog. *Ankara Univ Vet Fak Derg.* 2014;61:29-34.
36. Veta M, van Diest PJ, Jiwa M, Al-Janabi S, Pluim JP. Mitosis counting in breast cancer: Object-level interobserver agreement and comparison to an automatic method. *PloS One.* 2016;11:e0161286.
37. Vollmer RT. A probabilistic analysis of mitotic counts in melanoma. *Am J Clin Pathol.* 2014;141:213-8.
38. Warth A, Fink L, Fisseler-Eckhoff A, Jonigk D, Keller M, Ott G, Rieker RJ, Sinn P, Söder S, Soltermann A, Willenbrock K, Weichert W; Pulmonary Pathology Working Group of the German Society of Pathology. Interobserver agreement of proliferation index (Ki-67) outperforms mitotic count in pulmonary carcinoids. *VirchowsArchiv.* 2013;462:507-13.