Braz J Vet Pathol, 2022, 15(3), 127 – 132
DOI: 10.24070/bjvp.1983-0246.v15i3p127-132

BJVP
Brazilian Journal of Veterinary Pathology
ISSN 1983-0246

Original Full Paper

Canine splenic tumors: Histopathological study of 9 cases in Uruguay, 2019-2020

Belén Varela[1]*, Camila Larrañaga[1], Kanji Yamasaki[1], José Manuel Verdes[1]

[1] Unidad Patología, Departamento de Patobiología, Facultad de Veterinaria, Universidad de la República. Av. Alberto Lasplaces 1620, CP 11600, Montevideo, Uruguay

***Corresponding author:** E-mail: belenvarela42@gmail.com

Submitted December, 9th 2020, Accepted July, 13th 2022

Abstract

There are no reports of what kind of spleen tumors have developed within a certain period of time in Uruguay. Therefore, we investigated spleen tumors that were surgically resected and brought into our laboratory for a year (2019-2020). As a result, 9 splenic tumors were observed. Hemangiosarcomas occurred at the highest incidence in 6 of 9 cases. In addition, 1 case each of lymphoma, fibrosarcoma, and perivascular wall tumor was observed. Furthermore, the perivascular wall tumor, which has not been reported so far, was observed in a seven years-old female Cocker Spaniel.

Key words: dogs, pathology, spleen, tumor.

Introduction

Hemangiosarcoma has been described as the most common splenic tumors in dogs in some countries (1,3,8,10), and lymphoma has been well documented in the spleen (18). In addition, splenic tumors such as osteosarcoma, fibrosarcoma, leiomyosarcoma, liposarcoma, chondrosarcoma, myxosarcoma, perivascular cell tumor and rhabdomyosarcoma have also been reported (1,11,15,19). In South America, there have been no reports of histopathologic typification and epidemiologic study of spleen tumor has developed within a period. Therefore, we morphologically examined surgically resected splenic tumors brought to our laboratory for one year in order to investigate frequency of spleen tumors in Uruguay.

Materials and methods

Samples of 9 spleen tumors surgically removed from canines by private veterinary clinics from 2019 to 2020 were referred to the Diagnostic Pathology Laboratory of Facultad de Veterinaria – Universidad de la República (Montevideo, Uruguay) for histopathological diagnosis. The breeds examined were: Labrador Retriever (3/9), Crossbred (2/9), German Shepherd (1/9), Rodeshian ridgeback (1/9), Golden Retriever (1/9) and Cocker spaniel (1/9). There were 4 males and 5 females. The mean age of dogs was 9.6 years old (range 7-12 y. o.). Samples were fixed in 10% buffered formalin solution, processed, sectioned at 4 µm, stained with hematoxylin-eosin (H&E). Histopathological examination was performed under light microscopy by four veterinary pathologists (BV, CL, KY, JMV). The expression of the Factor VIII marker was evaluated in the selected samples according to protocols previously established by other authors (7,12,13). For this study, tissue sections were deparaffinized with xylen and hydrated through a series of decreasing gradation of passages in ethanol (100°, 95°, 70°). A 3% peroxidase blockade pre-treatment was performed, then heat-mediated antigen retrieval was carried out in a steamer (Panavox, China), keeping the histological slides submerged in 0.01 M citrate buffer at pH 6 .0 inside a polypropylene Coplin jar (Deltalab, Spain) for 30 min. The primary antibody was placed on the sample of the preparation, and they were left in a humid chamber at 4 °C overnight. The next morning, the detection system (Mouse-on-canine HRP-polymer, Biocare Medical , USA) and Streptavidin peroxidase were added. The visualization of the labeling was achieved from the use of Diaminobenzidine for 3 to 5 min., controlling the evolution of the process by permanent observation of the preparation under a microscope. Samples were counterstained with Mayer's hematoxylin.

Brazilian Journal of Veterinary Pathology. www.bjvp.org.br . All rights reserved 2007-2022.

Braz J Vet Pathol, 2022, 15(3), 127 – 132
DOI: 10.24070/bjvp.1983-0246.v15i3p127-132

Table 1. Data, histopathological and immunohistochemical (IHC) diagnosis in each case

Case Nº.	Breeds	Sex	Age (years)	Histological diagnosis	IHC against Factor VIII
1	Rodeshian ridgeback	Female	9	Hemangiosarcoma (capillary type)	Positive
2	Crossbred	Male	9	Hemangiosarcoma (capillary type)	Positive
3	German shepherd	Male	12	Hemangiosarcoma (capillary type)	Positive
4	Labrador Retriever	Male	12	Hemangiosarcoma (capillary type)	Positive
5	Cross	Female	11	Hemangiosarcoma (carvenous type)	Positive
6	Golden Retriever	Male	7	Hemangiosarcoma (solid type)	Positive
7	Labrador Retriever	Female	7	Lymphoma	Negative
8	Labrador Retriever	Female	12	Fibrosarcoma	Negative
9	Cocker spaniel	Female	7	Perivascular wall tumor	Negative

Positive controls were performed according to the manufacturer's instructions. For the negative controls, the primary antibody was replaced in samples of the same tissues by PBS, which were run in parallel and at the same time as the samples to which the primary antibody was added.

Results

Of the 9 cases under study, 6 came from the city of Montevideo, 2 from Canelones and 1 from Florida. Macroscopically, 4 of them presented a nodular neoplastic growth while 3 showed a diffuse growth. 2 of them have no macroscopic description. Hemangiosarcoma was found in 6 cases, and in each case fibrosarcoma, lymphoma, and perivascular wall tumor were also found (Table 1). Multiple primaries were not found. In hemangiosarcoma, the neoplastic cells often had prominent, bulging nuclei that were pleomorphic and hyperchromatic with mitoses in all cases. According to the main growth patterns of hemangiosarcoma, the capillary type was demonstrated in 4 cases, and the cavernous and solid types in 1 case, respectively (Figs. 1, 2 and 3). In the capillary histological type, the growth pattern was infiltrative, the neoplastic cells were arranged in monolayers or multiple layers along the collagen trabeculae or collagen fibers, forming irregular blood vessels. No invasion to blood or lymphatic vessels was observed, the maximum mitotic rate was 3 mitoses per 10 high-resolution fields. The neoplastic cells in the capillary hemangiosarcomas presented low pleomorphism and one of the cases presented atypical mitoses and more than 10 cells with multiple nuclei in 10 high-resolution fields. In the cavernous type, the growth pattern was expansive, without invasion of blood and/or lymphatic vessels, the neoplastic blood vessels were generally separated by fibrous connective tissue. In this case, the blood vessels varied in size and were often filled with blood cells. The cells of this tumor type presented a mitotic index of 2 mitoses per 10 high-resolution fields, their cells showed low pleomorphism and a high nucleus-to-cytoplasm ratio, more than 10 cells in 10 high-resolution fields showed multiple nuclei. Finally, in the case of the solid type, the growth pattern was non-infiltrative, the neoplastic proliferation was composed of solid cords of neoplastic cells that retained the ability to form vascular channels and some of them invaded normal blood vessels. Its mitotic index was 10 per high resolution field, presenting high pleomorphism, 4 atypical mitoses and more than 10 cells with multiple nuclei in 10 high resolution fields. Neoplastic cells had a 1:1 nucleus-cytoplasma ratio.

In another case, the marginal zone of lymphoid follicles proliferated, resulting in blurred borders between adjacent lymphoid follicles (Fig. 4). Lymphocytes in the proliferating marginal zone were rich in cytoplasm with medium-sized round to elliptical nuclei with clear chromatin, but no mitoses were observed. The neoplastic cells invaded blood and lymphatic vessels. This case was finally diagnosed as marginal zone lymphoma.

A fibrosarcoma composed of intertwined bundles of immature fibroblasts that produce collagen (Fig. 5) and invade blood vessels. In addition, mucin production was also detected in some areas. The growth pattern was expansive with a line of demarcation separating cell proliferation from an area of necrosis. Nuclear dysplasia, cells with multiple nuclei, and mitoses were frequently observed in tumor cells. High nucleus-cytoplasm ratio in these cells.

The final case reported here was a perivascular wall tumor whose growth pattern was infiltrative, characterized by the formation of concentric layers of spindle-shaped tumor cells centered around small blood vessels (Fig. 6). Most of the neoplastic cells were spindle cells, but occasionally polygonal cells and multinucleated cells were also found, producing collagen, with large nuclei in relation to the cytoplasm, the mitotic index was 8 mitoses per 10 high-resolution fields, without cells with atypical mitoses or multiple nuclei.

Immunohistochemistry performed with von Willebrand Factor-related antigen confirmed the presence of strongly marked neoplastic endothelial cells in capillary (Fig. 7), cavernous (Fig. 8), and solid (Fig. 9) hemangiosarcoma. The fibrosarcoma (Fig. 10), the perivascular tumor (Fig. 11) and the lymphoma (Fig. 12) did not show any labeling in the neoplastic cells. The normal vessels of the different specimens were used as positive controls of the technique.

Brazilian Journal of Veterinary Pathology. www.bjvp.org.br . All rights reserved 2007-2022.

Braz J Vet Pathol, 2022, 15(3), 127 – 132
DOI: 10.24070/bjvp.1983-0246.v15i3p127-132

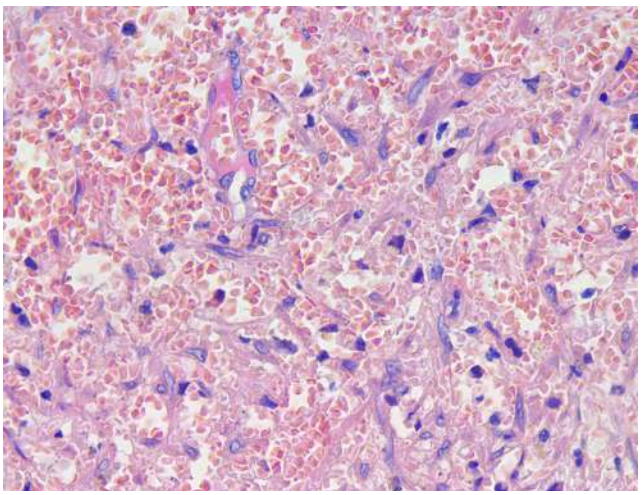

Figure 1. Hemangiosarcoma. Capillary type. Vascular spaces formed by single and multiple layers of neoplastic cells supported by collagen trabeculae and collagen fibers (H&E, 400x).

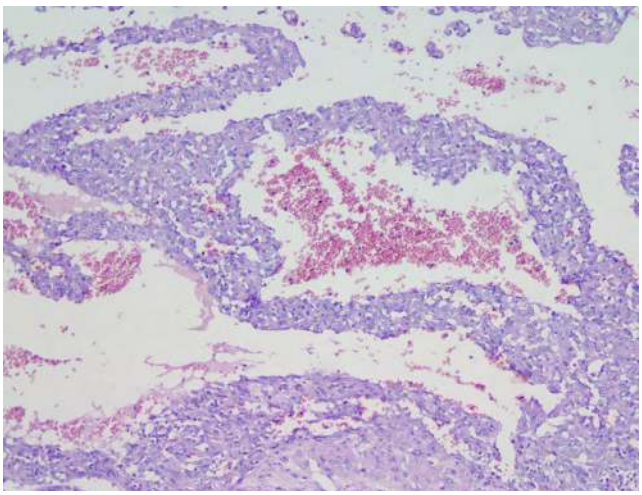

Figure 2. Hemangiosarcoma. Cavernous type. Neoplasic blood vessels of variable size and separated by fibrous tissue (H&E, 400x).

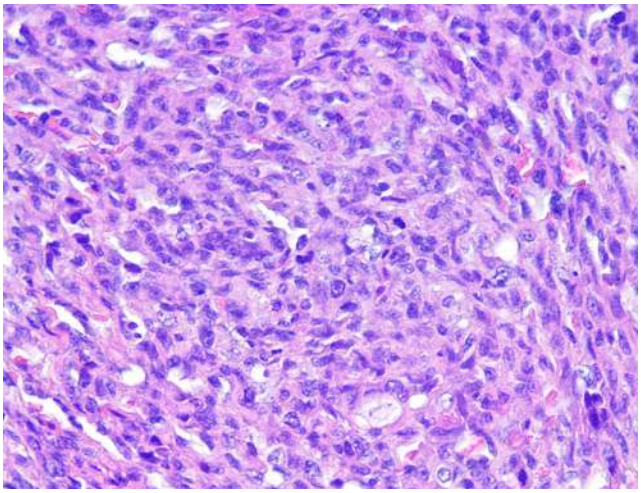

Figure 3. Hemangiosarcoma. Solid type. Solid cords formed by proliferating spindle cells surrounding small vascular channels (H&E, 400x).

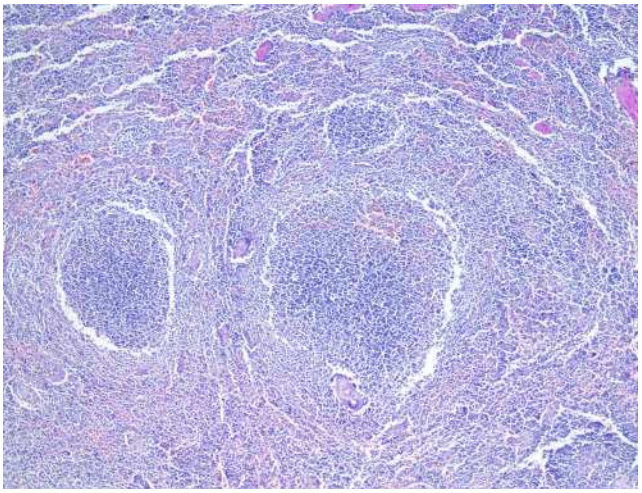

Figure 4. Lymphoma. Unclear borders between lymphoid follicles with proliferation of the marginal zone (H&E, 100x).

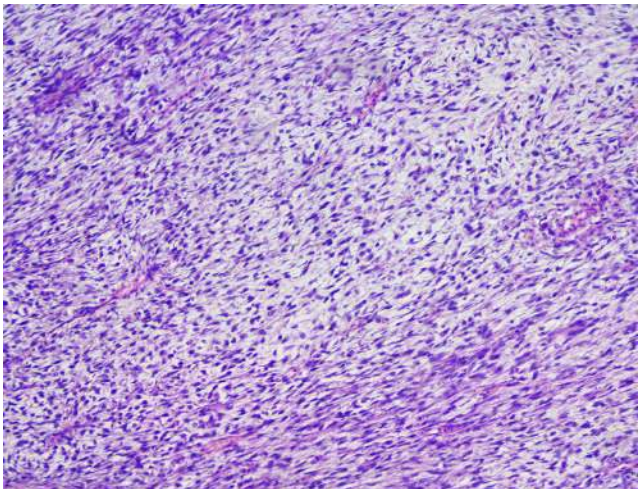

Figure 5. Fibrosarcoma. Spindle-shaped fibroblast cells arranged in intersected and interlaced bundles with collagenous intracellular substance (H&E, 100x).

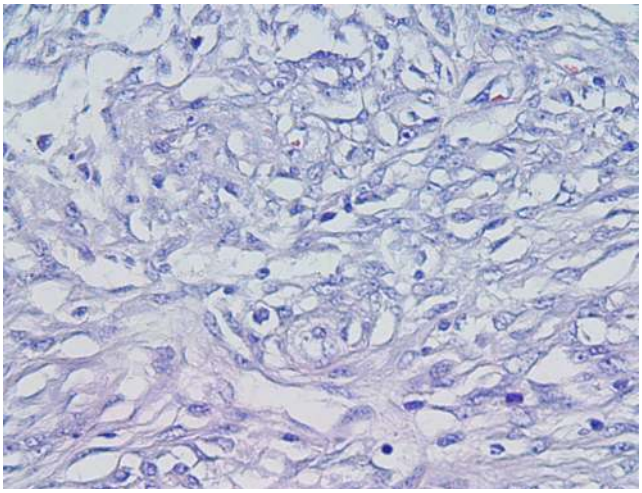

Figure 6. Perivascular wall tumor. Concentric formation of proliferating spinoid cells around small blood vessels (H&E, 100x).

Brazilian Journal of Veterinary Pathology. www.bjvp.org.br . All rights reserved 2007-2022.

Braz J Vet Pathol, 2022, 15(3), 127 – 132
DOI: 10.24070/bjvp.1983-0246.v15i3p127-132

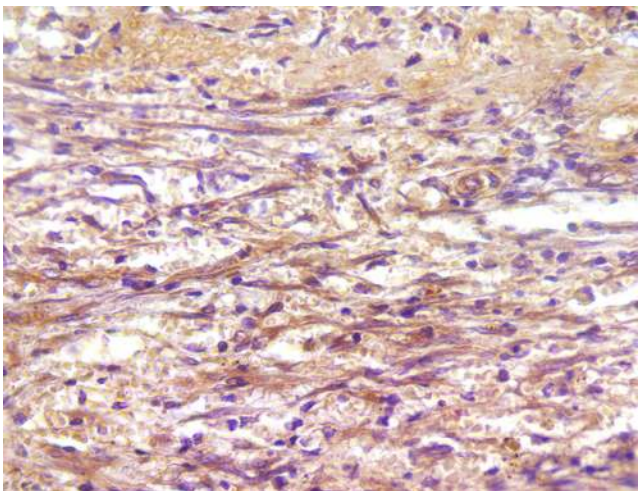

Figure 7. Hemangiosarcoma. Capillary type. Positive immunostaining against von Willebrand factor related antigen (IHC against factor VIII–related antigen, 100x).

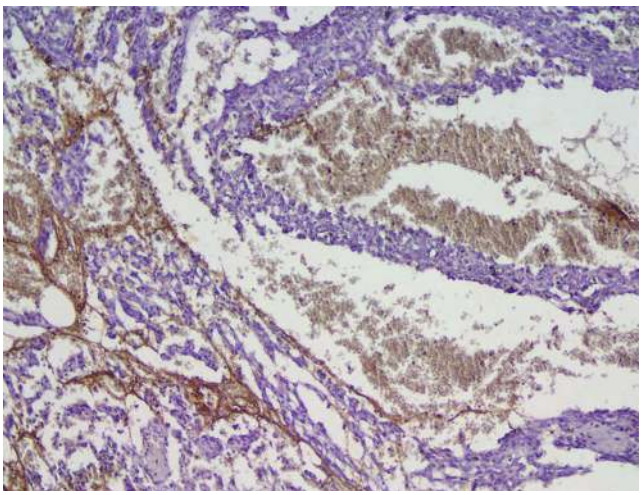

Figure 8. Hemangiosarcoma. Cavernous type. Positive immunostaining against von Willebrand factor related antigen (IHC against factor VIII–related antigen, 100x).

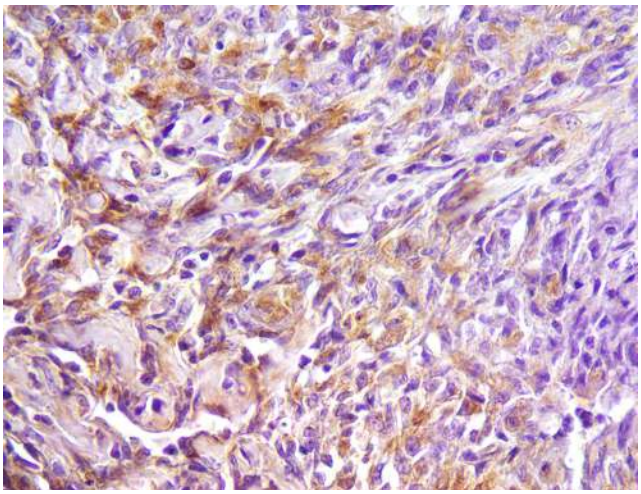

Figure 9. Hemangiosarcoma. Solid type. Positive immunostaining against von Willebrand factor related antigen (IHC against factor VIII–related antigen, 100x).

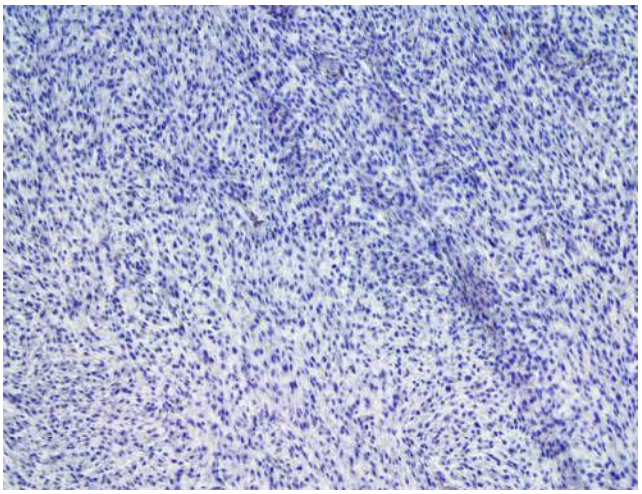

Figure 10. Fibrosarcoma. Negative immunostaining against von Willebrand factor related antigen (IHC against factor VIII–related antigen, 100x).

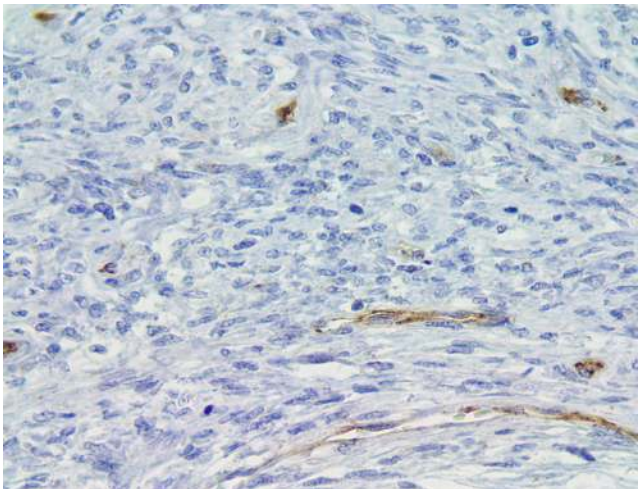

Figure 11. Perivascular wall tumor. Negative immunostaining against von Willebrand factor related antigen (IHC against factor VIII–related antigen, 100x).

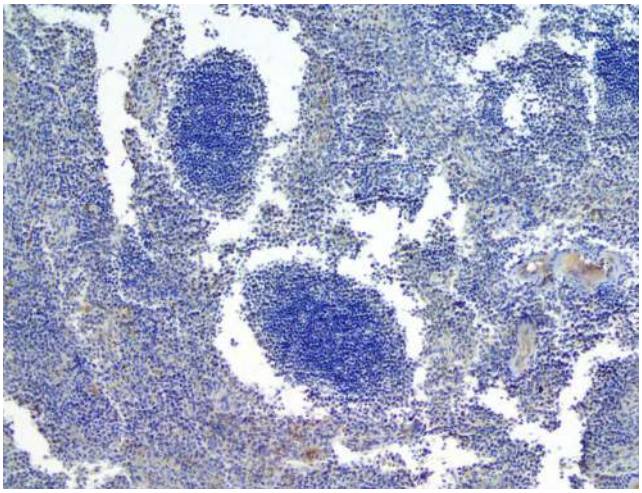

Figure 12. Lymphoma. Negative immunostaining against von Willebrand factor related antigen (IHC against factor VIII–related antigen, 40x).

Brazilian Journal of Veterinary Pathology. www.bjvp.org.br . All rights reserved 2007-2022.

Braz J Vet Pathol, 2022, 15(3), 127 – 132
DOI: 10.24070/bjvp.1983-0246.v15i3p127-132

Discussion

It is well known that hemangiosarcoma and lymphoma are frequent tumors of the spleen. Hemangiosarcoma has been reported to be present in about 20-40% of splenic abnormalities (1,3). It has also been reported that 80% of hemangiosarcomas were found in the biopsy materials of the abnormal spleens (10). The most common tumor in this study was hemangiosarcoma, which accounted for 60%. Hemangiosarcoma has been described to be divided into various growth patterns (2,4,9,17). In the present hemangiosarcomas, capillary growth patterns occurred most frequently in 4 out of 6 cases. The epithelioid growth pattern is considered to be highly malignant (14), but it was not observed in this study. The lymphoma described here was diagnosed as marginal zone lymphoma based on its morphological pattern. This type of lymphoma has been reported to occur frequently in dogs (11,18).

The mesenchymal sarcomas such as osteosarcoma, fibrosarcoma, leiomyosarcoma, liposarcoma, chondrosarcoma, myxosarcoma, hemangiopericytoma and rhabdomyosarcoma have been reported as non-angiogenic and non-hematogenic splenic sarcomas (1,11,15,19). In this study, fibrosarcoma was observed in one case. Fibrosarcoma was diagnosed based on the results of morphological characteristics. On the other hand, perivascular wall tumor (hemangiopericytoma) was found in one case. This tumor is known to occur in the skin (6). To our knowlegemente, only one case of splenic perivascular wall tumor has been reported (11). According to information from the veterinarian surgeon, this case was not associated with a skin tumor. In addition, the perivascular tumors of the skin have been reported to have spread to the lungs, breast, internal iliac lymph nodes and lumbar lymph nodes (5,16), but not to the spleen. Therefore, we suggested that the tumor described here was a primary splenic tumor.

In conclusion, morphological studies were performed on 9 surgically removed splenic tumors brought to our laboratory for one year. As a result, hemangiosarcoma was found in 6 cases, and lymphoma, fibrosarcoma and perivascular wall tumor were found in 1 case each.

References:

1. Day MJ, Lucke VM, Pearson H. A review of pathological diagnoses made from 87 canine splenic biopsies. J Small Anim Prac. 1995;36:426-433.
2. Dickerson EB, Thomas R, Fosmire SP, et al. Mutations of phosphatase and tensin homolog deleted from chromosome 10 in canine hemangiosarcoma. Vet Pathol. 2005;42:618-632.
3. Fernandez S, Lang JM, Maritato KC. Evaluation of Nodular Splenic Lesions in 370 Small-Breed Dogs (<15 kg). J Am Anim Hosp Assoc. 2019;55:201-209.
4. Gorden BH, Kim JH, Sarver AL, et al. Identification of three molecular and functional subtypes in canine hemangiosarcoma through gene expression profiling and progenitor cell characterization. Am J Pathol. 2014;184:985-995.
5. Handharyani E, Ochiai K, Kadosawa T, Kimura T, Umemura T. Canine hemangiopericytoma: an evaluation of metastatic potential. J Vet Diagn Invest. 1999;11:474-478.
6. Hendrick, MJ. Mesenchymal Tumors of the Skin and Soft Tissues. In: Meuten, DJ. Editor. Tumors in Domestic Animals. 5th ed., Iowa: Wiley Blackwell; 2017. p.142-175.
7. Jennings, R. N., Miller, M. A., & Ramos-Vara, J. A. Comparison of CD34, CD31, and factor VIII–related antigen immunohistochemical expression in feline vascular neoplasms and CD34 expression in feline nonvascular neoplasms. Veterinary pathology. 2012;49:532-537.
8. Johnson KA, Powers BE, Withrow SJ, et al. Splenomegaly in dogs. Predictors of neoplasia and survival after splenectomy. J Vet Intern Med. 1989;3:160-166.
9. Kim JH, Graef AJ, Dickerson EB, et al. Pathobiology of hemangiosarcoma in dogs: Research advances and future perspectives. Vet Sci. 2015;2:388-405.
10. Leyva FJ, Loughin CA, Dewey CW, et al. Histopathologic characteristics of biopsies from dogs undergoing surgery with concurrent gross splenic and hepatic masses: 125 cases (2012–2016). BMC Res Notes. 2018;11:12.
11. Obwolo ML. Primary splenic haemangiopericytoma in a German Shepherd Dog. J Comp Pathol. 1986;96:285-288.
12. Ramos-Vara, J. A., & Beissenherz, M. E. (2000). Optimization of immunohistochemical methods using two different antigen retrieval methods on formalin-fixed, paraffin-embedded tissues: experience with 63 markers. Journal of Veterinary Diagnostic Investigation. 2000;12:307-311.
13. Ramos-Vara, J. A., Miller, M. A., Gilbreath, E., & Patterson, J. S. Immunohistochemical detection of CD34, E-cadherin, claudin-1, glucose transporter 1, laminin, and protein gene product 9.5 in 28 canine and 8 feline meningiomas. Veterinary Pathology. 2010;47:725-737.
14. Sabattini S, Lopparelli RM, Rigillo A, et al. Canine splenic nodular lymphoid lesions: Immunophenotyping, proliferative activity, and clonality assessment. Vet Pathol. 2018;55:654-653.
15. Shor S, Helefard SC, Gorman E, et al. Diagnostic exercise: epithelioid hemangiosarcoma mimicking metastatic prostatic neoplasia in a dog. Vet Pathol. 2009;46:548-552.
16. Spangler WL, Culbertson MR, Kass PH. Primary mesenchymal (nonangiomatous/nonlymphomatous) neoplasms occurring in the canine spleen: anatomic classification, immunohistochemistry, and mitotic activity correlated with patient survival. Vet Pathol. 1994;31:37-47.

 All rights reserved 2007-2022.

Braz J Vet Pathol, 2022, 15(3), 127 – 132
DOI: 10.24070/bjvp.1983-0246.v15i3p127-132

17. Postorino NC, Berg RJ, Powers BE, et al. Prognostic variables for canine hemangiopericytoma: 50 cases (1979–1984). J Am Anim Hosp Assoc. 1988;24:501-509.
18. Valli VE, Bienzle D, Meuten DJ. Tumors of the hemolymphatic system. In: Meuten, DJ. Editor. Tumors in Domestic Animals. 5th ed., Iowa: Wiley Blackwell; 2017. p.209-321.
19. Valli VE, Vernau W, De Lorimier L P, et al. Canine indolent nodular lymphoma. Vet Pathol. 2006;43:241-256.
20. Weinstein MJ, Carpenter JL, Schunk CJ. Nonangiogenic and nonlymphomatous sarcomas of the canine spleen: 57 cases (1975-1987). J Am Vet Med Assoc. 1989;195:784-788.

Brazilian Journal of Veterinary Pathology. www.bjvp.org.br . All rights reserved 2007-2022.