Braz J Vet Pathol, 2022, 15(3), 143 – 146
DOI: 10.24070/bjvp.1983-0246.v15i3p143-146

BJVP
Brazilian Journal of Veterinary Pathology
ISSN 1983-0246

Case Report

Adenosquamous carcinoma in the palate of a dog: case report

Ana Laura Paulino Leite Gomes[1], Daniela Farias da Nóbrega[2], Patrícia Bruder Azzem[3], Dóris Bruder[3], Ana Paula Frederico Rodrigues Loureiro Bracarense[1]*

[1] Laboratory of Animal Pathology, Universidade Estadual de Londrina, Rodovia Celso Garcia Cid, km 380, 86057-970, Londrina, PR, Brazil.
[2]Laboratory Pat Animal, 1450 St Regente Feijó, 15070-000 São José do Rio Preto, SP, Brazil.
[3]Veterinary Clinic Dra. Dóris Bruder, 488 St Santos Dumont, 15013-100, São José do Rio Preto, SP, Brazil.

***Corresponding author:** Phone: +55 43 3371 4485. E-mail: anapaula@uel.br .

Submitted April, 17th 2022, Accepted October, 22th 2022

Abstract

Adenosquamous carcinoma is characterized by the simultaneous presence of squamous and glandular components. This article reports a case of adenosquamous carcinoma in the oral mucosa in a dog. Microscopically, the tumour revealed an infiltrative epithelial proliferation with a tubular pattern and areas of squamous differentiation. In the lumina of the tubules, there were eosinophilic material (mucin). The alcian blue staining showed positive intraluminal material and the cytoplasm of neoplastic cells were immunoreactive for cytokeratin, supporting the diagnosis of adenosquamous carcinoma. The cells exhibited reduced or negative immunoreactivity for E-cadherin, which could be associated with more aggressive tumour behaviour and worse prognosis.

Key words: Neoplasia, epithelial, oral

Introduction

Squamous cell carcinoma (SCC) is a malignant neoplasm originating from cells in the stratum spinosum of the epithelium with dyskeratosis and high infiltrative capacity, although rarely metastasizing (14). The aetiology of oral SCC in dogs is unknown, but it has been established that exposure to tobacco and alcohol and papillomavirus infection are reported as important risk factors for humans (8). It is considered the third most common oropharyngeal neoformation in dogs and macroscopically shows varied aspects (13).

The SSC's histological grading is performed by analysing the degree of keratinization, nuclear pleomorphism, mitotic rate and cellularity (7). There is a classification of histological subtypes: conventional, adenosquamous, acantholytic, papillary, basaloid and spindle cell (9). This paper reports a case of an adenosquamous carcinoma (ASC) of the palate in a dog.

Case description

A 10-year-old intact male mixed breed dog, presenting dysorexia, prostration, apathy, and emaciation, was presented for clinical evaluation. The owner reported that the animal was using prednisolone 5 mg once a day for 5 years. An infiltrative and poorly delimited mass of the palate mucosa was identified, and a biopsy was performed.

Gross examination revealed a mass measuring 3.2 x 2.5 x 1.6 cm, firm, multinodular, heterogeneous, and whitish with red areas. The sample was fixed in 10% buffered formalin solution, embedded in paraffin, sectioned at 4µm, and stained with haematoxylin and eosin (HE) and alcian blue. Immunohistochemistry for determination of the expression of cytokeratin (Pan Cytokeratin Plus [AE1/AE3+8/19], dilution 1:100, BioCare Medical, California, USA) and E-cadherin (Mouse anti-E-Cadherin [clone: 4A2C7], dilution 1:50, Invitrogen, Massachusetts, USA) was performed according to the specifications of manufactures.

 All rights reserved 2007-2022.

Braz J Vet Pathol, 2022, 15(3), 143 – 146
DOI: 10.24070/bjvp.1983-0246.v15i3p143-146

Microscopically, a proliferation of epithelial cells contiguous with the mucosa, forming tubules (Fig. 1A), sometimes with areas of squamous differentiation (Fig. 1B) and rare keratin "pearls" was observed in the submucosa. In the lumina of the tubules, discrete acantholytic cellular components and eosinophilic material (mucin) were detected. These cells were round to polygonal, with distinct eosinophilic cytoplasm. Nuclei were large, central, vesicular and with one or two large and distinct nucleoli. There was moderate pleomorphism, anisocytosis and anisocariosis (Fig. 1C). There was a high nucleus: cytoplasm ratio and 19 mitotic figures in 10 fields (400x magnification). A moderate intratumoral polymorphonuclear inflammatory infiltrate was observed intermingled with the moderate fibrovascular stroma.

The alcian blue staining showed positive intraluminal material in some tubules (mucin) (Fig. 1D). Immunohistochemically, the neoplastic cells were strongly positive for cytokeratin (Fig. 1E) and exhibited negative or weak E-cadherin immunostaining (Fig. 1F). Morphological, histochemical and immunohistochemical features are compatible with the diagnosis of ASC.

Twenty days after the biopsy, chemotherapy protocols were performed with carboplatin (300 mg/m2), six cycles, associated with metronomic chemotherapy with cyclophosphamide (15 mg/m2) daily for 60 days. After 60 days, the animal presented swelling in the ventral cervical region and respiratory distress. The computed tomography exam performed with the technique of 4-channel multi slice helical, 3.75 x 1.87 mm, with the administration of intravenous contrast medium (Gadopentetate dimeglumine), obtained the diagnostic impression of neoformation in the soft palate, epiglottis, and right palatine tonsil with bone involvement of the hyoid apparatus and right mandibular and retropharyngeal lymphadenopathy.

After another 60 days, an increase in tumour growth was observed, and two more cycles of chemotherapy were performed (same protocol) and electrochemotherapy with bleomycin (15000 UI/m2). The seventh cycle of chemotherapy was prescribed with mitoxantrone (5 mg/m2). After one month, the animal was hospitalized in status epilepticus, progressing to cardiorespiratory arrest, and died. The necropsy was not performed.

Discussion

ASC is a rare, aggressive and highly invasive variant of SCC (15). Histologically, it is characterized by the simultaneous and distinct presence of two components: glandular and squamous (2). This neoplasm has already been described in the lung, oesophagus, and ileum (16,10,19). In the literature, there is only one report of this subtype in the oral mucosa of animals (1) and a retrospective study of histological subtypes of oral SCC in dogs reporting a 3,6% incidence of ASC (9).

Differential diagnoses for oral ASC include mucoepidermoid carcinoma of minor salivary gland origin, conventional SCC with ductal involvement, basaloid SCC, and acantholytic SCC (17). Mucoepidermoid carcinoma of minor salivary gland origin frequently occurs in the oral cavity presenting proliferation of epidermoid cells without the formation of keratin, unlike ASC, which has areas of squamous differentiation (5).

Conventional SCC with ductal involvement occurs when neoplastic cells replace normal ductal cells. The abrupt transition from normal ductal epithelium to carcinoma is an important morphological feature for differentiation (15). The basaloid SCC is composed of basaloid and squamous components and is characterized by solid, large, rounded clumps of basaloid cells with comedo necrosis, a feature not observed in the ASC (12).

Acantholytic SCC is characterized by a neoplastic component of conventional squamous cell, in a pseudoglandular or pseudovascular pattern, with single or grouped acantholytic and dyskeratotic epithelial cells in the pseudolumen (4). Differently from ASC, acantholytic SCC shows no intraepithelial and intraluminal sialomucin in ductal structures (11). Therefore, the alcian blue staining, which identifies the sialomucin, it is possible to differentiate these two subtypes (6). The present case shows positivity for alcian blue in some tubules, which indicates that these tubular structures are truly of adenocarcinomatous differentiation and associated with areas of squamous differentiation allow the diagnosis of ASC.

The reduction or absence of E-cadherin expression in oral squamous cell carcinoma is associated with more aggressive tumour behaviour and worse prognosis (3), however, there are no data on the expression of this intercellular adhesion molecule in oral ASC.

The treatment of choice is wide surgical excision, which may be curative for tumours located more rostrally. The use of drugs such as carboplatin, the use of photodynamic therapy and electrochemotherapy are also indicated (18). Due to the location of the tumor in this case, complete surgical excision was not possible, and despite adjuvant treatments, the animal died 170 days after diagnosis.

This is a rare report of ASC in the palate of a canine. This neoplasm is a malignant and clinically aggressive lesion in dogs and should be considered as a differential diagnosis in oral mucosa tumours.

Conflict of Interest Statement

The authors declare no competing interest with respect to the publication of this manuscript.

Funding

This research did not receive any specific grant from funding agencies in the public, commercial, or not-for-profit sectors.

Brazilian Journal of Veterinary Pathology. www.bjvp.org.br . All rights reserved 2007-2022.

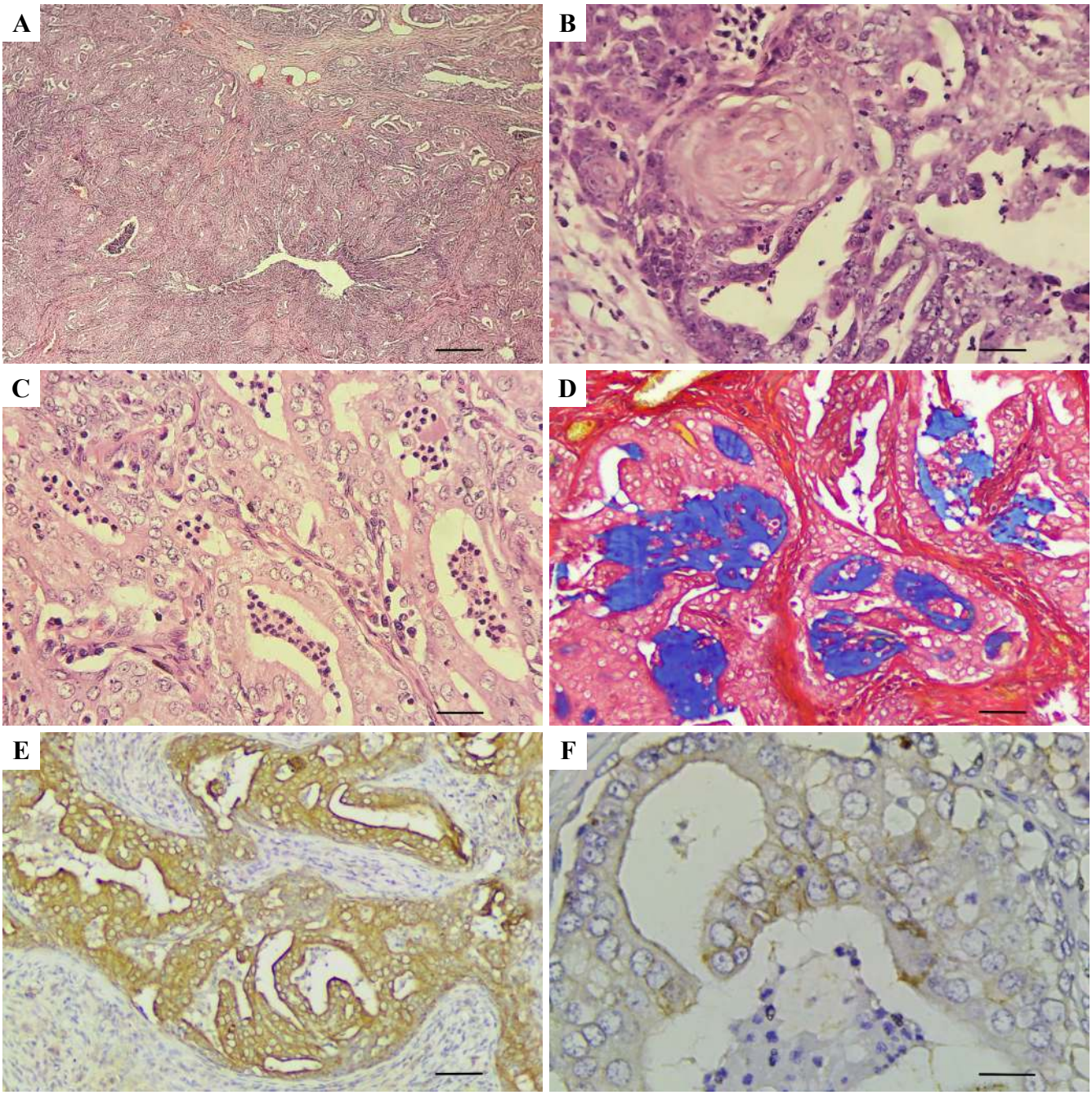

Figure 1. Oral mucosa; dog. Adenosquamous carcinoma.

A) In the submucosa, dense proliferation of epithelial cells in a tubular pattern. HE. Scale bar, 200 µm.
B) Squamous differentiation. HE. Scale bar, 20 µm.
C) Epithelial cells with moderate pleomorphism, anisocytosis and anisocariosis. HE. Scale bar, 20 µm.
D) Material in the lumina of the tubules positive for alcian blue. Scale bar, 50 µm.
E) Immunochemistry showing the cytoplasm of neoplastic cells with strongly positive immunostaining for cytokeratin. Scale bar, 50 µm.
F) Immunochemistry showing cytoplasmatic weak expression for E-cadherin. Scale bar, 20 µm.

References

1. Akashi Y, Uematsu K, Park YT. Oropharyngeal adenosquamous carcinoma in a dog. J. Animal Clin Med. 2020;29:63-9.
2. Chow KE, Krockenberger M, Collins D. Imaging diagnosis: computed tomographic findings in a case of adenosquamous carcinoma of the head and neck in a cat. Vet Radiol Ultrasound. 2016;57(2): E22-E6.
3. Diniz-Freitas M, García-Caballero T, Antúnez-López J, Gándara-Rey JM, García-García A. Reduced E-cadherin expression is na indicator of unfavourable prognosis in oral squamous cell carcinoma. Oral Oncol. 2006;42:190-200.
4. Kerawala CJ. Acantholytic squamous cell carcinoma of the oral cavity: a more aggressive entity?. Br J Oral Maxillofac Surg. 2009;47(2):123-5.
5. Mathew AL, Joseph BB, Sarojini DM, Premkumar P, Nair SS. Mucoepidermoid carcinoma of palate - a rare entity. Clin Pract. 2017;7(4):145-7.
6. Matsukuma S, Takahashi O, Utsumi Y, Tsuda M, Miyai K, Okada K, Takeo H. Esophageal adenosquamous carcinoma mimicking acantholytic squamous cell carcinoma. Oncol Lett. 2017;14(4): 4918-22.
7. Munday J, Löhr C, Kiupel M. Tumors of alimentary tract. In: Meuten D., editor. Tumor in Domestic Animals. 5th ed. Ames, Iowa: Wiley Blackwell; 2017. p. 503-7. 5th Edit.
8. Munday JS, Tucker RS, Kiupel M, Harvey CJ. Multiple oral carcinomas associated with a novel papillomavirus in a dog. J. Vet. Diagn. Invest. 2015; 27(2):221-5.
9. Nemec A, Murphy B, Kass PH, Verstraete FJM. Histological subtypes of oral non-tonsillar squamous cell carcinoma in dogs. J. Comp. Pathol. 2012;147(2-3):111-20.
10. Okanishi H, Shibuya H, Miyasaka T, Asano K, Sato T, Watari T. Adenosquamous carcinoma of the oesophagus in a dog. J Small Anim Pract. 2015;56(8):521-3.
11. Papadopoulou E, Tosios KI, Nikitakis N, Papadogeorgakis N, Sklavounou-Andrikopolou A. Acantholytic squamous cell carcinoma of the gingiva: report of a case and review of the literature. Oral Surg Oral Med Oral Pathol Oral Radiol Endod. 2010;109(6):e67-e71.
12. Peddapelli K, Rao GV, Sravya T, Ravipati S. Basaloid squamous cell carcinoma: report of two rare cases and review of literature. J. Oral Maxillofac Pathol. 2018;22(2):285.
13. Rosolem MC, Moroz LR, Rodigheri SM. Carcinoma de células escamosas em cães e gatos: Revisão de literatura, Pubvet. 2012;6:1295-1300.
14. Scully C, Bagan J. Oral squamous cell carcinoma overview. Oral Oncol. 2009;45:301-8.
15. Sravya T, Rao GV, Kumar MP, Sudheerkanth K. Oral adenosquamous carcinoma: Report of a rare entity with a special insight on its histochemistry. J. Oral Maxillofac Pathol. 2016;20(3):548.
16. Stewart J, Holloway A, Rasotto R, Bowlt K. Characterization of primary pulmonary adenosquamous carcinoma – associated pleura effusion. Vet Clin Pathol. 2016;45(1):179-83.
17. Thanakappan P, Venkata NSC, Amudala R, Botu M. Adenosquamous carcinoma of oral cavity. J. Cancer Res Ther. 2015;11(4):1034.
18. Verhaert L. Oral proliferative lesions in the dog and cat. EUR J. Companion Anim Pract. 2010;20(3):1-13.
19. Yuki M, Shimada R, Omachi T. Primary adenosquamous cell carcinoma of the ileum in a dog. Veterinary Sciences. 2020;7(4):155.

 All rights reserved 2007-2022.