Braz J Vet Pathol, 2022, 15(3), 153 – 156
DOI: 10.24070/bjvp.1983-0246.v15i3p153-156

BJVP
Brazilian Journal of Veterinary Pathology
ISSN 1983-0246

Case Report

Canine facial eosinophilic furunculosis in a dog

Adriano Lima Stelzer Bindaco[1]*, Lidianne Narducci Monteiro[1], Mariana Marques Sá[1], Marina Possa dos Reys[1], Renan Bernardo Lobo,[1] Laura Monteiro de Castro Conti[1], Mayra Cunha Flecher[1].

[1] Professor Ricardo Alexandre Hippler Veterinary Hospital, Vila Velha University (UVV)
Rua Mercúrio, s/n, Boa Vista I, Vila Velha, Espírito Santo, Brazil
***Corresponding author:** E-mail: adrianostelzer48@gmail.com

Submitted June, 6th 2022, Accepted September, 1st 2022

Abstract

Canine facial eosinophilic furunculosis (FEF) is a hyperacute dermatopathy especially of the nasal bridge of dogs and is probably associated with type I hypersensitivity secondary to arthropod bites. The aim of this study is to report on a FEF case in a four-year-old female free-roaming mixed-breed dog showing papules on the nasal bridge that evolved to an ulcerated plaque. No other clinical, hematological, or biochemical alterations were detected. Cytology revealed eosinophilic and neutrophilic inflammation associated with bacterial infection. Punch biopsies were obtained for histopathological and microbiological analysis. Histopathology revealed marked, acute, multifocal to coalescent granulomatous eosinophilic furunculosis, and mild, acute, multifocal eosinophilic folliculitis. Microbiology revealed growth of coagulase-positive *Staphylococcus* sp. Clinical and histopathological findings were suggestive of facial eosinophilic folliculitis and furunculosis. Complete remission of the lesions was obtained after treatment. This condition is hyperacute, progressive, with a papular and erosive to ulcerative pattern, good prognosis, and its development is linked to arthropod bites. Furthermore, anti-inflammatory therapy is effective in treating the disease.

Key words: inflammation, hair follicle, eosinophils, face.

Introduction

Canine facial eosinophilic furunculosis (FEF) is a rare skin disease of dogs. This disease has an unclear pathogenesis though to be associated to a type I hypersensitivity reaction secondary to arthropod bites (2, 5). Animals with two five years are more commonly affected, especially free-roaming dogs. Breed and sex predilection not reported. Grossly, papules, crusts, and/or erosive to ulcerative lesions can be observed. Lesions usually affect the nasal bridge, but it may also occurs in the periocular region, ears, lips, axillary region and, ventral abdomen (5, 8).

FEF must be distinguished from deep nasal bacterial folliculitis/furunculosis, demodicosis, dermatophytosis, nasal solar dermatitis, drug eruptions, pemphigus, and discoid lupus (7). The diagnosis is based on association of clinical and histopathological findings. Treatment consists in anti-inflammatory therapy. Antibiotics are also indicated in cases presenting secondary bacterial infection (5).

To this date, there's few reports of this condition, so this study reports on a canine facial eosinophilic furunculosis case, in order to provide anatomopathological (gross and microscopic findings) and clinical findings thus contributing to the diagnosis of the disease.

Case Report

A four-years-old female mixed-breed dog was presented for clinical evaluation at the Department of Small Animal Medical Clinic, Professor Ricardo Alexandre Hippler Veterinary Hospital, Vila Velha University (VH-UVV), Vila Velha, Brazil. The patient had pruritic crusts and popular lesions at the dorsum of the nasal bridge (Fig. 1A). According to the owner, the lesion appeared the night before. Anamnesis revealed free-roaming behavior and the habit of digging through grass and soil. The patient did not present any other clinical abnormalities. Hemogram and biochemical exams showed results within the normal range for the species.

Brazilian Journal of Veterinary Pathology. www.bjvp.org.br . All rights reserved 2007-2022.

Braz J Vet Pathol, 2022, 15(3), 153 – 156
DOI: 10.24070/bjvp.1983-0246.v15i3p153-156

Differential diagnoses included hypersensitivity reaction, pemphigus foliaceus, eosinophilic furunculosis, dermatophytosis, and sporotrichosis.

Samples were obtained by fine needle aspiration (FNA) and swabs. Cytology smears were stained by the hematology stain technique and revealed mild eosinophilic and neutrophilic inflammation with abundant bacterial cocci in the background. Treatment was started using Meloxicam (0.1 mg/Kg, orally, SID, for four days) and Cephalexin (22 mg/Kg, orally, BID, for four days) Histopathology, bacterial culture and antibiogram, as well as fungal culture were also performed.

Follow-up examination was performed after three days and revealed a progressive erosive to ulcerated plaque and bilateral periocular ulcerated papules (Fig. 1B & 1C). The owner reported increased pruritus in the area of the lesion. An incisional biopsy was performed for histopathological evaluation using a 6 mm punch, and samples for microbiology were collected using sterile swabs containing Stuart transport medium (23010P Model, Absorb ®).

Samples were formalin-fixed, routinely processed, and paraffin-embedded. Paraffin sections were obtained, stained using hematoxylin and eosin and Periodic Acid Schiff for subsequent analysis under light microscopy.

Histopathology revealed epidermal ulceration crusting associated with fibrin and cellular debris, impetiginization, acantholysis, spongiosis, exocytosis (eosinophils and neutrophils) and vacuolar degeneration of the stratum spinosum (Fig. 2). Superficial and deep dermis revealed ruptured hair follicles associated with marked eosinophilic infiltration, epithelioid macrophages, and few intact and degenerated neutrophils. Hair fragments were also surrounded by epithelioid macrophages. The external root sheaths of the follicular isthmus showed an eosinophilic infiltrate, often associated with intrafollicular degranulated and necrotic eosinophils. No hyphae, fungal yeast, and parasitic structures were observed. Morphological diagnosis was consistent with multifocal to coalescent, marked necrotizing eosinophilic granulomatous furunculosis and folliculitis. A diagnosis of canine facial eosinophilic furunculosis was made based on the association of clinical and histopathological findings.

Microbiologic analyses revealed negative results for fungal isolation on Sabouraud-Dextrose (Sabouraud Dextrose Agar, Neogen®) and Mycosel Agar (Mycosel Agar, BD®) media, as well as on bacterial culture using MacConkey Agar (MacConkey Agar, Kasvi®). However, bacterial growth occurred in 5% Sheep Blood Agar bacterial medium (Blood Agar Base, Kasvi®) within 24 hours. Coagulase-positive *Staphylococcus* sp. were identified after analysis based on Gram staining method and catalase and coagulase tests.



Figure 1. Gross lesions of canine facial eosinophilic folliculitis and furunculosis. **A.** Swelling and papules on the nasal bridge (10/08/21). **B & C.** An ulcerated and crusted plaque on the nasal bridge (asterisk) and ulcerated papules on the periocular region (arrow) (13/08/21). **D.** Crusts (asterisk) and granulation tissue (arrow) (17/08/21). **E & F.** Crusts (asterisk) and lesion remission (arrow) after treatment with anti-inflammatory drugs (08/25/21).

Brazilian Journal of Veterinary Pathology. www.bjvp.org.br . All rights reserved 2007-2022.

Braz J Vet Pathol, 2022, 15(3), 153 – 156
DOI: 10.24070/bjvp.1983-0246.v15i3p153-156

The owner reported improvement of the skin lesions after four days (Fig.1D). Lesions showed signs of remission fifteen days after the first examination (Fig. 1E & 1F). Prednisolone (20 mg/Kg, orally, SID, for seven days) treatment was initiated and the owner reported total remission of the skin lesions after three days.

Discussion

Cases reporting canine facial eosinophilic furunculosis are not common in the veterinary literature. The rapid onset and self-limiting course are responsible for making the diagnosis difficult and may justify the rare reports (8). This disease was reported by Curtis et al. (1995), Guaguère et al. (1996) and Pereira et al. (2012), and as in the present report, these authors also observed the acute onset and the aggressive course of the disease.

Papules, pustules, nodules, and/or plaques with ulcers and serosanguineous discharge and hemorrhagic crusting can be observed. Usually, dogs show facial lesions (nasal bridge, periocular region, ears, and lips) but can also occurs on the axillary region, abdomen, and limbs (2, 3, 5, 8). Severe pruritus can be detected (3), but there are also cases in which it is absent (8). In the case herein reported, marked pruritus was observed and may have contributed to ulceration and plaque formation on the nasal bridge. In this case, the use of an Elizabethan collar can be necessary to isolate the lesion and avoid additional trauma.

A relation between canine facial eosinophilic furunculosis and type I hypersensitivity reaction due to exposure to arthropod venom from bees, spiders, and ants was suggested. No breed or sex predilection is known; however, large breeds are among the most affected probably because they more commonly have access to outdoor environments (8). In the case herein reported the dog may have had contact with arthropods due to a free-roaming behavior and its habits of digging and sniffing.

Major differential diagnoses for canine facial eosinophilic furunculosis include deep nasal bacterial folliculitis/furunculosis, demodicosis, dermatophytosis, nasal solar dermatitis, drug eruptions, pemphigus (foliaceous and erythematosus), and discoid lupus (5, 7). The diagnosis is based on clinical history, anatomic location, clinical course, and histopathological features (5).

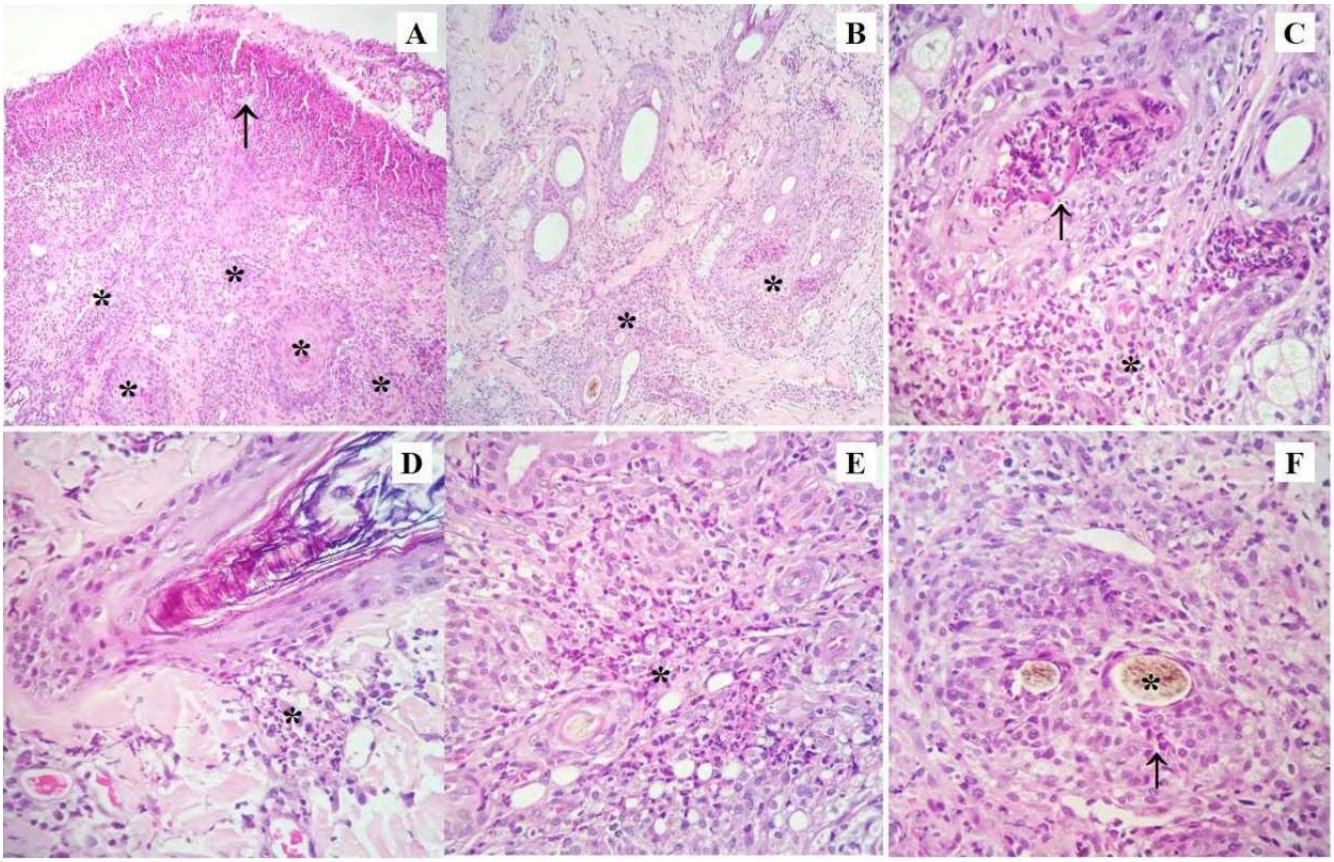

Figure 2. Photomicroscopy of canine facial eosinophilic folliculitis and furunculosis. A. Fragment of hairy skin showing ulcerated epidermis and crusting associated with fibrin and cellular debris (arrow), and furunculosis in the dermis (asterisk), HE – 40X objective. B. Eosinophilic infiltrate in hair follicles (asterisk), HE - 100X objective. C. Hair follicles showing marked eosinophilic mural infiltrate and necrotizing mural folliculitis (arrow), and external root sheath rupture (asterisk), HE – 400X objective. D. Hair follicle with focal invasion of eosinophils in the isthmus region (asterisk), HE – 400X objective. E. Intact hair follicles revealing perifollicular eosinophilic infiltrate (asterisk), HE – 400X objective. F. Fragments of hair (asterisk) surrounded by epithelioid macrophages (granulomas) (arrow), HE – 400X objective. Nikon Eclipse E200 Optical Light Microscope.

Brazilian Journal of Veterinary Pathology. www.bjvp.org.br . All rights reserved 2007-2022.

Skin cytology revealed eosinophilic inflammation, which is commonly associated with hypersensitivity or parasitic disease and may not be conclusive (1). Hence, histopathological analysis by incisional biopsy is essential for reaching a more appropriate diagnosis.

Characteristic histopathological findings of the disease include eosinophilic infiltration, destruction, and rupture of hair follicles (2, 5). This pattern is characterized by necrotizing mural folliculitis associated with eosinophilic degranulation within the follicular wall, resulting in accumulation of intrafollicular necrotic cells (5). Pyogranulomatous/granulomatous reaction occurs due to keratin released by follicular rupture that acts as a foreign body (6). Granuloma formation is commonly observed in furunculosis, with hair fragments surrounded by epithelioid macrophages and/or multinucleated giant cells (6).

Microbiological examination confirmed secondary bacterial infection that was previously observed in cytology and histology. *Staphylococcus* sp. is commonly found in several erosive to ulcerative skin lesions (5). Bacterial colonies grow primarily on crusts and/or ulcerated dermis, benefiting from the breakdown of the epidermal barrier. In this case, the term impetiginization can be used to designate the secondary bacterial infection (9). Thus, it is important to perform bacterial cultures and antibiogram, as well as initiate treatment using antibiotics.

Additionally, anti-inflammatory drugs can be effective in the treatment of canine facial furunculosis. Corticosteroids are commonly used due to their immunosuppression effect (2, 3); however, in the present case, a non-steroidal anti-inflammatory drug (Meloxicam) was used due to possible infection among differential diagnoses. Remission was observed even with the use of Meloxicam instead of a corticosteroid. Prednisolone was initiated only after the diagnosis – when the patient was already responsive. Thus, it is believed that the condition had a self-limiting character. Complete remission was observed after prednisolone treatment with decrease of pruritus.

Canine facial eosinophilic furunculosis and folliculitis is an hyperacute and progressive skin disease that shows papular, crusted, erosive, and ulcerative lesions with good prognosis. It affects dogs bitten by arthropod. In the present case, diagnosis was made based on the association of clinical signs and the histopathology, and anti-inflammatory therapy resulted in total remission of lesions.

References

1. Albanese F. Canine and Feline Skin Cytology: A Comprehensive and Illustrated Guide to the Interpretation of Skin Lesions via Cytological Examination. Switzerland: Springer, 2017;34-9.
2. Bloom PB. Canine and feline eosinophilic skin diseases. Vet. Clin. North. Am. Small Anim. Pract., 2006;36:141-6.
3. Curtis CF, Bond R, Blunden AS. Canine Eosinophilic Folliculitis and Furunculosis in three cases. J. Small Anim. Pract., 1995;36:119-23.
4. Guaguère E, Prelaud P, Peyronnet L. et al. Furonculose éosinophilique chez le chien: étude rétrospective de 12 cas. Prat. Méd. Chirurg. l'Anim. Compag. 1996;31:413-19.
5. Gross TL, Ihrke PJ, Walder EJ, Affolter VK. (ed). Skin diseases of the dog and cat: Clinical and histopathological diagnosis. 2.ed. Oxford: Blackwell Science Ltd. 2005;450-453.
6. Mauldin EA, Peters-kennedy J. Integumentary System. In: MAXIE, G. M. (ed) Jubb, Kennedy, and Palmer's pathology of domestic animals. St. Louis: Elsevier, Inc.; 2016. p.518-60.
7. Miller WH, Griffin CE, Campbell KL. Muller and Kirk's Small Animal Dermatology. St. Louis: Elsevier Inc.; 2013. p. 418-419.
8. Pereira AVP, Gremião IDF, Silva DA, Sá AC, Pereira AS. Furunculose eosinofílica canina. Acta Sci. Vet., 2012;40:1-4.
9. Petry V, Bessa GR, Poziomczyck CS. Bacterial skin colonization and infections in patients with atopic dermatites. An. Bras. Dermatol. 2012;87(5):729-34.