



Case Report

## Avian mycobacteriosis in a naturally infected captive nocturnal curassow (*Nothocrax urumutum*)

Laice Alves da Silva<sup>1</sup>, Thaynara Parente de Carvalho<sup>1</sup>, Ayisa Rodrigues Oliveira<sup>1</sup>, Daniel Oliveira dos Santos<sup>1</sup>, Clarissa Helena Santana<sup>1</sup>, Lauro Leite Soares Neto<sup>2</sup>, Fernanda Mara Aragão Macedo Pereira<sup>2</sup>, Ana Beatriz Portes Gonçalves<sup>1</sup>, Vitória Gavião Carvalho Correia<sup>2</sup>, Renato Lima Santos<sup>1\*</sup>

<sup>1</sup> Escola de Veterinária, Universidade Federal de Minas Gerais, Belo Horizonte, MG, Brazil.

<sup>2</sup> Parque Zoológico Municipal de Bauru. Rodovia Com. João Barros, km 232 s/n - Vargem Limpa, Bauru - SP, 17049-900, Brazil.

\*Corresponding author: E-mail: rsantos@vet.ufmg.br

Submitted June, 27<sup>th</sup> 2022, Accepted July, 15<sup>th</sup> 2022

### Abstract

A senile female nocturnal curassow (*Nothocrax urumutum*) kept under human care was found dead. Grossly, the lungs were congested and had a nodule with 2.0 cm in diameter adhered to the left lung. Histologically, there were multifocal to coalescent areas of necrosis characterized by deposition of amorphous and eosinophilic material with large amount of cellular debris, surrounded by numerous epithelioid macrophages, multinucleated Langhans giant cells, occasional lymphocytes and plasma cells. Ziehl-Neelsen stained sections demonstrated myriad of intralésional alcohol-acid resistant bacilli (BAAR). DNA extracted from lung samples were evaluated by nested polymerase chain reaction resulting in mycobacterial DNA identification. This is the first reported case of mycobacteriosis in a nocturnal curassow.

**Key words:** *Mycobacterium*, pneumonia, zoological, birds.

### Introduction

Avian mycobacteriosis or avian tuberculosis is an important disease affecting domestic and wild birds worldwide. Several species of *Mycobacterium* spp. cause the disease in birds, especially *Mycobacterium avium*, *M. intracellulare*, and *M. genavense*, which belong to the *M. avium* complex (MAC) (26). Disease caused by *M. tuberculosis* and *M. bovis* has also been reported, although these organisms are uncommon causes of infections in birds (19, 23).

The etiological agent of avian mycobacteriosis is an aerobic, nonspore-forming, and nonmotile rod shaped bacterium, which is weakly Gram-positive and intensely stained by acid fast method (Ziehl-Neelsen) due to high levels of mycolic acids in the cell wall, which contributes to make the genus more tolerant to antimicrobials and resistant to host defenses (16). MAC includes ubiquitous environmental saprophytes usually found in surface water,

soils rich in organic matter or heavily contaminated with animal feces (26). MAC can occasionally be isolated from human patients so they are also considered opportunistic pathogens, infecting particularly immunosuppressed patients (4, 30). Contaminated water is considered as the primary source of infection for humans (29).

The avian orders that appear to be most susceptible to MAC in zoological collections are Anseriformes, Gruiformes, and Galliformes (11, 26). However, according to Tell et al. (26) the reason for these differences may reflect the prevalence or overrepresentation of these birds in zoo collections rather than actual susceptibility.

Cracidae is a family within the order Galliformes whose Brazilian species have four distinct biotypes: chachalaca, guan, piping-guan, and curassow; which are classified in six genera: *Aburria*, *Crax*, *Nothocrax*, *Ortalis*, *Pauxi*, and *Penelope*. Cracidae is the family of birds with the highest number of endangered species, with approximately half of guans and curassows considered

vulnerable or threatened with extinction (21, 24). The only species representative of the genus *Nothocrax* is *Nothocrax urumutum*, a non-migratory and poorly studied bird that inhabits the Amazon Forest, including territories of Brazil, Colombia, Ecuador, Peru, Venezuela, and Bolivia. It has a current trend for decrease in its population, due to its susceptibility to hunting, resulting in an estimated decline of 25% over three generations (3, 25).

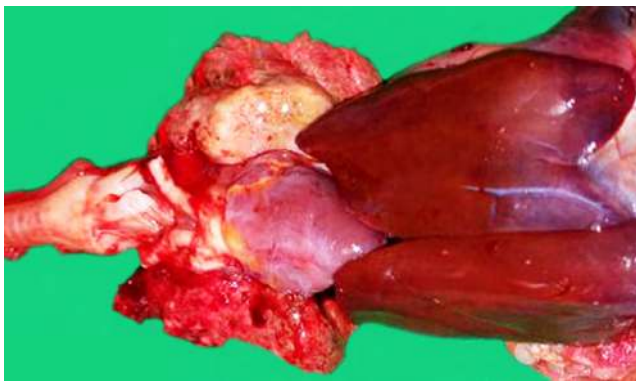
Several bacterial diseases can affect wild Galliformes, such as chlamydophylosis (9), avian tuberculosis (18), streptococcosis (20), and infectious coryza (1), especially when they are kept in captivity sharing premises with domestic avian species. Knowledge about the health profile of these birds raised under human care is very important to establish prophylactic measures, effective treatments, as well as for the development of sanitary protocols for reintroduction of birds (24).

In this report we describe a case of avian mycobacteriosis associated with a necrotizing and granulomatous mycobacterial pneumonia in a nocturnal curassow (*N. urumutum*) kept under human care. Despite *Mycobacterium* spp. being an important pathogen for various species of wild birds, including Ardeids and Threskiornithids (8), Phoenicopterids (12), Phasianids (2,10,13), and Psittacids (28), to the best of our knowledge this is the first report of avian tuberculosis in a *N. urumutum*.

### Case description

A senile female nocturnal curassow (*N. urumutum*) kept under human care at the Bauru Zoological Garden was found dead, and immediately submitted to necropsy.

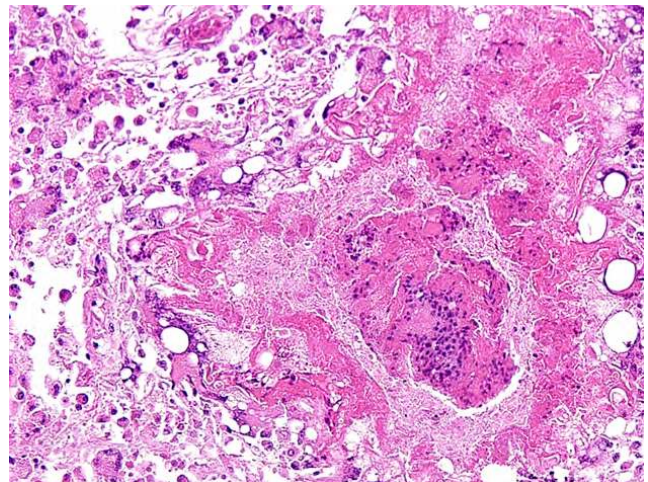
The bird was in good body condition. Lungs were congested and with a white-yellowish firm and gritty nodule with 2.0 cm in diameter in the left lung (Fig. 1). Tibiotarsal-tarsometatarsal and interphalangeal joints on plantar surface were swollen and the synovial fluid was thick and chalky white. No gross changes were observed



**Figure 1.** Pulmonary mycobacteriosis in a nocturnal curassow (*Nothocrax urumutum*). White-yellowish, firm nodular lesion in the left lung with 2.0 cm in diameter.

in other organs. Samples of the lung, heart, liver, spleen, kidney, brain, and intestines were fixed in 10% buffered formalin submitted for routine histological processing, stained with hematoxylin and eosin (HE), and evaluated under light microscopy. Sections of the lung were also stained with Ziehl-Neelsen and Schiff's Periodic Acid (PAS), and sections of the liver were stained with Masson's trichrome and Perl's Prussian Blue.

Microscopically, the lung had multifocal to coalescent areas of necrosis characterized by deposition of amorphous and eosinophilic material with large amounts of cellular debris, surrounded by numerous epithelioid macrophages, multinucleated Langhans giant cells, and fewer lymphocytes and plasma cells (Fig. 2). There was also intense multifocal deposition of gray pigment in alveoli (interpreted as anthracosis). Many acid-alcohol-resistant bacilli (BAAR) were observed in the cytoplasm of macrophages, giant cells and scattered in the interstitium of Ziehl-Neelsen stained sections (Fig. 2). No other intralésional microorganisms were evidenced in PAS-stained sections. In the liver, there was moderate accumulation of granular golden-brown cytoplasmic pigment in hepatocytes and macrophages, which was confirmed to be hemosiderin as evidenced by Perl's Prussian blue staining (Fig. 3). There was also a focal area of hepatocyte loss and replacement by fibrous connective tissue in subcapsular region, moderate bile duct hyperplasia, and moderate multifocal portal fibrosis, with accumulation of large amounts of collagen fibers as evidenced by Masson's trichrome (Fig. 4). Samples of the articular (gout) lesions were not sampled for histopathology.



**Figure 2.** Pulmonary mycobacteriosis in a nocturnal curassow (*Nothocrax urumutum*). Areas of multifocal to coalescent necrosis characterized by deposition of amorphous and eosinophilic material with large amount of cellular debris, surrounded by inflammatory cells and fibrous connective tissue. Hematoxylin and eosin (HE). Inset: Myriad of alcohol-acid resistant bacilli (BAAR) in the cytoplasm of macrophages, giant cells and scattered in the interstitial space. Ziehl Neelsen.

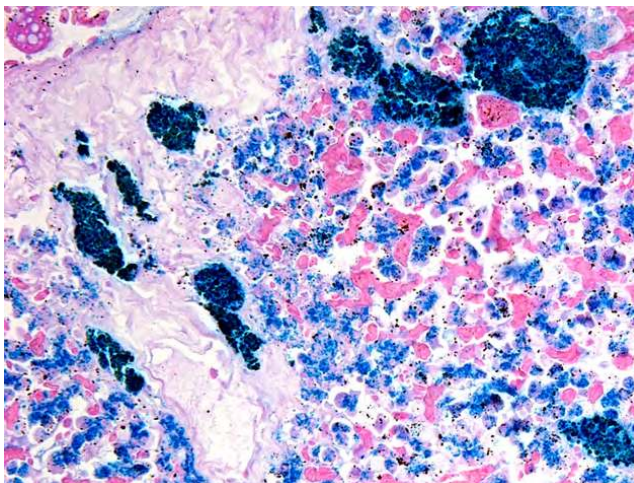
DNA was extracted from the lung lesion for performing a nested polymerase chain reaction to amplify *Mycobacterium* spp. 16S ribosomal RNA gene as previously described (27). Ten- $\mu\text{m}$ -thick sections were obtained from formalin-fixed, paraffin-embedded lung samples and placed into 1.5-mL sterile microtubes. DNA was extracted from samples using a DNA tissue extraction kit (ReliaPrep™ FFPE gDNA Miniprep System, Promega, Madison, USA) following the manufacturer's instructions. Nested PCR amplification was performed using primers targeting *Mycobacterium* spp. 16S ribosomal RNA gene region: forward 246 (5'-AGAGTTTGATCCTGGCTCAG-3') and reverse 247 (5'-TTTCACGAACAAGCCCAGAA-3'). The first step was performed in duplicate in a total volume of 25  $\mu\text{L}$  each, containing 1  $\mu\text{L}$  of each primer (25  $\mu\text{M}$ ), 2  $\mu\text{L}$  of DNA, 21  $\mu\text{L}$  of PCR supermix (Invitrogen). A control reaction without template DNA was used to demonstrate the absence of contamination. Cycling conditions were: a denaturation step at 95°C for 2 min; 30 cycles with denaturation (95°C, 30 sec), annealing (60°C, 60 sec), and extension (72°C, 60 sec); and a final extension step at 72°C for 7 min. Subsequently, the following primers were used: forward M1 (5'-AGTGGCGAACGGGTGAGTAAC-3') and reverse R7 (5'-TTACGCCCAGTAATTCCGGACAA-3'). Ten  $\mu\text{L}$  from the first PCR reaction was added to 35.2  $\mu\text{L}$  of PCR supermix and 1.2  $\mu\text{L}$  of each forward M1 and reverse R7 primers (25  $\mu\text{M}$ ). Cycling parameters were the same as in the first reaction. PCR products were analyzed by electrophoresis, resulting in amplification of a genus-specific 450 bp product. Amplicon was purified using QIAEXII kit (Quiagen®), according to manufactures instructions, and them subjected to capillary sequencing, which yielded data that was insufficient to identify the organism at the species level.

## Discussion

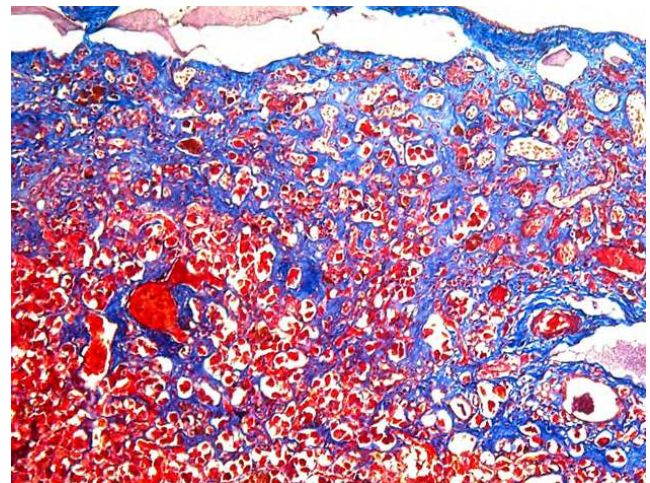
This is the first reported case of mycobacteriosis in a nocturnal curassow (*N. urumutum*). *Mycobacterium* spp. are important pathogens for wild and captive species. Infected birds shed *Mycobacterium* spp. through feces, hence contaminating the environment and being the most important source of infection for wild or domestic birds. *Mycobacterium* spp. may also infect several mammalian species including pigs, cattle, deer, sheep, goat, horses, cats, dogs, and exotic species as well as causing opportunistic infections in immunocompromised humans (6).

Necropsy in this case revealed a nodular lesion in the left lung, which was microscopically characterized by a necrotizing and granulomatous pneumonia with intralesional acid-alcohol-resistant bacilli. Importantly, morphologic diagnosis was followed by amplification of mycobacterial genomic DNA from the lesion. Unlike tuberculosis in ruminants and man, lesions in lungs are uncommon in avian species. Gross lesions usually include enlargement of organs and pale-yellow nodules in liver, spleen, intestine, and bone marrow. Pulmonary avian mycobacteriosis was an unexpected finding and suggested an airborne source of infection, in dust or as aerosols, which possibly occurred in this case (6, 8).

A previous study in Psittacines (15) indicated that there are three patterns of histological lesions, irrespective of affected organ, age, or species of bird. The most frequent pattern was an infiltration of large number of epithelioid macrophages, with occasional multinucleated giant cells, but lacking tissue necrosis. The second pattern was similar except for the infiltration of lymphocytes, plasma cells and heterophils. The third pattern, which was seen in few cases, was characterized by heterophilic granulomas with a central area of necrosis surrounded by multinucleated giant cells, macrophages, lymphocytes and fibrosis, which is similar to the case described in this report.



**Figure 3.** Hepatic hemosiderosis in a nocturnal curassow (*Nothocrax urumutum*). Multifocal deposits of moderate amount of granular pigment in the cytoplasm of hepatocytes and macrophages (interpreted as hemosiderin). Perl's Prussian blue.



**Figure 4.** Subcapsular fibrosis in a nocturnal curassow (*Nothocrax urumutum*). Focal area of loss and replacement of hepatocytes by fibrous connective tissue in subcapsular region. Masson's trichrome.

Predisposing factors to mycobacterial infection include stress, advanced age, overcrowded environments, unhygienic conditions, malnutrition, and concurrent diseases (22). The curassow in this case was an old bird and had others lesions possibly associated with aging, such as the areas of hepatic fibrosis. Age is considered a predisposing factor for avian tuberculosis since the disease is more frequently observed in adult or senile birds. However, this may be just a consequence of the chronic nature of the infection; thereby mycobacteriosis must also be considered as a differential diagnosis in juvenile birds (6, 26). The bird in this report had marked hepatic hemosiderosis, a process characterized by intracellular accumulation of iron without other evident lesions. Diet is usually associated with iron overload in birds and hepatic iron storage is commonly described in birds under human care due to their unnatural diets. This may occur due to excessive iron intake or high levels of ascorbic acid which increases intestinal iron absorption. Low levels of tannin, an iron chelator, has also been implicated in the etiology (5,7). However, a recent study demonstrated that iron accumulation is also commonly observed in several free-ranging avian species similarly to what is diagnosed in birds under human care (14).

Zoo animals are artificially managed in limited spaces. Thus, they are subjected to high animal density, which may favor exposure to high concentrations of infectious agents. In the case of MAC, the ability of the microorganisms to persist in the environment for many years, especially in soil contributes to the disease transmission. However, the prevalence of avian mycobacteriosis in zoo collections is usually low, but each individual case may have devastating consequences for sanitary status of the population so quarantine and surveillance for other infected birds are usually considered good practices in these cases (17, 24).

### Acknowledgements

Work in RLS labs is supported by CNPq (Conselho Nacional de Desenvolvimento Científico e Tecnológico, Brazil), FAPEMIG (Fundação de Amparo à Pesquisa do Estado de Minas Gerais, Brazil), and CAPES (Coordenação de Aperfeiçoamento de Pessoal de Nível Superior, Brazil).

### References

1. Adenkola AY, Jegede HO, Adeyemi AB, Raji LO, Kolapo TU, Oyedipe EO. Infectious coryza in a flock of peafowls (*Pavo cristatus*) in the University of Ilorin Zoological Garden. *Comp Clin Pathol*. 2016;25(1):247-50.
2. Álvarez PP, Moroni M, Verdugo C. Avian tuberculosis in a Lady Amherst's pheasant *Chrysolophus amherstiae*. *Austral J Vet Sci*. 2017;49(3):213-5.
3. BirdLife International: *Nothocrax urumutum*. The IUCN Red List of Threatened Species 2016; e.T22678461A92775039. <https://dx.doi.org/10.2305/IUCN.UK.2016-3.RLTS.T22678461A92775039.en>. Downloaded on 11 June 2021.
4. Chowdhary M, Narsinghani U, Kumar RA. Intracranial abscess due to *Mycobacterium avium* complex in an immunocompetent host: a case report. *BMC Infect Dis*. 2015;15(1): 281.
5. Cork SC. Iron storage diseases in birds. *Avian Pathol*. 2000;29(1):7-12.
6. Dhama K, Mahendran M, Tiwari R, Dayal-Singh S, Kumar D, Singh S, Sawant PM. Tuberculosis in birds: insights into the *Mycobacterium avium* infections. *Vet Med Int*. 2011;2011:712369.
7. Dierenfeld ES, Pini, MT, Sheppard, CD. Hemosiderosis and dietary iron in birds. *J Nutr*. 1994;124(12 Suppl):2685S-2686S.
8. Dvorska L, Matlova L, Ayele WY, Fischer OA, Amemori T, Weston RT, Alvarez J, Beran V, Moravkova M, Pavlik, I. Avian tuberculosis in naturally infected captive water birds of the Ardeidae and Threskiornithidae families studied by serotyping, IS901 RFLP typing, and virulence for poultry. *Vet Microbiol*. 2007;119(2-4):366-74.
9. Frutos MC, Monetti MS, Vaulet LG, Cadario ME, Fermepin MR, Ré VE, Cuffini CG. Genetic diversity of *Chlamydia* among captive birds from central Argentina. *Avian Pathol*. 2015;44(1):50-6.
10. Gerhold RW, Fischer JR. Avian tuberculosis in a wild turkey. *Avian Dis*. 2005;49(1):164-6.
11. Keymer IF, Jones DM, Pugsley SL, Wadsworth PF. A survey of tuberculosis in birds in the Regent's Park Gardens of the Zoological Society of London. *Avian Pathol*. 1982;11(4):563-8.
12. Kock ND, Kock RA, Wambua J, Kamau GJ, Mohan K. *Mycobacterium avium*-related epizootic in free-ranging lesser flamingos in Kenya. *J Wildl Dis*. 1999;35(2):297-300.
13. Ledwon A, Augustynowicz-Kopeć E, Parniewski P, Bonecka J, Ostrzeszewicz M, Dolka B, Szeleszczuk P. Mycobacteriosis in peafowl: analysis of four cases. *Med Weter*. 2018;74(12):772-6.
14. Oliveira AR, Santos DO, Pereira MPM, Carvalho TF, Tinoco HP, Pessanha AT, Costa MELT, Coelho CM, Paixão TA, Carvalho MPN, Santos RL. A retrospective study of hepatic hemosiderosis and iron storage disease in several captive and free-ranging avian species. *J Zoo Wildl Med*. 2022;53(2): 455-60.
15. Palmieri C, Roy P, Dhillon AS, Shivaprasad HL. Avian mycobacteriosis in psittacines: a retrospective study of 123 cases. *J Comp Pathol*. 2013;148(2-3):126-38.
16. Parker H, Lorenc R, Ruelas-Castillo J, Karakousis PC. Mechanisms of antibiotic tolerance in *Mycobacterium avium* complex: lessons from related *Mycobacteria*. *Front Microbiol*. 2020;11:2348-66.
17. Roller M., Hansen S, Böhlken-Fascher S, Knauf-Witzens T, Czerny CP, Goethe R, Abd El Wahed A. Molecular and serological footprints of *Mycobacterium avium* subspecies infections in Zoo animals. *Vet Sci*. 2020;7(3):117.

18. Saha GR, Sur SK, Mitra M, Bhowmik MK. Tuberculosis in captive birds at Alipore Zoo. Indian J Vet Pathol. 1995;19(2):142-3.
19. Sánchez FD, Yela IJ, Alfonseca E, Campuzano J, Morales E, Aguilar, C. Respiratory tract infection caused by *Mycobacterium bovis* in a black swan (*Cygnus atratus*). Avian Pathol. 2016;45(1):126-31.
20. Santos HF, Flôres ML, Lara VM, Silva MS, Battisti L, Lovato LT. Microbiota cloacal aeróbia de cracídeos cativos no Rio Grande do Sul e sua susceptibilidade a antimicrobianos. Pesq Vet Bras. 2010;30(12):1077-82.
21. Sao Bernardo CS. Reintroduction as a conservation tool for threatened Galliformes: the Red-billed curassow *Crax blumenbachii* case study from Rio de Janeiro state, Braz J Ornithol. 2012;153(1):135-40.
22. Sattar A, Zakaria Z, Abu J, Aziz SA, Rojas-Ponce G. Isolation of *Mycobacterium avium* and other nontuberculous *Mycobacteria* in chickens and captive birds in peninsular Malaysia. BMC Vet Res. 2021;17(1):13.
23. Schmidt V, Schneider S, Schlömer J, Krautwald-Junghanns ME, Richter E. Transmission of tuberculosis between men and pet birds: a case report. Avian Pathol. 2008;37(6):589-92.
24. Silva-Filho RP, Ruoppolo V, Cubas ZS, Silva JCR, Catão-Dias JL. Família Cracidae. In: Tratado de Animais Selvagens. Medicina Veterinária . São Paulo: Roca;2014. p.773-84.
25. Silveira LF. A família de aves mais ameaçada do Brasil. Cães e Cia. 2013;413:64-5.
26. Tell LA, Woods L, Cromie RL. Mycobacteriosis in birds. Rev Sci Tech. 2001;20:180-203.
27. Ullmann LS, Dias RDN, Cagnini DQ, Yamatogi RS, Oliveira JP, Nemer V, Teixeira RHF, Biondo AW, Araújo JP. *Mycobacterium genavense* infection in two species of captive snakes. J Venom Anim Toxins Incl Trop Dis.. 2016;22:2-4.
28. Washko RM, Hoefler H, Kiehn TE, Armstrong D, Dorsinville G, Frieden TR. *Mycobacterium tuberculosis* infection in a green-winged macaw (*Ara chloroptera*): report with public health implications. J Clin Microbiol. 1998;36(4):1101-2.
29. Whiley H, Keegan A, Giglio S, Bentham R. *Mycobacterium avium* complex– the role of potable water in disease transmission. J Appl Microbiol.. 2012; 113(2):223-32.
30. Wood BR, Buitrago MO, Patel S, Hachey DH, Haneuse S, Harrington RD. *Mycobacterium avium* complex osteomyelitis in persons with human immunodeficiency virus: case series and literature review. Open Forum Infect Dis. . 2015;2(3): ofv090.