



Case Report

First description of bacillary hemoglobinuria in a cattle in Minas Gerais, Brazil

Fabrcio Gomes Melo¹, Carlos Augusto Oliveira Junior¹, Rafael Gariglio Clark Xavier¹,
Diogo Soares Gonçaves Cruz¹, Gustavo Henrique Siqueira Ribeiro²,
Francisco Carlos Faria Lobato¹, Rodrigo Otávio Silveira Silva^{1*}.

¹Escola de Veterinária, Universidade Federal de Minas Gerais (UFMG),
Antônio Carlos Avenue, 6627. Belo Horizonte, MG – Brazil, 31.270-901.

*Corresponding author: E-mail: rodrigo.otaviosilva@gmail.com

Submitted August, 24th 2021, Accepted July, 14th 2022

Abstract

Bacillary hemoglobinuria (BH) is a histotoxic infection caused by *Clostridium haemolyticum* that affects mostly cattle parasitized with trematodes. The aim of present study was to describe an atypical case of BH in a cow without access to flooded areas and without parasitism by *Fasciola hepatica*. After eight days of sternal decubitus and apathy, a Nellore cow was euthanized and necropsied. During postmortem examination, mild jaundice, black urine and multifocal lesions in the liver were observed. Histopathology revealed multifocal coagulation foci of necrosis in liver and basophilic bacillary structures, which were confirmed as *C. haemolyticum* by bacterial isolation, PCR and sequencing techniques. This is the first description of BH in cattle in Minas Gerais state, Brazil and highlight the need for of inclusion of BH as differential diagnosis even in animals not parasitized by trematodes.

Key words: *Clostridium haemolyticum*, red water disease, *Fasciola hepatica*, *Clostridium novyi* type D.

Introduction

Bacillary hemoglobinuria (BH) is a highly lethal liver infection caused by *Clostridium haemolyticum* (previously *Clostridium novyi* type D) that affects mostly cattle (10). The disease is mostly described in animals infested by liver flukes, commonly *Fasciola hepatica*, which initiates the liver damage and creates the anaerobic condition that allows growth and toxin production by *C. haemolyticum* (6,10). Initially, affected animals shows high fever, hemoglobinuria and jaundice which rapidly evolve to dyspnea and tachycardia associated with toxemia (10,14). Eventually, affected animals can be found dead without any previous clinical signs (5,10).

The disease was already reported in many countries of Asia, Europe, Oceania, North America and South America (1,2,4,6,10,11,19). In Brazil, the reports of BH are restricted to South region and all associated with *F. hepatica* parasitism in grazing cattle (5,12,14). In the present report, we describe a case of BH in a cow without access to flooded areas and without parasitism by *F. hepatica* in Minas Gerais state, Brazil.

Case report

In September of 2019, a veterinary was called in Divinópolis city, Minas Gerais state, in a beef cattle farm. A Nellore cow, approximately 4 years old, was found in recumbency in the pasture. During clinical examination, apathy and weakness of hind quarters was observed. Five days after the beginning of the clinical signs, the cow received Flunixin Meglumine (Hertape, Brazil) (1 mg/kg, SID, IM). During all this period, the animal received water and was feeding. Direct microscopy on a Giemsa-stained peripheral blood smear, collected in the animal tail, was used to evaluate the presence of haemoparasites, including *Babesia* sp. and *Anaplasma* sp. (7). The Woo method (20) was also used to evaluate the presence of *Trypanosoma* sp. was also used. Both tests were negative. As no improvement was observed and due an unfavorable prognosis, the animal was euthanized and immediately necropsied eight days after the onset of symptoms.

At necropsy, the ocular mucosa and the carcass showed mild jaundice. Multifocal lesions varying from 5 to 10 centimeters, in green or black color, surrounded or not by a yellow rim were seen in the liver surface (Fig. 1). In liver parenchyma, these areas were irregular, well-defined, yellow, sometimes accompanied by red or black spots (Fig. 2). The kidneys and urine were diffusely black (Fig. 3). Samples from all organs were collected and fixed in 10% buffered formalin (pH 7.2). For histopathology, 4- μ m-thick sections were prepared from specimens, stained with hematoxylin and eosin (HE) and examined in optical microscopic. In addition, fragments of the liver were refrigerated and submitted to the Anaerobic Laboratory at Veterinary School of Universidade Federal de Minas Gerais (UFMG), for bacterial isolation and identification.

In the histopathologic evaluation, an accentuated multifocal necrotizing hepatitis was observed. Multifocal coagulation foci of necrosis were observed, surrounded by a well-defined layer of inflammatory infiltrate composed mainly of healthy neutrophils, degenerated neutrophils and cellular debris (Fig. 4). Some areas of mild hemorrhage near the periphery of the necrotic areas were also showed. Basophilic bacillary structures from 7 to 10 nm, compatible with *Clostridium* spp. were found in the necrotic areas and close to the inflammatory infiltrate (Fig. 5). In viable liver

tissue were identified thrombi in regions close to areas of necrosis and inflammation. Mild to moderate hepatocyte vacuolization was observed in liver tissue out of necrotic areas, while a mild multifocal tubular necrosis was seen in the kidneys.

For isolation, liver fragments were inoculated into Brain Heart Infusion broth (Oxoid, USA) and kept at 37°C in an anaerobic chamber (Thermo Fisher Scientific, USA) (80% N₂, 10% CO₂, 10% H₂) for seven days. Then, the broth was centrifuged and the resulting pellet was submitted to thermal DNA extraction and to a previously described PCR for *C. haemolyticum* and *C. novyi* type B (15). A band of 694 bp, compatible with a positive result for *C. haemolyticum*, was observed (15). To confirm this result, the amplicon was purified using Agencourt AMPure XP (Beckman Coulter, USA) according to the manufacturer's instructions and was sequenced in both directions using previously described primers (15) and the Big Dye V3.1 Terminator Kit using an ABI 3500 DNA analyzer (Applied Biosystems, USA). The sequences were submitted to the BLASTN computational tool (<https://blast.ncbi.nlm.nih.gov>). The sequences obtained revealed a nucleotide sequence identity of 100% with *C. haemolyticum* gene for flagellin protein FliA(H), confirming the specificity of the PCR product and the presence of *C. haemolyticum* in liver.

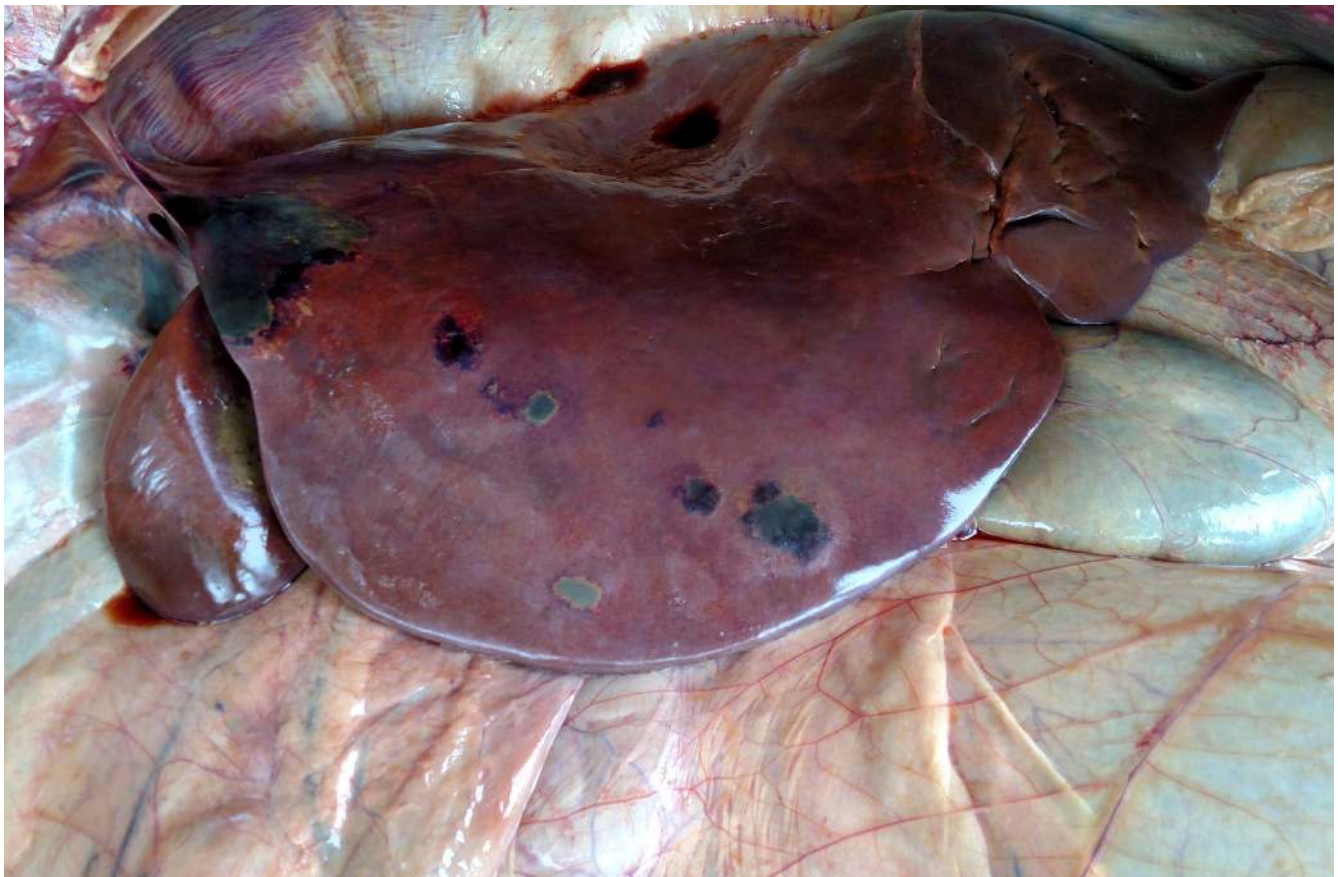

Figure 1. Bacillary hemoglobinuria, liver, bovine. Multiple necrotic foci with varying sizes of green or black color.



Figure 2. Bacillary hemoglobinuria, liver, bovine. Yellow areas of multifocal to coalescent necrosis and areas of multifocal bleeding

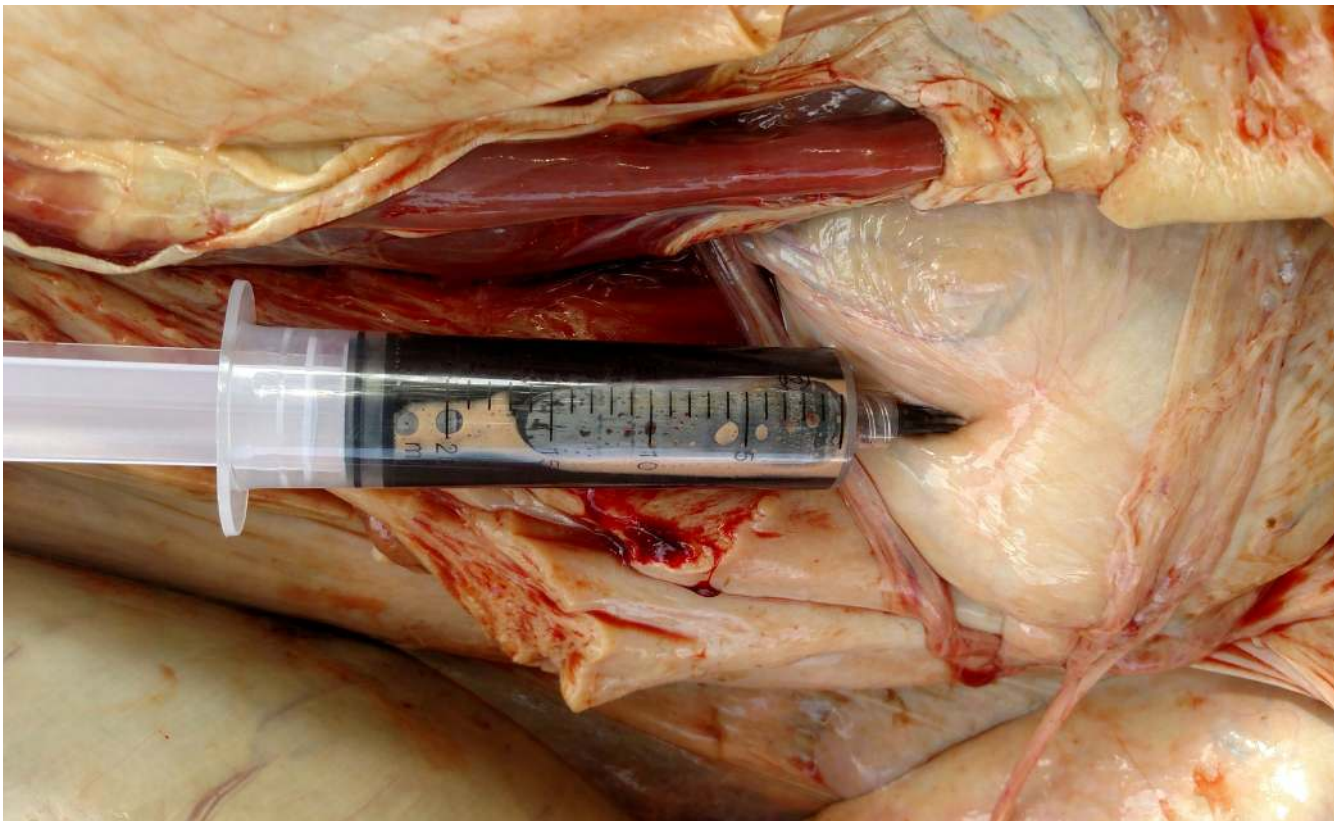


Figure 3. Bacillary hemoglobinuria, urine, bovine. Bladder puncture with black urine.

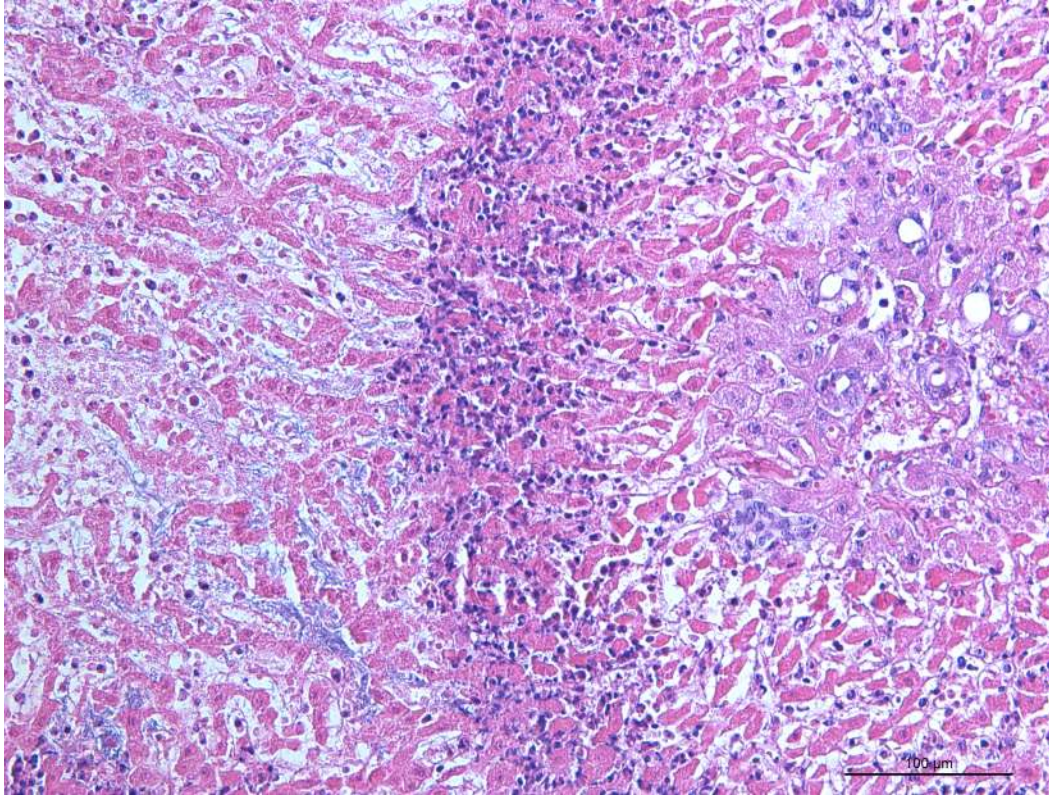


Figure 4. Bacillary hemoglobinuria, liver, bovine, histopathology. Coagulation necrosis area containing well-defined inflammatory infiltrate composed by neutrophils and pyocytes, which delimits the parenchyma with intact or vacuolized hepatocytes. HE, 200 x.

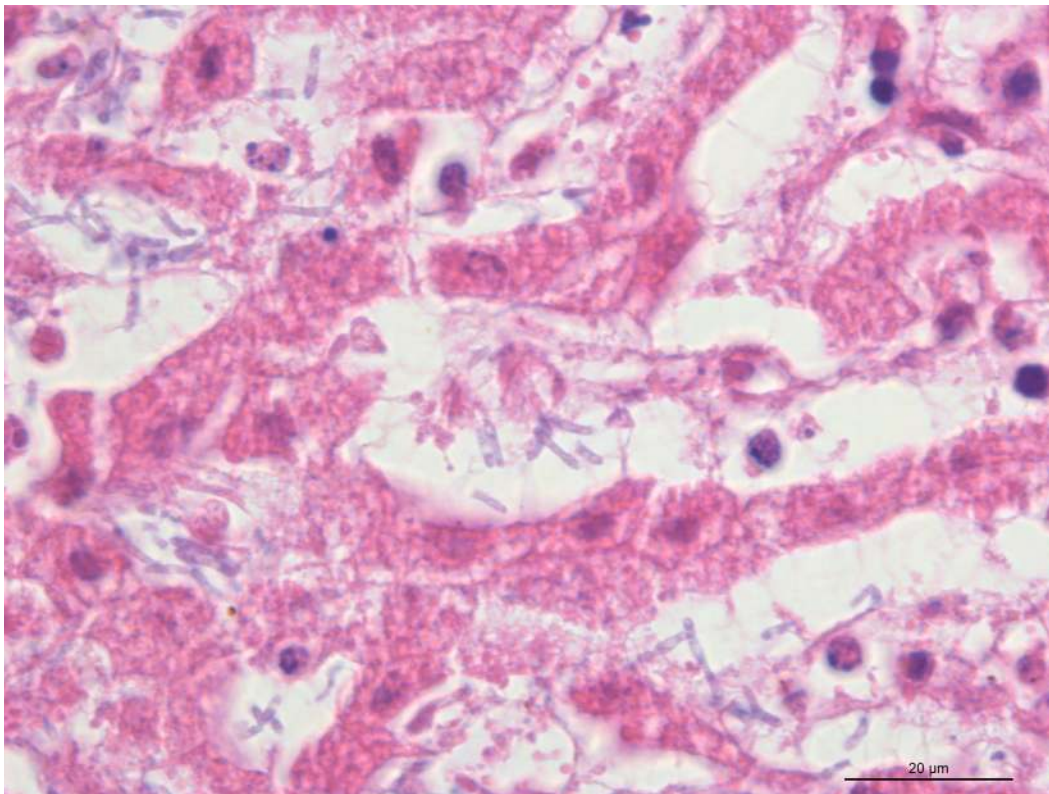


Figure 5. Bacillary hemoglobinuria, liver, bovine, histopathology. Within a segment of necrotic liver there are numerous bacilli, suggestive of *Clostridium* spp. HE, 1000 x.

Discussion

Bacillary hemoglobinuria (BH) is a histotoxic clostridial disease that affects mainly cattle older than 2 years and, occasionally, sheep, horses and wild animals (3,4,6,10). In Brazil, the disease is often reported in cattle in Rio Grande do Sul state in animals parasitized by *F. hepatica* in farms with flooded areas (5,12,14). In this scenario, *C. haemolyticum* reaches the liver after ingestion and, in an anaerobic environment caused by the lesions due to the migration of trematodes in the liver, *C. haemolyticum* spores germinates and produce beta toxin, leading to the BH (8,10,14). Interestingly, in the present work we describe the diagnosis of BH in a cow not parasitized with *F. hepatica* and from a farm without flooded areas. It is uncertain what may have caused the initial lesion in the liver or even if the disease was primarily caused by *C. haemolyticum*. Previous works have hypothesized other possible triggering events that can lead to BH, including telangiectasia and necrobacillosis secondary to rumenitis (8,17).

C. haemolyticum beta toxin, the main virulence factor involved in BH, is known to cause hemolysis, disruption of endothelium and hepatotoxicity, leading to jaundice, hemoglobinuria and hepatic necrosis (8,10,14), all clinical signs seen in the present report. BH is commonly acute, animals die within 48 hours and, in some cases, no symptom is observed before death (5,9,12). On the other hand, some animals can present a sub-acute form, characterized by a decrease on milk production and weakness of hind quarters, clinical signs also seen the present case (10,11).

In addition to the suggestive clinical signs, the gross and microscopic lesions seen in the present case also corroborates other reports of BH in cattle (8,10,14), including the multiple necrotic foci in the liver (Fig. 1) and the typical dark urine (Fig. 3).

The presumptive diagnosis of BH are based on the association of history and clinical signs, but the laboratorial diagnosis is of importance to confirm BH (10). Once *C. haemolyticum* is a fastidious specie, the direct culture of this microorganism commonly leads to a false-negative result. Thus, other techniques, such as direct immunofluorescence, immunohistochemistry or PCR are more common choices (8,10,18). In the present work, an enrichment in BHI broth followed by PCR of the resulting culture was used to confirm the presence of *C. haemolyticum* in the liver. Notheworthy, this PCR was previously used only in isolated colonies, so this is the first study to apply this technique in an unspecified culture in broth. The sequencing of the amplicon was also performed to confirm the specificity of the result. It is also important to note that this animal was also tested for some other causes that would possibly lead to this clinical signs, including infectious necrotic hepatitis (caused by *C. novyi* type B), babesiosis, anaplasmosis and trypanosomiasis (9,13).

There are few reports of successful treatment of bacillary hemoglobinuria, all of them based in antimicrobial therapy (2,16,17). However, the efficiency of treatment is known to be low due the acute course of the disease (10,19). In present report no antimicrobials were administered once BH was not initially considered. Once the treatment is rarely possible and has commonly not effective, the control of BH should focus on the prevention of disease, which is based in control of trematodes and vaccination against *C. haemolyticum* (10,14).

It is also important to note that the affected cow was regularly vaccinated with a commercial vaccine against the most common clostridial infections, including botulism, malignant edema, blackleg and enterotoxaemia, but the vaccine did not contain *C. haemolyticum* in its formulation. Due the possibility of occurrence of BH, the routine vaccination against clostridiosis with immunogens that includes *C. haemolyticum* was recommended.

Conclusions

To the best of our knowledge, this is the first description of BH in Minas Gerais, Brazil. Interestingly, the affected cow was diagnosed in a farm without flood areas and without *F. hepatica* parasitism. The present report highlights the need for of inclusion of BH as differential diagnosis even in animals not parasitized by trematodes and reinforces the need for routine vaccination against this *Clostridium*.

Acknowledgments

This research was supported by funds from FAPEMIG, CAPES, CNPq and PRPq-UFMG.

Ethics of animal experimentation

The case report here occurred in a commercial farm and the diagnosis was forward to our lab for a veterinarian. Thus, no previous approval by an Ethical Committee for the Use of Experimental Animals was necessary.

Conflict of interest

The authors declare no conflict of interest. The founding sponsors had no role in the design of the study; in the collection, analyses, or interpretation of data; in the writing of the manuscript, and in the decision to publish the results.

References

1. Ahourai P, Ardehali M, Ezzi A, Gholami MR, Moosavi M. Bovine Bacillary Hemoglobinuria (*Clostridium Haemolyticum*) in Iran: Journal of Veterinary Diagnostic Investigation. 2016;2:143–4.

2. Arteaga GD. La Hemoglobinuria Ictero-hemorrágica (Hemoglobinuria Bacilar, Enfermedad de la Aguas Rojas) en Venezuela (*). Revista de la Facultad de Medicina Veterinaria y de Zootecnia. 1956;21:504–7.
3. Bender LC, Hall PB, Garner MM, Oaks JL. Bacillary hemoglobinuria in a free-ranging elk calf. J Zoo Wildl Med. 1999;30:293–6.
4. ChangQing Q, XueLi Y. *Clostridium* Infection (Jisizheng) in Yaks in Qinghai, China. Vet Res Commun. 2001;25:555–63.
5. Estima-Silva P, Molarinho KR, Marcolongo-Pereira C, Soares MP, Sallis ESV, Ladeira SRL, et al. Morte súbita em bovinos no Sul do Rio Grande do Sul: epidemiologia e diagnóstico. Pesquisa Veterinária Brasileira. 2016;36:19–23.
6. Micheloud JF, Spath EM, García JA, Cantón GJ, Moreira AR, Odriozola ER. Estudio Retrospectivo de casos de Hemoglobinuria Bacilar Diagnosticados en bovinos de la provincia de Buenos Aires (Argentina). FAVE Cs Vet. 2018;17:30–5.
7. Mosqueda J, Olvera-Ramírez A, Aguilar-Tipacamú G, Cantó G. Current Advances in Detection and Treatment of Babesiosis. Curr Med Chem. 2012;19:1504–18.
8. Navarro MA, Dutra F, Briano C, Romero A, Persiani M, Freedman JC, et al. Pathology of Naturally Occurring Bacillary Hemoglobinuria in Cattle: Veterinary Pathology. 2017;54:457–66.
9. Navarro MA, Uzal FA. Pathobiology and diagnosis of clostridial hepatitis in animals: Journal of Veterinary Diagnostic Investigation. 2019;32:192–202.
10. Navarro M, Quintela FD, Uzal FA. Bacillary Hemoglobinuria. In: Clostridial Diseases of Animals. John Wiley & Sons, Ltd; 2016. p. 265–74.
11. Randhawa SS, Sharma DK, Randhawa CS, Gill BS, Brar RS, Singh J. An outbreak of bacillary haemoglobinuria in sheep in India. Trop Anim Health Prod. 1995;27:31–6.
12. Raymundo D, Bandarra P, Boabaid F, Sonne L, Carloto Gomes D, Driemeier D. Clostridial Diseases Diagnosed in Herbivores in Southern Brazil. Acta Scientiae Veterinari. 2014;42:1–8.
13. Rondelli LAS, Becker M, Caldeira FHB, Ribeiro M, Furlan FH, Colodel EM, et al. Anemia hemolítica em bovinos de corte em sistema de criação extensiva em Mato Grosso e Rondônia. Pesquisa Veterinária Brasileira. 2018;38:1475–83.
14. Santos BL, Ladeira SRL, Riet-Correa F, Soares MP, Marcolongo-Pereira C, Sallis ESV, et al. Clostridial diseases diagnosed in cattle from the South of Rio Grande do Sul, Brazil. A forty-year survey (1978-2018) and a brief review of the literature. Pesquisa Veterinária Brasileira. 2019;39:435–46.
15. Sasaki Y, Kojima A, Aoki H, Ogikubo Y, Takikawa N, Tamura Y. Phylogenetic analysis and PCR detection of *Clostridium chauvoei*, *Clostridium haemolyticum*, *Clostridium novyi* types A and B, and *Clostridium septicum* based on the flagellin gene. Veterinary Microbiology. 2002;86:257–67.
16. Takagi M, Kohyama M, Ono T, Adachi S, Shirao D, Tamura H, et al. Recovery with a regular dose of antibiotics from bacillary hemoglobinuria in a Holstein cow. Journal of Veterinary Medical Science. 2016;78:1737–40.
17. Takagi M, Yamato O, Sasaki Y, Mukai S, Fushimi Y, Yoshida T, et al. Successful Treatment of Bacillary Hemoglobinuria in Japanese Black Cows. Journal of Veterinary Medical Science. 2009;71:1105–8.
18. Uzal FA, Belak K, Rivera E, Robles CA, Feinstein RE. Bacillary Haemoglobinuria Diagnosis by the Peroxidase-Antiperoxidase (PAP) Technique. Journal of Veterinary Medicine, Series B. 1992;39:595–8.
19. Vine N, Fayers J, Harwood D. Bacillary haemoglobinuria in dairy cows. Veterinary Record. 2006;159:160–160.
20. Woo PTK. The haematocrit centrifuge technique for the diagnosis of African trypanosomiasis. Acta Tropica. 1970;27:384–6.