



Case Report

Hematological and biochemical changes in a cow with metastatic cholangiocarcinoma

Lucas Alencar Fernandes Beserra¹; José Augusto Bastos Afonso¹;
Carla Lopes de Mendonça¹; Eduardo Zache¹;
Thailan Arlindo da Silva¹; Luiz Teles Coutinho¹;
Maria Isabel Souza¹; Alexandre Arenales^{1*}

¹Clínica de Bovinos, Campus Garanhuns, Universidade Federal Rural de Pernambuco (UFRPE)
Av. Bom Pastor s/n, Boa Vista, Garanhuns - PE, Brasil.

*Corresponding author: E-mail: alexandre.arenales88@gmail.com

Submitted September, 16th 2022, Accepted October, 26th 2022

Abstract

We describe here hematological and biochemical findings in a cow with metastatic cholangiocarcinoma. On physical examination, apathy with congested mucous membranes, tachycardia and enlarged abdomen; hypoperistalsis in rumen, abomasum and intestines. In hematological examination, icteric plasma with leukocytosis by neutrophilia with regenerative left shift and inversion of the proportion between lymphocytes and segmented neutrophils, and hypofibrinemia. In serum biochemistry: hyperproteinemia, hypoalbuminemia, hyperglobulinemia, low albumin/globulin ratio and high levels of aspartate aminotransferase, gamma-glutamyltransferase. The cow died and in necropsy was observed a severe and diffuse increase in volume predominantly on the hepatic right lobe and moderate increase of volume in mesenteric lymph nodes. Which was diagnosed microscopically as a cholangiocarcinoma, characterized by arrangements in irregular and coalescent ducts. In conclusion, cholangiocarcinoma may cause important hematological and biochemical changes in cattle.

Key words: Aspartate aminotransferase, gamma-glutamyltransferase, enzymatic lactate.

Introduction

Primary hepatic neoplasia is incommun in cattle, being mostly incidental findings in slaughterhouses (6,7,10,12). Cholangiocarcinoma is a malignant neoplasm from epithelial cells of intra or extra hepatic biliary ducts described in various species as cats, dogs, ovines, caprines, equines and cattle (1,8). Generally, hepatopathies are characterized by disturbances in serum compounds that are synthesized, removed, metabolized and excreted by the liver (11). In hepatic neoplasms, the main changes are elevation of extravasation enzymes (alanine aminotransferase, aspartate aminotransferase, sorbitol dehydrogenase) and induction enzymes (alkaline phosphatase and gamma-glutamyl transferase); also, elevation of bile acids, serum bilirubin, glycemic level and nonspecific hematological findings (1,11). This paper aims to describe hematological and biochemical changes in a cow with metastatic cholangiocarcinoma.

Case Description

A female 8-years-old Girolando cow, was referred to the *Clínica de Bovinos de Garanhuns/ Universidade Federal Rural de Pernambuco (CBG/UFRPE)*, with anamnesis of apathy, progressive anorexia, drop in milk production and treatment with one dose of imidocarb dipropionate (9 mL, subcutaneous). In physical examination, permanent left sternal lateral recumbency, apathy, congested and icteric mucous membranes, tachypnea (44 bpm) with polipnea, tachycardia (84 bpm), no appetite, ventrally bulging abdomen, slightly increased abdominal tension, and hypomotility of the rumen, abomasum, and intestines. On rectal examination, dry feces covered by mucus, and roughness in the parietal peritoneal surface. Hemogram showed icteric plasma with inversion of the proportion between lymphocytes and segmented neutrophils; and neutrophilic leukocytosis with regenerative left shift,

Table 1. Hematological findings in a cow affected with metastatic cholangiocarcinoma.

	Results	Reference range (2)
Erythrocytes (10 ⁶ /μL)	7.15	5.0 - 10.0
PCV (%)	31	24 – 36
Hemoglobin (g/dL)	10.31	8.0 – 15.0
MCV (fL)	43.3	40.0 – 60.0
MCHC (%)	33.3	30.0 – 36.0
Plasma protein (g/dL)	9.0	7.0 – 8.5
Plasma fibrinogen (mg/dL)	200	300 – 700
Leukocytes (μL)	16,900	4,000 – 12,000
Lymphocytes (/μL)	5,239	2,500 – 7,500
Segmented neutrophils (/μL)	11,323	600 - 4,000
Band neutrophils (/μL)	338	0 – 200

PCV: packed cell volume; MCV: mean corpuscular volume; CHCM: mean corpuscular hemoglobin concentration.

Table 2. Biochemical findings in a cow affected with metastatic cholangiocarcinoma

	Results	Reference ranges (3)
Plasma protein (mg/dL)	9.05	6.74 - 7.46
Albumin (g/dL)	2.34	3.03 - 3.55
Globulin (g/dL)	6.71	3.0 - 3.48
Albumin:Globulin ratio	0.34	0.84 - 0.94
Aspartate aminotransferase(U/I)	576.2	78 - 132
Gamma-glutamyltransferase (U/I)	963.9	6.1 - 17.4
Enzymatic lactate (mmol/L)	12.9	0.55 - 2.22

hyperproteinemia and hypofibrinemia (Table 1). In the analysis of rumen fluid: compromised flora, pH of 9.0 and chloride content of 17.05 mEq/L. In serum biochemistry, increase in total serum protein, hypoalbuminemia, hyperglobulinemia, reduction in albumin/globulin ratio and elevation in liver enzymes aspartate aminotransferase (AST), gamma-glutamyltransferase (GGT) and elevation in enzymatic lactate (Table 2).

The animal died and in necropsy was observed in the liver, marked and diffuse increase in volume predominately on the right lobe, with scattered irregular yellowish natural surface and severe increase in consistency. On the cut surface, multifocal to coalescent poor delimited scattered yellowish areas among hepatic parenchyma with severe evidence of lobular pattern and multiple thrombi in blood vessels (Fig.1). In the parietal peritoneum multiple coalescing nodular structures, white with irregular surface, of approximately 0.3 cm in diameter. Multifocal moderate and diffuse enlargement of mesenteric lymph nodes. In mesentery and mesocolon, diffuse and marked severe with gelatinous aspect.

Microscopically, hepatic parenchyma was approximately half replaced by a neoplastic proliferation of moderate cell density arranged in irregular and coalescent ducts, lined by one to two layers of flat cuboidal epithelial

cells and supported by moderate to abundant dense fibrous avascular stroma. Individually, the cells were small, poorly delimited and well grouped, with scant cytoplasm and small, round, central nucleus with dense chromatin, moderate anisocytosis and anisokaryosis. No mitotic figures were observed. In the mesenteric lymph node, occasional multiple foci of irregular ductal arrangements, similar to those described in the liver.

Discussion

Here we describe the first case of metastatic cholangiocarcinoma in cattle with findings of hematological and serum biochemistry of liver enzymes, which are non-existent in the literature. In dogs with cholangiocarcinoma, the evaluation of liver enzymes showed elevation of serum alanine aminotransferase, alkaline phosphatase, aspartate aminotransferase and gamma-glutamyltransferase (2,5,9); elevated serum lactate dehydrogenase and nonspecific hematological abnormalities as leukocytosis, are also observed (4,9).

The diagnosis in the present case was based on anatomopathological findings, with laboratory data indicating hepatic functional impairment (11). In

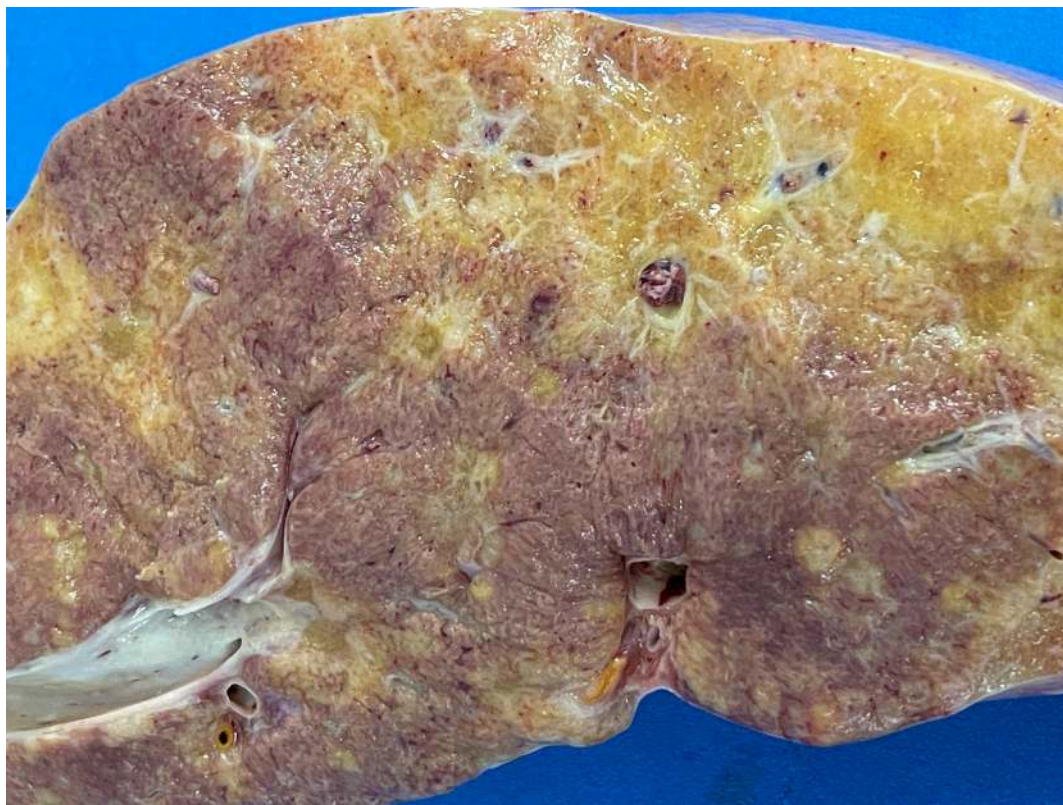


Figure 1. Cow, liver, cut surface. Multifocal to coalescent poor delimited scattered yellowish areas diagnosed microscopically as cholangiocarcinoma.

conclusion, cholangiocarcinoma in cattle may cause important hematological alterations as icteric plasma, hyperproteinemia and hypofibrinemia, and changes in serum levels of liver enzymes, such as elevation of AST, GGT and enzymatic lactate.

References

1. Cullen JM. Tumor of the liver and gallbladder. In Meuten DJ, editor. *Tumors in Domestic Animals*. 5 ed. Ames: Wiley Blackwell; 2017. p. 495-499.
2. Jain NC. *Essentials of veterinary hematology*. Philadelphia: Lea & Febinger, 417f. 1993.
3. Kaneko JJ, Harvey JW, Bruss ML. *Clinical biochemistry of domestic animals*. 6.ed. New York: Academic Press, 904f. 2008.
4. Patnaik AK, Hurvitz AI, Lieberman PH. Canine hepatic neoplasms: a clinicopathologic study. *Vet Pathol* 17:553-564, 1980.
5. Patnaik AK, Hurvitz AI, Lieberman PH, Johnson GF. Canine hepatocellular carcinoma. *Vet Pathol* 18:427-438, 1981.
6. Reis MO, Slavieiro M, Lorenzett MP, Cruz RAS, Guimarães LLB, Pavarini SP, Driemeier D, Sonne C. Neoplasmas bovinos diagnosticados no Setor de Patologia Veterinária da UFRGS, Porto Alegre (2005-2014). *Pesq Vet Bras* 37(2):105-109, 2017.
7. Santos RL, Alessi AC. *Patologia veterinária*. 2.ed. Rio de Janeiro: Roca, 2016.
8. Stalker MJ, Hayes MA. Liver and biliary system. In: MAXIE MG, Jubb, Kennedy and Palmer's *Pathology of Domestic Animals*, 5 ed. Saunders Elsevier, 2007. p. 297-388.
9. Strombeck DR. Clinicopathologic features of primary and metastatic neoplastic disease of the liver in dogs. *J Am Vet Med Assoc* 173:267-269, 1978.
10. Tessele B, Barros CSL. Tumores em bovinos encontrados em abatedouros frigoríficos. *Pesq Vet Bras* 36(3):145-160, 2016.
11. Thrall MA, Weiser G, Alisson RW, Campbell TW. *Hematologia e Bioquímica Clínica Veterinária*. 2.ed. Rio de Janeiro: Guanabara Koogan, 678p. 2015.
12. Vielmo A, Panziera W, Bianchi MV, Argenta FF, Lorenzo C, Vielmo LA, Pavarini SP, Driemeier D. Primary hepatic neoplasms in cattle. *Pesq Vet Bras*; 40:409-416, 2020.