

**Review Article****Infectious diseases of neotropical primates**Ayisa Rodrigues Oliveira¹, Renato Lima Santos^{1*}¹Departamento de Clínica e Cirurgia Veterinárias, Escola de Veterinária, Universidade Federal de Minas Gerais.
Av. Antonio Carlos, 6627 - 31270-901 Belo Horizonte, MG, Brazil.*Corresponding author: rls@ufmg.brSubmitted October, 31th 2022, Accepted February, 13th 2023**Abstract**

Neotropical primates are represented by more than 200 species and subspecies distributed in five families. Considering that some of these species are considered endangered, disease investigation in these populations is critical for conservation strategies. Therefore, an increasing number of studies and publications on this topic became available in the past few years. This review deals with infectious diseases of neotropical primates, with focus on free-ranging animals, including those caused by bacterial, viral, protozoal, metazoan, or mycotic infectious organisms, with particular emphasis on gross and microscopic lesions associated with these diseases. In addition, a few relevant unpublished cases of infection by *Staphylococcus* spp., *Streptococcus* spp., *E. coli* and *Pseudomonas* spp. were included in this review.

Key words: non-human primates, neotropical primates, infectious diseases, conservation medicine.

Introduction

Neotropical primates (New World primates - NWP) are represented by five large families: Callitrichidae (tamarins and marmosets), Cebidae (capuchins and squirrel monkeys), Aotidae (owl monkeys), Pitheciidae (sakis, titi monkey and uakaris) and Atelidae (howler monkey, woolly monkey, muriqui and spider monkey), totalizing 204 species and sub-species (174, 217). These groups have animals with variable sizes and weights, such as the small pigmy (*Cebuella pigmaea*) weighting 100 g and muriquis (*Brachyteles arachnoides*) weighting 14 kg (192). They have arboreal behavior and diversified eating habits, with species that consume predominantly fruits and leaves, while other species have diets based on invertebrates and small mammals (217). These animals represent approximately 40% of all mammalian biomass in Western Amazon (except for flying mammals), and its frugivorous behavior, together with other frugivorous animals, are responsible for the maintenance of about 80% of the neotropical plants (192).

All NWP are included in the Convention on International Trade in Endangered Species of Wild Fauna and Flora (CITES) (217). The Brazilian Atlantic Forest itself holds 24 species of NWP, being 20 endemic and nine critically endangered, according to IUCN Red List (79). There are many factors associated with this threatening, such as habitat loss and degradation, anthropization, illegal trade, hunting and emerging infectious diseases (55, 192, 224). Importantly, NWP are natural and accidental hosts of various infectious agents, and due to the phylogenetic proximity with humans, these animals may often be considered reservoir and sentinels of important zoonoses, as exemplified in yellow fever (YF) outbreaks (93, 135).

Identification of diseases that affects free-ranging NWP, as well as the understanding of their pathogenesis, aids, in addition to the recognition of sentinels and potential reservoirs of infectious agents, also in the development of public health and *in situ* and *ex situ* conservation programs. Therefore, our goal was to provide a comprehensive review of the literature on infectious diseases of neotropical primates.

Neotropical primates (New World Primates - NWP)

NWP, also known as platyrrhines, are species from Primates Order with wide distribution in the Central and South America. These species differ from Old-World primates (OWP), or catarrhines, due to its flat nose and lateral nostrils (217). There are some discussions in the literature about the taxonomy of the Platyrrhini Parvorder: some authors divide this group in five Families (Callithrichidae, Cebidae, Aotidae, Pitheciidae and Atelidae) (174, 217); and others in three Families (Cebidae, Atelidae and Pitheciidae) (53, 217), with 20 genus and 152 species (174). In this study will be use the taxonomy described by Rylands et al. (174).

Callithrichidae have seven genera, being four named as marmosets (*Callithrix*, *Cebuella*, *Callibella*, and *Mico*) and three as tamarins (*Saguinus*, *Leontopithecus*, and *Callimico*). This Family have the smallest primate's specie of the world, the 100 g-weight small pigmy (*Cebuella pigmaea*) and differ from the other Platyrrhini families due to its claws, instead of nails, useful to climb and access sap from the threes, an important feature from its diet; and due to the number of molars, two rather than three in each side of mandibular and maxillae. Also, the animals from this family usually have head ornaments such as tufts, crests, manes, and whiskers, and a long non-prehensile tail, are mainly arboreal, diurnal, and omnivorous, feeding from sap to insects and small vertebrates, according to availability (192, 217). Tamarins and marmoset are extensively used in biomedical research, being the common marmoset (*Callithrix jacchus*) the most widely NWP used in experimental laboratories, due to its small size, easy breeding and well adaptation to captivity (222).

Cebidae holds two to three genera of monkeys: capuchins – *Cebus* and *Sapajus*; and squirrel monkeys – *Saimiri* (192, 217). The existence of *Sapajus* as a different

genus from *Cebus* is still questionable (192). Capuchins are medium-size monkeys with 2.5 to 5 kg, with a semi prehensile tail and thick molars (192). Squirrel monkeys are smallest than capuchins, weighting 900 g to 1 kg and have a white mask around their eyes (192). Capuchins and squirrel monkeys are also commonly used in laboratorial facilities (222).

Atelidae have the largest monkeys from the Neotropics with four genera (*Ateles*, *Brachyteles*, *Alouatta*, and *Lagothrix*). They all have a prehensile long tail with mostly arboreal habitat and frugivorous diet. *Alouatta* has very developed laryngeal and hyoid processes, significantly increasing its vocalization potential (192, 217). Species from the Atelidae and Pitheciidae families are not well adapted to captivity, being hardly used in biomedical research (222). In wildlife, populations of *Alouatta* have being giving more attention due to their high susceptibility to YF virus (YFV) infection, being considered an important sentinel to that disease (180).

Pitheciidae have four genera (*Cacajao*, *Callicebus*, *Chiropotes* and *Pithecia*). These animals do not have a prehensile tail and its diets vary from fruits and leaves to insects (192).

Aotidae have only one genus, *Aotus*, known as night monkey or owl monkey. These animals have big eyes and lack of a prehensile tail, weighting 570 g to 1.6 kg. They are the only nocturnal primate from de Neotropics, being more active at dawn and dusk. Their diet is based on fruits, flowers, leaves and insects and they are widely distributed throughout the rain forest areas of South America (192,222). Owl monkeys became very important for research in antimalarial drug development and to immunological and ocular studies (222).

Infectious diseases

Table 1 summarizes bacterial, viral, protozoan, and fungal pathogens reported in free-ranging NWP.

Table 1. List of bacterial, viral, protozoan and fungal pathogens reported in free-ranging NWP.

Pathogen	Agent	Host genus	Host origin	Pathological findings	Diagnostic tool
Bacteria	<i>Escherichia coli</i>	<i>Alouatta</i> ^{55,214}	Brazil ⁵⁵ , Mexico ²¹⁴	Suppurative pneumonia ⁵⁵ NP ²¹⁴	N ⁵⁵ , HP ⁵⁵ , IHC ⁵⁵ , BC ^{55,214}
	<i>Pasteurella</i> spp.	<i>Alouatta</i> ⁵⁵ , <i>Mico</i> ¹⁹⁵	Brazil ^{55,195}	Suppurative pneumonia ^{55,195} Systemic leukocytosis ¹⁹⁵	N ^{55,195} , HP ^{55,195} , BC ^{55,195} , PCR ¹⁹⁵
	<i>Pseudomonas</i> spp.	<i>Alouatta</i> ¹²⁴ , <i>Cebus</i> ¹²⁴	Brazil ¹²⁴	NP ¹²⁴	Blood-PCR ¹²⁴
	<i>Klebsiella pneumoniae</i>	<i>Leontopithecus</i> ²⁴	Brazil ²⁴	Fibrinosuppurative bronchopneumonia ²⁴ Fibrinosuppurative pericarditis ²⁴ Splenic lymphoid depletion ²⁴ Diffuse hepatic degeneration ²⁴	N ²⁴ , HP ²⁴ , BC ²⁴

Bacteria	<i>Staphylococcus aureus</i>	<i>Leontopithecus</i> ¹²⁷	Brazil ¹²⁷	Suppurative meningoencephalitis ¹²⁷	N ¹²⁷ , HP ¹²⁷ , BC ¹²⁷
	<i>Leptospira</i> spp.	<i>Alouatta</i> ⁵⁵ , <i>Ateles</i> ⁸⁴ , <i>Callithrix</i> ²²⁴ , <i>Leontocebus</i> ⁹ , <i>Leontopithecus</i> ¹²⁹ , <i>Saguinus</i> ⁹ , <i>Sapajus</i> ⁶⁹	Bolivia ⁸⁴ , Brazil ^{55,69,129,224} , Peru ⁹	Interstitial pneumonia with hemorrhage, edema, and fibrin exudation ²²⁴ Interstitial nephritis with tubular degeneration and necrosis ²²⁴ Hepatocyte cord dissociation and necrosis with sinusoid leukocytosis ²²⁴ ND ⁵⁵ , NP ^{9,69,84,129}	N ^{55,224} , HP ^{55,224} , IHC ²²⁴ , qPCR ²²⁴ , PCR ¹²⁹ , MAT ^{9,69,84,129}
	<i>Borrelia burgdorferi</i>	<i>Leontopithecus</i> ¹⁷⁹	Brazil ¹⁷⁹	NP ¹⁷⁹	Nested-PCR ¹⁷⁹
	<i>Clostridium botulinum</i> type C toxin	<i>Callithrix</i> ¹⁹⁷	Brazil ¹⁹⁷	NP ¹⁹⁷	MNT ¹⁹⁷
Virus	<i>Mycoplasma</i> spp. (hemoplasmas)	<i>Alouatta</i> ^{44,181} , <i>Saimiri</i> ²⁰ , <i>Saguinus</i> ²⁰ , <i>Sapajus</i> ²⁰	Brazil ^{20,44,181}	NP ^{20,44,181}	Blood-PCR ^{20,44,181} , Blood-smears cytology ⁴⁴
	Herpes simplex virus (HSV)	<i>Callithrix</i> ^{21,40,102,223}	Brazil ^{21,40,102,223}	Erosive and ulcerative lesions at skin and mucocutaneous junctions, conjunctivitis, nuclear inclusion bodies in epithelial cells that surrounds the vesicles or erosions ^{21,40,102,223} Ulcerative glossitis with syncytial cells and nuclear inclusion bodies ^{102,223} Necrotizing hepatitis with nuclear inclusion bodies ²²³ Lymphoplasmacytic to neutrophilic encephalitis with nuclear inclusion bodies ^{21,40,102,223} Lymphocytic adenitis, nephritis, and lymphoid hyperplasia ^{40,223}	N ^{40,102,223} , HP ^{21,40,102,223} , IHC ^{102,223} , Nested PCR ⁴⁰ , qPCR ²²³ , TEM ^{21,223}
	Gammaherpesvirus	<i>Saguinus</i> ²¹⁰ , <i>Saimiri</i> ²¹⁰ , <i>Pithecia</i> ²¹⁰	French Guiana ²¹⁰	NP ²¹⁰	Blood-PCR ²¹⁰
Yellow fever virus (YFV)	<i>Alouatta</i> ^{10,46,55,73,82,93,180} , <i>Ateles</i> ⁸⁴ , <i>Callicebus</i> ^{59,180} , <i>Callithrix</i> ^{46,82,93,180} , <i>Leontopithecus</i> ¹⁸⁰ , <i>Sapajus</i> ^{93,180}	Bolivia ⁸⁴ , Brazil ^{10,46,55,59,73,82,93,180}	Midzonal to diffuse hepatocellular necrosis with apoptotic bodies, mild mononuclear infiltrate and lipidosis ^{59,73,93,180} Lymphoid depletion ⁵⁹ Acute renal tubular necrosis ^{59,93} NHF ^{93,180} , ND ^{10,46,55,82} , NP ⁸⁴	N ^{55,59,73,93,180} , HP ^{10,55,59,73,93,180} , IHC ^{10,46,55,59,73,93,180} , RT-qPCR ^{46,59,73,82,180} , VI ¹⁰ , IFA ¹⁰ , ND ⁸⁴	

Virus	Dengue virus (DENV)	<i>Alouatta</i> ^{35,51,134} , <i>Cebus</i> ⁵¹ , <i>Saimiri</i> ³⁵	Costa Rica ^{35,51} , Argentina ¹³⁴	NP ^{35,51,134}	PRNT ^{35,134} , RT-PCR ⁵¹
	Zika virus (ZIKV)	<i>Callithrix</i> ^{57,209} , <i>Sapajus</i> ^{57,209}	Brazil ^{57,209}	NHF ²⁰⁹ , NP ^{57,209}	HP ²⁰⁹ , RT-qPCR ^{57,209} , PRNT ⁵⁷
	Saint Louis encephalitis virus (SLEV)	<i>Ateles</i> ⁸⁴ , <i>Alouatta</i> ^{35,39,134,205} , <i>Sapajus</i> ²⁰⁵	Argentina ^{39,134} , Bolivia ⁸⁴ , Brazil ²⁰⁵ , Costa Rica ³⁵	NP ^{35,39,84,134,205}	PRNT ^{35,134} , HI ^{39,205} , MNT ²⁰⁵ , ND ⁸⁴
	West Nile virus (WNV)	<i>Alouatta</i> ^{35,51,134}	Costa Rica ^{35,51} , Argentina ¹³⁴	NP ^{35,51,134}	PRNT ^{35,134} , RT-PCR ⁵¹
	Ilheus virus (ILHV)	<i>Alouatta</i> ¹³⁴	Argentina ¹³⁴	NP ¹³⁴	PRNT ¹³⁴
	Bussuquara virus (BSQV)	<i>Alouatta</i> ¹³⁴	Argentina ¹³⁴	NP ¹³⁴	PRNT ¹³⁴
	Eastern equine encephalitis virus (EEEV)	<i>Ateles</i> ⁸⁴	Bolivia ⁸⁴	NP ⁸⁴	ND ⁸⁴
	Flavivirus (undetermined)	<i>Alouatta</i> ^{35,51} , <i>Cebus</i> ⁵¹ , <i>Saimiri</i> ⁵¹	Costa Rica ^{35,51}	NP ^{35,51}	PRNT ³⁵ , ELISA ⁵¹
	Tetraparvovirus (PARV4)	<i>Alouatta</i> ³⁴ , <i>Cebus</i> ³⁴ , <i>Ateles</i> ³⁴	Costa Rica ³⁴ , El Salvador ³⁴	NP ³⁴	Blood-PCR ³⁴
	Bocaparvovirus (HBoV)	<i>Alouatta</i> ³⁴ , <i>Cebus</i> ³⁴	Costa Rica ³⁴ , El Salvador ³⁴	NP ³⁴	Blood-PCR ³⁴
	Erythroparvovirus (B19)	<i>Alouatta</i> ³⁴ , <i>Cebus</i> ³⁴	Costa Rica ³⁴ , El Salvador ³⁴	NP ³⁴	Blood-PCR ³⁴
	Rabies lyssavirus (RABV)	<i>Callithrix</i> ^{136,58,88} , <i>Sapajus</i> ^{86,107}	Brazil ^{136,58,86,88,107}	NP ^{58,86,88,107,136}	DIF ^{58,86,88,136} , MIT ^{86,88,136} , RT-PCR ^{58,86,88,136} , RFFIT ¹⁰⁷
	Simian foamy virus (SFV)	<i>Aotus</i> ⁶⁶ , <i>Ateles</i> ⁶⁶ , <i>Cebus</i> ⁶⁶ , <i>Lagothrix</i> ⁶⁶ , <i>Leontopithecus</i> ¹²⁶ , <i>Pithecia</i> ⁶⁶	Brazil ¹²⁶ , Peru ⁶⁶	NP ^{126,66}	EIA ⁶⁶ , WB ⁶⁶ , qPCR ^{126,66}
	Hepatitis A virus (HAV)	<i>Sapajus</i> ²⁰⁶	Brazil ²⁰⁶	NP ²⁰⁶	ELISA ²⁰⁶
	Papillomavirus (PV)	<i>Alouatta</i> ¹⁷⁶ , <i>Sapajus</i> ¹⁷⁶	Argentina ¹⁷⁶	NP ¹⁷⁶	PCR ¹⁷⁶
	Adenovirus (AdV)	<i>Alouatta</i> ¹² , <i>Callithrix</i> ⁵⁶ , <i>Cebus</i> ⁵⁶	Brazil ⁵⁶ , Mexico ¹²	NP ^{12,56}	Stool-PCR ¹² , PRNT ⁵⁶
	Vaccinia virus (orthopoxvirus)	<i>Alouatta</i> ¹ , <i>Sapajus</i> ¹	Brazil ¹	NP ¹	PRNT ¹
	SARS-COV-2	<i>Mico</i> ¹⁵⁶	Brazil ¹⁵⁶	Interstitial pneumonia ¹⁵⁶	RT-PCR ¹⁵⁶ , IHC ¹⁵⁶

Protozoan	<i>T. gondii</i>	<i>Alouatta</i> ^{55,128,143} , <i>Brachyteles</i> ¹⁸³ , <i>Callithrix</i> ¹²⁸ , <i>Cebus</i> ¹⁴³ , <i>Sapajus</i> ²³	Brazil ^{23,55,128,143,183}	Necrotizing hepatitis, splenitis, lymphadenitis and nephritis ¹⁸ Non-suppurative meningoencephalitis ¹⁸³ Observation of intralesional tachyzoites and bradyzoites in multiple organs ^{55,183} NP ^{23,128,143}	N ^{55,183} , HP ^{55,183} , IHC ^{55,183} , MAT ^{23,128,143} , PCR ¹⁸³
	<i>Leishmania</i> sp.	<i>Alouatta</i> ^{112,120,172} , <i>Aotus</i> ^{4,28,78} , <i>Callithrix</i> ^{154,212} , <i>Chiropotes</i> ^{89,90} , <i>Mico</i> ²⁸ , <i>Saguinus</i> ^{89,90} , <i>Sapajus</i> ^{23,28}	Argentina ^{4,112} , Brazil ^{23,28,89,90,154,212} , French Guiana ¹²⁰ , Mexico ¹⁷² , Panama ⁷⁸	NP ^{4,23,28,78,89,90,112,120,154,172,212}	ELISA ^{23,154,172} , Blood-PCR ^{28,123,154,212} , Skin-PCR ^{112,154} , PCR-RFLP ^{4,112} , PI ^{78,89,90} , WB ⁷⁶ , IFA ¹⁷²
	<i>Trypanosoma</i> sp.	<i>Alouatta</i> ^{113,172,173} , <i>Ateles</i> ¹⁷³ , <i>Callithrix</i> ³⁸ , <i>Mico</i> ²⁸ , <i>Leontopithecus</i> ^{99,132,133} , <i>Saguinus</i> ¹⁹³ , <i>Saimiri</i> ²²⁷ , <i>Sapajus</i> ^{23,28}	Argentina ¹¹³ , Brazil ^{23,28,38,99,132,133,193,227} , Mexico ^{172,173}	NP ^{23,28,38,113,99,132,133,172,173,193,227}	ELISA ^{172,173} , TESA-blot ²³ , Blood-PCR ^{28,38,113,193,173} , qPCR-HRM ¹⁷³ , Blood-smears cytology ^{38,99,193} , IFA ^{99,132,133,172} , HC ^{99,132,227} , Xenodiagnosis ²²⁷
	<i>Plasmodium</i> spp.	<i>Alouatta</i> ^{3,41,83,145,169} , <i>Ateles</i> ^{33,169} , <i>Callicebus</i> ²⁵ , <i>Cebus</i> ¹⁶⁹ , <i>Pithecia</i> ²⁵ , <i>Saimiri</i> ³³ , <i>Sapajus</i> ^{23,33,64}	Brazil ^{3,23,25,41,64,145} , Colombia ¹⁶⁹ , Costa Rica ³³	Hemozoin pigment intracytoplasmic in macrophages at red pulp from the spleen ³ NP ^{23,25,33,41,64,145,169}	HP ³ , Blood-smears cytology ^{3,25,64} , Blood-PCR ^{3,23,25,33,41,64} , Stool-PCR ^{79,169} , Nested-PCR ¹⁴⁵ , IFA ⁶⁴
	<i>Entamoeba</i>	<i>Alouatta</i> ²¹⁹	Mexico ²¹⁹	NP ²¹⁹	FPE ²¹⁹ , PCR ²¹⁹
Fungal agent	<i>Aspergillus fumigatus</i>	<i>Alouatta</i> ⁷³	Brazil ⁷³	Necrosuppurative bronchopneumonia with angioinvasive fungal hyphae ⁷³	N ⁷³ , HP ⁷³ , CISH ⁷³ , PCR ⁷³
	<i>Microsporium</i> spp.	<i>Leontopithecus</i> ¹⁴²	Brazil ¹⁴²	NP ¹⁴²	FC ¹⁴²
	<i>Malassezia</i> spp.	<i>Leontopithecus</i> ¹⁴²	Brazil ¹⁴²	NP ¹⁴²	PI ¹⁴² , cytology ¹⁴²

BC: bacterial culture, CISH: chromogenic in situ hybridization, DIF: direct immunofluorescence test, DPI: direct parasitological identification, EIA: enzyme immunoassay, FC: fungal culture, FPE: fecal parasitological examination, HC: hemoculture, HI: hemagglutination inhibition, HP: histopathology stained by hematoxylin and eosin, IFA: indirect immunofluorescence assay, IHC: immunohistochemistry, MIT: mouse inoculation test, MNT: mouse neutralization test, N: necropsy, ND: not described, NP: not performed, NHF: nonspecific histopathological findings, PI: parasite isolation, PRNT: plaque reduction neutralization test, RFFIT: rapid fluorescent focus inhibition test, TEM: transmission electron microscopy, VI: viral isolation.

Bacteria

Among all the infectious diseases, the ones caused by bacteria are the most commonly reported in free-ranging NWP (55), and it is often associated with history of trauma, which is an important predisposing factor or a consequence of it (55, 195).

Gram-positive cocci

Staphylococcus spp. are Gram-positive cocci with zoonotic potential, being a part of the microbiota, but considered opportunistic pathogens. *Staphylococcus aureus* is the species most reported. The infection usually starts as a skin lesion, evolving to cellulitis, lymphangitis, and bacteremia. Once bacteremia is established, suppurative inflammation with intralésional bacterial colonies can be found in multiple organs, causing suppurative pneumonia, hepatitis, meningitis, endocarditis, and nephritis (29, 116). Reports of infections in free-ranging NWP are rare. Molina et al. (127) described a single case of suppurative meningoencephalitis in an infant golden-headed lion tamarin (*Leontopithecus chrysomelas*), that, although was rescue from wildlife, stayed at a captive environment for 33 days before developing clinical signs. Diagnosis in that case was performed by the visualization of Gram-positive cocci by histopathology and was confirmed by bacterial culture. Additionally, we have unpublished data with *Staphylococcus* spp. causing suppurative meningitis, bronchopneumonia, and bacteremia in free-ranging marmosets (*Callithrix* spp.) and necrotizing

and suppurative hepatitis in a free-ranging capuchin (*Sapajus* spp.) (Fig. 1). These cases were detected in a study of disease investigation in free-ranging NWP from Rio de Janeiro State, which died naturally in wild (146). The diagnoses were performed by histopathology, immunohistochemistry (IHC), and polymerase chain reaction (PCR).

Streptococcus pneumoniae is a Gram-positive coccus carried by asymptomatic animals and humans and transmitted by aerosol. Infections are enhanced by stressful factors and starts in the respiratory tract quickly progressing to bacteremia and multiple organs infections, being meningitis and arthritis a common consequence in NWP (116, 217). Other species of *Streptococcus* have also been described in NWP, such as *Streptococcus pasteurianus* causing endocarditis and sepsis in a puerperal tamarin (*Saguinus imperator*) (147) and *Streptococcus equi* subsp. *zooepidemicus* responsible for outbreaks in colonies of marmosets after being exposed by horse meat or keepers in contact with horses (117, 185). Diagnostic is performed based on identification of Gram-positive cocci at histopathology, confirmed by bacterial culture or PCR (116, 117, 147, 185). There is no information in the literature about the prevalence of *Streptococcus* species in free-ranging NWP. However, we have two unpublished cases of necrotizing bronchopneumonia with Splendore-Hoeppli and bacteremia caused by *Streptococcus* spp. in free-ranging marmosets (*Callithrix* spp.) (Fig. 2). Both animals were free-ranging adults, one male and one female, which died naturally, and the diagnoses were performed by histopathology IHC, and PCR (146).

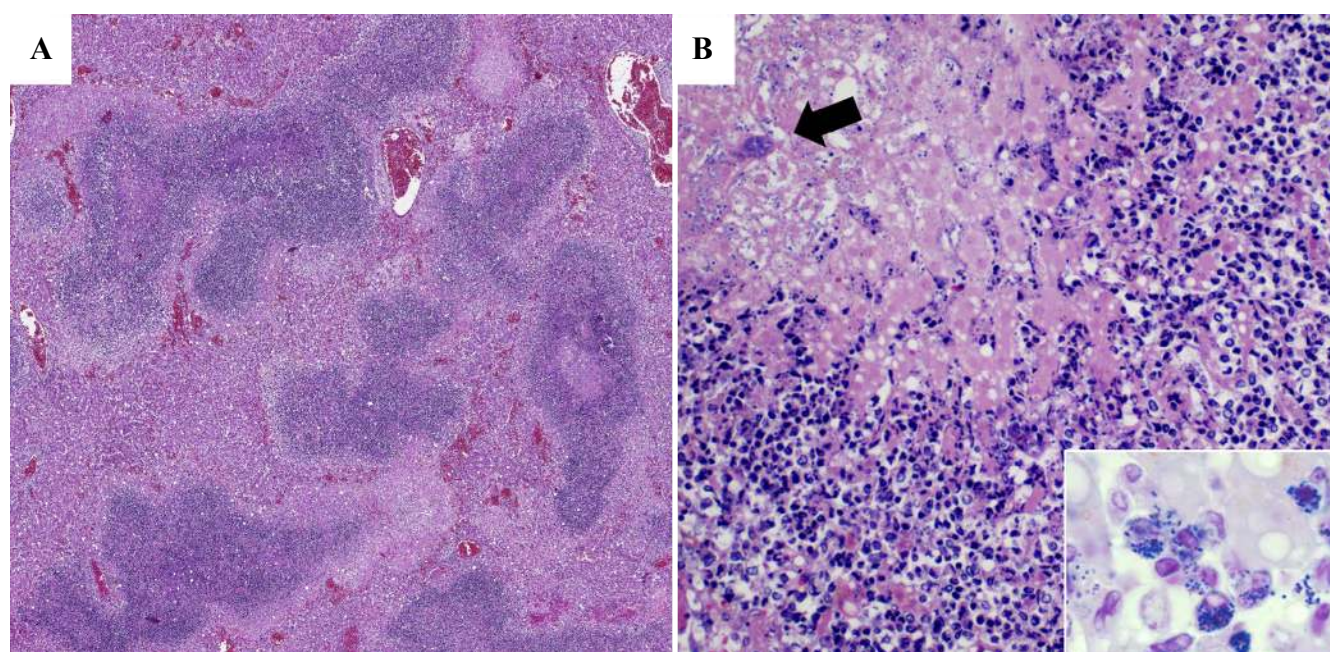


Figure 1. Random necrotizing hepatitis in a free-ranging capuchin (*Sapajus* spp.) caused by *Staphylococcus* spp. (A) Marked random multifocal to coalescent areas of necrosis with inflammatory infiltrate, liver, HE, 50x. (B) Marked inflammation with abundant neutrophilic infiltrate and myriad of Gram-positive cocci (down right, Gram stain, 1000x) forming colonies (arrow), liver, HE, 200x.

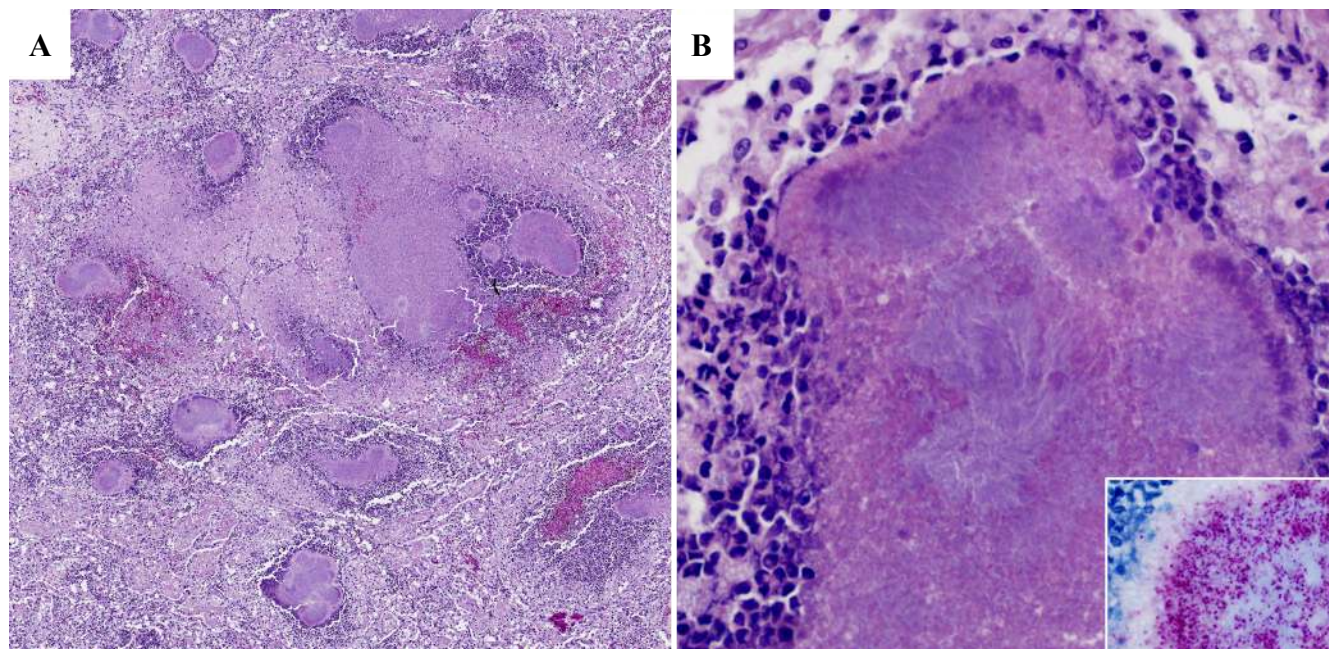


Figure 2. Necrotizing bronchopneumonia with Splendore-Hoeppli reaction in a free-ranging marmoset (*Callithrix* spp.) caused by *Streptococcus* spp. (A) Marked diffuse bronchioalveolar septal thickening and necrosis, lung, HE, 50x. (B) Splendore-Hoeppli reaction with myriad of intralésionais cocci (down right, anti-*Streptococcus* immunohistochemistry, Permanent Red, 400x) associated with neutrophilic inflammation, lung, HE, 400x.

Enterobacteriaceae and other Gram-negative bacilli and coccobacilli

Salmonella enterica is a Gram-negative bacillus that causes salmonellosis, a zoonotic disease, usually asymptomatic for NWP, but responsible for sporadic outbreaks in captive primates (217). In cases of symptomatic infection, affected animals usually progress rapidly to death (116). The main clinical sign is watery to bloody diarrhea and histopathology shows necrotizing and suppurative enterocolitis (Fig. 3) with sepsis and systemic dissemination of the bacteria, often causing a suppurative to pyogranulomatous hepatitis and splenitis (116, 217). The serovars frequently identified in NHP are Enteritidis and Typhimurium (116). In wildlife, this bacterium is rarely described with one single report of *Salmonella*-induced enterocolitis in a free-ranging howler monkey (55). Usually, this organism is identified by histopathology, with Gram stain, and by IHC, being usually confirmed by bacterial culture and/or by DNA amplification and sequencing (55).

Escherichia coli is a Gram-negative bacillus associated with self-limiting to lethal diarrhea in NHP colonies, mainly of marmosets and tamarins (77, 111, 116, 211). The disease can be caused by enteropathogenic (EPEC), enterotoxigenic (ETEC), enterohemorrhagic (EHEC), enteroinvasive (EIEC) and diffusely adherent (DAEC) serotypes (116). However, EPEC is the most reported serotype in enzootic infections of captive NHP, frequently characterized by acute hemorrhagic diarrhea (77, 111, 116, 211).

Histopathology shows neutrophilic colitis with hyperplasia of the intestinal crypt epithelium, increased

mitotic index, loss of goblet cells, crypt abscesses and Gram-negative rods attached to the apical portion of the mucosal lining epithelium (111, 116). The identification of *E. coli* adhered to the intestinal epithelium is an important feature for the confirmation of the disease and can be performed by routine histological stains, hematoxylin and eosin, Gram stain and toluidine blue, or by electron microscopy (105).

In addition to enterocolitis, *E. coli* has been described as an important cause of septicemia for captive NWP (55). *E. coli* was identified as a cause of enterocolitis in one free-ranging howler monkey and was also associated with suppurative bronchopneumonia in free-ranging animals from this species (55). We also have an unpublished case of *E. coli* infection in an adult male free-ranging marmoset (*Callithrix* spp.) causing a fibrinonecrotic and suppurative bronchopneumonia with bacteremia (Fig. 4). This animal was found dead in the Metropolitan region of Rio de Janeiro State, and the diagnose was performed by histopathology, IHC, and PCR (146).

Diagnosis is performed by bacterial culture, histopathology and IHC (55, 116). Molecular techniques, such as PCR of fecal samples, are important to monitoring the disease in a given population, since bacterial culture can underestimate the number of carrier animals (111). Importantly, *E. coli* is a commensal bacterium of digestive tract from healthy NHP, therefore, it is extremely important to perform phylogenetic typification to assess the pathogenicity in cases suspected of pathogenic *E. coli* infection (118). Additionally, Vásquez-Aguilar et al. (214) detected antimicrobial resistance genes in *E. coli* isolates from free-ranging howler monkeys (*A. pigra*) and domestic animals (cattle, sheep,

and horses) in a Mexican Fragmented Rainforest, confirming that wild animals exposed to anthropized environment are also susceptible to resistant bacteria, enhancing the impact of indiscriminate use of antibiotics.

Shigella spp. are Gram-negative bacillus that causes shigellosis, a severe zoonotic disease of the large intestine (cecum and colon) of all primates, including humans, but which is rarely described in NWP (110). Four serogroups are identified: *Shigella flexneri*, *Shigella dysenteriae*, *Shigella boydii*, and *Shigella sonnei* (116). Microscopically, infection

is usually associated with ulcerative and necrotizing colitis/typhlitis with crypt abscesses, herniation of intestinal crypts into the intestine-associated lymphoid tissue, and exudation of neutrophils on the mucosal surface (116). In OWP, *S. flexneri* is also associated with a linear ulcerative gingival syndrome (116), with no reports in NWP. The diagnosis is confirmed through bacterial culture (116), but it is usually difficult to distinguish from *E. coli* isolates, so the use of PCR becomes essential for accurate identification of this bacterium (110). There are no reports of *Shigella* infection in free-ranging NWP.

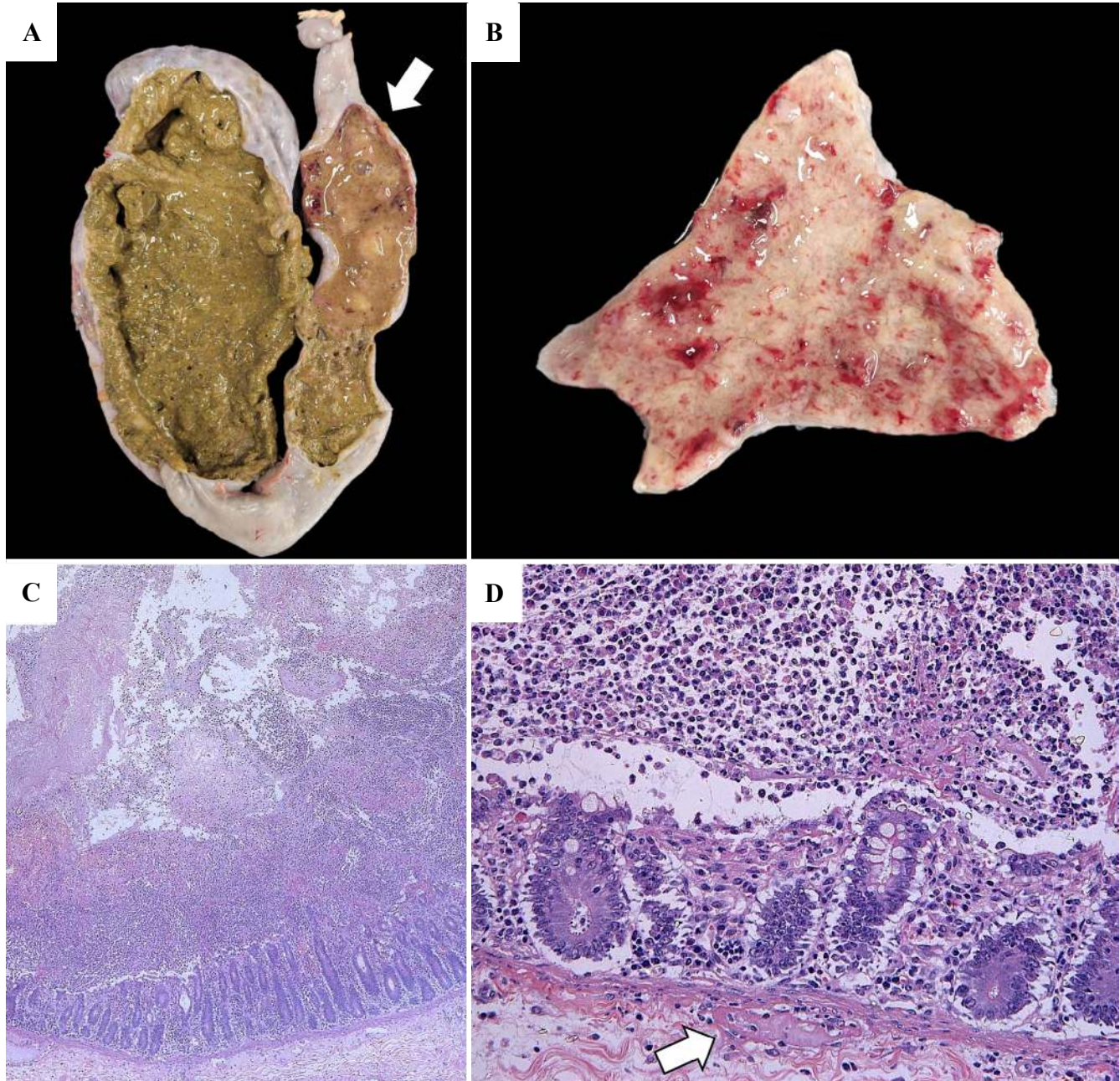


Figure 3. Fibrinonecrotic colitis in a captive brown howler monkey (*Alouatta guariba clamitans*) caused by *Salmonella enterica*. (A) Large intestine with mucous and bloody content. (B) Large intestine mucosa diffusely thick and pale with multifocal to coalescent areas of hemorrhage, necrosis, and fibrin deposition. (C, D) Marked diffuse neutrophilic infiltrate at mucosa, with fibrin deposition, erosion and vascular necrosis with thrombosis (arrow), colon, HE, 50x (C), 200x (D).

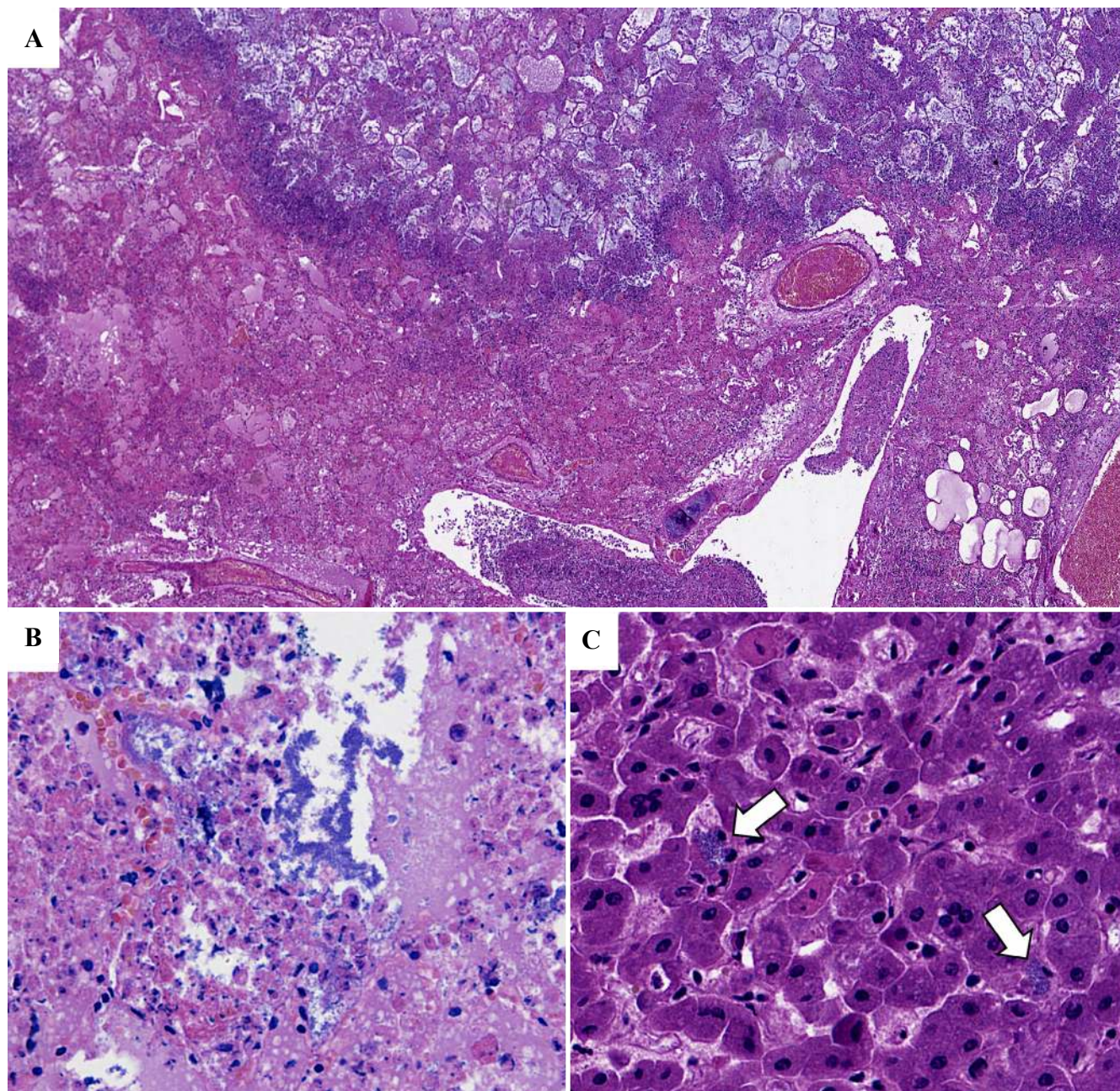


Figure 4. Fibrinonecrotic bronchopneumonia in a free-ranging marmoset (*Callithrix* spp.) caused by *Escherichia coli*. (A, B) Marked diffuse bronchointerstitial neutrophilic inflammation and necrosis with marked fibrin deposition and myriad of rods forming big colonies, lung, HE, 50x (A), 400x (B). Sinusoids with myriad of free and intra-histiocytic rods (arrows), interpreted as bacteremia, liver, HE, 400x.

Yersinia enterocolitica and *Yersinia pseudotuberculosis* are Gram-negative coccobacilli that cause yersiniosis, a disease frequently reported causing outbreaks in NWP colonies with high morbidity and mortality (15, 116, 140). Wild birds and rodents are the reservoir and the source of infection, transmitting the bacteria through its feces, contaminating the water and food offered to these animals in captivity (116, 217). Grossly, there is an ulcerative enterocolitis with multiple small yellowish nodules at liver and spleen, microscopically characterized by necro-suppurative enteritis, hepatitis

and splenitis, with big intralesional colonies (116, 140). Diagnostic can be performed by histopathology and IHC, confirmed by bacterial culture (15, 116, 140). Co-infection with *E. coli* was recently described in nine wild caught marmosets (*Callithrix penicillata*) presenting diarrhea and 100% of lethality (95). Although this disease is high relevant in captive NWP, the importance in free-ranging animals is unknown, with no reports in the literature.

Klebsiella pneumoniae is an encapsulated Gram-negative bacillus implicated in outbreaks in captive NWP, especially in marmosets, howler monkeys and tamarins, with

lethal course, causing bacteremia with marked sinusoidal leukocytosis, suppurative splenitis, interstitial pneumonia, necrotizing adrenalitis, necrotizing myocarditis, peritonitis, and neutrophilic enteritis (11, 72, 74, 116, 160). Intralesional and intravascular small bacilli surrounded by a clear halo can be observed. Transmission occurs via oral or respiratory secretions and the disease is associated with stress and debilitating co-infections, being infants and juveniles more susceptible (116). Diagnoses is performed by bacterial culture, IHC and PCR (72, 116, 160), being important to identify the phenotype at bacterial culture, once hypermucoviscosity (HMV) phenotype are highly pathogenic and infective (11, 72, 116).

Although it seems to be an important cause of sepsis and death in captive NWP, the incidence and importance of *K. pneumoniae* in free-ranging animals is unknown. One free-ranging tamarin from a translocation program developed a *Klebsiella*-induced pneumonia and septicemia during the 30-days-quarantine, when it was housed for clinical examination with other tamarins from the same group. In this case, the animal was prior negative for *Klebsiella* in fecal and blood samples, but another healthy contact tamarin was positive, being considered the reservoir and source of the infection (24).

Pasteurella spp. are Gram-negative bacillus responsible for necro-suppurative bronchopneumonia in captive NWP with reports of *Pasteurella multocida* co-infection with *K. pneumoniae* in some of these cases (116). *Pasteurella* spp. were also identified causing suppurative bronchopneumonia in free-ranging NWP with history of dog attack (55, 195). Interestingly, *Pasteurella* sp., especially *Pasteurella canis*, is a commensal bacterium from the oral cavity of healthy dogs, being also reported in humans involved with dog accidents, such as biting and scratching (18). Diagnosis can be performed by bacterial culture and PCR for speciation (55, 195).

Pseudomonas spp. are Gram-negative bacillus

associated with septicemia in humans and animals, being *Pseudomonas aeruginosa* the most pathogenic strain described. In NWP, *Pseudomonas simae* was reported as cause of death of a captive marmoset (*Callithrix geoffroyi*) causing an acute bronchopneumonia and bacteremia (215). In this case, in addition to bacterial culture, PCR and DNA sequencing have been performed to have a phylogenetic characterization of the isolate. Menezes-Costa et al. (124) detected by blood PCR four phylotypes of *Pseudomonas* spp. in free-ranging howler monkeys and capuchins from different regions of Brazil, confirming the circulation of this bacterium in a wild population.

Although *Pseudomonas* spp. are poorly described in captive or free-ranging NWP, it is one of the differential diagnoses for septicemia in primates. It has been isolated from a muscle abscess in one of our unpublished cases of electrocution in a free-ranging Geoffroyi marmoset (*C. geoffroyi*) (Fig. 5). This animal was an adult female marmoset that was rescue from an urbanized area in the State of Espírito Santo after being electrocuted. One week after the rescue, the animal was hospitalized presenting apathy and severe necrosis of righ forelimb and hindlimb, dying minutes later, before any treatment could be attempted. The diagnosis was based on necropsy and histopathology, with the identification of *Pseudomonas* spp. by bacterial culture of samples from the muscular abscess in the forelimb.

Bordetella bronchiseptica is a Gram-negative coccobacillus that causes bordetellosis, a respiratory disease commonly reported in NWP colonies (116, 217). *B. bronchiseptica* has an affinity to the respiratory tract, attaching to the ciliary epithelium of the airways, causing a necro-suppurative bronchopneumonia that is usually triggered by a stressful event (116). Diagnosis can be confirmed by bacterial culture and PCR. Although it is very prevalent in captive NWP, the frequency and impact in free-ranging population have not been reported.

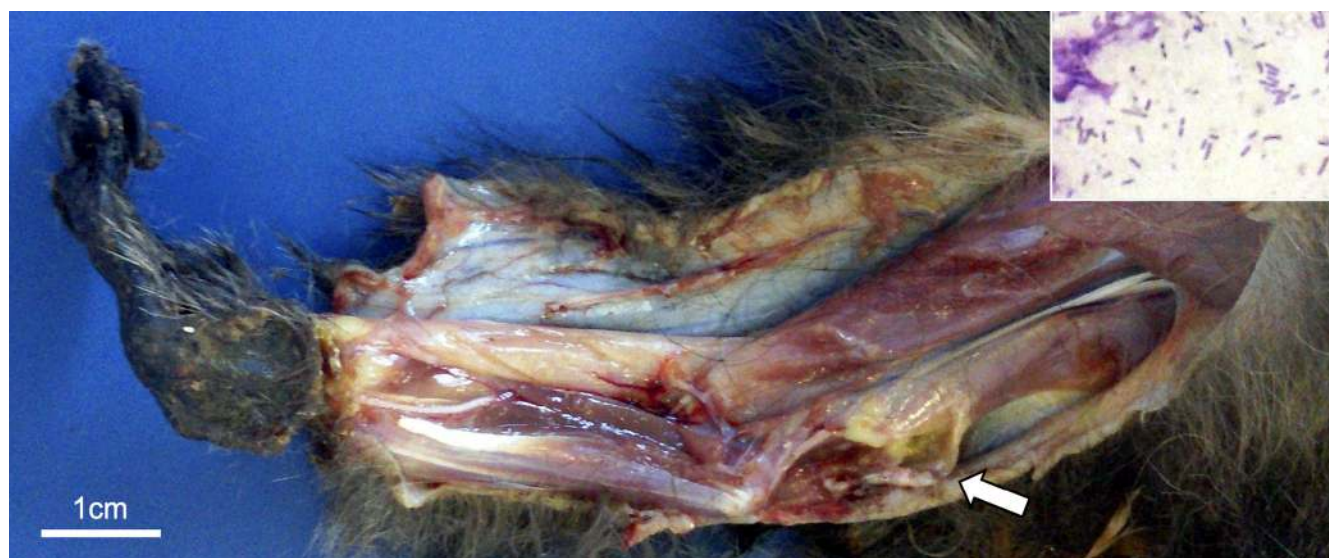

Figure 5. Infection by *Pseudomonas* spp. in a free-ranging Geoffroyi marmoset (*Callithrix geoffroyi*) with history of electrocussion. Muscle abscess (arrow) with myriad of Gram-negative rods (Top right, Gram stain, 1000x). Grossly, dry gangrene of the extremity of the right forelimb was also observed, with necrosis and degeneration of the adjacent musculature, due to electrocussion.

Anaerobic bacteria

Clostridioides difficile (previously known as *Clostridium difficile*) is a Gram-positive anaerobic bacillus from commensal microbiota of healthy mammals, including NWP, being considered an opportunistic pathogen. The disease occurs when a disruption of the microbiota happens and the *C. difficile* starts to overgrow, producing high concentrations of cytokine, responsible to induce a severe pseudomembranous colitis (116). Usually, histopathology shows multifocal areas of fibrin and necrotic debris erupting from the intestinal mucosa, forming a characteristic “volcano” aspect, evolving to a diffuse pattern with a thick layer of fibrin, mucus, cell debris and neutrophils (13). However, in a case of lethal acute diarrhea associated with *C. difficile* toxin A and B in a buffy-tufted-ear marmoset (*Callithrix aurita*) it was observed just a mild neutrophilic colitis (30), warning that even with mild lesions, *C. difficile* must be considered in the differential diagnosis of diarrhea cases in NWP.

Stress, hospitalization, and prolonged use of antibiotics are the main predisposing factors (13, 85, 116). Although there is no report of the disease in free-ranging NWP, it could potentially happen in wildlife, especially in free-ranging animals submitted to a high anthropogenic environment and translocation programs. The diagnose of *C. difficile* can be tricky, once the identification of the bacteria in IHC or bacterial culture is not enough to confirm that the agent is causing the disease. *C. difficile* toxins, such as CDT, TcdA, and TcdB, must be identified by cytokine neutralization assays, enzyme-linked immunosorbent assay (ELISA), or PCR, to establish a cause-effect association (13, 85).

Clostridium tetani is an obligated anaerobic Gram-positive spore-forming bacillus that causes tetanus, a disease that affect must of mammal species. OWP and NWP are susceptible to this disease, developing characteristic clinical signs such as triad of trismus, opisthotonos and status epilepticus. Diagnosis is based on history and clinical signs, but to confirm is necessary to identify the neurotoxin tetanospasmin, produced by *C. tetani* (116, 217). Once this bacterium is found in the soil and infection occurs by the contamination of skin wounds, it can potentially happen in free-ranging animals, even not being described yet. Importantly, pathological findings in this case are non-specific.

Clostridium botulinum is an anaerobic Gram-positive spore-forming bacillus that causes botulism by producing a neurotoxin (A, B, C, D, E, F, and G) in the host organism that will cause a flaccid paralysis by inhibition of acetylcholine release from the presynaptic motor neuron terminal (163). Diagnosis is performed based on clinical signs and confirmed by the identification of the neurotoxin (163). Although botulism is a rarely reported disease in NHP, there are few reports of *C. botulinum* causing outbreaks in captive OWP and NWP (96, 158). Silva et al. (197) described an outbreak of botulism in a rural area of Minas Gerais, Brazil, affecting chickens, dogs and one free-ranging marmoset (*C. penicillata*). In this outbreak

all the species involved were found in the same region presenting flaccid paralysis progressing to death, and type C neurotoxin was identified in the stomach content and serum of two chickens and one dog by mouse neutralization test. Pathological findings are absent or non-specific (163).

Spirochete bacteria

Leptospira spp. are important zoonotic bacteria responsible for leptospirosis. It is uncommon to observe natural infections in captive NWP (116), and it have been rarely described in free-ranging animals, with studies focusing mainly in serological and molecular evidence (9, 23, 128, 129). In two serological study of a free-ranging NWP population none of the animals showed positive serology anti-*Leptospira* by microagglutination test (MAT): the first study evaluated anti-*Leptospira* serology in 20 howler-monkeys (*A. caraya*) and 48 marmosets (*C. penicillata*) (128); and second in 48 capuchins (*S. flavius*) (23). Also, in another study with 593 free-ranging tamarins (*L. chrysomelas*) using MAT, only two tamarins were positive (129). Contrasting with the other previous studies, Aliaga-Samanez et al. (9) found a high prevalence (43.3% to 61.5%) of *Leptospira* sp. antibodies in asymptomatic free-ranging tamarins (*L. weddelli* and *S. imperator*) from Peru. This high prevalence was also observed in a free-ranging capuchin (*S. apella nigrurus*) population from São Paulo, Brazil, with 78% (39/50) of reactivity by MAT (69). Together, these data suggest a difference of susceptibility and exposure between those studied species and confirms that *Leptospira* spp. circulate in the wild NWP population.

There are only two reported cases of leptospirosis-induced death in a free-ranging NWP, one in a howler monkey (*Alouatta guariba*) from Rio Grande do Sul, Brazil (55), and the other one in a black-tufted marmoset (*C. penicillata*) from Brasilia, Brazil (224). Pathological findings reported by Wilson et al. (224) were icterus, interstitial pneumonia with hemorrhage, edema, and fibrin exudation, interstitial nephritis with tubular degeneration and necrosis and hepatocyte cord dissociation and necrosis with sinusoid leukocytosis. Diagnosis in this case was based on observation of spirochetes through Warthin-Starling stain, specific anti-*Leptospira* IHC and real-time PCR targeting the lipL32 gene. Importantly, in this case, a great number of spirochetes were observed in the renal tubules, raising the possibility that marmosets may be important in the transmission of this zoonosis, especially because marmosets are well-adapted in urban environments increasing human-marmoset interactions (224).

Borrelia sp. is another spirochete that causes disease in humans and animals with an important zoonotic impact. In humans it is usually associated with Lyme disease and Brazilian Lyme-like disease, caused mainly by *Borrelia burgdorferi*, and transmitted to humans by ticks. NHP are used as experimental models for Lyme disease, reproducing all the three phases of the infection: localized, disseminated, and

persistent; and developing persistent characteristic lesions, such as myocarditis (27, 43). *B. burgdorferi* was identified by PCR in 16% (32/200) free-ranging golden-headed lion tamarin (*L. chrysomelas*) from Rio de Janeiro, Brazil, confirming that this bacterium circulates in this region and suggesting that these tamarins may play a role in transmission of this pathogen to other animals or human beings (179).

Helicobacter pylori is a spiral bacterium (spirochete), commensal of the stomach, and associated with mild to moderate proliferative and erosive gastritis in immunosuppressed patients. Silver stain, such as Warthin-Starry impregnation method, and IHC are used to identify the bacteria in the tissue (116). Although, *Helicobacter* spp. have been naturally identified in the stomach of marmosets, no association with specific pathological findings was observed (122, 190). There is no information on *Helicobacter* spp. in free-ranging NWP.

Mycobacterium tuberculosis complex (MTBC)

MTBC is a group of *Mycobacterium* species, such as *Mycobacterium tuberculosis*, *Mycobacterium africanum*, *Mycobacterium bovis*, *Mycobacterium canettii*, and *Mycobacterium microti*, with the potential to cause tuberculosis, a zoonotic disease, in humans and other mammals. In captive primates this infection is usually associated with the proximity of these animals with humans, being considered an important anthrozoosis (54, 116). In NHP this disease is mainly associated with *M. tuberculosis* and, although well described in captive primates, NWP seems to be more resistant to the infection, being uncommon in captive NWP and considered non-existent in free-ranging NWP with no human contact (116, 131). Rosenbaum et al. (171) found molecular evidence of *M. tuberculosis* complex in NWP, mainly from Atelidae and Cebidae family, from different captive origin (pet, market, and zoological animals) in Peru. In that study, oral swabs were obtained from 220 individuals, with 13.6% of positive DNA amplification. Market origin had 5% (5/72) of positive animals. This group was represented by animals that were capture in wildlife and sold in the illegal market, being the closest reference of prevalence in free-ranging NWP described in the literature. In the contrast the prevalence in zoo primates was 22% (22/100), in agreement with the notion that this disease is highly associated with human contact.

Diagnosis is performed with necropsy and histopathology, with the identification of typical granulomas in multiples organs, but especially in the lungs, associated with variable amount of intralésional alcohol-acid resistant bacilli (54, 116). Typical tuberculosis granulomas are characterized by well-delimited nodules with a mineralized necrotic center surrounded by epithelioid macrophages, lymphocytes, plasma cells and multinucleated giant cells, usually of the Langham's-type (116). This typical presentation is often observed in OWP. However, in NWP, it is also described a poorly delimited presentation with multifocal to coalescent

granulomatous inflammation without central necrosis (54, 131). IHC and PCR can be performed to confirm the intralésional agent (54). Bacterial culture, although confirmative, must be performed in a biological safety cabinet class 3, being not always accessible. Besides MTBC, *Mycobacterium avium complex*, *M. avium paratuberculosis* and *Mycobacterium leprae* also infects captive NHP, however NWP are extremely less susceptible than OWP (116), and there are no reports of infections in free-ranging NWP.

Hemotropic bacteria

Bartonella spp. are facultative intracellular Gram-negative bacillus that infects erythrocytes and endothelial cells in a prolonged bacteremia. *Bartonella henselae* is responsible for the “cat scratch” disease, a zoonosis that has the cat as the most important reservoir and is transmitted by cat bite and scratches or by vectors (fleas or ticks). In humans it is responsible for causing endocarditis and other angioproliferative lesions, being associated to angiomas and hepatic/splenic peliosis (161). *Bartonella* spp. have been poorly described in captive and free-ranging NHP (81, 97, 153). Bonato et al. (20) investigated *Bartonella* infection in 112 free-ranging capuchins and tamarins from São Luís, Brazil, by blood quantitative PCR (qPCR), but no positive animal was found. The authors, however, believes that the negative results may be due to a low bacteremia, once the animals from the study were all asymptomatic. Also, bartonellosis was investigated by PCR, Warthin-Starry stain and IHC in two cases of hepatic peliosis in captive owl monkeys (*A. infulatus*), but no evidence of bacteria was found (204).

Mycoplasma spp. (hemoplasmas or hemotropic mycoplasmas) are bacteria that infect the surface of erythrocytes of a broad range of hosts, including primates, leading to hemolytic anemia by intra and extravascular hemolysis. Hemoplasmas have been detected in captive OWP and NWP, with new identified bacterial species, such as *Candidatus Mycoplasma kahanei* from squirrel monkeys (*Saimiri sciureus*) and *Candidatus Mycoplasma aoti* from owl monkeys (*Aotus trivirgatus*) (14, 123, 141, 184). There are some studies detecting hemoplasmas in free-ranging NWP as well (20, 44, 181).

A free-ranging howler monkey was diagnosed with *Candidatus M. kahanei*-related hemoplasma by blood PCR and presented a regenerative anemia with low red blood cell count (RBC) and high mean corpuscular volume (MCV) (181). Another study investigating 112 healthy free-ranging NWP had molecular evidence of hemoplasmas in 35.7% of the evaluated animals, being represented by capuchins, squirrel monkeys and tamarins (20). Cubilla et al. (44) detected, by blood smears cytology and blood PCR, 20% to 25% (8-10/40), respectively, of hemoplasma-infected capuchins and howler monkeys. In this study, the authors also observed that wild-borne animals were more likely to test positive than captive-born animals and howler monkeys were 45 times more likely to test positive than capuchins and marmosets, presenting mild anemia when infected.

Ehrlichia canis is an obligate intracellular Gram-negative α -proteobacterium that infects leukocytes and causes the canine monocytic ehrlichiosis, a potentially zoonotic disease that affects dogs and is transmitted by *Rhipicephalus sanguineus* bites (218). *E. canis* was detected by blood PCR in one of 19 healthy free-ranging marmosets (108). Interestingly, the genotype of the *E. canis* sequenced from this marmoset was very similar to other genotypes identified in domestic dogs, indicating the overlap of habitats between these animals.

Brucella spp.

Brucella spp. are facultative intracellular Gram-negative coccobacillus, that causes brucellosis, a recognize zoonotic disease, with high importance in public health, and a broad range of infected hosts, being the most important: *Brucella melitensis* (small ruminants), *Brucella abortus* (bovine), *Brucella suis* (swine), and *Brucella canis* (canine) (152). *Brucella* spp. gained attention in NHP after being isolated a new species, named *Brucella papionis*, from stillbirth and retained placenta of two wild-caught baboons (*Papio* sp.) (186, 221). However, studies searching for serological evidence of this bacteria in free-ranging NWP had negative results, even in regions with brucellosis endemic herds (23, 128, 164), questioning the real important of this disease for an NWP population.

Viruses

There are many well-known viruses that cause disease in captive NWP. However, most of them are not reported in wildlife or were only observe in experimental conditions (116). Viral diseases in free-ranging NWP are usually associated with outbreaks, and the main viruses described are the Herpesvirus simplex type I (HSV-I) and the yellow fever virus (YFV).

Human herpesvirus – HSV-I and II

HSV-I and II are alpha herpesvirus that have the human as primary host with high morbidity and mild or absent clinical signs. The virus is latent in the trigeminal and lumbosacral ganglia, with intermittent reactivation and viral shedding in periods of stress. In the primary host, lesions associated to viral infection consist of vesicles and ulcers on the oral (type I) or genital (type II) mucosa, sometimes associated with conjunctivitis, with rare cases of disseminated infections, usually associated with immunosuppression (116). Histopathology shows a necrotizing and ulcerative lesion with multinucleated syncytial cells on the edge and eosinophilic intranuclear viral inclusion bodies (116). OWP can also be infected, developing a similar disease observed in humans. NWP are highly susceptible and usually develops fatal disseminated disease with high morbidity and high mortality (16, 31, 40, 76, 83, 115, 187, 223). Interestingly, the NWP that survives

the outbreak develops a prolonged antibody response that last for at least four years, but do not extend to the offspring (76), indicating that these outbreaks could have a cyclic pattern.

In free-ranging NWP populations, this disease has been reported mainly in peri-urban marmosets and it is usually associated with lethal outbreaks with monkey-to-monkey transmission after the virus has been introduced by the contact with secretions of the infected human host, and neurological signs are frequently reported (21, 40, 102, 223). Pathological findings in NWP are similar to the ones described in humans, but they tend to be more severe and disseminated. Usually, is observed ulcerative and necrotizing lesions at mucocutaneous junctions with syncytial epithelial cells and nuclear viral inclusions, necro-ulcerative glossitis, and an acute marked encephalitis, characterized by mononuclear inflammation with variable amounts of neutrophils and severe necrosis, hemorrhage and vasculitis (Fig. 6) (16, 31, 40, 115, 223). Necrotizing hepatitis and conjunctivitis, although less common, is also observed (223). Nuclear inclusions are also observed in neurons and astrocytes. Although the pathological findings are very characteristic of the HSV infection, PCR, electron microscopy and IHC are usually performed to confirm the diagnosis (16, 40, 115, 223). Importantly, in a study with 16 cases of HSV in free-ranging marmosets, only HSV-type I was detected (223).

There is one single report of a possible HSV-type II transmission from an asymptomatic infected howler monkey (*A. guariba*) to a human. After being bitten by the monkey, the human patient started to present a recurrent vesicular skin lesion in the site of the bite, being isolated HSV-II from the vesicle secretion (106). Once HSV is a latent virus, it is possible that the howler monkey from this case got infected after being exposed to virus by a human source, and surprisingly did not die with the initial infection, becoming a carrier and transmitting it to a human host, in an unusual monkey-to-human transmission.

Saimiriine Herpesvirus (SaHV-1 and 2)

SaHV-1 is an alpha herpesvirus that causes a disseminated necrotizing disease in NWP and SaHV-2 is a gamma herpesvirus T-lymphotropic related to Kaposi's sarcoma-associated herpesvirus (HHV-8) (116, 220). Both viruses are enzootic in captive squirrel monkeys, considered the primary host for these viruses, therefore, infected animals are usually asymptomatic. However, there is one report associating a leukemic histiocytic sarcoma with SaHV-2 in a squirrel monkey that was also infected with *Saimiri sciureus* lymphocryptovirus 2 and Squirrel monkey retrovirus, although it is difficult to establish a correlation between viral infection and the sarcoma (22). When transmitted to another susceptible NWP, such as tamarins, owl monkeys and marmoset, SaHV will lead to a systemic and lethal disease (116,

220). SaHV-1 causes a disseminated necrotizing disease affecting skin, oral mucosa, and parenchymal organs, with syncytial cells and nuclear inclusion bodies (220); and SaHV-2 causes an acute lymphoproliferative disorder, with CD3-CD8 positive T-lymphocytes proliferation in multiple organs, including GI tract, spleen, liver and kidney and leukemia (116).

Others gammaherpesviruses have been described in NWP as well, such as herpesvirus ateles from spider monkeys and Callitrichine herpesvirus 3 (CalHV-3), that

was isolated from spontaneous lymphoma in captive marmosets (7, 121, 162). Gammaherpesvirus was also detected by blood PCR in free-ranging golden-handed tamarin (*Saguinus midas*), white-faced saki (*Pithecia pithecia*), and squirrel monkey (*S. sciureus*), all from *Lymphocryptovirus* genus (210). Those studies brought a lot of contribution describing novel herpesvirus in NWP; however, little is known about the impact of these viruses in the health of those animals and the pathological features associated with these infections.

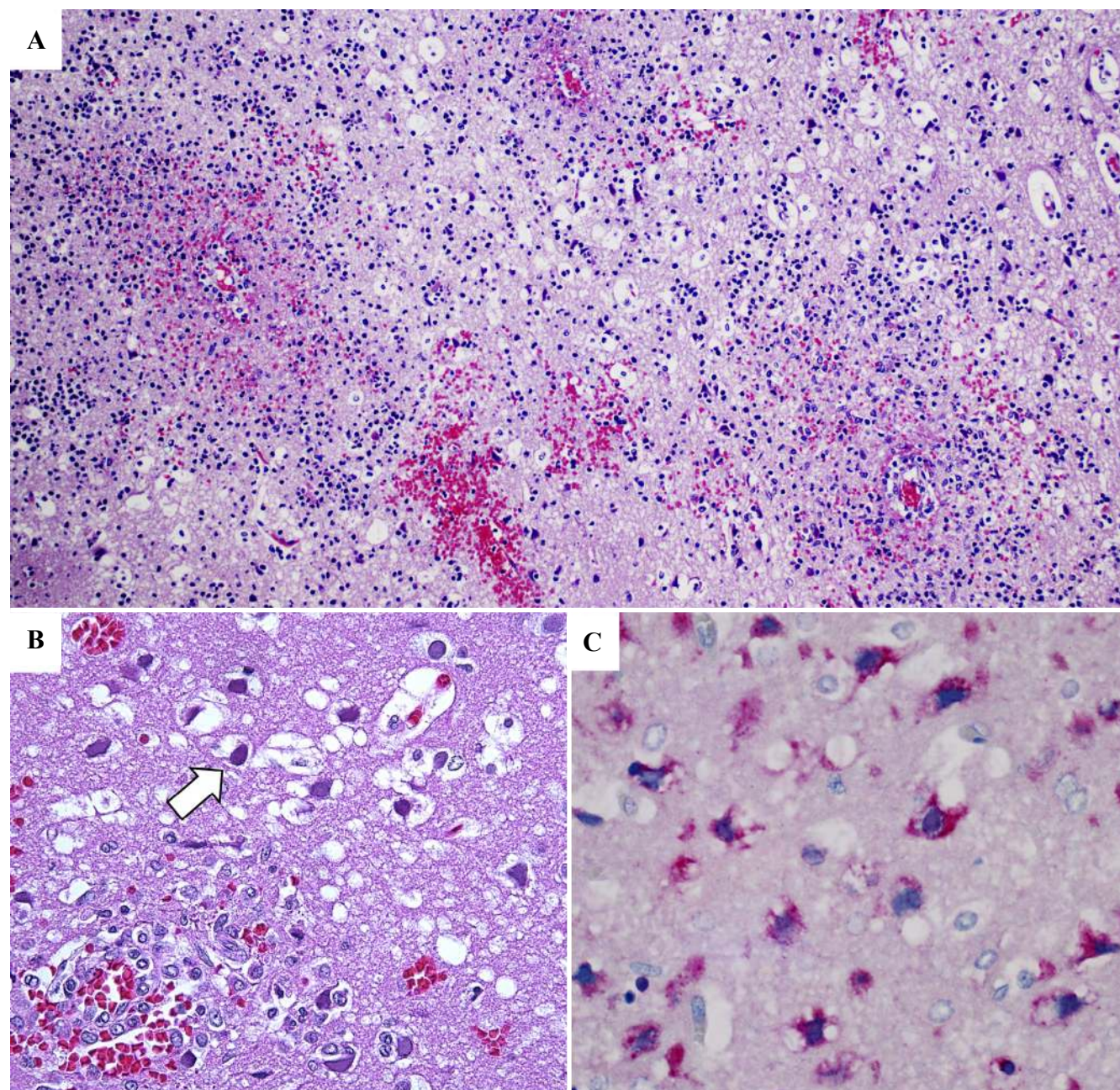


Figure 6. Encephalitis caused by *Human Herpesvirus* (HHV) in a free-ranging Geofroyi marmoset (*Callithrix geofroyi*). (A) Encephalitis was characterized by marked necrosis, hemorrhage, and vasculitis with lymphoplasmacytic infiltrate, rich in neutrophils, brain, HE, 100x (B) Multiple basophilic viral nuclear inclusions were observed in the neurons (arrow), brain, HE, 200x. (C) Neuronal intracytoplasmic immunolabeling of anti-HHV, brain, Permanent Red, 400x.

Flaviviruses

Yellow fever virus (YFV) is an arbovirus transmitted by mosquitos belonging to the genera *Sabethes* and *Haemagogus* in the sylvatic cycle, or *Aedes* in the urban cycle. This virus causes the yellow fever (YF), a disease of high importance in public health and NWP conservation. YF usually occurs as 10 years cyclic outbreaks in non-endemic regions with low vaccine coverage, and it usually starts in NWP population in the wild, extending to the adjacent human population, therefore NWPs are considered YF sentinels and important public health tools for the control and prevention of this disease (100).

The classic pathological findings of YF in NHP are jaundice with an enlarged and yellow liver characterized in histopathology by marked midzonal to massive hepatocellular necrosis with apoptotic hepatocytes (Councilman-Rocha Lima bodies), steatosis, and hemorrhage (Fig. 7) (59, 61, 93, 116). Official diagnosis is performed by liver histopathological evaluation with intracytoplasmic antigen immunolabeling in hepatocytes by IHC, confirmed by RT-qPCR (61, 68). Viral isolation and immunofluorescence can also be performed but is unusual (10).

Santos et al. (180) analyzed the histopathological findings of 57 positive NWP, including howler monkeys, marmosets, and capuchins. In this study the authors identified that there were differences in the pattern of liver injury of YFV-infected among different species of neotropical primates, being the howler monkey, the genus with the most aggressive pattern, characterized by the classic YFV histological features (180). In contrast, infected marmosets had unspecific findings, such as mild inflammatory infiltrate and occasional glycogenosis. This anatomopathological profile is compatible with the viral load identified in the tissues of those animals, where howler monkeys have a high viral load, proving to be good indicators of the disease, capuchins have a median viral load and marmosets have a low viral load (61). Titi-monkeys (*Callicebus* spp.) is also highly susceptible to YFV, developing a massive necrotizing hepatitis with high viral loads (59). Importantly, this high susceptibility of YFV in howler monkeys reflects directly in its wild population that drastically decreases during YF outbreaks (135).

The last outbreak happened in the Brazilian Southeast region, started by the end of 2016, and finished in 2019 and was considered the most severe over the past 80 years, with introduction of the virus in regions that it has never been reported before (68, 82, 196). During this period there were more than 2,000 human cases with approximately 30% of lethality (68). The wild population of NWP was extremally impacted by YFV, with thousands of positive lethal cases and an important reduction in its density, directly affecting conservation programs of species already threatened (50, 207). During this outbreak was also detected by RT-qPCR YFV-positive marmosets from urbanized regions of São Paulo, Brazil, increasing concern about the development of the urban cycle of the disease,

which has not occurred in Brazil since 1942 (46, 60). In one non-autochthonous case the marmoset, raised as pet, presented clinical signs, such as fever, vomit, diarrhea, jaundice, difficulty in walking and loss of movement of pelvic members, for nine days before death (60). Considering this extremely fearful scenario, efforts have been made to use the human YF vaccine (17DD) in captive and free-living NWPs, with promising results observed in captive howler monkeys (62).

Zika virus (ZIKV) was also investigate in free-ranging NWP from Brazil, and there was evidence of viral infection by RT-qPCR in marmosets and capuchins from peri-urban regions during YF outbreak (57, 209), suggesting that these species could play a role as a sylvatic reservoir of ZIKV, contributing to the maintenance of this virus in the environment (75). Histopathology from 16 of the 32 positive animals revealed only nonspecific findings, such as pneumonia, cholangiohepatitis, splenic lymphoid reactive hyperplasia, interstitial nephritis, and myocarditis (209). Squirrel monkeys, marmosets, and owl monkeys have been used as experimental models for ZIKV infections, being susceptible to the disease, with significant viremia and reproducing the congenital abnormalities and abortions commonly observed in humans (8).

Other flaviviruses have being investigated in wild NWP populations (35, 39, 51, 103, 134, 165, 205, 209). NWP are susceptible to most of flavivirus infections with human and veterinary importance in experimental conditions, being used as models to study this disease (8, 116).

However, little is known about the importance of the NWP as a reservoir of those viruses in wildlife and the real impact of these diseases in natural infections. Studies with NWP population from Costa Rica and Argentina observed molecular evidence and neutralizing antibodies for dengue virus (DENV), Saint Louis encephalitis virus (SLEV) and West Nile virus (WNV) in asymptomatic howler monkeys (35, 39, 51, 134). DENV was also identified in free-ranging capuchins and squirrel monkeys from Costa Rica (35, 51) and there is one report of positive serology for Equine eastern encephalitis virus (EEEV) in on spider monkey from Bolivia (84). At Brazil, SLEV was observed in one free-ranging howler monkey and eight capuchins from Porto Rico County region, between the states of Paraná and Mato Grosso do Sul (205). Ilheus virus (ILHV) and Bussuquara virus (BSQV) was also detected in one free-ranging howler monkey from Argentina (134), although these two viruses have less importance in human medicine.

Rabies virus (RABV)

The rabies virus (RABV) is a Lyssavirus that causes rabies, a zoonosis with 100% of lethality that infects a wide range of mammal hosts and is transmitted by infected animal saliva. In Brazil RABV has been controlled by preventive vaccination programs focusing on domestic animals. However, currently, wild animals, especially vampire

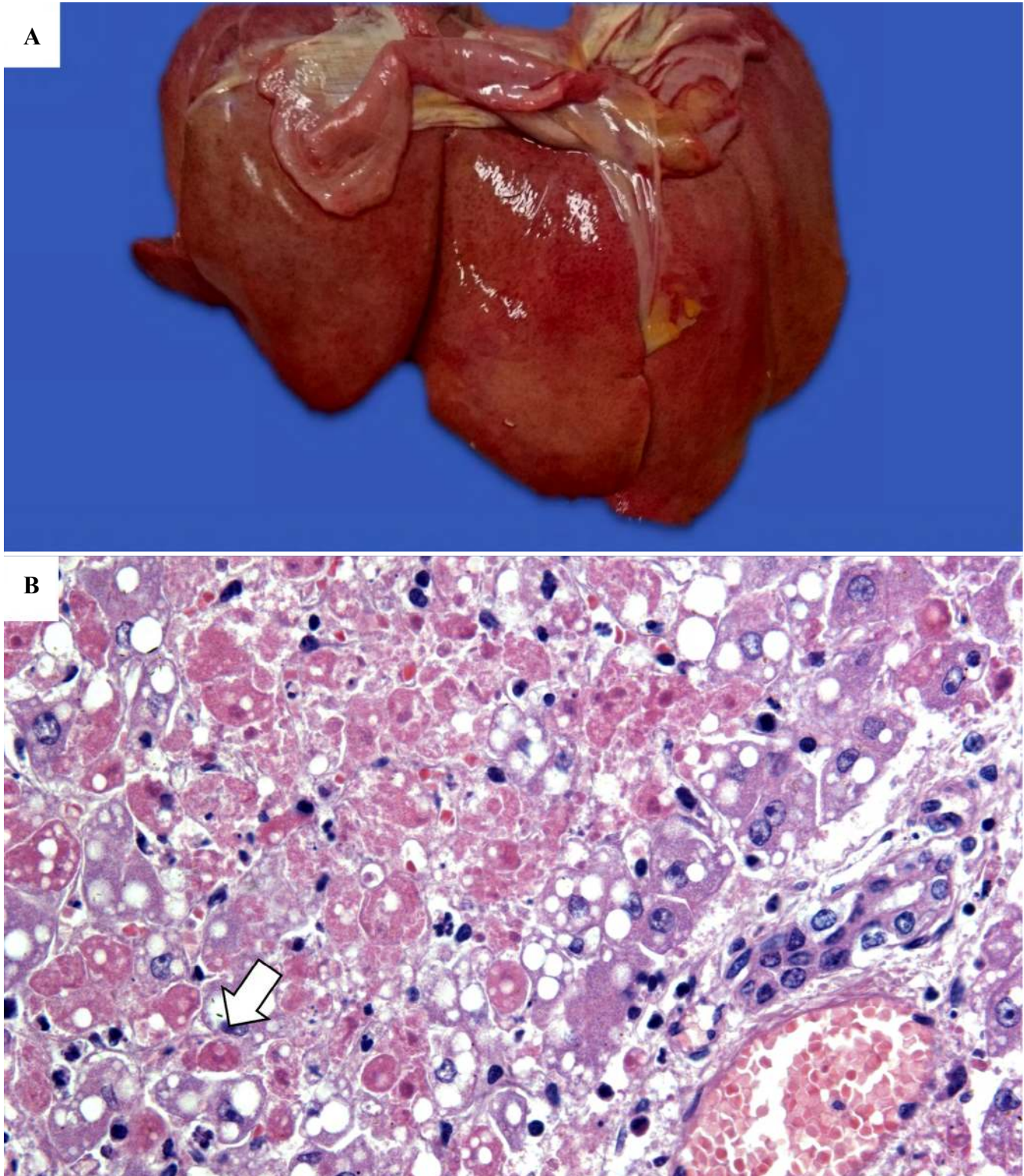


Figure 7. Yellow fever virus (YFV) infection in free-ranging howler monkey (*Alouatta* spp.). (A) Grossly, the liver is enlarged, diffusely yellowish, with multiple foci of hemorrhage (Cortesy of Dr. Fabiana Pizzolato de Lucena – Instituto Municipal de Medicina Veterinária Jorge Vaitsman, Rio de Janeiro, Brazil). (B) Marked mediozonal hepatic necrosis, with apoptotic hepatocytes (namely *Councilman-Rocha Lima* bodies - arrow), steatosis of de adjacent hepatocytes and minimal lymphoplasmacytic infiltrate, liver, HE, 400x (Cortesy of Dr. Daniel Oliveira dos Santos – Universidade Federal de Minas Gerais, Belo Horizonte, Brazil).

bats (*Desmodus rotundus*), are the main source of human infections. The role of NWP in the rabies cycle increased in the past years, mainly associated wild populations of common marmoset (*C. jacchus*) from Brazilian Northeast and Southeast regions, with 91 human exposures to infected common marmoset in the past 12 years (2008-2020) (19, 58, 88, 107, 136). Interestingly, outbreaks of RABV were initially concentrated in the states of Ceará and Pernambuco (up to 2012) but now extended to other states, such as Piauí (since 2013), Bahia (2017), and Rio de Janeiro (2019) (19).

A juvenile infected marmoset that died with neurological signs was recently reported in urbanized area from Niterói, Brazil (136). In this case the sequenced viral DNA showed characteristic of hematophagous bats *Desmodus rotundus* RABV strain (AgV3), similar to the one detected in the cases from Bahia. *C. jacchus* antigenic RABV strain was also identified in 20 reported cases from the Brazilian Northeast (19). Capuchins (*Sapajus* sp.), although less frequent than marmosets, were also identified as a potential reservoir for RABV (107) with a confirmed symptomatic lethal case (86). In this symptomatic case, the capuchin bit a horse and had an aggressive and isolated behavior. The phylogenetic analysis from this case also showed a viral strain Chiroptera-related (86).

Classical pathological finding is the non-suppurative encephalitis with round intracytoplasmic eosinophilic inclusion bodies (Negri-bodies) observed mainly in neurons including Purkinje cells (116). Official diagnosis is performed by immunofluorescence and mouse inoculation test, but histopathology is highly indicative of the disease (136).

Parvoviruses

Parvoviral infections in NHP have been poorly described in free-ranging and captive OWP (5, 189, 200). Its relevance and role as a zoonotic agent in NWP is poorly known, especially in a wild environment. Chaves et al. (34) investigated by blood PCR the prevalence of three parvovirus groups (Bocaparvovirus-HBoV, Erythroparvovirus-B19 and Tetraparvovirus-PARV4) in captive and free-ranging howler monkeys (*Alouatta palliata*), white-face monkeys (*Cebus imitator*), spider monkeys (*Ateles geoffroyi*) and squirrel monkeys (*Saimiri oerstedii*) from Central America for 15 years. In this study they found evidence of PARV4 infection, both in captive and free-ranging animals, in howler monkeys, capuchins and spider monkeys. HBoV and B19 were identified only in howler monkeys and capuchins, both from wildlife. The authors discussed that the identification of these viruses in the blood could indicate an active infection with viremia and the similarity between the human and NWP strains from these cases may indicate a cross-species transmission with a zoonotic potential (34).

In humans PARV4 is responsible for influenza-like symptoms, encephalitis, transient rash, hepatitis, and fetal hydrops; HBoV is also found in the respiratory

tract, being associated respiratory diseases and B19 is a common cause of myocarditis, being also responsible for arthritis, glomerulonephritis and myelosuppression leading to anemia (34). In OWP is described a macaque parvovirus (erythroparvovirus) that is also associated with anemia with identification of intranuclear inclusions in erythroid precursors in bone marrow (116).

Simian foamy virus (SFV)

SFV are a complex zoonotic exogenous retrovirus that naturally infects OWP and NWP, with occasional reports in humans that have close contact with these primates (138, 139, 159, 178). It has been recently reported in free-ranging NWP, being the only known exogenous retrovirus naturally infecting this group and it is apparently non-pathogenic (66, 126, 137, 159, 178), although co-infections with simian immunodeficient virus (SIV) accelerated SIV immunodeficiency-induced death (159, 178). SFV is transmitted through bites and grooming and is latent in red blood cells. It is believed that SFV primary infection occurs in blood and migratory cells, such as macrophages or leukocytes, carrying the virus to the basal epithelium of oropharyngeal tissues, with subsequent replication in differentiated epithelial cells (178). T lymphocyte differentiation and monocyte activation was observed in humans chronically infected with SFV (65).

In captive NWP the prevalence ranges from 23% to 61%, being detected by serology and molecular evaluation (139; 178). SFV was detected in 34.8% (32/92) recently wild-caught tamarins from Rio de Janeiro, Brazil, by qPCR of saliva, with similar prevalence between sex and age (126). Importantly, prevalence increased in animals with more than seven months in captivity. This same profile was observed in NWP from Peru, where captive animals had a prevalence of 47%, contrasting with 19% in free-ranging animals (66). Two distinct lineages of SFV co-circulating in this groups of tamarins, SFV1cm-1, known as infective for Cebidae family, and SFV1cm-2, infective for capuchins (*Sapajus xanthosternos*) and marmosets (*C. jacchus*) (126).

Adenoviruses (AdV)

AdV are DNA viruses that infect most vertebrate animals, including humans and NHP. AdV infections in NWP have been described since 1970, when it was first detected by serology in captive squirrel monkeys and owl monkeys. Since then, this virus has been associated with asymptomatic to fatal infections, dependent of age and immunological status (36, 167). Although AdV is usually specie-specific, there are reports of cross-infection between different NHP species and even between NHP and humans, being considered a zoonotic pathogen (36, 225). Importantly, free-ranging and captive marmosets and capuchins also showed neutralizing antibodies for human AdV in Brazil (56) and AdV was detected by PCR in 17.9% (12/67) fecal samples of free-ranging howler monkeys (*Alouatta pigra*)

from Mexico (12). Pathological findings may be systemic with necrotizing lesions in the liver, intestine, pancreas, and spleen, but interstitial pneumonia is the main feature observed in NWP, causing fulminant respiratory outbreaks with high morbidity and lethality (36, 167). Intranuclear inclusion bodies can be observed in epithelial cells present in the borders of the necrotizing lesions (167). AdV is eliminated in the feces. Therefore, PCR with template DNA extracted from fecal samples can be a good tool to detect a viral infection in primate colonies (167).

Hepatitis A virus (HAV)

HAV was investigated by serology in 419 free-ranging and captive NWP from Brazilian Southeast region, and the results showed positive serology only in captive animals with a frequency of 5.2% (188), contrasting with the high frequency of 22% to 37% observed in free-ranging OWP (26, 42). In a free-ranging population of howler monkeys and capuchins was observed a similar prevalence of anti-A hepatitis antibodies (4.5% - 5/107), assessed by ELISA, and detected exclusively in capuchins (206). HAV is a picornavirus, RNA that is transmitted by fecal-oral route and has the primates as the only natural host.

Clinical manifestations of symptomatic HAV infection in humans vary from mild, anicteric illness to fulminant hepatitis (63). Naturally and experimental infections are reported in OWP and NWP, being described natural disease in owl monkeys, marmosets, and tamarins (45). Histopathology of the liver from infected marmosets and tamarins showed hepatitis with hepatocellular necrosis, ballooned hepatocytes, portal inflammation with piecemeal necrosis and proliferation of small-caliber bile ductules (45). Importantly, NHP HAVs are potentially zoonotic, and primates can become infected with human strains (116).

Hepatitis B virus (HBV)

HBV is a hepadnavirus, being the major cause of hepatitis in humans and is transmitted by infected blood, saliva, and semen, leading to a persistent infection that causes chronic hepatitis and induces the development of hepatocellular carcinoma (116). OWP are susceptible, especially cynomolgus monkeys, and the disease can be transmitted by humans. Pathological findings are periportal inflammation with lymphocytic cell infiltration progressing to cirrhosis (116). A specific hepadnavirus was isolated from a captive woolly monkey (*Lagothrix* sp.) with a lethal fulminant hepatitis and nine others from the same institution tested positive by PCR, being seven also positive for anti-HBV serology (92). This is the only report in NWP, with no data about this virus in wildlife.

Measles virus

Measles virus is a morbillivirus from the Paramyxoviridae family that have humans as primary hosts, but NHP are highly susceptible. Pathological findings in OWP

are initially rash (maculopapular exanthema) progressing to a severe interstitial pneumonia rich in giant multinucleated syncytial cells with intranuclear and intracytoplasmic inclusions. In NWP the disease is more characterized by necrotizing gastroenteritis with multinucleated syncytia in various tissues including lymph nodes. Once measles virus is strongly immunosuppressive, opportunistic co-infections are often observed (116).

No evidence of measles virus in free-ranging NWP has been reported, however, measles virus was controlled by high vaccine coverage in human populations for years, reducing the circulation of the virus in most of countries. Over the last two decades the number of measles cases has been progressively increasing and, since 2018, vaccination coverage has been falling worryingly with high number of human cases, including in Brazil (119). The COVID-19 pandemic has further undermined measles vaccination coverage, with vaccination levels reducing by up to 40% in the past two years (191, 198). These data raise concerns regarding the re-emergence of a disease that can be controlled with vaccine in the human population and at the same time alerts about the possibility of infection of susceptible NWP that live in areas of high human density, such as marmosets.

Orthopoxvirus

Seroprevalence of vaccinia virus (VACV) in free-ranging capuchins and howler monkeys from Brazilian Amazon detected 25.3% (68/269) and 48.1% (13/27) of positive animals, respectively, indicating that this virus circulates in an NWP population in natural conditions (1). VACV is an Orthopoxvirus, closely related to cowpox virus, a virus that captive NWP, especially callitrichids, seems to be highly susceptible to infection (116). Infection in NWP usually have lethal course and is characterized by vesicular and hemorrhagic to erosive-ulcerative dermal and mucocutaneous lesion with eosinophilic intracytoplasmic inclusion bodies in epithelial cells. Necrotizing lesions may be observed in multiple organs, such as liver, spleen, lymph nodes, stomach, and intestines. PCR and IHC can be performed to confirm the viral infection (114).

Oropouche virus (OROV)

OROV is an arbovirus from the family Bunyaviridae, which also comprises the genera Hantavirus, and is responsible to cause the Oropouche fever, a human disease that causes epidemics in Amazon region, being characterized by fever, headaches, chills, myalgia, arthralgia, retroocular pain, and, in a few cases, non-suppurative meningitis or meningoencephalitis (17). OROV have a sylvatic and urban cycle, depending on the vector. NWP are considered to play a role in the maintenance of this virus in the sylvatic cycle, with evidence of viral circulation in free-ranging capuchins and howler monkeys with positive serology to anti-OROV antibodies (67).

Papillomaviruses (PV)

PV are DNA viruses that infect epithelium and mucosa of a wide range of vertebrates, including humans, with 429 types, where 218 are found exclusively in humans (HPV). In humans and OWP, infections have been associated with dysplasia and neoplasia, being the most common cause of uterine cervical carcinoma in humans and causing typical papillomas with acanthosis and koilocytes in OWP (87, 116). PV infection in NWP is scarcer, with reports in asymptomatic captive marmosets, squirrel monkeys, howler monkeys, spider monkeys and titi monkeys (37, 47, 199). In wildlife PV was detected by PCR in oral swabs of two free-ranging NWP, one capuchin and one howler monkey, both from Argentina (176). HPV was investigated by IHC in a case of multicentric cutaneous keratoacanthomas in a free-ranging marmoset, but no viral antigen was detected (49).

Severe acute respiratory syndrome coronavirus 2 (SARS-CoV-2)

SARS-CoV-2 is an RNA virus responsible for the COVID-19 pandemic that began in December 2019 and is characterized by an acute respiratory syndrome with systemic inflammatory reaction. NHP, including common marmosets (*C. jacchus*) has been extensively used as experimental models for SARS-CoV-2 and others respiratory coronavirus (MERS-COV and SARS-COV), reproducing the disease that is observed in human patients (70, 104, 166, 201, 213). Therefore, two studies were performed searching for evidence of SARS-CoV-2 in free-ranging NWP populations from the genera *Callithrix*, *Callicebus*, and *Alouatta*, all from hotspots for COVID-19 in Brazil (2, 175). A total of 111 NWP was evaluated by RT-qPCR of oral and nasal swabs, blood and/or tissues and by PRNT, but no SARS-CoV-2 positive samples were detected, regardless of NWP species or biome tested (2, 175), raising questions about the susceptibility of these animals to SARS-CoV-2 under natural conditions. However, there is a recent case of natural infection in a free-ranging black-tailed marmoset (*Mico melanurus*). This animal developed an interstitial pneumonia with identification of the viral spike protein in the lung tissue by IHC. Nasopharyngeal and oropharyngeal swabs were also positive to RT-PCR (156).

Other viruses

Molina et al. (129) investigated by PCR hundreds free-ranging golden headed lion tamarin (*L. chrysomelas*) from Rio de Janeiro, Brazil, searching for hepatitis E virus genotype 3 (HEV-3), rotavirus A and norovirus GI and GII, but no positive animals was identified.

Protozoan parasites

Toxoplasma gondii

Toxoplasmosis, caused by *T. gondii*, is an important and lethal disease for almost all NWP species, being frequently reported in captive animals, usually associated with outbreaks

and an acute lethal evolution with sudden death (155, 177). Animals are infected by ingesting food contaminated with infective oocysts, which are released in the feces of domestic and wild felines, considered the definitive hosts (116). Pathological findings are represented by random necrotizing lesions in many organs (Fig. 8), especially at liver, lungs, spleen, and brain, associated with intralésional tachyzoites, that are better observed by IHC (71, 116, 155, 177, 183). Another important feature of the *T. gondii* infection in NWP is the severe pulmonary edema and hemorrhage, in some cases associated with diffuse alveolar damage, characterized by alveolar hyaline membrane (144, 177). There are only few reported cases of death by toxoplasmosis in free-ranging NWP, being three howler monkeys (*A. guariba*) (55) and one southern muriqui (*B. arachnoides*) (183). However, a recent study demonstrated that toxoplasmosis is also an important cause of lethality in free-ranging *Callithrix* spp., being identified as the cause of death of 1.6% of 1,001 marmosets examined, but the disease affects more commonly animals in urbanized areas (151). In both cases, intralésional tachyzoites were observed in multiple organs, highlighted by IHC. Molecular studies are important to characterize the genotype of the *T. gondii*, which may play a role in the pathogenicity of the disease (177, 183).

In captive, due to its acute lethal course, NWP usually dies from the infection before developing an immunological response (155), making serology a poorly efficient tool to evaluate the presence of the disease in these animals. This profile was also observed by Molina et al. (130) in a serosurvey for toxoplasmosis in a free-ranging population of tamarins (*L. chrysomelas*) from Niterói, Brazil, where 126 animals were tested by MAT and all were negative. However, some serological studies showed evidence of antibody anti-*T. gondii* in free ranging capuchins, howler monkeys and marmosets (23, 94, 128, 143), which indicate that some free-ranging NWP, although exposed to *T. gondii*, were able to survive to the acute phase. The severity of clinical toxoplasmosis in NWP may be associated with the protozoan (eg, inoculum, infective stage, genetic characteristics of the strain), host (eg, immune response, feeding behavior), and environment (eg, parasitic burden in soil and water) (6), justifying this contrasting results. In fact, it is known that capuchins are more resistant to infection than others NWP, even in similar exposure environment (155, 177).

Leishmania spp.

Leishmaniosis, caused by *Leishmania* spp., has been reported in captive NWP from endemic regions with serology and molecular detection in asymptomatic animals, with few symptomatic cases, sometimes resulting in death (98, 101, 109, 150, 182). Pathological findings in a lethal case of a captive titi-monkey (*Callicebus nigrifrons*) infected by *L. infantum* were marked emaciation, severe pulmonary edema and hemorrhage, moderate splenomegaly, and lymphadenopathy, hepatic

microgranulomas and lymphoplasmohytiocytic interstitial nephritis with macrophages containing amastigotes in all organs evaluated (109). IHC was performed to better visualize the amastigotes and PCR from the tissues confirmed the diagnosis. The other symptomatic NWP case reported in the literature was from a captive spider monkey (*A. paniscus*) that presented weight loss and pale mucous membranes and blood PCR detected *Leishmania amazonensis* (98).

In wildlife there are serologic and molecular

evidence of *Leishmania infantum*, *Leishmania mexicana*, *Leishmania shawi*, *L. amazonensis*, and *Leishmania braziliensis* in a wide range of NWP from endemic areas (4, 23, 28, 78, 89, 90, 112, 120, 154, 172, 182, 212), but no symptomatic animals were identified. These findings could represent a public health concern once some species of NWP were competent in transmitting *L. infantum* to the invertebrate vector *Lutzomyia longipalpis* (150, 182), being a potential reservoir of this parasite contributing to its maintenance in the environment.

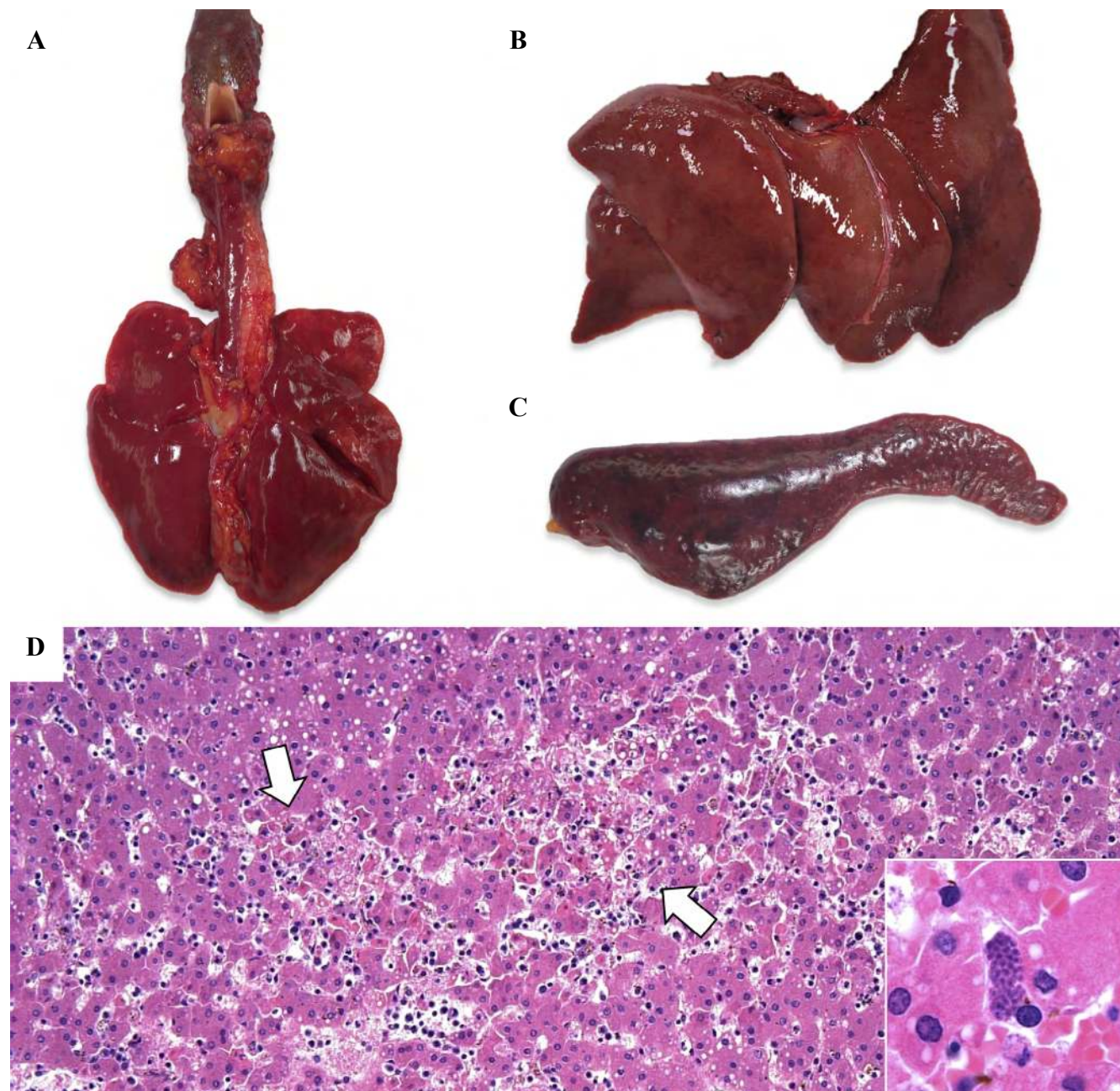


Figure 8. *Toxoplasma gondii* infection in neotropical primates. Grossly, it is observed marked pulmonary edema and congestion (A), enlarged liver, diffusely pale, with focuses of hemorrhage and necrosis (B), and enlarged spleen, with multifocal to coalescent areas of necrosis (C). (D) Random necrotizing hepatitis characterized by lytic necrosis (arrow) with intralésional tachyzoites (down right, HE, 400x). Steatosis may be observed in the adjacent hepatocytes.

Trypanosoma spp.

Trypanosoma cruzi is a mammal parasite, being the etiological agent of Chagas disease in humans, endemic throughout Latin America and classically transmitted by wound bites contaminated with feces of blood-sucking triatomine bugs (125). Oral transmission is also recognized in humans and animals, by ingestion of infected triatomines or contaminated foods and drinks (52, 80, 216). Pathological findings associated to *Trypanosoma* infections, especially for *T. cruzi*, are better known in captive primates, mainly reported in OWP. For *T. cruzi*, usually, it is observed a severe lymphoplasmacytic myocarditis with variable number of protozoan cysts filled with amastigotes in the cytoplasm of cardiomyocytes. Inflammation and amastigotes can be observed in other tissues, such as testis, but it is uncommon (48). Importantly, sometimes the amastigotes are not easily observed in the tissue, therefore IHC and *in situ* hybridization (ISH) are important tools to confirm the diagnosis (48). PCR is also frequently use and is important to differentiate from *Leishmania* sp. and others *Trypanosoma* species (28).

Serological evidence of *T. cruzi* was identified in 16% (8/48) of a free-ranging capuchin (*S. flavius*) population from the Brazilian Northern region, being five of these positive animals, also positive for *Leishmania* sp. (23). Free-ranging populations of golden lion tamarin (*L. rosalia*) from Rio de Janeiro, Brazil, had a high prevalent (> 50%) and persistent (> five years) parasitemia, with identification of *T. cruzi* genotype II by hemoculture and serological assays, with no evidence of clinical signs, being considered the most important wild reservoir for that genotype (99). However, mild cardiac alterations by electrocardiogram and hypergammaglobulinemia were identified by other studies in golden lion tamarin *T. cruzi*-infected, suggesting that, although difficult to identify, tamarins may have clinical signs and pathological disturbance similar to infected humans (132, 133). Xenodiagnosis performed in two free-ranging squirrel monkeys (*Saimiri* sp.) infected by *T. cruzi* detected trypanosomes in the gut and salivary gland of the exposed triatomine (227) and a study with captive NWP identified positive primates and bugs in the same enclosure (125). Together, these data highlight the role of NWP in the trypanosome transmission, with direct impact in the public health, being an important key to the transmission and maintenance of this agent in wildlife.

Serology, blood smears cytology and blood PCR also detected *T. cruzi* and others *Trypanosoma* species in wild populations of marmosets (*Callithrix* sp. and *Mico melanurus*), howler monkeys (*Aloatta pigra*, *Alouatta caraya*, and *A. palliata*), spider monkeys (*A. geoffroyi*), tamarins (*Saguinus bicolor*) and capuchins (*Sapajus apella*) (28, 38, 113, 172, 173, 193). In some of those studies, besides *T. cruzi*, *Trypanosoma minasense* and/or *Trypanosoma rangeli* were confirmed by DNA sequencing. These two species are primitive *Trypanosoma* species considered of low pathogenicity in vertebrates, but with a constant low parasitemia in NWP (28, 38). No symptomatic animals were identified in those studies.

Plasmodium spp.

Plasmodium spp. are extremally studied due to its importance on public health, being the causative agents of

malaria, the deadliest human vector-transmitted disease in the world. The species associated with this disease are *Plasmodium vivax* and *Plasmodium falciparum*, with cases of mixed infections (169). There are 29 species of *Plasmodium* that parasitize NHP, with reports in free-ranging NWP of *P. falciparum*, *Plasmodium brazilianum* and *Plasmodium simium*, closely related to *P. vivax* and identified in human malaria outbreaks. *P. brazilianum* was also detected in humans, being classified as quartan malaria parasite, which is considered harmless but have been associated with the development of renal disease (91).

Free-ranging howler monkeys (*A. guariba clamitans*) are considered de main reservoir of malaria in the Atlantic Forest. Studies using blood and stool PCR have shown high prevalence (30 to 70%) of *Plasmodium* in free-ranging populations from fragmented and peri-urbanized areas, in some cases coinciding with human malarian outbreaks (3, 33, 41, 145, 169). Animals were infected with *P. simium*, *P. falciparum*, and *P. brazilianum*, and at hematological and biochemical analysis the infected animals presented lymphocytosis, hypoalbuminemia, and high levels of ALT, that were even higher in mixed infections (3, 145, 169). One symptomatic case presented inappetence, weakness, apathy, intermittent muscle tremors, dry and pale mucous membranes, mild dehydration and loss of muscle mass and body weight, with severe thrombocytopenia, anemia, and uremia (41). In another study, histopathology revealed hemozoin pigment at the spleen of the infected animals (3).

In wildlife, from Amazon to Atlantic Forest, a wide range of NWP has been detected with *Plasmodium* spp., such as capuchins (*Sapajus* sp., *Sapajus flavius*, and *Cebus vesicolor*) (23, 33, 64, 169), spider monkeys (*Ateles* sp. and *Ateles hybridus*) (33, 169), titi monkeys (*Callicebus dubius* and *Callicebus caligatus*) (25), sakis (*Pithecia* sp.) (25), and squirrel monkeys (*S. sciurus*) (33). Therefore, studied have been demonstrating the importance of NWP as potential reservoir of malaria parasite. However, studies about the impact of these parasites on the health of NWP are still scarce.

Metazoan parasites

There are many studies of helminth fauna in free-ranging NWP, most of them evaluating feces from wild animals during capture and some performed during necropsies (32, 157, 168, 170, 202, 208, 226). Free-ranging animals are usually parasitized and asymptomatic (32, 168, 208). However, in cases of any disturbance in the organism homeostasis, this balance is broken, and the animal may progress to clinical signs and death (148). Some parasites, such as *Platynosomum* sp. and *Prosthenorchis* sp., are well described in captive NWP, being extremally lethal and difficult to control (149, 194, 203), but its impact in free-ranging animals is still unknown.

In general, the diagnostic of metazoan parasites is usually performed based on morphological features of the adult parasite and/or its eggs found in the feces or tissues of the animals (Fig. 9). Unfortunately, there are only few studies focusing on molecular characterization of these parasites, therefore, there is scarce information on genomic database, making this a difficult tool to use in routine studies (226).

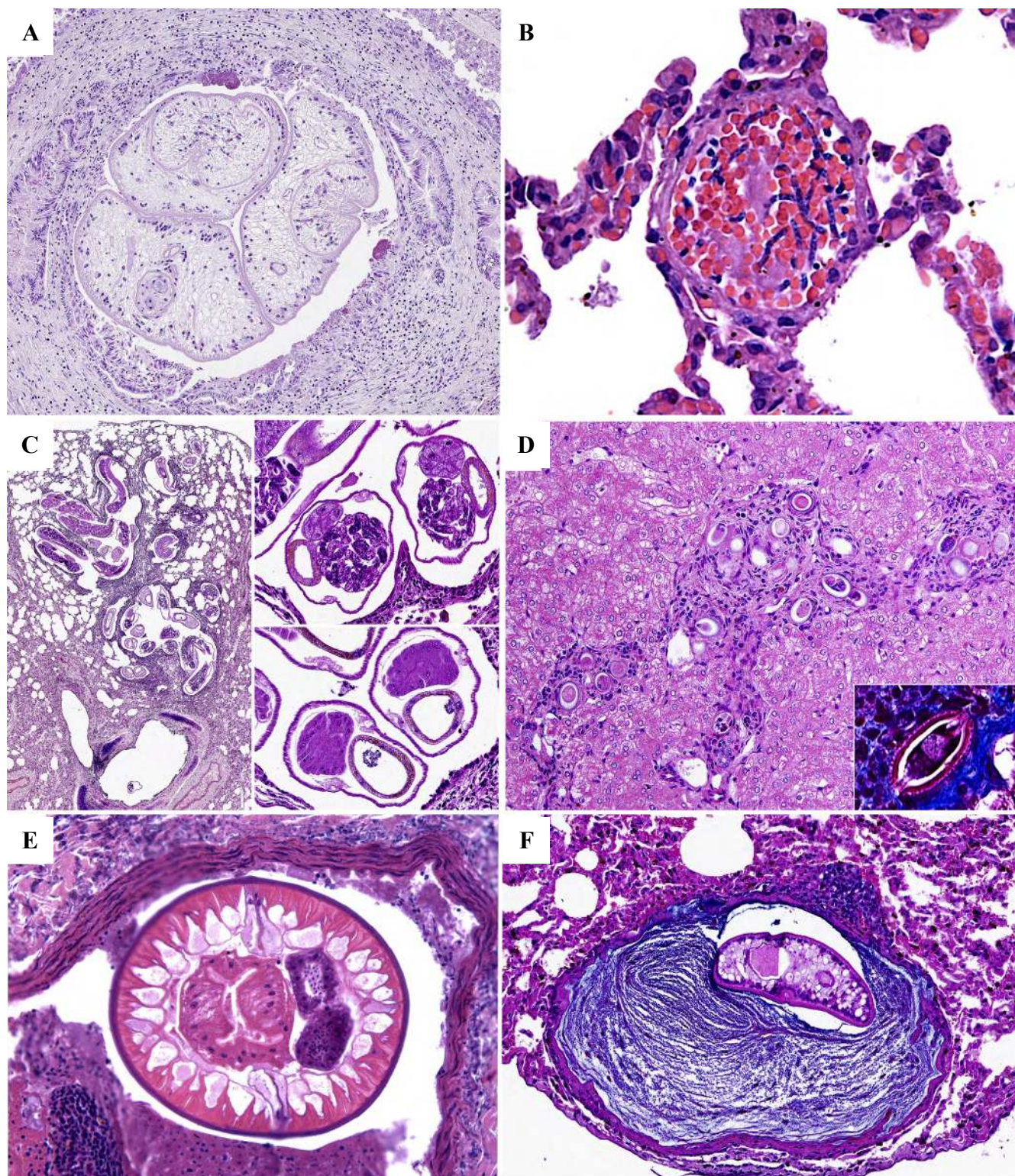


Figure 9. Metazoan infection in free-ranging marmoset (*Callithrix* spp.). (A) Fibrosing and proliferative cholangiohepatitis with intraductal trematode morphologically compatible with *Platynosomum* spp. Liver, HE, 200x. (B) Myriad of intravascular microfilariae associated with mild fibrin clusters. Lung, HE, 400x. (C) Transversal and longitudinal sections of adult nematode at the airways (left frame, 50x), compatible with females (top right, 200x) and males (down right, 200x) of metastrongylus. Lung, HE. (D) Pyogranulomatous portal hepatitis with intralesional bi-operculated nematode eggs (down right, Masson's trichome, 400x), compatible with hepatic capillaritis. Liver, HE, 200x. (E) Adult intravascular nematode, lung, HE, 200x. (F) Pulmonary pseudocyst containing trematode mesocercaria immersed in a myxomatous matrix. Lung, HE, 200x.

Fungi

Fungal infections in NWP have been rarely described, even in captive animals (116).

Aspergillus spp.

Aspergillus sp. is a commensal fungus from NWP mucosa and is considered an opportunistic pathogen (116). Guerra et al. (73) described one single report of an *A. fumigatus* pulmonary infection in a free-ranging howler monkey infected by YFV. In this case the animal developed a necrosuppurative bronchopneumonia with angioinvasive fungal hyphae. Chromogenic ISH (CISH) was performed to highlight the fungi in the tissue and PCR with DNA sequencing confirmed the diagnosis (73).

Dermatophytosis

Dermatophytosis was investigated in 232 free-ranging tamarins (*L. chrysomelas*) with isolation of *Microsporum cookie* in one young healthy female (142). The diagnosis was performed by fungal culture on Sabouraud dextrose agar and phenotype identification. *Malassezia* spp. were isolated from 32.8% of a free-ranging tamarin population, being more frequently isolated from the haircoat than the ear canals of these animals (142). No superficial cutaneous lesions or signs of external otitis were observed in the infected animals, indicating that *Malassezia* spp. may be part of the normal microbiota of its skin.

Concluding remarks and perspectives

This comprehensive review clearly indicates an increasing number of studies and publications on infectious diseases of free-ranging neotropical primates. For a long period of time, disease investigation in wildlife was neglected. However, there are growing numbers of evidence that anthropic influences may create conditions in which infectious diseases may decimate entire populations. Therefore, the effort on disease investigation is of maximum priority under a conservation medicine point of view. Furthermore, the One Health concept has gained momentum so neotropical primates may play a key role for a thorough understanding of the epidemiology, disease manifestation, and zoonotic risk in the context of several tropical diseases. Together, these notions strongly indicate that scientific investigation of non-human primate diseases is a field of study that should experience marked expansion, both quantitatively and qualitatively, in the foreseeable future.

Acknowledgements

This study was sponsored by the Fresno Chaffee Zoo Wildlife Conservation Fund (Fresno, CA, USA). Work in RLS lab is supported by CNPq (Conselho Nacional de Desenvolvimento Científico e Tecnológico, Brazil), FAPEMIG (Fundação de Amparo a Pesquisa do Estado de Minas Gerais, Brazil), and CAPES (Coordenação de Aperfeiçoamento de Pessoal de Nível Superior, Brazil).

Conflict of Interest

The authors declare no competing interests.

References

1. Abrahão JS, Silva-Fernandes AT, Lima LS, Campos RK, Guedes MI, Cota MM, Assis FL, Borges IA, Souza-Júnior MF, Lobato ZI, Bonjardim CA, Ferreira PC, Trindade GS, Kroon EG. Vaccinia virus infection in monkeys, Brazilian Amazon. *Emerg Infect Dis.* 2010;16(6):976-9.
2. Abreu FVS, Macedo MV, Silva AJJ, Oliveira CH, Ottone VO, Almeida MAB, Santos E, Cardoso JC, Campos AS, Silva CMD, Silva AG, Andrade MS, Bernis VMO, Bernis Filho WO, Trindade GS, Albuquerque GR, Sevã AP, Ribeiro BM, Teixeira DS, Campos FS, Franco AC, Roehle PM, Oliveira DB. No Evidence of SARS-CoV-2 Infection in neotropical primates sampled during COVID-19 pandemic in Minas Gerais and Rio Grande do Sul, Brazil. *Ecohealth.* 2021;18(4):414-20.
3. Abreu FVS, Santos E, Mello ARL, Gomes LR, Alvarenga DAM, Gomes MQ, Vargas WP, Bianco-Júnior C, Pina-Costa A, Teixeira DS, Romano APM, Manso PPA, Pelajo-Machado M, Brasil P, Daniel-Ribeiro CT, Brito CFA, Ferreira-da-Cruz MF, Lourenço-de-Oliveira R. Howler monkeys are the reservoir of malarial parasites causing zoonotic infections in the Atlantic forest of Rio de Janeiro. *Plos Neglect Trop Dis.* 2019;13(12):e0007906.
4. Acardi SA, Rago MV, Liotta DJ, Fernandez-Duque E, Salomón OD. *Leishmania (Viannia)* DNA detection by PCR-RFLP and sequencing in free-ranging owl monkeys (*Aotus azarai azarai*) from Formosa, Argentina. *Vet Parasitol.* 2013;193(1-3):256-9.
5. Adlhoch, C, Kaiser M, Loewa A, Forbrig C, Adjogoua EV, Akoua-Koffi C, Couacy-Hymann E, Leendertz SAJ, Rietschel W, Boesch C, Ellerbrok H, Schneider BS, Leendertz FH. Diversity of parvovirus 4-like viruses in humans, chimpanzees, and monkeys in hunter-prey relationships. *Emerg Infect Dis.* 2012;18(5), 859-62.
6. Ajzenberg D, Bañuls AL, Su C, Dumètre A, Demar M, Carne B, Dardé ML. Genetic diversity, clonality and sexuality in *Toxoplasma gondii*. *Int J Parasitol.* 2004;34:1185-96.
7. Albrecht JC. Primary structure of the *Herpesvirus ateles* genome. *J Virol.* 2002;74:1033-7.
8. Alcantara BN, Imbeloni AA, Durans DBS, Araújo MTF, Cruz ERM, Carvalho CAM, Mendonça MHR, Sousa JR, Moraes AF, Martins Filho AJ, Lima MLG, Amador Neto OP, Chiang JO, Scalercio SRRA, Carneiro LA, Quaresma JAS, Vasconcelos PFC, Medeiros DBA. Histopathological lesions of congenital Zika syndrome in newborn squirrel monkeys. *Sci Rep.* 2021;11(1):6099.
9. Aliaga-Samanez GG, Lescano J, Urday MJQ, Rodríguez GSS, Watsa ME, Escalante JEC, Erkenwick GA. First detection of antibodies against *Leptospira* among free-ranging neotropical non-human primates in the Peruvian Amazon lowland rainforest. *Transbound Emerg Dis.* 2022;69(3):1458-65.

10. Almeida MAB, Santos E, Cardoso JC, Fonseca DF, Noll CA, Silveira VR, Maeda AY, Souza RP, Kanamura C, Brasil RS. Yellow fever outbreak affecting *Alouatta* populations in southern Brazil (Rio Grande do Sul State), 2008–2009. *Am J Primatol.* 2012;74(1):68-76.
11. Anzai EK, Júnior JCS, Peruchi AR, Fonseca JM, Gimpl EK, Pignatari ACC, Hirano ZMB, Silveira ACO. First case report of non-human primates (*Alouatta clamitans*) with the hypervirulent *Klebsiella pneumoniae* serotype K1 strain ST 23: a possible emerging wildlife pathogen. *J Med Primatol.* 2017;46(6):337-42.
12. Argüello-Sánchez LE, Monteros AE, Santiago-Alarcon D, García-Sepúlveda CA. Detection and prevalence of adenoviruses from free-ranging black howler monkeys (*Alouatta pigra*). *Virus Genes.* 2018;54(6):818-22.
13. Armstrong AR, Wünschmann A, Rigatti LH, Klein EC. *Clostridium difficile* enterocolitis in a captive Geoffroy's spider monkey (*Ateles geoffroyi*) and common marmosets (*Callithrix jacchus*). *Vet Pathol.* 2019;56(6):959-63.
14. Baker EN, Helps CR, Neimark H, Peters IR, Peters W, Tasker S. A novel haemoplasma species identified in archived primate blood smears. *Vet. Microbiol.* 2011;149:478-81.
15. Bakker J, Kondova I, Groot CW De, Remarque EJ, Heidt PJ. A report on *Yersinia*-related mortality in a colony of New World Monkeys. *Lab Primate Newsletter.* 2007;46:11-6.
16. Barnes KJ, Garner MM, Wise AG, Persiani M, Maes RK, Kiupel M. Herpes simplex encephalitis in a captive black howler monkey (*Alouatta caraya*). *J Vet Diagn Invest.* 2016;28:76-8.
17. Bastos MS, Figueiredo LTM, Naveca FG, Monte RL, Lessa N, Figueiredo RMP, Gimaque JBL, João GP, Ramasawmy R, Mourão MPG. Identification of Oropouche Orthobunyavirus in the cerebrospinal fluid of three patients in the Amazonas, Brazil. *Am J Trop Med Hyg.* 2012;86:732-5.
18. Bath S, Acharya PR, Biranthabail D, Rangnekar A, Shiragavi S. A case of lower respiratory tract infection with canine-associated *Pasteurella canis* in a patient with chronic obstructive pulmonary disease. *J Clin Diagn Res.* 2015;9(8):3-4.
19. Benavides JA, Raghavan RK, Boere V, Rocha S, Wada MY, Vargas A, Voietta F, Oliveira E, Silva I, Leal S, Castro A, Arruda MF, Peterson AT, Megid J, Carrieri ML, Kotait I. Spatio-temporal dynamics of rabies and habitat suitability of the common marmoset *Callithrix jacchus* in Brazil. *PLoS Negl Trop Dis.* 2022;16(3):e0010254.
20. Bonato L, Figueiredo MAP, Gonçalves LR, Machado RZ, André MR. Occurrence and molecular characterization of *Bartonella* spp. and hemoplasmas in neotropical primates from Brazilian Amazon, Comp. Immunol. Microbiol. Infect. Dis. 2015;42:15-20.
21. Bruno SF, Liebhold MM, Mätz-Rensing K, Romão MA, Didier A, Brandes F, Bressan AC, Kaup FJ. Herpesvirus infections in free living black tufted ear marmosets (*Callithrix penicillata*, E. Geoffroyi 1812) at the State Park of Serra da Tiririca, Niterói, Rio de Janeiro, Brazil [in German]. *Berl Munch Tierarztl Wochenschr.* 1997;110:427-30.
22. Buchanan A, Díaz-Delgado J, Balamayooran G, Anguiano M, Groch K, Krol L. Leukemic histiocytic sarcoma in a captive common squirrel monkey (*Saimiri sciureus*) with Saimiriine Gammaherpesvirus 2 (Rhadinovirus), *Saimiri sciureus* lymphocryptovirus 2 (Lymphocryptovirus) and Squirrel monkey retrovirus (β -Retrovirus) coinfection. *J Med Primatol.* 2020;49(6):341-3.
23. Bueno MG, Catão-Dias JL, Laroque PO, Vasconcellos SA, Ferreira Neto JS, Gennari SM, Ferreira F, Laurenti MD, Umezawa ES, Kesper N, Kirchgatter K, Guimarães LO, Pavanato HJ, Valença-Montenegro MM. Infectious Diseases in Free-Ranging Blonde Capuchins, *Sapajus flavius*, in Brazil. *Int J Primatol.* 2017;38(6):1017-31.
24. Bueno MG, Iovine RO, Torres LN, Catão-Dias JL, Pissinatti A, Kierulff MCM, Carvalho VM. Pneumonia and bacteremia in a golden-headed lion tamarin (*Leontopithecus chrysomelas*) caused by *Klebsiella pneumoniae* subsp. *pneumoniae* during a translocation program of free-ranging animals in Brazil. *J Vet Diagn Investig.* 2015;27(3):387-91.
25. Bueno MG, Rohe F, Kirchgatter K, Di Santi SMF, Guimarães LO, Witte CL, Costa-Nascimento MJ, Toniolo CRC, Catão-Dias JL. Survey of *Plasmodium* spp. in free-ranging neotropical primates from the Brazilian Amazon region impacted by anthropogenic actions. *Ecohealth.* 2013;10(1):48-53.
26. Burke DS, Heisey GB: Wild malaysian cynomolgus monkeys are exposed to hepatitis A virus. *Am J Trop Med Hyg.* 1984;33:940-4.
27. Cadavid D, Bai Y, Hodzic E, Narayan K, Barthold SW, Pachner AR. Cardiac involvement in non-human primates infected with the Lyme disease spirochete *Borrelia burgdorferi*. *Lab Invest.* 2004;84(11):1439-50.
28. Cândido SL, Pavelegini LAD, Pacheco TA, Pacheco RC, Silva VLB, Morgado TO, Colodel EM, Nakazato L, Almeida ABPF, Dutra V. Molecular detection of trypanosomatids in neotropical primates in the state of Mato Grosso, Midwest, Brazil. *Rev Bras Parasitol Vet.* 2021;30(2):e001321.
29. Carvalho TP, Moreira LGA, Vieira AD, Silva LA, Santana CH, Santos DO, Oliveira AR, Tinoco HP, Coelho CM, Xavier RGC, Silva ROS, Paixão TA, Santos RL. *Mammaliicoccus (Staphylococcus) sciuri*-induced suppurative meningoencephalitis and bacteremia in an infant western lowland gorilla (*Gorilla gorilla gorilla*). *J Med Primatol.* 2022;51(6):396-399.

30. Carvalho TP, Santos DO, Oliveira AR, Vasconcelos IMA, Tinoco HP, Coelho CM, Carvalho GM, Xavier RGC, Silva ROS, Paixão TA, Santos RL. Lethal acute diarrhea associated with *Clostridioides difficile* toxin A and B in a buffy-tufted-ear marmoset (*Callithrix aurita*). *J Med Primatol*. 2022;51(6):400-403.
31. Casagrande RA, Pannuti CS, Kanamura C, Freire WS, Grespan A, Matushima ER. Fatal human herpesvirus 1 (HHV-1) infection in captive marmosets (*Callithrix jacchus* and *Callithrix penicillata*) in Brazil: clinical and pathological characterization. *Pesq Vet Bras*. 2014;34:1109-14.
32. Catenacci LS, Oliveira JBS, Vleeschouwer KMD, Oliveira LC, Deem SL, Sousa Júnior SC, Santos KRD. Gastrointestinal parasites of *Leontopithecus chrysomelas* in the Atlantic Forest, Brazil. *Rev Bras Parasitol Vet*. 2022;31(1):e013521.
33. Chaves A, Dolz G, Ibarra-Cerdeña CN, Núñez G, Ortiz-Malavasi E, Bernal-Valle S, Gutiérrez-Espeleta GA. Presence and potential distribution of malaria-infected New World primates of Costa Rica. *Malaria J*. 2022;21(1):17.
34. Chaves A, Ibarra-Cerdeña CN, López-Pérez AM, Monge O, Avendaño R, Ureña-Saborio H, Chavarría M, Zaldaña K, Sánchez L, Ortiz-Malavasi E, Suzan G, Foley J, Gutiérrez-Espeleta GA. Bocaparvovirus, Erythroparvovirus and Tetraparvovirus in New World Primates from Central America. *Transbound Emerg Dis*. 2020;67(1):377-87.
35. Chaves A, Piche-Ovares M, Ibarra-Cerdeña CN, Corrales-Aguilar E, Suzán G, Moreira-Soto A, Gutiérrez-Espeleta GA. Serosurvey of nonhuman primates in Costa Rica at the human-wildlife interface reveals high exposure to Flaviviruses. *Insects*. 2021;12(6):554.
36. Chen EC, Yagi S, Kelly KR, Mendoza SP, Tarara RP, Canfield DR, Maninger N, Rosenthal A, Spinner A, Bales KL, Schnurr DP, Lerche NW, Chiu CY. Cross-species transmission of a novel adenovirus associated with a fulminant pneumonia outbreak in a new world monkey colony. *PLoS Pathog*. 2011;7:e1002155.
37. Chen Z, Wood CE, Abee CR, Burk RD. Complete Genome sequences of three novel *Saimiri sciureus* papillomavirus types isolated from the cervicovaginal region of squirrel monkeys. *Genome Announc*. 2018;6(1):e01400-17.
38. Coimbra DP, Penedo DM, Silva MOM, Abreu APM, Silva CB, Verona CE, Heliodoro GC, Massard CL, Nogueira DM. Molecular and morphometric identification of *Trypanosoma (Megatrypanum) minasense* in blood samples of marmosets (*Callithrix*: Callithrichidae) from the city of Rio de Janeiro, Brazil. *Parasitol Int*. 2020;75:101999.
39. Contigiani MS, Fernández C, Spinsanti LI, Díaz GE. Prevalence of Flavivirus antibodies in *Alouatta caraya* primate autochthonous of Argentina. *Medicina (B Aires)*. 2000;60(3):348-50.
40. Costa A, Luppi MM, Malta MCC, Luiz APMF, Araujo MR, Coelho FM, Fonseca FG, Ecco R, Resende M. Outbreak of Human Herpesvirus Type 1 Infection in Nonhuman Primates (*Callithrix penicillata*). *J Wildlife Dis*. 2011;47(3):690-93.
41. Costa DC, Cunha VP, Assis GMP, Souza Junior JC, Hirano ZMB, Arruda ME, Kano FS, Carvalho LH, Brito CFA. *Plasmodium simium/Plasmodium vivax* infections in southern brown howler monkeys from the Atlantic Forest. *Mem Inst Oswaldo Cruz*. 2014;109(5):641-53.
42. Coursaget P, Levesque B, Gretillat E, Eyraud M, Ferrara L, Germain M: Hepatitis A virus in primates outside captivity. *Lancet*. 1981;2:929.
43. Crossland NA, Alvarez X, Embers ME. Late Disseminated Lyme Disease. *Am J Pathol*. 2018;188(3):672-82.
44. Cubilla MP, Santos LC, Moraes W, Cubas ZS, Leutenegger CM, Estrada M, Vieira RFC, Soares MJ, Lindsay LL, Sykes JE, Biondo AW. Occurrence of hemotropic mycoplasmas in non-human primates (*Alouatta caraya*, *Sapajus nigritus* and *Callithrix jacchus*) of Southern Brazil, *Comp Immunol Microbiol Infect Dis*. 2017;52:6-13.
45. Cullen JM, Lemon SM. Comparative pathology of hepatitis A virus and hepatitis E virus infection. *Cold Spring Harb Perspect Med*. 2018;9(4):a033456.
46. Cunha MS, Faria NR, Caleiro GS, Candido DS, Hill SC, Claro IM, Costa AC, Nogueira JS, Maeda AY, Silva FG, Souza RP, Spinola R, Tubaki RM, Menezes RMT, Abade L, Mucci LF, Timenetsky MDCST, Sabino E. Genomic evidence of yellow fever virus in *Aedes scapularis*, southeastern Brazil, 2016. *Acta Trop*. 2020;205:105390.
47. D'arc M, Moreira FRR, Dias CA, Souza AR, Seuánez HN, Soares MA, Tavares MCH, Santos AFA. The characterization of two novel neotropical primate papillomaviruses support the ancient within-species diversity model. *Virus Evol*. 2020;6(1):36.
48. DeLorenzo M, Carias E, Mustonen A, Gonzalez O, Dick EJ, Kumar S. *In situ* hybridization assay for the diagnosis of chagas myocarditis and orchitis in a rhesus macaque (*Macaca mulatta*): a case report. *J Med Primatol*. 2019;48(3):182-5.
49. Díaz-Delgado J, Sanches TC, Cirqueira CS, et al. Multicentric cutaneous keratoacanthomas in a free-living marmoset (*Callithrix sp.*). *J Med Primatol*. 2018;47(3):205-208.
50. Dietz JM, Hankerson SJ, Alexandre BR, Coimbra AAC, Guerra JM, Olivares V, Di Loretto C, Ressio RA, Iglezias S, Fernandes NCCA, Kanamura C, Groch KR, Catão-Dias JL. Yellow fever in Brazil threatens successful recovery of endangered golden lion tamarins. *Sci Rep*. 2019;9(1):12926.
51. Dolz G, Chaves A, Gutiérrez-Espeleta GA, Ortiz-Malavasi E, Bernal-Valle S, Herrero MV. Detection of antibodies against Flavivirus over time in wild non-human primates from the lowlands of Costa Rica. *Plos One*. 2019;14(7):e0219271.

52. Dorn PL, Daigle ME, Combe CL, Tate AH, Stevens L, Phillippi-Falkenstein KM. Low prevalence of Chagas parasite infection in a nonhuman primate colony in Louisiana. *J Am Assoc Lab Anim Sci.* 2012;51(4):443-7.
53. Dumas F, Mazzoleni S. Neotropical primate evolution and phylogenetic reconstruction using chromosomal data. *Eur Zool J.* 2017;84:1,1-18.
54. Ehlers LP, Bianchi MV, Argenta FF, Lopes BC, Taunde PA, Wagner PGC, Driemeier D, Pavarini SP, Mayer FQ, Siqueira FM, Sonne L. *Mycobacterium tuberculosis* var. *tuberculosis* infection in two captive black capuchins (*Sapajus nigritus*) in Southern Brazil. *Braz J Microbiol.* 2020;51(4):2169-73.
55. Ehlers LP, Slaviero M, Bianchi MV, Mello LS, De Lorenzo C, Surita LE, Alievi MM, Driemeier D, Pavarini SP, Sonne L. Causes of death in neotropical primates in Rio Grande do Sul State, Southern Brazil. *J Med Primatol.* 2022;51(2):85-92.
56. Ersching J, Hernandez MIM, Cezarotto FS. Neutralizing antibodies to human and simian adenoviruses in humans and New-World monkeys. *Virology.* 2010;10;407(1):1-6.
57. Favoretto SR, Araujo DB, Duarte NFH, Oliveira DBL, Crus NG, Mesquita F, Leal F, Machado RRG, Gaio F, Oliveira WF, Zanotto PMA, Durigon EL. Zika Virus in Peridomestic Neotropical Primates, Northeast Brazil. *Ecohealth.* 2019;16(1):61-9.
58. Favoretto SR, Mattos CC, Morais NB, Araújo FAA, Mattos CA. Rabies in marmosets (*Callithrix jacchus*), Ceará, Brazil. *Emerg Infect Dis.* 2001;7(6):1062-5.
59. Fernandes NCCA, Cunha MS, Guerra JM, Diaz-Delgado J, Ressio RA, Cirqueira CS, Kanamura CT, Fuentes-Castillo D, Catão-Dias JL. Yellow fever as cause of death of titi monkeys (*Callicebus* spp.). *Vet Pathol.* 2021;58(4):730-5.
60. Fernandes NCCA, Guerra JM, Cunha MS, Beraldo KRF, Ressio RA, Cirqueira CS, D'Agostini TL, Camargo JP, Landi NCSF, Saad LDC, Spinola RMF, Paula RAC, Sanches TC, Rivas L, Catão-Dias JL. Yellow fever surveillance challenge: investigation of a marmoset non-autochthonous case. *Acta Trop.* 2020;212:105702.
61. Fernandes NCCA, Guerra JM, Diaz-Delgado J, Cunha MS, Saad LC, Iglezias SD, Ressio RA, Cirqueira CS, Kanamura CT, Jesus IP, Maeda AY, Vasami FGS, Carvalho J, Araújo LJT, Souza RP, Nogueira JS, Spinola RMF, Catão-Dias JL. Differential yellow fever susceptibility in New World nonhuman primates, comparison with humans, and implications for surveillance. *Emerg Infect Dis.* 2021;27(1):47-56.
62. Fernandes ATS, Moreira SB, Gaspar LP, Simões M, Cajaraville ACRA, Pereira RC, Gomes MPB, Linhares JHR, Santos VO, Santos RT, Amorim JF, Barros TAC, Melgaço JG, Silva AMV, Fernandes CB, Tubarão LN, Silva J, Caride EC, Borges MB, Guimarães RC, Marchevsky RS, Lima SMB, Bom APDA, Neves PCC, Pissinatti A, Freire MS. Safety and immunogenicity of 17DD attenuated fever vaccine in howler monkeys (*Alouatta* spp.). *J Med Primatol.* 2021;50(1):36-45.
63. Fiori AE. Hepatitis A transmitted by food. *Clin Infect Dis.* 2004;38:705-15.
64. Figueiredo MAP, Santi SMFD, Figueiredo TAP, Machado RZ. Natural *Plasmodium* infection in neotropical primates in the island of São Luís, state of Maranhão, Brazil. *Rev Bras Parasitol Vet.* 2015;24(2):122-8.
65. Gessain A, Montange T, Betsem E, Ndongo CB, Njouom R, Buseyne F. Case-control study of the immune status of humans infected with zoonotic gorilla simian foamy viruses. *J Infect Dis.* 2020;221(10):1724-1733.
66. Ghersi BM, Jia H, Aiewsakun P, Katzourakis A, Mendoza P, Bausch DG, Kasper MR, Montgomery JM, Switzer WM. Wide distribution and ancient evolutionary history of simian foamy viruses in New World primates. *Retrovirology.* 2015;12(1):89.
67. Gibrail MM, Fiaccadori FS, Souza M, Almeida TNV, Chiang JO, Martins LC, Ferreira MS, Cardoso DDP. Detection of antibodies to Oropouche virus in non-human primates in Goiânia City, Goiás. *Rev Soc Bras Med Trop.* 2016;49(03):357-60.
68. Giovanetti M, Mendonça MCL, Fonseca V, Mares-Guia MA, Fabri A, Xavier J, Jesus JG, Gräf T, Rodrigues CDS, Santos CC, Sampaio SA, Chalhoub FLL, Nogueira FB, Theze J, Romano APM, Ramos DG, Abreu AL, Oliveira WK, Said RFC, Alburque CFC, Oliveira T, Fernandes CA, Aguiar SF, Chieppe A, Sequeira PC, Faria NR, Cunha RV, Alcantara LCJ, Filippis AMB. Yellow fever virus reemergence and spread in southeast Brazil, 2016–2019. *J Virol.* 2019;94(1):e01623-19.
69. Girio RJS, Andrade-Cruvinel TM, Vasconcellos SA, Repetti CSF, Friolani M, Bueno PCS, Felix M, Teixeira DB. Serological survey and DNA screening of *Leptospira* spp. in free-living adult tufted capuchin monkeys (*Cebus apella nigritus*) in a forest reserve Southeast São Paulo State, Brazil. *J Med Primatol.* 2021;50(1):3-8.
70. Greenough, TC, Carville A, Coderre J, Somasundaran M, Sullivan JL, Luzuriaga K, Mansfield K. Pneumonitis and multi-organ system disease in common marmosets (*Callithrix jacchus*) infected with the severe acute respiratory syndrome-associated Coronavirus. *Am J Pathol.* 2005;167:455-63.
71. Grumann MR, Silva Z, Filho JRS, Costa MM, Vieira MIB, Motta AC. Immunohistochemical and serological aspects of *Toxoplasma gondii* infection in Neotropical primates. *Semina Ciênc Agr.* 2016;38(3):1375-82.
72. Guerra JM, Fernandes NCCA, Santos ALM, Repetti CSF, Friolani M, Bueno PCS, Felix M, Teixeira DB. Hypervirulent *Klebsiella pneumoniae* as unexpected cause of fatal outbreak in captive marmosets, Brazil. *Emerg Infect Dis.* 2020;26(12):3039-43.
73. Guerra JM, Ferreira CSS, Diaz-Delgado J, Takahashi JPF, Kimura LM, Araújo LJT, Rêssio RA, Cirqueira CS, Ozahatar CH, Cunha MS, Luchs A, Fernandes NCCA. Concurrent yellow fever and pulmonary aspergillosis due to *Aspergillus fumigatus* in a free-ranging howler monkey (*Alouatta* sp.). *J Med Primatol.* 2021;50(3):201-4.

74. Guerra MFL, Teixeira RHF, Ribeiro VL, Cunha MPV, Oliveira MGX, Davies YM, Silva KC, Silva APS, Lincopan N, Moreno AM, Knöbl T. Suppurative peritonitis by *Klebsiella pneumoniae* in captive gold-handed tamarin (*Saguinus midas midas*). *J Med Primatol*. 2016;45(1):42-6.
75. Han BA, Majumdar S, Calmon FP, Glicksberg BS, Horesh R, Perer AKA, Elisa B von Marschall EB, Wei D, Mojsilović A, Varshney KR. Confronting data sparsity to identify potential sources of Zika virus spillover infection among primates. *Epidemics*. 2019;27:59-65.
76. Hatt JM, Grest P, Posthaus H, Bossart W. Serologic survey in a colony of captive common marmosets (*Callithrix jacchus*) after infection with herpes simplex type 1-like virus. *J Zoo Wildl Med*. 2004;35:387-90.
77. Hayashimoto N, Inoue T, Morita H, Yasuda M, Ueno M, Kawai K, Itoh T. Survey and experimental infection of enteropathogenic *Escherichia coli* in common marmosets (*Callithrix jacchus*). *Plos One*. 2016;11(8):e0160116.
78. Herrer A, Christensen HA. Epidemiological patterns of cutaneous leishmaniasis in Panama III. Endemic persistence of the disease. *Am J Trop Med Hyg*. 1976;25:54-8.
79. Hirsh A, Dias LG, Martins LO, Resende NAT, Landau EC. database of georeferenced occurrence localities of neotropical primates. Department of Zoology, UFMG, Belo Horizonte. <http://www.icb.ufmg.br/zoo/primatas/home/bdgeoprim.htm>. 2006.
80. Hodo CL, Wilkerson GK, Birkner EC, Gray SB, Hamer SA. *Trypanosoma cruzi* Transmission Among Captive Nonhuman Primates, Wildlife, and Vectors. *Ecohealth*. 2018;15(2):426-436.
81. Huang R, Liu Q, Li G, Song X, Birtles RJ, Zhao F. *Bartonella quintana* infections in captive monkeys, China. *Emerg Infect Dis*. 2011;17:1707-9.
82. Jesus JG, Gräf T, Giovanetti M, Mares-Guia MA, Xavier J, Maia ML, Fonseca V, Fabri A, Santos RF, Pereira FM, Santos LFO, Silva LRO, Maia ZPG, Cerqueira JXG, Thèze J, Abade L, Cordeiro MCS, Torquato SSC, Santana EB, Silva NSJ, Dourado RSO, Alves AB, Guedes AS, Silva Filho PM, Faria NR, Albuquerque CFC, Abreu AL, Romano APM, Croda J, Said RFC, Cunha GM, Cerqueira JMF, Mello ALES, Filippis AMB, Alcantara LCJ. Yellow fever transmission in non-human primates, Bahia, Northeastern Brazil. *Plos Neglect Trop Dis*. 2020;14(8):e0008405.
83. Juan-Sallés C, Ramos-Vara JA, Prats N, Solé-Nicolás J, Segalés J, Marco AJ. Spontaneous herpes simplex virus infection in common marmosets (*Callithrix jacchus*). *J Vet Diagn Invest*. 1997;9:341-5.
84. Karesh WB, Wallace RB, Painter RLE, Rumiz D, Braselton WE, Dierenfeld ES, Puche H. Immobilization and health assessment of free-ranging black spider monkeys (*Ateles paniscus chamek*). *Am J Primatol*. 1998;44:107-23.
85. Keel MK, Songer JG. The comparative pathology of *Clostridium difficile*-associated Disease. *Vet Pathol*. 2006;43(3):225-40.
86. Kobayashi Y, Sugimoto K, Mochizuki N, Segawa T, Ito T, Carvalho AAB, Nociti DP, Mello RM, Santos AKRA, Ito FH, Sakai T. Isolation of a phylogenetically distinct rabies virus from a tufted capuchin monkey (*Cebus apella*) in Brazil. *Virus Res*. 2013;178(2):535-8.
87. Köhler A, Gottschling M, Manning K, Lehmann MD, Schulz E, Krüger-Corcoran D, Stockfleth E, Nindl I. Genomic characterization of ten novel cutaneous human papillomaviruses from keratotic lesions of immunosuppressed patients. *J Gen Virol*. 2011;92(7):1585-94.
88. Kotait I, Oliveira R de N, Carrieri ML, Castilho JG, Macedo CI, Pereira PMC, Boere V, Montebello L, Rupperecht CE. Non-human primates as a reservoir for rabies virus in Brazil. *Zoonoses Public Hlth*. 2019;66(1):47-59.
89. Lainson R, Braga RR, Souza AA, Pôvoa MM, Ishikawa EA, Silveira FT *Leishmania (Viannia) shawi* sp., a parasite of monkeys, sloths and procyonids in Amazonian Brazil. *Ann Parasitol Hum Comp*. 1989;64(3):200-207.
90. Lainson R, Shaw JJ, Braga RR, Sacawa E, Souza AA, Silveira FT. Isolation of *Leishmania* from monkeys in the Amazon region of Brazil. *Trans Roy Soc Trop Med Hyg*. 1988;82:132.
91. Lalremruata A, Magris M, Vivas-Martínez S, Koehler M, Esen M, Kempaiah P, Jeyaraj S, Perkins DJ, Mordmüller B, Wolfram G Metzger WG. Natural infection of *Plasmodium brasilianum* in humans: Man and monkey share quartan malaria parasites in the Venezuelan Amazon. *EBioMedicine*. 2015;2(9):1186-92.
92. Lanford RE, Chavez D, Brasky KM, Burns RB, Rico-Hesse R. Isolation of a hepadnavirus from the woolly monkey, a New World primate. *Proc National Acad Sci USA*. 1998;95(10):5757-61.
93. Leal SG, Romano APM, Monteiro RV, Melo CB, Vasconcelos PFC, Castro MB. Frequency of histopathological changes in Howler monkeys (*Alouatta* sp.) naturally infected with yellow fever virus in Brazil. *Rev Soc Bras Med Tro*. 2016;49(1):29-33.
94. Leite TNB, Maja TA, Ovando TM, Cantadori DT, Schimidt LR, Guércio AC, Cavalcanti A, Lopes FMR, Cunha IAL, Navarro IT. Ocorrência de infecção por *Leishmania* spp. e *Toxoplasma gondii* em macacos-prego (*Cebus apella*) de Campo Grande, MS. *Rev Bras Parasitol Vet*. 2008;17(1):307-10.
95. Lemos GAA, Pires BG, Mainardi RM, Chideroli RT, Pereira UP, Bracarense APFRL. Spontaneous outbreak of *Yersinia enterocolitica* infection and co-infection with *Escherichia coli* in black-tufted marmosets (*Callithrix penicillata*). *Braz J Vet Pathol*, 2021;14(3):173-9.

96. Lewis J, Smith G, White V. An outbreak of botulism in captive hamadryas baboons (*Papio hamadryas*). Vet Rec. 1990;126(9):216.
97. Li H, Bai JY, Wang LY, Zeng L, Shi YS, Qiu ZL, Ye HH, Zhang XF, Lu QB, Kosoy M, Liu W, Cao WC. Genetic diversity of *Bartonella quintana* in macaques suggests zoonotic origin of trench fever. Mol. Ecol. 2013;22:2118-27.
98. Lima VM, Santiago ME, Sanches LC, Lima BD. Molecular diagnosis of *Leishmania amazonensis* in a captive spider monkey in Bauru, São Paulo, Brazil. J Zoo Wildl Med. 2012;43(4):943-5.
99. Lisboa CV, Mangia RH, Lima NRCD, Martins A, Dietz J, Baker AJ, Ramon-Miranda CR, Ferreira LF, Fernandes O, Jansen AM. Distinct patterns of *Trypanosoma cruzi* infection in *Leontopithecus rosalia* in distinct Atlantic Coastal Rainforest fragments in Rio de Janeiro – Brazil. Parasitology. 2004;129(6):703-11.
100. Litvoc MN, Novaes CTG, Lopes MIBF. Yellow fever. Rev Assoc Med Bras. 2018;64(2):106-13.
101. Lombardi MC, Turchetti AP, Tinoco HP, Pessanha AT, Soave SA, Malta MCC, Paixão TA, Santos RL. Diagnosis of *Leishmania infantum* infection by polymerase chain reaction in wild mammals. Pesq Vet Bras. 2014;34:1243-6.
102. Longa CS, Bruno SF, Pires AR, Romijn PC, Kimura LS, Costa CH. Human herpesvirus 1 in wild marmosets, Brazil, 2008. Emerg Infect Dis. 2011;17:1308-10.
103. Loza-Rubio E, Rojas-Anaya E, López-Ramírez RDC, Saiz JC, Escribano-Romero E. Prevalence of neutralizing antibodies against West Nile virus (WNV) in monkeys (*Ateles geoffroyi* and *Alouatta pigra*) and crocodiles (*Crocodylus acutus* and *C. acutus*–*C. moreletti hybrids*) in Mexico. Epidemiol Infect. 2016;144(11):2371-3.
104. Lu S, Zhao Y, Yu W, Yang Y, Gao J, Wang J, Kuang D, Yang M, Yang J, Ma C, Xu J, Qian X, Li H, Zhao S, Li J, Wang H, Long H, Zhou J, Luo F, Ding K, Wu D, Zhang Y, Dong Y, Liu Y, Zheng Y, Lin X, Jiao L, Zheng H, Dai Q, Sun Q, Hu Y, Ke C, Liu H, Peng X. Comparison of nonhuman primates identified the suitable model for COVID-19. Signal Transduct Target Ther. 2020;5:157.
105. Ludlage E, Mansfield KG. Clinical care and diseases of the common marmoset (*Callithrix jacchus*). Comp Med. 2003;53:369-82.
106. Lyra MR, Oliveira LB, Silva EE. Herpes simplex virus transmission following brown howler monkey (*Alouatta guariba*) bite. Rev Soc Bras Med Trop. 2019;52:e20180218.
107. Machado GP, Antunes JMAP, Uieda W, Biondo AW, Cruvinel TMA, Kataoka AP, Martorelli LFA, Jong D, Amaral JMG, Hoppe EGL, Guerra Neto G, Megid J. Exposure to rabies virus in a population of free-ranging capuchin monkeys (*Cebus apella nigrurus*) in a fragmented, environmentally protected area in southeastern Brazil. Primates. 2012;53(3):227-31.
108. Mafra C, Barcelos RM, Mantovani C, Carrizo J, Soares AC, Moreira HNS, Maia NL, Silva FFR, Silva VHD, Boere V, Silva IO. Occurrence of *Ehrlichia canis* in free-living primates of the genus *Callithrix*. Rev Bras Parasitol Vet. 2015;24(1):78-81.
109. Malta M, Tinoco HP, Xavier MN, Vieira A, Costa EA, Santos RL. Naturally acquires visceral leishmaniasis in non-human primates in Brazil. Vet Parasitol. 2010;169:193-7.
110. Mansfield KG, Fox JG. Bacterial diseases. In: Marini R, Wachtman L, Tardif S, Mansfield K, Fox J (Eds). The common marmoset in captivity and biomedical research. Elsevier: Missouri, 2019, 265-87.
111. Mansfield KG, Lin KC, Xia D, Newman JV, Schauer DB, MacKey J, Lackner AA, Carville A. Enteropathogenic *Escherichia coli* and ulcerative colitis in cotton-top tamarins (*Saguinus oedipus*). J Infect Dis. 2001;184(6):803-7.
112. Martínez MF, Kowalewski MM, Giuliani MG, Acardi SA, Salomón OD. Molecular identification of *Leishmania* in free-ranging black and gold howler monkeys (*Alouatta caraya*) in northeastern Argentina. Acta Trop. 2020;210:105534.
113. Martínez MF, Kowalewski MM, Salomón OD, Schijman AG. Molecular characterization of trypanosomatid infections in wild howler monkeys (*Alouatta caraya*) in northeastern Argentina. Int J Parasitol Parasites Wildl. 2016;5(2):198-206.
114. Mätz-Rensing K, Ellerbrok H, Ehlers B, Pauli G, Floto A, Alex M, Czerny CP, Kaup FJ. Fatal poxvirus outbreak in a colony of New World Monkeys. Vet Pathol. 2006;43:212-8.
115. Mätz-Rensing K, Jentsch KD, Rensing S, Langenhuyzen S, Verschoor E, Niphuis H, Kaup FJ. Fatal herpes simplex infection in a group of common marmosets (*Callithrix jacchus*). Vet Pathol. 2003;40:405-11.
116. Mätz-Rensing K, Lowenstine. New World and Old World monkeys. In: Terio KA, McAloose D, Leger JS. Pathology of wildlife and zoo animals. Elsevier Inc: Cambridge. 2018;343-74.
117. Mätz-Rensing K, Winkelmann J, Becker T, Burckhardt I, van der Linden M, Köndgen S, Leendertz F, Kaup FJ. Outbreak of *Streptococcus equi* subsp. *zooepidemicus* infection in a group of rhesus monkeys (*Macaca mulatta*). J Med Primatol. 2009;38:328-34.
118. McCoy CS, Mannion AJ, Feng Y, Madden CM, Artim SC, Au GG, Dolan M, Haupt JL, Burns MA, Sheh A, Fox JG. Cytotoxic *Escherichia coli* strains encoding colibactin, cytotoxic necrotizing factor, and cytolethal distending toxin colonize laboratory common marmosets (*Callithrix jacchus*). Sci Rep. 2021;11(1):2309.
119. Measles & Rubella Initiative. Measles and rubella strategic framework 2021–2030. 1st ed. Geneva: 2021.
120. Medkour H, Davoust B, Levasseur A, Mediannikov O. Molecular Evidence of *Leishmania infantum* and *Leishmania guyanensis* in red howler monkey (*Alouatta seniculus*) from French Guiana. Vector Borne Zoonotic Dis. 2019;19(12):896-900.

121. Melendez LV, Hunt RD, King NW, Barahona HH, Daniel MD, Fraser CE, Garcia FG. Herpesvirus ateles, a new lymphoma virus in monkeys. *Nat New Biol.* 1972;235:182-4.
122. Mello MFV, Monteiro ABS, Fonseca EC, Pissinatti A, Ferreira AMR. Identification of *Helicobacter* sp. in gastric mucosa from captive marmosets (*Callithrix* sp.; callitrichidae, primates). *Am J Primatol.* 2005;66(2):111-8.
123. Melo CMF, Daneze ER, Mendes NS, Ramos IAS, Morales-Donoso JA, Fernandes SJ, Machado RZ, André MR, Sobreira MFR. Genetic diversity and hematological and biochemical alterations in *Alouatta* primates naturally infected with hemoplasmas in Brazil. *Comp Immunol Microbiol Infect Dis.* 2019;63:104-11.
124. Menezes-Costa A, Machado-Ferreira E, Voloch CM, Bonvicino CR, Seuánez HN, Leoncini O, Soares CA. Identification of bacterial infection in neotropical primates. *Microbial Ecol.* 2013;66(2):471-8.
125. Minuzzi-Souza TTC, Nitz N, Knox MB, Reis F, Hagström L, Cuba CAC, Hecht MM, Gurgel-Gonçalves R. Vector-borne transmission of *Trypanosoma cruzi* among captive Neotropical primates in a Brazilian zoo. *Parasite Vector.* 2016;9(1):39.
126. Miranda TS, Muniz CP, Moreira SB, Bueno MG, Kierulff MCM, Molina CV, Catão-Dias JL, Pissinatti A, Soares MA, Santos AF. Eco-epidemiological profile and molecular characterization of simian foamy virus in a recently-captured invasive population of *Leontopithecus chrysomelas* (golden-headed lion tamarin) in Rio de Janeiro, Brazil. *Viruses.* 2019;11(10):931.
127. Molina CV, Bueno MG, Kierulff MCM, Pissinatti A, Cunha MPV, Knöbl T, Catão-Dias JL, Díaz-Delgado J. Spontaneous meningoencephalitis by *Staphylococcus aureus* in an infant golden-headed lion tamarin (*Leontopithecus chrysomelas*). *J Med Primatol.* 2019;48(6):370-3.
128. Molina CV, Catão-Dias JL, Ferreira Neto JS, Vasconcellos SA, Gennari SM, Valle RDR, Souza GO, Morais ZM, Vitaliano SN, Strefezzi RF, Bueno MG. Sero-epidemiological survey for brucellosis, leptospirosis, and toxoplasmosis in free-ranging *Alouatta caraya* and *Callithrix penicillata* from São Paulo State, Brazil. *J Med Primatol.* 2014;43(3):197-201.
129. Molina CV, Heinemann MB, Kierulff C, Pissinatti A, Silva TF, Freitas DG, Souza GO, Miotto BA, Cortez A, Semensato BP, Moreno LZ, Catão-Dias JL, Bueno MG. *Leptospira* spp., rotavirus, norovirus, and hepatitis E virus surveillance in a wild invasive golden-headed lion tamarin (*Leontopithecus chrysomelas*; Kuhl, 1820) population from an urban park in Niterói, Rio de Janeiro, Brazil. *Am J Primatol.* 2019;81(3):e22961.
130. Molina CV, Krawczak F da S, Bueno MG, Soares HS, Genari SM, Pissinatti A, Kierulff MCM, Silva TF, Freitas DG, Caneli LC, Catão-Dias JL. Negative serosurvey of *Toxoplasma gondii* antibodies in Golden-headed Lion Tamarin (*Leontopithecus chrysomelas*) from Niterói/RJ, Brazil. *Rev Bras Parasitol Vet.* 2016;26:115-8.
131. Montali RJ, Mikota SK, Cheng LI. *Mycobacterium tuberculosis* in zoo and wildlife species. *Rev Sci Tech.* 2001;20(1):291-303.
132. Monteiro RV, Baldez J, Dietz J, Baker A, Lisboa CV, Jansen AM. Clinical, biochemical, and electrocardiographic aspects of *Trypanosoma cruzi* infection in free-ranging golden lion tamarins (*Leontopithecus rosalia*). *J Med Primatol.* 2006;35(1):48-55.
133. Monteiro RV, Dietz JM, Jansen AM. The impact of concomitant infections by *Trypanosoma cruzi* and intestinal helminths on the health of wild golden and golden-headed lion tamarins. *Res Vet Sci.* 2010;89(1):27-35.
134. Morales MA, Fabbri CM, Zunino GE, Kowalewski MM, Luppó VC, Enría DA, Levis SC, Calderón GE. Detection of the mosquito-borne flaviviruses, West Nile, Dengue, Saint Louis Encephalitis, Ilheus, Bussuquara, and Yellow Fever in free-ranging black howlers (*Alouatta caraya*) of Northeastern Argentina. *Plos Neglect Trop Dis.* 2017;11(2):e0005351.
135. Moreno ES, Agostini I, Holzmann I, Bitetti MS, Oklander LI, Kowalewski MM, Beldomenico PM, Goenaga S, Martínez M, Lestani E, Desbiez ALJ, Miller P. Yellow fever impact on brown howler monkeys (*Alouatta guariba clamitans*) in Argentina: a metamodelling approach based on population viability analysis and epidemiological dynamics. *Mem Inst Oswaldo Cruz.* 2015;110(7):865-76.
136. Moutinho FFB, Andrade MGA de, Nunes VMA, Rubião ECN, Batista HBCR, Romijn PC, Cattaneo CA, Oliveira FG, Oliveira RN, Marcanth N, Silvestre LGGR, Borges FVB, Bruno SF. Rabies in *Callithrix* sp. in the urban area of Niterói, Rio de Janeiro, Brazil. *Rev Soc Bras Med Trop.* 2020;53:e20190402.
137. Muniz CP, Cavalcante LTF, Dudley DM, Pissinatti A, O'Connor DH, Santos AF, Soares MA. First complete genome sequence of a simian foamy virus infecting the neotropical primate *Brachyteles arachnoides*. *Microbiol Resour Announc.* 2018;7(2):e00839-18.
138. Muniz CP, Cavalcante LTF, Jia H, Zheng HQ, Tang S, Augusto AM, Pissinatti A, Fedullo LP, Santos AF, Soares MA, Switzer WM. Zoonotic infection of Brazilian primate workers with New World simian foamy virus. *Plos One.* 2017;12(9):e0184502.
139. Muniz CP, Jia H, Shankar A, Troncoso LL, Augusto AM, Farias E, Pissinatti A, Fedullo LP, Santos AF, Soares MA, Switzer WM. An expanded search for simian foamy viruses (SFV) in Brazilian New World primates identifies novel SFV lineages and host age-related infections. *Retrovirology.* 2015;12(1):94.
140. Nakamura S, Hayashidani H, Iwata T, Namai S, Une Y. Pathological changes in captive monkeys with spontaneous yersiniosis due to infection by *Yersinia enterocolitica* serovar O8. *J Comp Pathol.* 2010;143:150-6.

141. Neimark H, Barnaud A, Gounon P, Michel JC, Contamin H, The putative haemobartonella that influences *Plasmodium falciparum* parasitemia in squirrel monkeys is a haemotrophic *Mycoplasma*. *Microbes Infect.* 2002;4:693-8.
142. Neves JJ, Francelino M, Silva FG, Baptista LCI, Bueno MG, Catão-Dias JL, Molina C, Kierulff MCM, Pissinatti A, Coutinho SDA. Survey of *Malassezia* sp and dermatophytes in the cutaneous microbiome of free-ranging golden-headed lion tamarins (*Leontopithecus chrysomelas* - Kuhl, 1820). *J Med Primatol.* 2017;46(3):65-9.
143. Niehaus C, Spínola M, Su C, Rojas N, Rico-Chávez O, Ibarra-Cerdeña CN, Foley J, Suzán G, Gutiérrez-Espeleta GA, Chaves A. Environmental factors associated with *Toxoplasma gondii* exposure in neotropical primates of Costa Rica. *Frontiers Vet Sci.* 2020;7:583032.
144. Nishimura M, Goyama T, Tomikawa S, Fereig RM, El-Alfy EN, Nagamune K, Kobayashi Y, Nishikawa Y. Outbreak of toxoplasmosis in four squirrel monkeys (*Saimiri sciureus*) in Japan. *Parasitol Int.* 2019;68(1):79-86.
145. Nunes AJD, Alvarenga DAM, Souza Junior JC, Peruchi AR, Gonçalves GHP, Hirano ZMB, Brito CFA, Cremer MJ. *Plasmodium infection* and its association with biochemical and haematological parameters in free-living *Alouatta guariba clamitans* (Cabrera, 1940) (Primates: Atelidae) in Southern Brazil. *Mem Inst Oswaldo Cruz.* 2020;114:e190210.
146. Oliveira AR. Disease investigation in free-ranging neotropical primates from the Brazilian Atlantic Forest. Tese (Doutorado em Ciência Animal) – Universidade Federal de Minas Gerais, Belo Horizonte, 2022.
147. Oliveira AR, Castro M, Pimentel SP, Carvalho TP, Santana CH, Santos DO, Tinoco HP, Coelho CM, Pessanha AT, Paixão TA, Santos RL. *Streptococcus pasteurianus*-induced valvular endocarditis and sepsis in a puerperal emperor tamarin (*Saguinus imperator*). *J Med Primatol.* 2022;51(6):388-391.
148. Oliveira AR, Hiura E, Guião-Leite FL, Flecher MC, Braga FR, Silva LPC, Sena T, Souza TD. Pathological and parasitological characterization of *Prosthenorchis elegans* in a free-ranging marmoset *Callithrix geoffroyi* from the Brazilian Atlantic Forest. *Pesq Vet Bras.* 2017;37(12):1514-18.
149. Oliveira AR, Pereira FMAM, Santos DO, Carvalho TP, Soares-Neto LL, Mangueira DKA, Lisboa LM, Mamede RB, Hoppe EGL, Momo C, Santos RL. Epidemiological, clinical and pathological aspects of lethal acanthocephalosis in captive neotropical primates. *J Med Primatol.* 2021;50(6):313-22.
150. Oliveira AR, Pinheiro GRG, Tinoco HP, Loyola ME, Coelho CM, Dias ES, Monteiro EM, Silva FOL, Pessanha AT, Souza AGM, Pereira NCL, Gontijo NF, Fujiwara RT, Paixão TA, Santos RL. Competence of non-human primates to transmit *Leishmania infantum* to the invertebrate vector *Lutzomyia longipalpis*. *Plos Neglect Trop Dis.* 2019;13(4):e0007313.
151. Oliveira AR, Ritter JR, Santos DO, Lucena FP, Mattos SA, Carvalho TP, Bullock H, Moreira LGA, Vasconcelos IMA, Costa FB, Paixão TA, Santos RL. Pathology and epidemiology of fatal toxoplasmosis in free-ranging marmosets (*Callithrix* spp.) from the Brazilian Atlantic forest. *PLoS Negl Trop Dis.* 2022;16(9):e0010782.
152. Olsen SC, Palmer MV. Advancement of knowledge of *Brucella* over the past 50 years. *Vet Pathol.* 2014;51(6):1076-89.
153. O'Rourke LG, Pitulle C, Hegarty BC, Kraycirik S, Killary KA, Grosenstein P, Brown JW, Breitschwerdt EB. *Bartonella quintana* in cynomolgus monkey (*Macaca fascicularis*). *Emerg Infect Dis.* 2005;11:1931-4.
154. Paiz LM, Motoie G, Richini-Pereira VB, Langoni H, Menozzi BD, Tolezano JE, Donalisio MR. Antibodies and molecular detection of *Leishmania (Leishmania) infantum* in samples of free-ranging marmosets (Primates: Callitrichidae: *Callithrix* spp.) in an area of canine visceral leishmaniasis in Southeastern Brazil. *Vector Borne Zoonotic Dis.* 2019;19(4):249-54.
155. Paula NF, Dutra KS, Oliveira AR, Santos DO, Rocha CEV, Vitor RWA, Tinoco HP, Costa MELT, Paixão TA, Santos RL. Host range and susceptibility to *Toxoplasma gondii* infection in captive neotropical and Old-world primates. *J Med Primatol.* 2020;49(4):202-10.
156. Pereira AH, Vasconcelos AL, Silva VL, Nogueira BS, Silva ACP, Pacheco RC, Souza MA, Colodel EM, Ubiali DG, Biondo AW, Nakazato L, Dutra V. Natural SARS-CoV-2 Infection in a free-ranging black-tailed marmoset (*Mico melanurus*) from an urban area in mid-west Brazil. *J Comp Pathol.* 2022;194:22-7.
157. Pereira FV, Lucena FP, Rodrigues RL, Barros LA, Pires CA, Ferreira AMR, Mello MFV. Prevalence and spatial distribution of the occurrence of helminths in free-living nonhuman primates in the State of Rio de Janeiro, Brazil. *Arq Bras Med Vet Zootec.* 2020;72(5):1705-12.
158. Petit T. Seasonal outbreaks of botulism in captive South American monkeys. *Vet Rec.* 1991;128(13):311-2.
159. Pinto-Santini DM, Stenbak CR, Linial ML. Foamy virus zoonotic infections. *Retrovirology.* 2017;14(1):55.
160. Pisharath HR, Cooper TK, Brice AK, Cianciolo RE, Pistorio AL, Wachtman LM, Mankowski JL, Newcomer CE. Septicemia and peritonitis in a colony of common marmosets (*Callithrix jacchus*) secondary to *Klebsiella pneumoniae* infection. *Contemp Top Lab Anim Sci.* 2005;44(1):35-7.
161. Psarros G, Riddell J, Gandhi T, Kauffman CA, Cinti SK. *Bartonella henselae* infections in solid organ transplant recipients: report of 5 cases and review of the literature. *Medicine (Baltimore).* 2012;91:111-21.
162. Ramer JC, Garber RL, Steele KE, Boyson JF, O'Rourke C, Thomson JA. Fatal lymphoproliferative disease associated with a novel gammaherpesvirus in a captive colony of common marmosets. *Lab Anim Sci.* 2000;60:59-68.

163. Rao AK, Sobel J, Chatham-Stephens K, Luquez C. Clinical guidelines for diagnosis and treatment of botulism, 2021. *MMWR Recomm Rep*. 2021;70(2):1-30.
164. Ricciardi ID, Nunes MP, Andrade CM, Da Silva AG. Anti-*Brucella* agglutinins in bats and “*Callithrix*” monkeys. *J Wildl Dis*. 1976;12(1):52-4.
165. Rocha TC, Batista PM, Andreotti R, Bona ACD, Silva MAN, Lange R, Svoboda WS, Gomes EC. Evaluation of arboviruses of public health interest in free-living non-human primates (*Alouatta* spp., *Callithrix* spp., *Sapajus* spp.) in Brazil. *Rev Soc Bras Med Trop*. 2015;48(2):143-8.
166. Rockx B, Kuiken T, Herfst S, Bestebroer T, Lamers MM, Munnink BBO, Meulder D, van Amerongen G, van den Brand J, Okba NMA, Schipper D, van Run P, Leijten L, Sikkema R, Verschoor E, Verstrepen B, Bogers W, Langermans J, Drosten C, van Vlissingen MF, Fouchier R, Swart R, Koopmans M, Haagmans BL. Comparative pathogenesis of COVID-19, MERS, and SARS in a nonhuman primate model. *Science*. 2020;368:1012-5.
167. Rogers DL, Ruiz JC, Baze WB, McClure GB, Smith C, Urbanowski R, Boston T, Simmons JH, Williams L, Abee CR, Vanchiere JA. Epidemiological and molecular characterization of a novel adenovirus of squirrel monkeys after fatal infection during immunosuppression. *Microb Genom*. 2020;6(9):mgen000395.
168. Rondón S, Cavallero S, Renzi E, Link A, González C, D'Amelio S. Parasites of free-ranging and captive American primates: a systematic review. *Microorganisms*. 2021;9(12):2546.
169. Rondón S, León C, Link A, González C. Prevalence of *Plasmodium* parasites in non-human primates and mosquitoes in areas with different degrees of fragmentation in Colombia. *Malaria J*. 2019;18(1):276.
170. Rondón S, Ortiz M, León C, Galvis N, Link A, González C. Seasonality, richness and prevalence of intestinal parasites of three neotropical primates (*Alouatta seniculus*, *Ateles hybridus* and *Cebus versicolor*) in a fragmented forest in Colombia. *Int J Parasitol Parasites Wildl*. 2017;6(3):202-8.
171. Rosenbaum M, Mendoza P, Ghersi BM, Wilbur AK, Perez-Brumer A, Yong NC, Kasper MR, Montano S, Zunt JR, Jones-Engel L. Detection of *Mycobacterium tuberculosis* complex in New World monkeys in Peru. *Ecohealth*. 2015;12(2):288-97.
172. Roviroso-Hernández MDJ, Cortes-Ortíz L, García-Orduña F, Guzmán-Gómez D, López-Monteon A, Caba M, Ramos-Ligonio A. Seroprevalence of *Trypanosoma cruzi* and *Leishmania mexicana* in Free-Ranging Howler Monkeys in Southeastern Mexico. *Am J Primatol*. 2013;75(2):161-9.
173. Roviroso-Hernández MJ, López-Monteon A, García-Orduña F, Torres-Montero J, Guzmán-Gómez D, Dumonteil E, Waleckx E, Lagunes-Merino O, Canales-Espinoza D, Ramos-Ligonio A. Natural infection with *Trypanosoma cruzi* in three species of non-human primates in southeastern Mexico: A contribution to reservoir knowledge. *Acta Trop*. 2021;213:105754.
174. Rylands AB, Mittermeier RA, Silva JS. Neotropical primates: taxonomy and recently described species and subspecies. *Int Zoo Yearb*. 2011;46(1):11-24.
175. Sacchetto L, Chaves BA, Costa ER, Medeiros ASM, Gordo M, Araújo DB, Oliveira DBL, Silva APB, Negri AF, Durigon EL, Hanley KA, Vasilakis N, Lacerda MVG, Nogueira ML. Lack of evidence of severe acute respiratory syndrome Coronavirus 2 (SARS-CoV-2) spillover in free-living neotropical non-human primates, Brazil. *Viruses*. 2021;13(10):1933.
176. Sanchez-Fernandez C, Bolatti EM, Culasso ACA, Chouhy D, Kowalewski MM, Stella EJ, Schurr TG, Rinas MA, Liotta DJ, Campos RH, Giri AA, Badano I. Identification and evolutionary analysis of papillomavirus sequences in New World monkeys (genera *Sapajus* and *Alouatta*) from Argentina. *Arch Virol*. 2022;167(5):1257-1268.
177. Santana CH, Oliveira AR, Santos DO, Pimentel SP, Souza LR, Moreira LGA, Braz HMB, Carvalho TP, Lopes CEB, Oliveira JBS, Paula NF, Carvalho MPN, Alves BF, Pena HFJ, Santos RL. Genotyping of *Toxoplasma gondii* in a lethal toxoplasmosis outbreak affecting captive howler monkeys (*Alouatta* sp.). *J Med Primatol*. 2021;50(2):99-107.
178. Santos AF, Cavalcante LTF, Muniz CP, Switzer WM, Soares MA. Simian foamy viruses in Central and South America: a New World of discovery. *Viruses*. 2019;11(10):967.
179. Santos AVP, Souza AM, Bueno MG, Catao-Dias JL, Toma HK, Pissinati A, Molina CV, Kierulff MCM, Silva DGF, Almosny NRP. Molecular detection of *Borrelia burgdorferi* in free-living golden headed lion tamarins (*Leontopithecus chrysomelas*) in Rio de Janeiro, Brazil. *Rev Inst Med Trop Sao Paulo*. 2018;60:e53.
180. Santos DO, Oliveira AR, Lucena FP, Mattos SA, Carvalho TP, Costa FB, Moreira LGA, Paixão TA, Santos RL. Histopathologic patterns and susceptibility of neotropical primates naturally infected with yellow fever virus. *Vet Pathol*. 2020;57(5):681-6.
181. Santos LC, Cubilla MP, Moraes W, Cubas ZS, Marcos J Oliveira MJ, Estrada M, Leutenegger CM, Sykes JE, Lindsay LL, Marcondes M, Barros Filho IR, Biondo AW. Hemotropic mycoplasma in a free-ranging black howler monkey (*Alouatta caraya*) in Brazil. *J Wildl Dis*. 2013;49:728-31.
182. Santos RL, Oliveira AR. Leishmaniasis in non-human primates: clinical and pathological manifestations and potential as reservoirs. *J Med Primatol*. 2020;49(1):34-9.
183. Santos SV, Pena HFJ, Talebi MG, Teixeira RHF, Kanamura CT, Diaz-Delgado J, Gennari SM, Catão-Dias JL. Fatal toxoplasmosis in a southern miquiqui (*Brachyteles arachnoides*) from São Paulo state, Brazil: Pathological, immunohistochemical, and molecular characterization. *J Med Primatol*. 2018;47(2):124-7.

184. Sashida H, Suzuki Y, Rokuhara S, Nagai K, Harasawa R. Molecular demonstration of hemotropic mycoplasmas in wild Japanese monkeys (*Macaca fuscata*). *J Vet Med Sci.* 2014;76:97-101.
185. Schiller CA, Wolff MJ, Munson L, Montali RJ. *Streptococcus zooepidemicus* infections of possible horsemeat source in red-bellied tamarins and Goeldie's monkeys. *J Zoo Wildl Med.* 1989;20:322-7.
186. Schlabritz-Loutsevitch NE, Whatmore AM, Quance CR, Koylass MS, Cummins LB, Dick Jr EJ, Snider CL, Cappelli D, Ebersole JL, Nathanielsz PW, Hubbard GB. A novel *Brucella* isolate in association with two cases of still- birth in non-human primates – first report. *J Med Primatol.* 2009;38(1):70-3.
187. Schrenzel MD, Osborn KG, Shima A, Klieforth RB, Maalouf GA. Naturally occurring fatal herpes simplex virus 1 infection in a family of white-faced saki monkeys (*Pithecia pithecia pithecia*). *J Med Primatol.* 2003;32:7-14.
188. Setzer AP, Gaspar AMC, Sidoni M, Bueno MG, Catão-Dias JL. Serosurvey for hepatitis A in neotropical primates in southeast Brazil. *J Med Primatol.* 2014;43(3):202-5.
189. Sharp CP, LeBreton M, Kantola K, Nana A, Diffo Jle D, Djoko CF, Tamoufe U, Kiyang JA, Babila TG, Ngole EM, Pybus OG, Delwart E, Delaporte E, Peeters M, Soderlund-Venermo M, Hedman K, Wolfe ND, Simmonds P. Widespread infection with homologues of human parvoviruses B19, PARV4, and human bocavirus of chimpanzees and gorillas in the wild. *J Virol.* 2010;84(19):10289-96.
190. Shen Z, Feng Y, Sheh A, Everitt J, Bertram F, Paster BJ, Fox JG. Isolation and characterization of a novel *Helicobacter* species, *Helicobacter jaachi* sp. nov., from common marmosets (*Callithrix jacchus*). *J Med Microbiol.* 2015;64:1063e73.
191. Shet A, Carr K, Danovaro-Holliday MC, Sodha SV, Prospero C, Wunderlich J, Wonodi C, Reynolds HW, Mirza I, Gacic-Dobo M, O'Brien KL, Lindstrand A. Impact of the SARS-CoV-2 pandemic on routine immunisation services: evidence of disruption and recovery from 170 countries and territories. *Lancet Glob Health.* 2022;10(2):e186-e194.
192. Shostell JM, Ruiz-García M. An introduction to the biodiversity of the neotropical primates. In: Phylogeny, molecular population genetics, evolutionary biology and conservation of the neotropical primates. Ruiz-García M, Shostell JM Eds. Nova Science Publisher: New York, 2016:5975.
193. Silva FM, Naiff RD, Marcili A, Gordo M, D'Afonseca JA No, Naiff MF, Franco AMR, Campaner M, Valente V, Valente SA, Camargo EP, Teixeira MMG, Miles MA. Infection rates and genotypes of *Trypanosoma rangeli* and *T. cruzi* infecting free-ranging *Saguinus bicolor* (Callitrichidae), a critically endangered primate of the Amazon Rainforest. *Acta Trop.* 2008;107(2):168-73.
194. Silva KSM, Silva RJ, Pereira WLA. Occurrence of infection by *Platynosomum illiciens* (Braun, 1901) in captive neotropical primates. *Primates.* 2012;53:79-82.
195. Silva MIV, Bento HJ, Maruyama FH, Rosa JMA, Mesquita MCSR, Pavelegini LAD, Morgado TO, Colodel EM, Nakazato L, Dutra V. *Pasteurella canis* infection in a non-human primate black-tailed marmoset (*Mico melanurus*) - a case report. *J Med Primatol.* 2020;49(2):107-9.
196. Silva NIO, Sacchetto L, Rezende IM, Trindade GS, LaBeaud AD, Thoisy B, Drumond BP. Recent sylvatic yellow fever virus transmission in Brazil: the news from an old disease. *Virology.* 2020;17(1):9.
197. Silva ROS, Martins RA, Assis RA, Oliveira Junior CA, Lobato FCF. Type C botulism in domestic chickens, dogs and black-pencilled marmoset (*Callithrix penicillata*) in Minas Gerais, Brazil. *Anaerobe.* 2018;51:47-49.
198. Silva TMR, Sá ACMGN, Vieira EWR, Prates EJS, Beininger MA, Matozinhos FP. Number of doses of Measles-Mumps-Rubella vaccine applied in Brazil before and during the COVID-19 pandemic. *BMC Infect Dis.* 2021;21(1):1237.
199. Silvestre RV, Souza AJ, Sousa Júnior EC, Silva AK, Mello WA, Nunes MR, Júnior JLSGV, Cardoso JF, Vasconcelos JM, Oliveira LF, Silva SP, Silva AMJ, Fries BG, Summa MEL, Sá LRM. First new world primate papillomavirus identification in the Atlantic Forest, Brazil: *Alouatta guariba papillomavirus 1*. *Genome Announc.* 2016;4(4):e00725-16.
200. Simon M. Simian parvoviruses: Biology and implications for research. *Comp Med.* 2008;58(1):47-50.
201. Singh DK, Singh B, Ganatra SR, Gazi M, Cole J, Thippeshappa R, Alfson KJ, Clemmons E, Gonzalez O, Escobedo R, Lee TH, Chatterjee A, Goetz-Gazi Y, Sharan R, Gough M, Alvarez C, Blakley A, Ferdin J, Bartley C, Staples H, Parodi L, Callery J, Mannino A, Klaffke B, Escareno P, Platt RN 2nd, Hodara V, Scordo J, Gautam S, Vilanova AG, Olmo-Fontanez A, Schami A, Oyejide A, Ajithdoss DK, Copin R, Baum A, Kyratsous C, Alvarez X, Ahmed M, Rosa B, Goodroe A, Dutton J, Hall-Ursone S, Frost PA, Voges AK, Ross CN, Sayers K, Chen C, Hallam C, Khader SA, Mitreva M, Anderson TJC, Martinez-Sobrido L, Patterson JL, Turner J, Torrelles JB, Dick EJ Jr, Brasky K, Schlesinger LS, Giavedoni LD, Carrion R Jr, Kaushal D. Responses to acute infection with SARS-CoV-2 in the lungs of rhesus macaques, baboons and marmosets. *Nat Microbiol.* 2021;6:73-86.
202. Solórzano-García B, Pérez-Ponce de León G. Helminth parasites of howler and spider monkeys in Mexico: Insights into molecular diagnostic methods and their importance for zoonotic diseases and host conservation. *Int J Parasitol Parasites Wildl.* 2017;6(2):76-84.
203. Sousa MBC, Leão AC, Coutinho JFV, Ramos AMO. Histopathology findings in common marmosets (*Callithrix jacchus* Linnaeus, 1758) with chronic weight loss associated with bile tract obstruction by infestation with *Platynosomum* (Loos, 1907). *Primates.* 2008;49:283-7.

204. Souza AJS, Coutinho LN, Silva WB, Imbeloni AA, Carneiro LA, Kanashiro-Galo L, Hagen SCF, Malheiros AP, Sá LRM. Hepatic lesions in captive owl monkeys (*Aotus inflatus*) with ultrasonographic “starry sky” liver. *J Med Primatol*. 2021;50(5):240-8.
205. Svoboda WK, Martins LC, Malanski L de S, Shiozawa MM, Spohr KAH, Hilst CLS, Aguiar LM, Ludwig G, Passos FC, Silva LR, Headley SA, Navarro IT. Serological evidence for Saint Louis encephalitis virus in free-ranging New World monkeys and horses within the upper Paraná River basin region, Southern Brazil. *Rev Soc Bras Med Trop*. 2014;47(3):280-6.
206. Svoboda WK, Soares MDCP, Alves MM, Rocha TC, Gomes EC, Menoncin F, Batista PM, Silva LR, Headley SA, Hilst CLS, Aguiar LM, Ludwig G, Passos FC, Souza Jr JC, Navarro IT. Serological Detection Of Hepatitis A Virus In Free-Ranging Neotropical Primates (*Sapajus* spp., *Alouatta caraya*) From The Paraná River Basin, Brazil. *Rev Inst Med Trop Sao Paulo*. 2016;58:9.
207. Strier KB, Tabacow FP, Possamai CB, Ferreira AIG, Nery MS, Melo FR, Mendes SL. Status of the northern muriqui (*Brachyteles hypoxanthus*) in the time of yellow fever. *Primates*. 2019;60(1):21-8.
208. Tavela AO, Fuzessy LF, Silva VHD, Silva FFR, Carretta Junior M, Silva IO, Souza VB. Helminths of wild hybrid marmosets (*Callithrix* sp.) living in an environment with high human activity. *Rev Bras Parasitol Vet*. 2013;22(3):391-7.
209. Terzian ACB, Zini N, Sacchetto L, Rocha RF, Parra MCP, Sarto JLD, Dias ACF, Coutinho F, Rayra J, Silva RA, Costa VV, Fernandes NCCA, Réssio R, Díaz-Delgado J, Guerra J, Cunha MS, Catão-Dias JL, Bittar C, Reis AFN, Santos INP, Ferreira ACM, Cruz LEAA, Rahal P, Ullmann L, Malossi C, Araújo Jr JP, Widen S, Rezende IM, Mello E, Pacca CC, Kroon EG, Trindade G, Drumond B, Chiaravalloti-Neto F, Vasilakis N, Teixeira MM, Nogueira ML. Evidence of natural Zika virus infection in neotropical non-human primates in Brazil. *Sci Rep*. 2018;8(1):16034.
210. Thoisy B, Pouliquen JF, Lacoste V, Gessain A, Kazanjil M. Novel Gamma-1 Herpesviruses Identified in Free-Ranging New World Monkeys (Golden-Handed Tamarin [*Saguinus midas*], Squirrel Monkey [*Saimiri sciureus*], and White-Faced Saki [*Pithecia pithecia*]) in French Guiana. *J Virol*. 2003;77(16):9099-105.
211. Thomson JA, Scheffler JJ. Hemorrhagic typhlocolitis associated with attaching and effacing *Escherichia coli* in common marmosets. *Lab Anim Sci*. 1996;46(3):275-9.
212. Trüeb I, Portela RD, Franke CR, Carneiro IO, Ribeiro GJ Jr, Soares RP, Barrouin-Melo SM. *Trypanosoma cruzi* and *Leishmania* sp. infection in wildlife from urban rainforest fragments in Northeast, Brazil. *J Wildl Dis*. 2018;54(1):76-84.
213. van Doremalen N, Munster VJ. Animal models of Middle East respiratory syndrome coronavirus infection. *Antivir Res*. 2015;122:28-38.
214. Vásquez-Aguilar AA, Toledo-Manuel FO, Barbachano-Guerrero A, Hernández-Rodríguez D. Detection of antimicrobial resistance genes in *Escherichia coli* isolated from black howler monkeys (*Alouatta pigra*) and domestic animals in fragmented rain-forest areas in Tabasco, Mexico. *J Wildlife Dis*. 2020;56(4):922-7.
215. Vela AI, Gutiérrez MC, Falsen E, Rollán E, Simarro I, García P, Domínguez L, Ventosa A, Fernández-Garayzábal JF. *Pseudomonas simiae* sp. nov., isolated from clinical specimens from monkeys (*Callithrix geoffroyi*). *Int J Syst Evol Microbiol*. 2006;56(11):2671-6.
216. Velásquez-Ortiz N, Ramírez JD. Understanding the oral transmission of *Trypanosoma cruzi* as a veterinary and medical foodborne zoonosis. *Res Vet Sci*. 2020;132:448-461.
217. Verona CE, Pissinatti A. Capítulo 34: Primates – Primatas do Novo Mundo (sagui, macaco-prego, macaco-aranha, bugio e muriqui). In: Cubas ZS, Silva JCR, Catão-Dias JL (eds). *Tratado de Animais Selvagens – Medicina Veterinária Volume 1*. 2aEd, Editora Roca Ltda, São Paulo-SP, p. 723-743, 2014.
218. Vieira RFC, Biondo AW, Guimarães MAS, Santos AP, Dos Santos RP, Dutra LH, Diniz PP, de Moraes HA, Messick JB, Labruna MB, Vidotto O. Ehrlichiosis in Brazil. *Rev Bras Parasitol Vet*. 2011;20(1):1-12.
219. Villanueva-García C, Gordillo-Chávez EJ, Baños-Ojeda C, Rendón-Franco E, Muñoz-García CI, Carrero JC, Córdoba-Aguilar A, Maravilla P, Galian J, Martínez-Hernández F, Villalobos G. New *Entamoeba* group in howler monkeys (*Alouatta* spp.) associated with parasites of reptiles. *Parasitol Res*. 2017;116(8):2341-2346.
220. Wachtman L, Mansfield K. Viral diseases of nonhuman primates. In: Abee CR, Mansfield K, Tardif S, Morris T, Morris T, eds. *Nonhuman primates in biomedical research*. London, UK: Academic Press; 2012:7-26.
221. Whatmore AM, Davison N, Cloeckaert A, Dahouk SA, Zygmunt MS, Brew SD, Perrett LL, Koylass MS, Vergnaud G, Quance C, Scholz HC, Dick EJ, Hubbard G, Schlabritz-Loutsevitch NE. *Brucella papionis* sp. nov., isolated from baboons (*Papio* spp.). *Int J Syst Evol Microbiol*. 2014;64(Pt 12):4120-4128.
222. Whitney RA. Taxonomy. In: Bennett B, Abee C, Henrickson R, eds. *Nonhuman primates in biomedical research. Biology and Management*. Elsevier: Missouri. 1995.
223. Wilson TM, Ritter JM, Martines RB, Bullock HA, Fair P, Radford KW, Macêdo IL, Sousa DER, Gonçalves AAB, Romano AP, Passos PHO, Ramos DG, Costa GRT, Cavalcante KRLJ, Melo CB, Zaki SR, Castro MB. Fatal human Alphaherpesvirus 1 infection in free-ranging black-tufted marmosets in anthropized environments, Brazil, 2012–2019. *Emerg Infect Dis*. 2022;28(4):802-11.

224. Wilson TM, Ritter JM, Martines RB, Gonçalves AAB, Fair P, Galloway R, Weiner Z, Romano APM, Costa GRT, Melo CB, Zaki SR, Castro MB. Pathology and One Health implications of fatal *Leptospira interrogans* infection in an urbanized, free-ranging, black-tufted marmoset (*Callithrix penicillata*) in Brazil. *Transbound Emerg Dis.* 2021;68(6):3207-16.
225. Yu G, Yagi S, Carrion R, Chen EC, Liu M, Brasky KM, Lanford RE, Kelly KR, Bales KL, Schnurr DP, Canfield DR, Patterson JL, Chiu CY. Experimental Cross-Species Infection of Common Marmosets by Titi Monkey Adenovirus. *Plos One.* 2013;8(7):e68558.
226. Zárate-Rendón DA, Salazar-Espinoza MN, Catalano S, Sobotyck C, Mendoza AP, Rosenbaum M, Verocai G. Molecular characterization of *Dipetalonema yatesi* from the black-faced spider monkey (*Ateles chamek*) with phylogenetic inference of relationships among *Dipetalonema* of Neotropical primates. *Int J Parasitol Parasites Wildl.* 2022;17:152-7.
227. Ziccardi M, Lourenço-de-Oliveira R. The infection rates of trypanosomes in squirrel monkeys at two sites in the Brazilian Amazon. *Mem Inst Oswaldo Cruz.* 1997;92(4):465-70.