



Case Report

First report of nocardiosis due to *Nocardia asteroides* in a domestic canary (*Serinus canaria domestica*) in Mexico

Rubén Arturo López-Crespo¹, Samantha Miroslava Torres-Cervantes¹, Jwerlly Tatiana Pico-Rodríguez², Manuel Arturo Moreno-Borjas³, Luary Carolina Martínez-Chavarría^{2*}

¹ Aquapath. Laboratorio de Anatomopatología Veterinaria. Paseo de las Palmas #45. Col. Villas de Bugambilias. CP: 28979. Villa de Álvarez, Colima, México.

² Departamento de Patología. Facultad de Medicina Veterinaria y Zootecnia. Universidad Nacional Autónoma de México. Av. Universidad #3000, Ciudad Universitaria. CP: 04510. Coyoacán, Ciudad de México, México.

³ Veterinaria Zoo Mascota. Paseo de los Cedros #2. Col. Villas de Bugambilias. CP: 28979. Villa de Álvarez, Colima, México.

*Corresponding author: luary@unam.mx

Submitted: November 8th, 2022. Accepted: March 22th, 2023.

Abstract

Nocardiosis is a multi-systemic disease that has been reported in several species of birds. It is characterized by the development of granulomatous inflammation in several organs, mainly affecting the respiratory system. An adult male domestic canary (*Serinus canaria domestica*) weighing 14.5 g was received for examination. Multiple nodules were identified in the epicardium, air sacs, and lungs. Histologically these nodules corresponded to granulomas, in which numerous thin, filamentous branching bacteria were identified. Gram stains of the epicardium, air sacs, and lungs revealed many filamentous branching Gram-positive bacteria. These bacteria were also strongly acid-fast positive by Fite-Faraco stain. PCR end-point analysis and sequencing using total DNA extracted from formalin-fixed paraffin-embedded samples of lungs, heart, and air sacs confirmed the presence of *Nocardia asteroides*. To the best of the authors' knowledge, this is the first case report of nocardiosis associated with *Nocardia asteroides* in a Domestic Canary (*Serinus canaria domestica*) in Mexico.

Keywords: Nocardiosis, *Nocardia asteroides*, granulomatous disease, Passeriformes, domestic canary, *Serinus canaria domestica*.

Introduction

Nocardiosis is a multi-systemic disease caused by various species of the genus *Nocardia* that has been reported in several species, including birds (1, 5, 10). This genus corresponds to aerobic non-sporulating Gram-positive branching filamentous rods that are environmental saprophytes found in soil (3, 10).

In birds, this disease is characterized by the development of granulomatous inflammation in several organs, being the lungs the main affected organs and the suspected source of hematogenous dissemination to other organs (1, 3, 5, 9, 12).

In most cases reported to date, the diagnosis of nocardiosis has been presumptive, based on macroscopic and microscopic lesions (4, 6-9, 11, 13), while in other reports, it has only been possible to identify the genus (5, 12). There are

only 4 cases where the species were determined; these include 2 cases due to *N. asteroides* (2, 10) and 2 cases due to *N. nova* (1, 3).

Nocardiosis in birds has been reported in several countries, including Australia (9, 11), China (3), England (4), India (5-7), Switzerland (1, 2), and the United States (8, 10, 12, 13). However, there is no report of this disease affecting birds in Mexico.

Some of the affected bird orders include the Accipitriformes (4), Anseriformes (7), Columbiformes (5), Passeriformes (6,10,12), Procellariiformes (13), Psittaciformes (2, 3, 8, 9, 11) and Gruiformes (1). In the order of Passeriformes, this disease has been described in a Hill Mynah (*Gracula religiosa*) (6), a Purple Throated Sunbird (*Nectarinia sperapa*) (10), and a Prothonotary Warbler (*Protonotaria citrea*) (12), but there are no reported cases in Domestic Canaries (*Serinus*

canaria domestica). To the best of the authors' knowledge, this is the first case report of nocardiosis associated with *Nocardia asteroides* in a domestic canary (*Serinus canaria domestica*) in Mexico.

Case Description

A group of domestic canaries (*Serinus canaria domestica*) were examined in a private aviary. The owner reported the recent introduction of two new canaries into the aviary, and a few days after that, they began to get sick. At clinical examination, the affected canaries showed apertia and itching on the head, neck, and wings, as well as epiphora, depression, and anorexia. Diseased animals were isolated, and all the birds in the aviary were subjected to precautionary quarantine. Based on the clinical signs, trichomoniasis was suspected, and treatment with metronidazole (50 mg/kg, once a day for seven days) was administered to the affected animals. At the end of the treatment, no clinical improvement was noted. For this reason, one of the sick birds was humanely euthanized and submitted to the laboratory for necropsy.

An adult male domestic canary (*Serinus canaria domestica*) weighing 14.5 g was received for *post mortem* examination at Aquapath Diagnostic Laboratory. During the external physical examination, the corpse showed good body condition and a good state of preservation (Fig. 1A). No other external lesions were found. On internal examination, multiple well-demarcated, white-yellowish, and firm nodules

measuring 1 to 3 mm in diameter were identified in the epicardium, air sacs, and lungs (Fig. 1B, 1C, and 1D). The other organs and tissues examined did not show relevant macroscopic changes.

Histological sections of several tissues were examined; however, only the lungs, heart, and air sacs were affected. The nodules described grossly in these organs corresponded to granulomas, characterized by the compact (organized) collection of epithelioid macrophages, lymphocytes, plasma cells, and occasional multinucleated giant cells surrounding a central necrotic area. These granulomas were occasionally encapsulated by a thin layer of fibroblasts infiltrated by macrophages and lymphocytes (Fig. 2A and 2C). Numerous thin, filamentous branching bacteria were identified within the necrotic centers and at the periphery of the granulomas (Fig. 2B and 2D).

Gram, Ziehl-Neelsen, Fite-Faraco, and Grocott Methenamine Silver stains were performed to highlight the bacterial morphology and rule out the presence of fungal structures. Gram stains of the epicardium, air sacs, and lungs revealed many filamentous branching Gram-positive bacteria (Fig. 3A and 3B). These bacteria were also strongly acid-fast positive by Fite-Faraco stain (Fig. 3C and 3D). No positivity was observed with Ziehl-Neelsen or Grocott Methenamine Silver stains.

Genomic DNA was isolated from paraffin-embedded sections of lungs, heart, and air sacs using a DNeasy blood & tissue kit (Qiagen, Ventura CA, USA) according to the manufacturer's instructions. Based on the Gram-positive stain of branching and filamentous bacilli and positive Fite-Faraco stain, Polymerase chain reaction (PCR) was performed to detect *Nocardia* sp., using a set of primers Noc1 (5'- GCTTAACACATGCAAGTCG -3') and Noc2 (5'- GAATTCAGTCTCCCCTG -3') reported by Tan *et al.* (14), which amplify the 16S rRNA gene of *Nocardia* sp. PCR reactions were performed in a final volume of 25 µl containing 12.5 µl of TopTaq Master Mix (1.25 units of TopTaq DNA polymerase, 1X PCR buffer with 1.5 mM MgCl₂ and 200 µM of each dNTP), 1 µl of each oligonucleotide at a concentration of 25 pmol, DNA (100 ng) and molecular biology grade water 25 µl. The cycling program consisted of 1 cycle of 95°C for 5 min, 33 cycles of denaturing (95°C, 45 s), annealing (69°C, 45 s), and extension (72°C, 1 min 12 s), followed by a final extension at 72°C for 5 min. PCR fragments were subjected to electrophoresis in a 1% agarose gel stained with Sybr Safe and subsequently visualized with ultraviolet light in a UVP UVsolo transilluminator (Analytik jena, Thuringia, Germany). Further species identification was based on sequencing of the fragment corresponding to the 16S rRNA gene of *Nocardia* sp. The fragment was purified using a QIAquick Gel Extraction Kit (Qiagen, Ventura CA, USA) according to the manufacturer's instructions and sequenced in both directions. The sequence was submitted to a BLAST search of all available databases at the National Center for

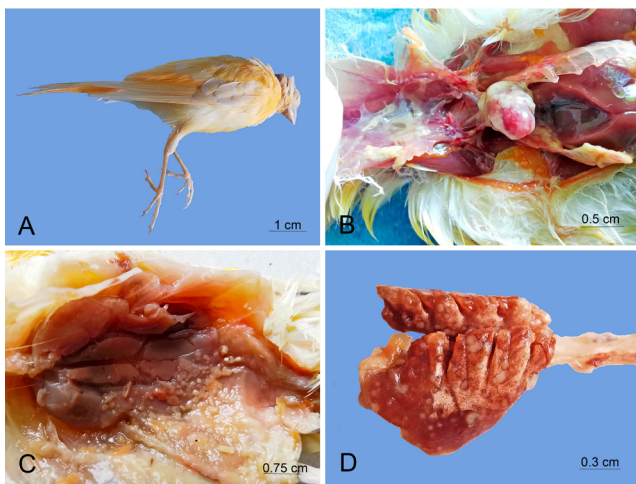


Figure 1. Gross lesions observed during *post mortem* examination of the domestic canary. A) Corpse of the canary showing no external lesions and good body condition. B) Epicardium and interclavicular air sac showing multiple white-yellowish, coalescent, well-demarcated, raised, and firm nodules measuring 1-3 mm in diameter (granulomas). C) Granulomas on the abdominal air sac and the adjacent muscular wall. D) Lungs exhibiting several granulomas on the surface and the parenchyma.

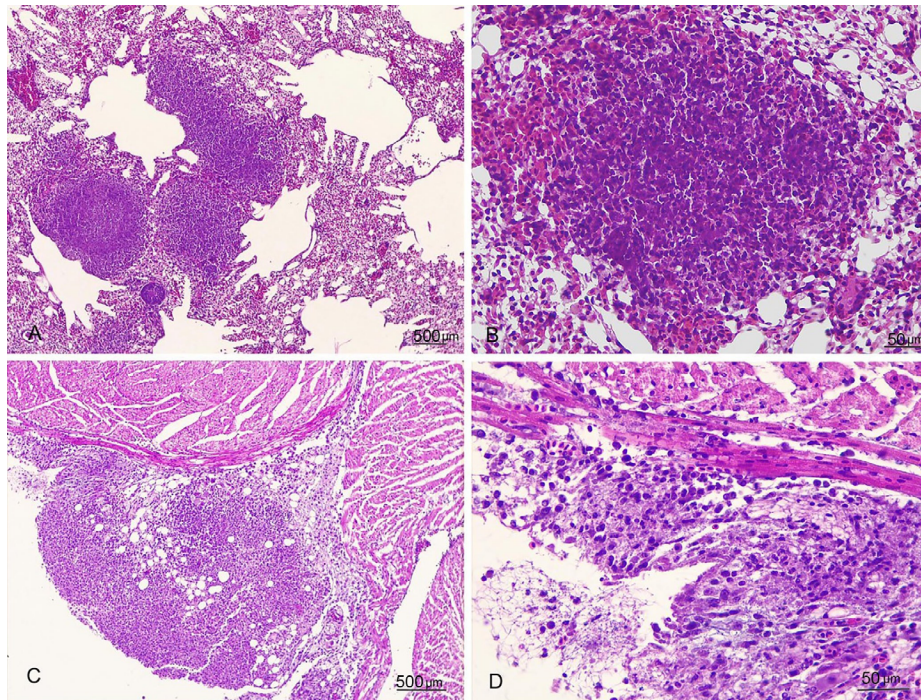


Figure 2. Microscopic lesions observed in tissues obtained during *post mortem* examination. A) Histological section of the lung showing multiple granulomas expanding the parenchyma (H&E stain). B) Granulomas composed of a central core of necrosis surrounded by macrophages, lymphocytes, and plasma cells. Some filamentous bacteria are intermixed with the inflammatory cells (H&E stain). C) Marked granulomatous inflammation expanding the epicardium (H&E stain). D) Several filamentous bacteria mixed with the inflammatory cells (H&E stain).

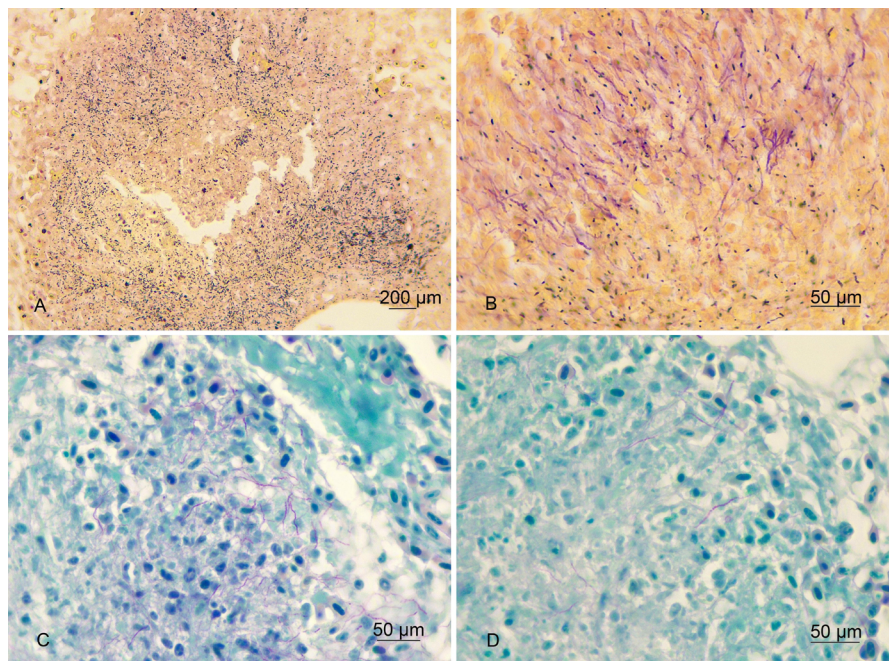


Figure 3. Special stains performed on histological sections of the lungs and epicardium. A) Granuloma of the lung showing multiple Gram-positive filamentous bacteria (Gram stain). B) Several Gram-positive filamentous bacteria intermingled within the inflammatory infiltrate of the epicardium (Gram stain). C) Granuloma of the lung showing multiple acid-fast filamentous bacteria (Fite-Faraco stain). D) Several acid-fast filamentous bacteria intermingled within the inflammatory infiltrate of the epicardium (Fite-Faraco stain).

Biotechnology Information (<https://www.ncbi.nlm.nih.gov>) and showed a 98.95% homology with *Nocardia asteroides*. We submitted this sequence to the GenBank (accession number OP740777).

Discussion

Nocardiosis is a multi-systemic disease caused by bacteria of the genus *Nocardia* that has been documented in several species of birds (1-13). In these species, the disease is characterized by the presence of granulomas in several organs, the lungs being the main affected organs (1, 3-11) and the suspected source of hematogenous dissemination to other organs (1, 3, 5, 9, 12). Here we report a case of nocardiosis in a domestic canary that developed granulomas in the lungs, air sacs, and epicardium but not in other organs, as shown in previous reports (3, 5, 6, 9, 11). Since the lesions were found mainly in the lungs and air sacs, we suppose the canary acquired the disease by the respiratory route, and thus the heart was secondarily affected by contiguity with the affected lungs or by hematogenous spreading.

In general, the reported cases are isolated events but have also occurred as outbreaks affecting several birds (1, 5). Although in the case reported here, only one bird was evaluated, some other birds showed similar clinical signs to those observed in the bird submitted for necropsy; therefore, this case could probably be part of an outbreak. Based on the clinical history, the disease was suspected to be introduced to the aviary by new birds bought by the owner. Those birds did not have a health certificate and were not subjected to quarantine before their introduction to the aviary.

One of the most affected bird orders is the Psittaciformes (2, 3, 8, 9, 11), followed by the Passeriformes (6, 10, 12). The present case corresponds to the first case in a domestic canary (*S. canaria domestica*) which is also included within the order of Passeriformes.

There are few cases of nocardiosis in birds reported worldwide; in America, specifically in the United States, there are only four reports, which were identified in a Purple throated sunbird (*Nectarinia sperapa*) (10), a Prothonotary warbler (*Protonotaria citrea*) (12), two Laysan albatross (*Diomedea immutabilis*) (13) and two Pesquet's parrots (*Psittirichas fulgidus*) (8). However, no report of this disease affecting birds in Mexico or any other Latin American country exists. Since it was impossible to know the origin of those new birds introduced to the aviary, it is difficult to hypothesize how they became infected. The possibility that these birds were imported from the United States or even from another country is not ruled out, but this could not be confirmed.

Diagnosis of nocardiosis in companion birds is important since, as other authors have suggested (5), infected animals can excrete bacteria into the environment, thus making human beings, other mammals, and birds susceptible to infection.

Most of the reported cases of nocardiosis were diagnosed only by bacteriological culture, and in several of them, the presence of *Nocardia* was only assumed by the lesions, special stains, and morphology of the bacteria present in the tissues (1, 2, 5, 8, 10, 13). It is noteworthy that even in those cases where culture was performed, the identification of the microorganism was limited to the genus *Nocardia*, without reaching the species identification. Molecular approaches were used only in two reports; Churgin *et al.* identified *N. nova* in a yellow-bibbed lory using MLST (3), and Reynolds *et al.* used ISH to identify *Nocardia* in a prothonotary warbler, but this was limited only to the genus *Nocardia* (12). In this study, the use of PCR and sequencing allowed not only to confirm the presence of *Nocardia*, but also to identify the species.

Currently, the disease has been controlled in the aviary, and no new cases have been detected in the remaining birds. The management of the outbreak included the quarantine of the rest of the birds and the cleaning and disinfection of the cages.

The case presented here contributes significantly to the generation of information on the diseases occurring in birds from Mexico and helps avian clinicians to consider nocardiosis as a differential diagnosis in cases of respiratory disease. To our knowledge, this is the first confirmed case of nocardiosis due to *Nocardia asteroides* in a domestic canary, which highlights the need to include specific molecular tests within the routine pathological diagnosis to reach accurate and specific diagnoses. Identifying the *Nocardia* at the species level is crucial for understanding the epidemiology of nocardiosis in birds.

Acknowledgments

The authors thank Karen J. Guitareo Quintana and Alfredo Díaz Estrada for their technical assistance in histopathology and Jaime Cordova López for imaging technical support.

Conflict of Interest

The authors declare no competing interests.

References

1. Bacciarini LN, Posthaus H, Pagan O, Miserez R. *Nocardia nova* causing pulmonary nocardiosis of black crakes (*Limnecorax flavirostra*). Vet Pathol. 1999;36(4):345-7.
2. Baumgartner R, Hoop RK, Widmer R. Atypical nocardiosis in a red-lored amazon parrot (*Amazona autumnalis autumnalis*). J Assoc Avian Vet. 1994;8(3):125-7.

3. Churgin SM, Teng JLL, Ho JHP, Graydon R, Martelli P, Lee FK, Hui SK, Fong JYH, Lau SKP, Woo PCY. First case report of fatal *Nocardia nova* infection in a yellow-bibbed lory (*Lorius chlorocercus*) identified by multilocus sequencing. BMC Vet. Res. 2019;15(4):1-5.
4. Cooper JE. Postmortem findings in east African birds of prey. J Wildl Dis. 1973;9(4):368-75.
5. Darzi MM, Mir MS, Nashiruddullah N, Kamil SA. Nocardiosis in domestic pigeons (*Columba livia*). Vet Rec. 2006;158(24):834-6.
6. Iyer PK, Rao AT, Acharjyo LN, Sahu S, Mishra SK. Systemic nocardiosis in a hill mynah (*Gracula religiosa*). A pathological study. Mycopathol Mycol Appl. 1972;48(2):223-9.
7. Iyer PK, Rao PP. Suspected pulmonary nocardiosis in a duck. Sabouraudia. 1971;9(2):79-80.
8. Long P, Choi G, Silberman M. Nocardiosis in two Pesquet's parrots (*Psittirichas fulgidus*). Avian Dis. 1983;27(3):855-9.
9. Park FJ, Jaensch S. Unusual multifocal granulomatous disease caused by actinomycetous bacteria in a nestling Derbyan parrot (*Psittacula derbiana*). Aust Vet J. 2009;87(1):63-5.
10. Parnell MJ, Hubbard GB, Fletcher KC, Schmidt RE. *Nocardia asteroides* infection in a purple throated sunbird (*Nectarinia sperapa*). Vet Pathol. 1983; 20(4):497-500.
11. Raidal SR. Bilateral necrotizing pectenitis causing blindness in a rainbow lorikeet (*Trichoglossus haematodus*). Avian Pathol. 1997;26(4):871-6.
12. Reynolds TL, Barnes HJ, Wolfe B, Lu L, Camp DM, Malarkey DE. Bilateral nocardial endophthalmitis in a prothonotary warbler (*Protonotaria citrea*). Vet Pathol. 2009;46(1):120-3.
13. Sileo L, Sievert PR, Samuel MD. Causes of mortality of albatross chicks at midway atoll. J Wildl Dis. 1990;26(3):329-38.
14. Tan CK, Lai CC, Lin SH, Liao CH, Chou CH, Hsu HL, Huang YT, Hsueh PR. Clinical and microbiological characteristics of nocardiosis including those caused by emerging *Nocardia* species in Taiwan, 1998–2008. Clin Microbiol Infect. 2010;16(7):966–972.