Braz J Vet Pathol, 2023, 16(2), 132-138
DOI: https://doi.org/10.24070/bjvp.1983-0246.v16i2p132-138

BJVP
Brazilian Journal of Veterinary Pathology
ISSN 1983-0246

Case Report

Urethral obstruction secondary to *Staphylococcus felis* chronic urethritis and hepatoid gland adenoma in a captive ocelot (*Leopardus pardalis*)

Mariana Ferreira de Castro[1], Thaynara Parente de Carvalho[1], Daniel Oliveira dos Santos[1], Ayisa Rodrigues Oliveira[1], Samantha Pinheiro Pimentel[1], Nayara Ferreira de Paula[1], Herlandes Penha Tinoco[2], Carlyle Mendes Coelho[2], Jordana Almeida Santana[1], Flávia Mello Viegas[1], Rodrigo Otávio Silveira Silva[1], Tatiane Alves da Paixão[3], Renato Lima Santos[1]

[1] Departamento de Clínica e Cirurgia Veterinárias, Escola de Veterinária, Universidade Federal de Minas Gerais, 31270-901, Belo Horizonte, Minas Gerais, Brazil.
[2] Fundação de Parques Municipais e Zoobotânica, 31365-450, Belo Horizonte, Minas Gerais, Brazil.
[3] Departamento de Patologia Geral, Instituto de Ciências Biológicas, Universidade Federal de Minas Gerais, 31270-901, Belo Horizonte, Minas Gerais, Brazil.

***Corresponding author:** rls@ufmg.br
Submitted: February 2nd, 2023. Accepted: April 3rd, 2023.

Abstract
A male adult ocelot (*Leopardus pardalis*) kept under human care developed anuria, which progressed to death. Grossly, the urinary bladder was markedly dilated and filled with red discolored urine containing blood clots. In addition, the animal had a hepatoid cell adenoma adjacent to the urethra, which likely caused partial urethral occlusion. Microscopically, there was a predominantly neutrophilic, fibrinous and hemorrhagic urethritis, cystitis, and pyelonephritis with intralesional gram-positive cocci. Microbiologic culture followed by MALDI-TOF MS analysis resulted in the identification of isolates from the urine and urethra as *Staphylococcus felis*.

Keywords: Felidae, zoo, urinary disease, wild felids, neoplasm, lower urinary tract, non-domestic felid.

Introduction

The ocelot (*Leopardus pardalis*) is a neotropical felid that occurs in Central and South America as well as Mexico and Southwest Texas in the United States (8). Considering the red list of International Union for Conservation of Nature and Natural Resources (14), ocelots are listed as least concern but with decreasing population (https://www.iucnredlist.org/, accessed 01 February 2022). However, ocelots are considered to have a low reproductive potential, which supports the need for conservation initiatives and expansion of our knowledge on diseases that affect this species (8). Despite the well-known prevalence of infectious urinary diseases in domestic cats (4), this condition has not been properly studied in wild felids. Importantly, obstructive nephropathy may result in acute kidney injury, which may be fatal without intervention (2, 28).

Disruption of the urinary flow is often associated with uroliths, urethral plugs, infectious process, and less commonly with anatomic malformations or neoplasms (27). Urinary obstruction may also be due to pathologic changes in adjacent structures, particularly in the pelvic region. Perianal gland tumors are common in non-neutered older male dogs, and less frequently in female dogs or cats (11, 21, 29). Apocrine gland adenocarcinoma and carcinoma are rarely reported in domestic cats (10, 24, 25). Nonetheless, although the causes may vary, clinical signs are similar and include anuria, hematuria, and pollakiuria (12).

Staphylococcus spp. are gram-positive, facultative anaerobic bacteria, which are considered members of normal

Brazilian Journal of Veterinary Pathology. www.bjvp.org.br . All rights reserved 2007-2023.

Braz J Vet Pathol, 2023, 16(2), 132-138
DOI: https://doi.org/10.24070/bjvp.1983-0246.v16i2p132-138

microbiota of the skin and mucous membranes of mammals and birds (3, 30). Among more than 40 known species, *Staphylococcus felis* is the most common *Staphylococcus* spp. isolated from the skin and saliva of healthy cats (13, 17, 18). There is a previously reported case of pyelonephritis in a Siberian tiger *(Pathera tigris altaica)* caused by *Staphylococcus intermedius* (15).

To the best of our knowledge, there are no previous reports of *S. felis* infection in wild felids. Therefore, the aim of this report is to describe an unusual case of urinary obstruction, with secondary *S. felis*-associated hemorrhagic cystitis and pyelonephritis.

Case Description

An adult male ocelot (*Leopardus pardalis*) kept under human care at the BH-Zoo (Belo Horizonte, Brazil) was daily monitored and developed anuria one day before death. The animal was found dead and immediately submitted to necropsy.

Grossly, the ocelot had a good body condition. Oral and ocular mucosae were moderately pale. The urinary bladder was markedly dilated occupying approximately two-thirds of the abdominal cavity (Fig. 1A). The serosa of the urinary bladder was diffusively red with a markedly thin wall, and the mucosa had multifocal to coalescent dark red areas interpreted as hemorrhage (Fig. 1B), with a dark red content in lumen with moderate amount of blood clots. The pelvic segment of the urethra was diffusely enlarged and firm, with approximately 4.0 cm in diameter (Fig. 1C). On a cross-sectional cut surface, the urethral lumen was diminished, and the wall was thickened and firm with multifocal dark red areas interspersed with brown soft areas (Fig. 1D). Dorsally, there were two whitish, soft and solid focally extensive areas that were contiguous to the perianal glands. Both kidneys were diffusely pale and the left kidney had a reddish focally extensive area in the cranial pole. On cut surface, this area was multifocal to coalescent red areas extending from the pelvis to the cortical surface of the cranial pole of the left kidney (Fig. 2A and B). The prostate gland was diffuse and intensely

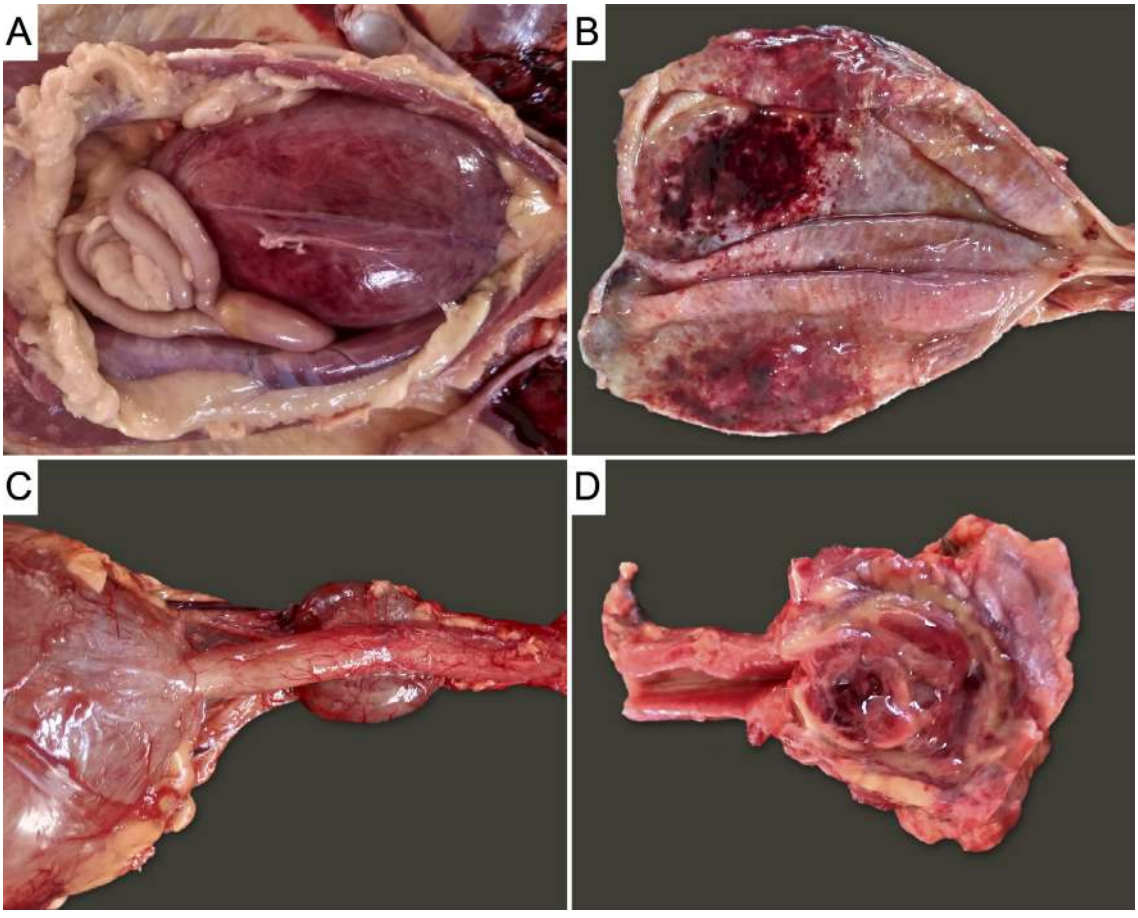

Figure 1. Urethritis and cystitis in an ocelot (*Leopardus pardalis*). (A) Markedly distended urinary bladder with multifocal to coalescing serosal hemorrhage, and partially occupying the abdominal cavity. (B) Focally extensive area of hemorrhage in the urinary bladder mucosa. (C) Enlarged pelvic urethra with a diameter of approximately 4.0 cm. (D) Cut surface of pelvic urethra with stenosis of the urethral lumen and thickening of the wall.

Brazilian Journal of Veterinary Pathology. www.bjvp.org.br . All rights reserved 2007-2023.

Braz J Vet Pathol, 2023, 16(2), 132-138
DOI: https://doi.org/10.24070/bjvp.1983-0246.v16i2p132-138

swollen, dark red, with a solid and dark red cut surface. Other gross findings included moderate pulmonary edema and mild liver congestion. Samples of urethra, perianal glands, prostate, kidneys, urinary bladder, liver, lungs, and lymph nodes were fixed in 10% buffered formalin and processed for paraffin embedding, and 3-4 µm sections were stained with hematoxylin and eosin (HE) and Gram staining. Swabs from urethra and urine samples were aseptically collected for microbiological culture.

Microscopically, the urethra had multifocal to coalescent areas of intense inflammatory infiltrate predominantly composed of neutrophils (Fig. 3A), with some macrophages, associated with fibrin accumulation and moderate numbers of intralesional gram-positive cocci (Fig. 3B), which were also observed within the urethral lumen. There was also severe fibrosis and neutrophilic infiltrate in the urethral wall. Cortical and medullary renal tubules had intra-luminal accumulation of neutrophils containing gram-positive intracytoplasmic cocci (Fig. 4A). There was also an interstitial multifocal to coalescent mild predominantly neutrophilic inflammatory infiltrate, with multifocal areas of fibrin deposition and hemorrhage. Glomeruli had

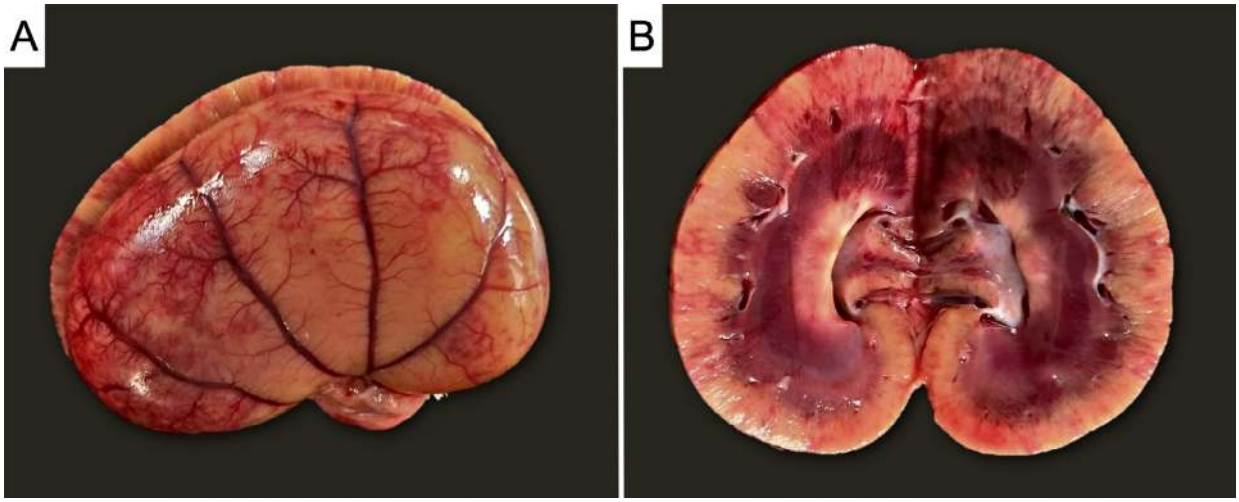

Figure 2. Pyelonephritis in an ocelot (*Leopardus pardalis*). (A) Red discoloration on the cortical surface of the cranial pole of the left kidney. (B) Cut surface of the left kidney with multifocal to coalescing hemorrhage extending from the pelvis to the cortext in the cranial pole of the kidney.

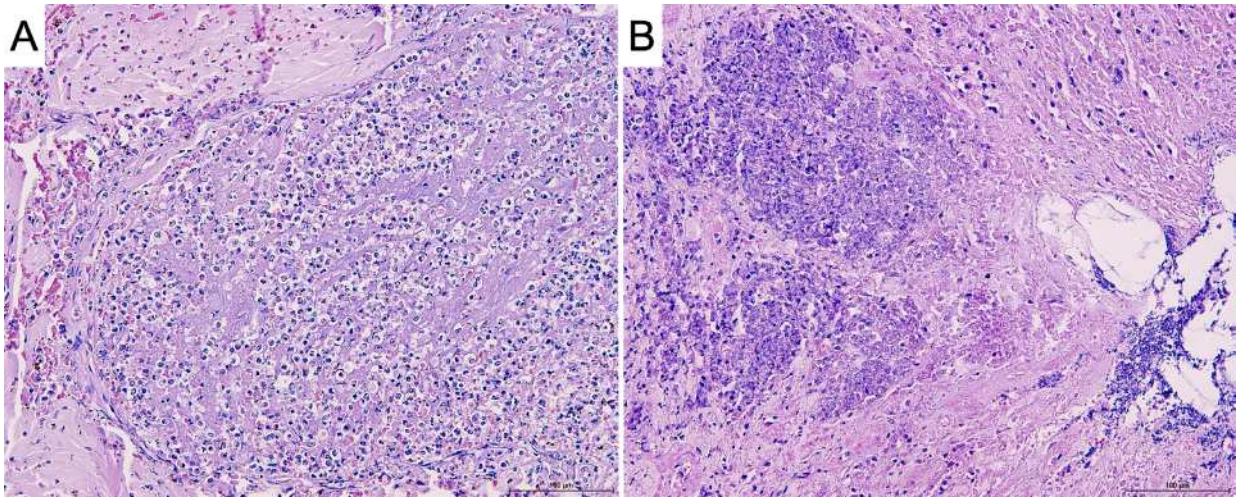

Figure 3. Urethritis in an ocelot (*Leopardus pardalis*). (A) Severe inflammatory infiltrate with many neutrophils, fewer macrophages and fibrin accumulation. Hematoxylin and eosin, bar = 100 µm. (B) Area of necrosis with large numbers of intralesional cocci. Hematoxylin and eosin, bar = 100 µm.

Brazilian Journal of Veterinary Pathology. www.bjvp.org.br . All rights reserved 2007-2023.

Braz J Vet Pathol, 2023, 16(2), 132-138
DOI: https://doi.org/10.24070/bjvp.1983-0246.v16i2p132-138

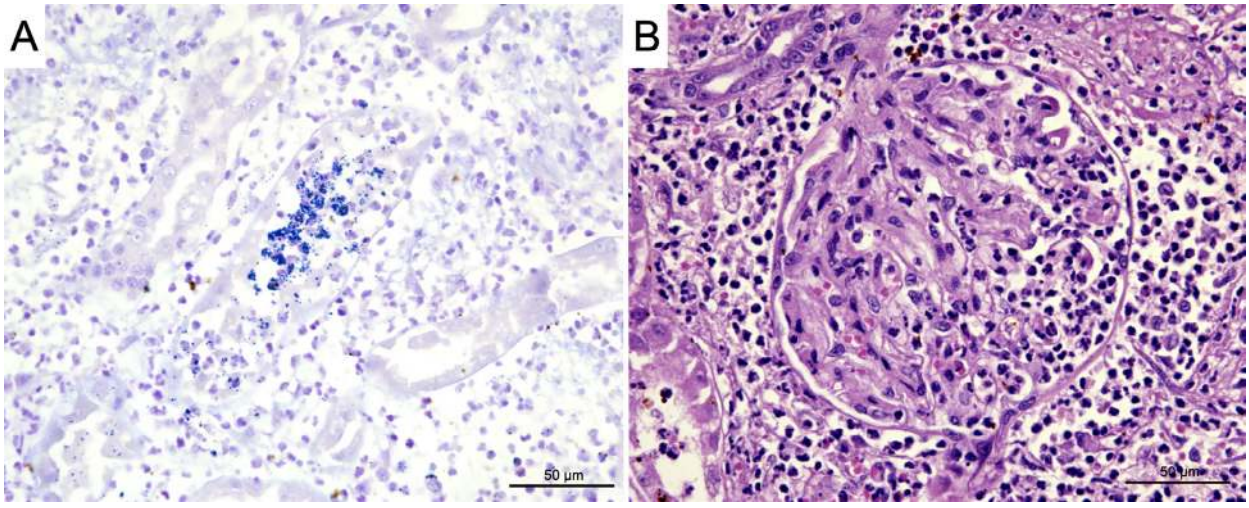

Figure 4. Pyelonephritis in an ocelot (*Leopardus pardalis*). (A) Large numbers of gram-positive cocci in the tubular lumen and in the interstitium. Gram staining, bar = 50 µm. (B) Severe neutrophilic infiltrate in the interstitium and glomerulus. Hematoxylin and eosin, bar = 50 µm.

necrosis, fibrin accumulation and neutrophilic infiltration (Fig. 4B). The urinary bladder had a mild inflammatory infiltrate composed of neutrophils, lymphocytes, macrophages and plasma cells associated with multifocal to coalescent hemorrhage in the mucosa, and to a less extent in the muscular and serosa. Perianal glands had multifocal areas of epithelial proliferation interspersed with thin connective tissue, at times forming cords of cuboidal cells with an abundant homogeneous eosinophilic cytoplasm and well-demarcated cellular limits (Fig. 5). Nuclei were round, with dense chromatin, and occasionally with a single nucleolus. These findings supported the morphologic diagnosis of hepatoid gland adenoma. The prostate had an increase in the number and volume of glandular epithelial cells, which was interpreted as diffuse hyperplasia. In addition, the prostatic urethra had an intense inflammatory infiltrated composed by neutrophils, lymphocytes, macrophages, and plasma cells with multifocal hemorrhage. There was a mild histiocytic inflammatory infiltrate, with some multinucleated giant cells, associated with loss of hepatocytes, fibrosis and biliary duct proliferation. The lymph node had mild edema and hemorrhage. The lungs had severe alveolar edema and hemorrhage.

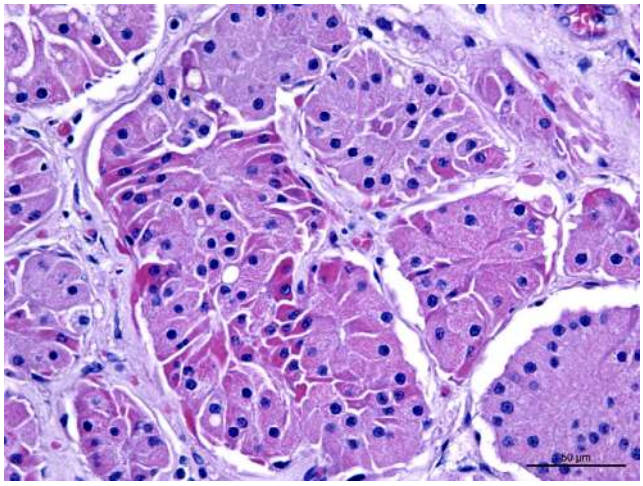

Figure 5. Hepatoid adenoma in an ocelot (*Leopardus pardalis*). Cuboidal well differentiated cells arranged in cords or nests with an abundant homogeneous eosinophilic cytoplasm and well-defined cellular limits. Hematoxylin and eosin, bar = 50 µm.

Swabs were plated on mannitol salt agar (Kasvi, Brazil) and sheep blood agar (Difco, USA), and incubated for 24 h at 37°C. Selected colonies were plated on Müller Hinton agar (Difco, USA) and identified by matrix-assisted laser desorption/ionization time-of-flight mass spectrometry (MALDI-TOF MS), as described by Assis and coworkers (1). For each isolate, 1 µL of formic acid (70%) and 1 µL of MALDI-TOF MS matrix, consisting of a saturated solution of α-cyano-4-hydroxycinnamic acid (HCCA) (Bruker Daltonics, Bremen, Germany), were applied to the spot and allowed to air-dry. Spectra were acquired using the FlexControl MicroFlex LT mass spectrometer (Bruker Daltonics) with a 60-Hz nitrogen laser, in which up to 240 laser shots. Parameters for mass range detection were defined to allow the identification from 1,960 to 20,137 m/z, where Ion source 1 v was 19.99 kv, Ion source 2 voltage was 18.24 kv and the lens voltage was

Brazilian Journal of Veterinary Pathology. www.bjvp.org.br . All rights reserved 2007-2023.

Braz J Vet Pathol, 2023, 16(2), 132-138
DOI: https://doi.org/10.24070/bjvp.1983-0246.v16i2p132-138

6.0 kv for data acquisition. Prior to measurements, calibration was preceded with a bacterial test standard (*Escherichia coli* DH5 alpha; Bruker Daltonics). Real-Time (RT) identification score criteria used were those recommended by the manufacturer, with a score ≥ 2.0 indicating a species-level identification. MALDI-ToF demonstrated that the isolates had a profile compatible with *Staphylococcus felis*.

Antimicrobial susceptibility of both *S. felis* isolates was tested by the disk diffusion method and interpreted according to the Clinical and Laboratory Standards Institute (CLSI) documents, M100-Ed31 (CLSI, 2021) and VET01S-Ed5 (6, 7). The following antimicrobials were tested: oxacillin (1 µg), cefoxitin (30 µg), penicillin (10 IU), gentamicin (10 µg), erythromycin (15 µg), clindamycin (2 µg), tetracycline (30 µg), ciprofloxacin (5 µg), nitrofurantoin (300 µg), trimethoprim-sulfamethoxazole (1.25 and 23.75 µg, respectively), chloramphenicol (30 µg), and rifampicin (5 µg) (Oxoid, USA). *Staphylococcus aureus* ATCC 25923 was used as a control. Both *S. felis* isolates were sensitive to all tested antimicrobials.

Discussion

Here we described a case of a *S. felis* infection in an ocelot with chronic urethritis with fibrosis associated with a hepatoid gland adenoma leading to an acute urethral obstruction. Isolation and identification of the agent in this case was compatible with the finding of intralesional gram-positive cocci as demonstrated by histopathologic examination. Our findings support the hypothesis that the animal had an ascending infection that led to cystitis and pyelonephritis. To the best of our knowledge there are no previous reports of urinary infections with *S. felis* in wild felids.

Among domestic animals, inflammatory diseases of urinary tract are often diagnosed in dogs and cats, due to various causes (9). In wild felids, Carvalho et al. (5) reported a suppurative hemorrhagic cystitis in an adult male snow leopard (*Panthera uncia*) caused by an extraintestinal pathogenic *Escherichia coli* strain. Additionally, Wronski et al. (32) reported a case of pyelonephritis due to uropathogenic *E. coli* in a captive jaguar (*Panthera onca*). However, in this case, urinary obstruction was caused by association of an inflammatory process and a compressive neoplasm.

In domestic cats, gram-negative bacteria are more often associated with urinary infections, with *E. coli* being the most prevalent pathogen. However, among gram-positive bacteria, *S. felis* is the most commonly isolated pathogen in cases of urinary infections (4). *S. felis* is a normal commensal microorganism present on the skin, the eyelid, and in the saliva of healthy domestic cats (19). Urine samples that are positive for *S. felis* have significantly higher pH and are more likely to contain urine crystals (19). Although urinary infections are quite common in cats, the urinary tract is an adverse environment for bacterial growth. Thus, establishment of a urinary infection requires expression of virulence factors responsible for colonization, avoidance of innate host defenses, and initiation of host tissue damage (20). However, there are some factors that favor bacterial colonization, such as urinary retention, incomplete urination, and trauma of the urinary bladder mucosa (27). Therefore, urethral obstruction is a major risk factor for occurrence of urinary infections. Urethral obstructions are more common in young male cats, due to the long and narrow anatomy of the urethra (28). The most frequent causes of urethral obstruction are urethral plugs (12). However, in this case the identified causes of urinary obstruction were chronic bacterial urethritis and an adjacent hepatoid cell adenoma. Hepatoid glands are modified sebaceous structures located in the perianal region of some mammals. Proliferative lesions of these glands include hyperplasia, adenoma, epithelioma, and carcinoma (26). Hepatoid gland adenomas are also common in dogs, but rare in cats (11). However, in this case there was evident neoplastic proliferation of the hepatoid cells that presumably resulted in compression of the urethra, contributing to the urinary obstruction.

Although it is not possible to establish the chronology of events in this case, both compression and infection likely contributed to urinary retention. Considering that urine accumulation favors urinary infections and that hepatoid adenomas as slow growing neoplasms, it is reasonable to think that the tumor in this case may have favored urinary retention, which favored opportunistic infection and consequently an acute urinary obstruction (27).

Bacterial identification in this case was based on isolation followed by characterization using MALDI-TOF. This technique has been increasingly used in veterinary medicine with reliable results for bacterial identification at the species levels (22, 23). In this case, the antimicrobial profile of the *S. felis* isolates indicated low levels or absence of antimicrobial resistance, which is similar to previous reports (19, 20, 31). However, methicillin resistance has been identified amongst *S. felis* isolates (16).

In conclusion, we described a case of acute urinary obstruction in an ocelot kept under human care that developed *S. felis* infection with urethritis, cystitis, and pyelonephritis, associated with a hepatoid cell adenoma that may have caused compression, urinary retention, thus predisposing to infection and inflammation.

Acknowledgments

Work in RLS lab is supported by CNPq (Conselho Nacional de Desenvolvimento Científico e Tecnológico, Brazil), FAPEMIG (Fundação de Amparo à Pesquisa do Estado de Minas Gerais, Brazil), and CAPES (Coordenação de Aperfeiçoamento de Pessoal de Nível Superior, Brazil).

Braz J Vet Pathol, 2023, 16(2), 132-138
DOI: https://doi.org/10.24070/bjvp.1983-0246.v16i2p132-138

Conflict of Interest

The authors declare no competing interests.

References

1. Assis GBN, Pereira FL, Zegarra AU, Tavares GC, Leal CA, Figueiredo HCP. Use of MALDI-TOF mass spectrometry for the fast identification of gram-positive fish pathogens. Front Microbiol. 2017;8:1492.
2. Bartges JW, Finco DR, Plzin DJ, Osborne CA, Barsanti JA, Brown SA. Pathophysiology of urethral obstruction. Vet Clin North Am Small Anim Pract. 1996;26(2):255-64.
3. Becker K, Heilmann C, Peters G. Coagulase-negative Staphylococci. Clin Microbiol Rev. 2014;27:870-926.
4. Byrion JK. Urinary tract infection. Vet Clin North Am Small Anim Pract. 2018;45(4):721-46.
5. Carvalho VM, Osugui L, Setzer AP, Lopez RPG, Pestana de Castro AF, Irino K, Catão-Dias JL. Characterization of extraintestinal pathogenic *Escherichia coli* isolated from captive wild felids with bacteremia. J Vet Diagn Invest. 2012;24(5):1014-6.
6. Clinical and Laboratory Standards Institute (CLSI). Performance Standards for Antimicrobial Disk and Dilution Susceptibility Tests for Bacteria Isolated from Animals. 5th ed. CLSI supplement VET01S. Wayne: Clinical and Laboratory Standards Institute; 2020. 216 p.
7. Clinical and Laboratory Standards Institute (CLSI). Performance Standards for Antimicrobial Susceptibility Testing. 31st ed. CLSI supplement M100. Wayne: Clinical and Laboratory Standards Institute; 2021. 315 p.
8. Cubas ZS, Silva JCR, Catão-Dias JL. Tratado de animais selvagens: Medicina Veterinária. 2nd ed. São Paulo: Roca, 2014. 2492 p.
9. Dorsh R, Von Vopelius-Feldt C, Wolf G, Straubinger RK, Hartmann K. Feline urinary tract pathogens: prevalence of bacterial species and antimicrobial resistance over a 10-year period. Vet Rec. 2015;176(8):201.
10. Elliott JW, Blackwood L. Treatment and outcome of four cats with apocrine gland carcinoma of the anal sac and review of the literature. J Feline Med Surg. 2011;13(10):712-7.
11. Goldshmidt MH. Sebaceous and hepatoid gland neoplasms of dogs and cats. Am J Dermatopathol. 1984;6(3):287-93.
12. Hostutler RA, Chew DJ, Stephen P, Dibartola DVM. Recent concepts in feline lower urinary tract disease. Vet Clin North Am Small Anim Pract. 2005;35:147-70.
13. Igimi S, Kawamura S, Takahashi E, Mitsuoka T. *Staphylococcus felis*, a new species from clinical specimens from cats. Int. J. Syst. Bacteriol. 1989;39:373-7.
14. IUCN. The IUCN Red List of Threatened Species. *Leopardus pardalis* (Ocelot). Avaliable on: <https://www.iucnredlist.org/species/11509/97212355>. 2022.
15. Jee H, Pakhrin B, Bae IH, Shin NS, Lee SI, Yoo HS, Kim DY. Pyelonephritis Associated with *Staphylococcus intermedius* in a Siberian Tiger (*Panthera tigris altaica*). J Vet Med Sc. 2007;69(8):851-2.
16. Kwaszewska A, Lisiecki P, Szemraj M, Szewczyk EM. Animal *Staphylococcus felis* with the potential to infect human skin Med. Dosw. Mikrobiol. 2015;67:69-78.
17. Lilenbaum W, Nunes E, Azeredo M. Prevalence and antimicrobial susceptibility of Staphylococci isolated from the skin surface of clinically normal cats. Lett Appl Microbiol. 1998;27:224-8.
18. Lilenbaum W, Esteves AL, Souza GN. Prevalence and antimicrobial susceptibility of Staphylococci isolated from saliva of clinically normal cats. Lett Appl Microbiol. 1999;28:448-52.
19. Litster A, Moss SM, Honnery M, Rees B, Trott DJ. Prevalence of bacterial species in cats with clinical signs of lower urinary tract disease: recognition of *Staphylococcus felis* as a possible feline urinary tract pathogen. Vet Microbiol. 2007;121:182-8.
20. Litster A, Thompson M, Moss S, Trott D. Feline bacterial urinary tract infections: An update on an evolving clinical problem. Vet J. 2011;187:18-22.
21. Mellanby R, Foale R, Friend E, Woodger N, Herrtage M, Dobson J. Anal sac adenocarcinoma in a Siamese cat. J Feline Med Surg. 2002;4(4):205-7.
22. Moreno LZ, Matajira CEC, Costa BLP, Ferreira TSP, Silva GFR, Dutra MC, Gomes VTM, Silva APS, Christ APG, Sato MIZ, Moreno AM. Characterization of porcine *Truperella pyogenes* by matrix-assisted laser desorption ionization time of light mass spectrometry (MALDI-TOF-MS), molecular typing and antimicrobial susceptibility profiling in São Paulo State. Comp Immunol Microbiol Infect Dis. 2017;51:49-53.
23. Nyvan GH, Jensen AK, Bocher S, Damkjaer S, Bartels D, Pedersen M, Clausen ME, Redha RA, Dargis R, Hojlyng N, Kemp M, Christensen JJE. Mass spectrometry: pneumococcal meningitis verified, and *Brucella* species identified in less than half an hour. Scand J Infect Dis. 2010;42:716-8.
24. Parry NMA. Anal sac gland carcinoma in a cat. Vet. Pathol. 2006;43(6):1008-9.
25. Raleigh JS, Lanza MR, Perry JA. Apocrine gland anal sac adenocarcinoma with perineural metastasis in a cat. JFMS Open Rep. 2018 Dec 3;4(2):2055116918815323.
26. Sabattini S, Renzi A, Rigillo A, Scarpa F, Capitani O, Tinto D, Brenda A, Bettini G. Cytological differentiation between benign and malignant perianal gland proliferative lesions in dogs: a preliminary study. J Small Anim Pract. 2019;60(10):616-22.

Braz J Vet Pathol, 2023, 16(2), 132-138
DOI: https://doi.org/10.24070/bjvp.1983-0246.v16i2p132-138

27. Santos RL, Alessi AC. Patologia Veterinária. 3. ed. Rio de Janeiro: Guanabara Koogan, 2023. 1008 p.
28. Segev G, Livne H, Ranen E, Lavy E. Urethral obstruction in cats: predisposing factors, clinical, clinicopathological characteristics and prognosis. J Feline Med Surg. 2011;13:101-8.
29. Sobczyńska-Rak A, Żylińska B, Jarosz Ł, Brodzki A, Tatara M. EGF level in hepatoid gland adenomas and hepatoid gland epitheliomas in dogs after administering tamoxifen. In Vivo. 2018;32(5):1175-81.
30. Weese JS. The canine and feline skin microbiome in health and disease. Vet Dermatol. 2013;24:1317.
31. Worthing K, Pang S, Trott DJ, Abraham S, Coombs GW, Jordan D, McIntyre L, Davies MR, Norris J. Characterisation of *Staphylococcus felis* isolated from cats using whole genome sequencing. Vet Microbiol. 2018;222:98-104.
32. Wronski JG, Argenta FF, Raiter J, Ehlers LP, Sala RDV, Siqueira FM, Cardoso DF, Sonne L, Pavarini SP. Bilateral pyelonephritis due to *Escherichia coli* infection in a captive jaguar (*Panthera onca*). Pesq Vet Bras. 2020;40(7):554-8.

Brazilian Journal of Veterinary Pathology. www.bjvp.org.br . All rights reserved 2007-2023.