























Case Report

Mycobacteroides chelonae-abscessus group infection in a Paraguayan rainbow boa (*Epicrates crassus*)

Sarah Raquel Jesus Santos Simões¹ , Eduardo Ferreira-Machado^{1,2} ,
 Jamile Macedo Garcia¹ , Ticiania Brasil Ervedosa¹ , Pedro Enrique Navas-Suárez¹ ,
 Isis Paixão de Jesus¹ , Julia de Carvalho¹, Gabrielle Fernanda Pereira da Silva Gagliotti^{1,2} ,
 Rodrigo Albergaria Ressio¹ , Cinthya dos Santos Cirqueira¹ , Ketlyn Bolsachini Figueiredo¹ ,
 Ana Carolina Souza Ramos de Carvalho¹ , Thaís Eleonora Madeira Butti³ ,
 Rodrigo Hidalgo Friçiello Teixeira⁴ , André Luiz Mota da Costa⁴ , Maraya Lincon Silva⁴ ,
 Mayara Grego Caiaffa⁴ , Cassia Regina Ramos Gonzaga⁴ , Flora Nogueira Matos⁴ ,
 Juliana Mariotti Guerra^{1,2*} , Natália Coelho Couto de Azevedo Fernandes^{1,2} 

¹ Pathology Center, Adolfo Lutz Institute, São Paulo, SP, Brazil

² Laboratory of Wildlife Comparative Pathology, School of Veterinary Medicine and Animal Sciences, University of São Paulo, São Paulo, SP, Brazil

³ Zoonoses Surveillance, Municipal Health Department, Sorocaba, SP, Brazil

⁴ Sorocaba Zoological Park, Sorocaba, SP, Brazil

* Corresponding author: jumariotti.vet@gmail.com

Submitted: February 2nd, 2023. Accepted: April 19th, 2023.

Abstract

Paraguayan rainbow boa (*Epicrates crassus*) is widely distributed in the central portion of South America, threatened by human actions, and commonly maintained as a pet or in scientific collections. *Mycobacteroides chelonae-abscessus* group (MCABC) is the most important emerging nontuberculous mycobacterium pathogen in humans. This report describes a systemic MCABC infection in a captive *E. crassus*, with heterophilic granulomatous lesions in the lungs, liver, kidneys, and peripheral nervous system. Histochemical stains demonstrated Gram-positive and alcohol-acid-fast bacilli that cross-reacted with antigens of *Bacillus Calmette-Guérin* in immunohistochemistry. A nested polymerase chain reaction followed by DNA sequencing indicated the genus of the mycobacteria. Despite the rapid systemic spread of MCABC, it is necessary to develop safer, more rapid, and more effective treatments and diagnoses to understand the role of reptiles in this disease.

Keywords: Reptile pathology, Heterophilic granuloma, *Mycobacteriaceae*, wild animal, zoological garden.

Introduction

Epicrates crassus (Paraguayan rainbow boa) is a constrictor belonging to the Boidae family, widely distributed in the central portion of South America, threatened by human actions, and commonly maintained as a pet or in scientific collections (1). Mycobacterial infections are frequently found in captive snakes and can result in localized (pulmonary, oral, dermal) or disseminated lesions (14). The *Mycobacteroides*

chelonae-abscessus group (MCABC) members are close to the mycobacterial ancestor and include human and other mammals, reptiles, and fish pathogens (4). It is the most important emerging nontuberculous mycobacterium pathogen due to its high rate of antimicrobial resistance and rapid growth (12). They are alcohol-acid-fast, aerobic, non-spore-forming, and non-motile bacilli (4). This work aims to report an infection by MCABC in a captive *E. crassus* in the state of São Paulo, Brazil.

Case description

A captive adult female *E. crassus* presented with dehydration, hyporexia, weight loss, regurgitation, and skin lesions for three days. The serpent was referred to the veterinary sector, and the treatment consisted of fluid therapy, nutritional support, supplementation with vitamin C, and antibiotic therapy with enrofloxacin every 48 hours. The animal was found dead in the enclosure after three months. At postmortem examination, it was observed a poor body condition score, weighing 0.260 kg, and three skin lesions in the dorsal region of the middle third of the animal, ranging from 1-5 cm in length and from 0.5-1 cm in width, with red and necrotic areas. Foaming serous fluid content in the trachea and granulomas of approximately 2 mm of diameter distributed throughout the pulmonary parenchyma were observed (Fig. 1). The liver was brown with an irregular surface. The stomach had thickened mucosa.

For histologic analysis, fixed samples were embedded in paraffin wax, sectioned at 4 µm thick and stained with Hematoxylin and Eosin (HE), Brown-Brenn, Grocott-Gomori's methenamine silver, and Ziehl-Neelsen stains.

Histopathological examination revealed marked to moderate multifocal heterophilic granulomatous lesions in the parenchyma of the lungs, liver (Fig. 2A), and kidney, and a focal in periphery nervous system in the lungs (Fig. 2B). Severe diffuse hepatocyte macrovesicular degeneration was observed in liver sections. Abundant Gram-positive (Fig. 2C)

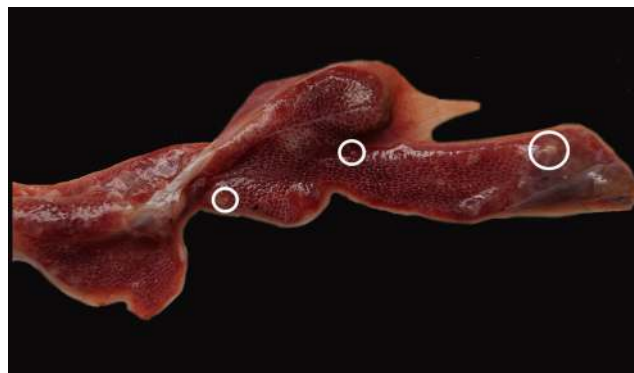

Figure 1. Lungs with granulomas (circles) of approximately 2 mm distributed throughout the parenchyma.

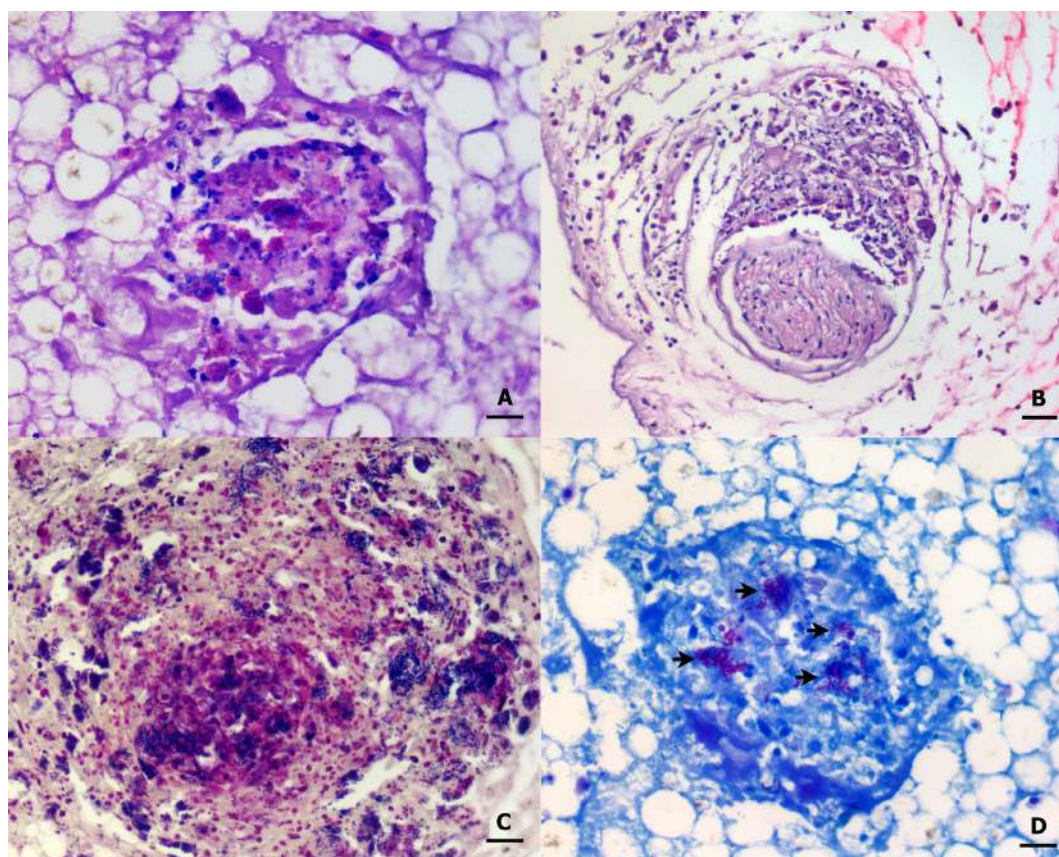


Figure 2. Photomicrographs of MCABC infection in an *E. crassus*. A- Heterophilic granuloma and macrovesicular degeneration of hepatocytes. Liver, HE, obj. 40x, bar = 10 µm. B- Granulomatous heterophilic perineuritis. Lung, HE, obj. 20x, bar = 20 µm. C- Gram-positive bacilli in the center of granuloma. Lung, Brown-Brenn stain, obj. 40x, bar = 10 µm. D- Acid alcohol resistant bacilli. Lung, Ziehl-Neelsen stain, obj. 40x, bar = 10 µm.

and acid-alcohol-resistant bacilli (Fig. 2D) were evidenced inside the granulomas. Deparaffinized 3µm sections of tissues in silanized slides were submitted to endogenous peroxidase block with 6% hydrogen peroxide for 30 min, followed by overnight incubation with anti-*Mycobacterium bovis* bacillus Calmette-Guérin- BCG (rabbit polyclonal, Dako A/S, Glostrup, Denmark) at a concentration of 1/30,000. The signal was amplified by an HRP-polymer detection system (Spring Bioscience, Pleasanton, CA, USA), and visualization was achieved by chromogenic substrate with diaminobenzidine. The samples were counterstained with Harris Hematoxylin (20 sec), followed by dehydration and slide mounting with synthetic resin. Pulmonary mammal tissue fragments known to be positive and confirmed by immunohistochemistry (IHC) were used as positive controls. The same steps were followed for the negative control, except the incubation of the primary antibody, replaced by non-immune serum from those species where the antibodies were generated. The IHC identified the presence of BCG antigens in granulomas of the kidney, lung, and liver (Fig. 3).

DNA from fresh frozen liver samples was extracted using Wizard® Genomic DNA Purification Kit (Promega, Madison, WI, USA). A semi-nested polymerase chain reaction (PCR) was performed with oligonucleotide primers specific for the 65-kDa antigen gene of mycobacteria (3) and GoTaq® Green Master Mix (Promega). The PCR amplicons were purified with ExoSap-IT (USB/Affymetrix, Santa Clara, CA, USA) and subjected to dye terminator cycle sequencing. Sequencing products were treated with BigDye XTerminator purification Kit (Applied Biosystems, Foster City, CA, USA) and electrophoresed on an Applied Biosystems 3500 genetic analyzer. The sequences were assembled and re-edited with sequence editor software BioEdit 7.2.5, and the consensus sequence was compared with the GenBank DNA database using the basic local alignment search tool (BLAST; <http://blast.ncbi.nlm.nih.gov/Blast.cgi> accessed on Nov 16, 2022). The result sequence was submitted to GenBank (Accession number OQ116678) and exhibited 96.27% nucleotide sequence similarity with *Mycobacteroides abscessus* complex and *Mycobacteroides chelonae* (GenBank accession number ON194490 for *M. abscessus* subsp. *Abscessus*; ON194488 for *M. abscessus* subsp. *massiliense* and OP899893 to OP899898 for *M. chelonae* isolated from human patients in Iran) in a query cover length of 98%.

Discussion

This report describes a systemic MCABC infection in a captive *E. crassus*, with heterophilic granulomatous lesions in respiratory, hepatic, renal, and peripheral nervous system associated with cachexia and hepatic metabolic steatosis. The MCABC infection was detected by histological, IHC, and molecular techniques. Fast-growing mycobacteria have been observed as important human pathogens, present

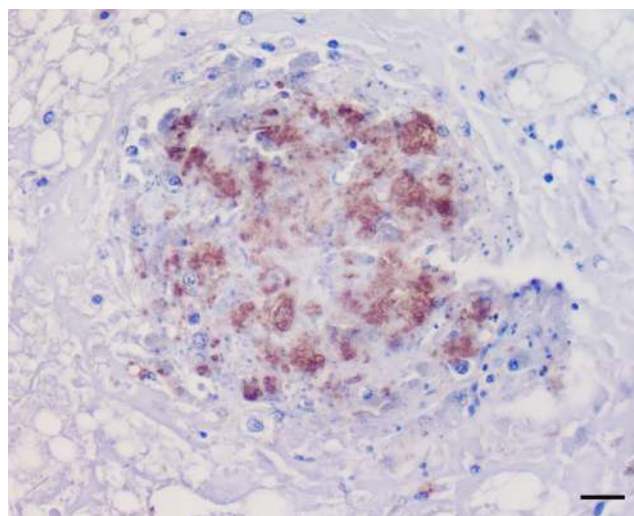


Figure 3. Positive immunoreactivity for rabbit polyclonal antibody directed against the *Mycobacterium bovis* bacillus Calmette-Guérin (BCG). Kidney, IHC, obj. 40x, bar = 10 µm.

in water sources, soil, and domestic and wild animals as opportunistic pathogens (5, 6, 16). The distinguished genus *Mycobacterioides* was one of five recently proposed genera in which *Mycobacterium* was divided based on the analysis of specific genetic markers (19). Previously designated as *M. chelonae* subspecies *abscessus*, *Mycobacteroides abscessus* complex was recognized as an independent species, and whole-genome sequencing-based phylogenetic studies supported the differentiation of three distinct subspecies: *M. massiliense*, *M. bolletii*, and *M. abscessus* (10, 11). However, it still has phylogenetic proximity to *M. chelonae* (10,11). MCABC also exhibits several similarities with *Mycobacterium tuberculosis*, such as the induction of granulomatous lesions (9), and the etiologic diagnosis is only possible by molecular techniques (6).

Mycobacterial infections have already been described in captive reptiles, most common by ubiquitous organisms with low prevalence and risk factors including immunosuppression, stress, poor nutrition, and chronic diseases (4). In the same collection of this snake, *M. fortuitum* in an ex-situ emerald tree boa (*Corallus batesii*) (Gonzaga et al., personal comm.) and *M. genavense* in two captive snakes have been detected by Ulmann et al. (20).

Of the rapid growers of the *Mycobacteriaceae* family, the most commonly reported cases in snakes are by *M. thamnopheos* and *M. chelonae* with systemic distribution (15, 17). There is only one report of the *Mycobacterium chelonae/abscessus* group in a crocodile (*Crocodylus niloticus*) with multifocal to coalescing heterophilic granulomas in the lungs and other organs (7). Mycobacterial infections typically culminate in granulomatous inflammation in captive snakes that can be localized (pulmonary, oral, dermal) or disseminated (14). They are most often characterized by the formation of

histiocytic or chronic granulomas; however, the histological appearance of these infections can vary widely, occasionally manifesting as heterophilic granulomas, depending on the agent involved and the host response (13, 18). Therefore, it is crucial to search for mycobacteria in this type of lesion (17). In heterophilic granulomas, there is degranulation and necrosis of heterophils in the center of the lesions, while at the edges, intact heterophils and macrophages are observed. As exudates in reptiles do not liquefy, it is believed that forming granulomas is a way to disperse the infectious process (18). The rapidly growing mycobacteria usually stain quite well with a Gram stain, as Gram-positive bacilli, and may not be easily recognized as acid-fast organisms.

MCABC has been described on a global scale as an emerging, underestimated pathogen of great relevance to One Health. Human infections without risk factors with local or disseminated lesions have already been reported (8). MCABC is intrinsically resistant to many classes of antibiotics, such as beta-lactams, aminoglycosides, and rifamycin (2). Despite the rapid spread and difficulties in treating MCABC, it is necessary to invest in developing safer, more rapid, and more effective treatments and diagnoses. More studies should be conducted to establish the role of reptiles infected by mycobacteria as potential reservoirs and sources of infection for human or other animal pathogen transmission.

Conflict of Interest

The authors declare no competing interests.

Acknowledgments

We would like to thank all staff at Biological Sample Management Center, Anatomic Pathology Laboratory, and Quantitative Pathology Laboratory at Adolfo Lutz Institute.

Funding

This study was supported by Grupo de Apoio às Políticas de Prevenção e Proteção à Saúde/Fundo Especial de Saúde para Imunização em Massa e Controle de Doenças (GAPS/FESIMA # 040/2019 and # 28/2020), Conselho Nacional de Desenvolvimento Científico e Tecnológico (CNPq) (#404510/2021), and PDIP - São Paulo Research Foundation (FAPESP) (grant# 2017/50333-7).

Additional information

The registration access on the National System for Genetic Heritage and Associated Traditional Knowledge Management (SisGen, Brazil) was under number AD49254.

References

1. Arzamendia V, Fitzgerald L, Scrocchi G, Giraud A, Williams J, Silveira AL, Prudente ALC, Argôlo AJS, Abrahão CR, Nogueira CC, Barbo FE, Costa GC, Pontes GMF, Colli GR, Zaher HD, Borges-Martins M, Martins MRC, Oliveira ME, Passos PGH, Bérnils RS, Sawaya RJ, Cechin CTZ, Guedes da Costa, TB. *Epicrates crassus* [Internet]. *The IUCN Red List of Threatened Species* 2021: e.T15154897A15155053; 2021 [updated 2021; cited 2023 Jan 03]. Available from: <https://dx.doi.org/10.2305/IUCN.UK.2021-2.RLTS.T15154897A15155053.en>.
2. Chong SL, Tan JL, Ngeow YF. The resistomes of *Mycobacteroides abscessus* complex and their possible acquisition from horizontal gene transfer. *BMC Genomics*. 2022;23(1):715.
3. Cook SM, Bartos RE, Pierson CL, Frank TS. Detection and characterization of atypical mycobacteria by the polymerase chain reaction. *Diagn Mol Pathol*. 1994;3(1):53-8.
4. Ebani VV, Fratini F, Bertelloni F, Cerri D, Tortoli E. Isolation and identification of mycobacteria from captive reptiles. *Vet Sci*. 2012;93(3):1136-8.
5. Ebani VV. Domestic reptiles as source of zoonotic bacteria: a mini review. *Asian Pac J Trop Med*. 2017;10(8):723-8.
6. Fogelson SB, Camus AC, Lorenz WW, Vasireddy R, Vasireddy S, Smith T, Brown-Elliott BA, Wallace Jr. RJ, Hasan NA, Reischl U, Sanchez S. Variation among human, veterinary and environmental *Mycobacterium chelonae-abscessus* complex isolates observed using core genome phylogenomic analysis, targeted gene comparison, and antimicrobial susceptibility patterns. *PLoS ONE*. 2019;14(3):e0214274.
7. Gobbi M, Corneli S, D'Avino N, Manuali E, Di Paolo A, Sebastiani C, Ciullo M, Tentellini M, Pacciarini ML, Sebastianelli M, Pavone S, Mazzone P. Granulomatous pneumonia in a Nile crocodile (*Crocodylus niloticus*) caused by a member of *Mycobacterium Chelonae/Abscessus* group. *J Zoo Wildl Med*. 2010;41(3):550-4.
8. Johansen MD, Herrmann JL, Kremer L. Nontuberculous mycobacteria and the rise of *Mycobacterium abscessus*. *Nat Rev Microbiol*. 2020;18(7):392-407.
9. Kim BJ, Kim GN, Kim BR, Shim TS, Kook YH, Kim BJ. New *Mycobacteroides abscessus* subsp. *massiliense* strains with recombinant hsp65 gene laterally transferred from *Mycobacteroides abscessus* subsp. *abscessus*: Potential for misidentification of *M. abscessus* strains with the hsp65-based method. *PLoS ONE*. 2019;14(9):e0220312.
10. Lee MR, Sheng WH, Hung CC, Yu CJ, Lee LN, Hsueh PR. *Mycobacterium abscessus* complex infections in humans. *Emerg Infect Dis*. 2015;21(9):1638-46.

11. Lopeman RC, Harrison J, Desai M, Cox JAG. *Mycobacterium abscessus*: environmental bacterium turned clinical nightmare. *Microorganisms*. 2019;7(3):90.
12. Medjahed H, Gaillard JL, Reytrat JM. *Mycobacterium abscessus*: a new player in the mycobacterial field. *Trends Microbiol*. 2010;18(3):117-23.
13. Montali RJ. Comparative pathology of inflammation in the higher vertebrates (reptiles, birds and mammals). *J Comp Pathol*. 1988;99(1):1-26.
14. Ossiboff RJ. Serpentes. In: Terio K, Mcaloose D, St Leger J, editors. *Pathology of Wildlife and Zoo Animals*. London: Elsevier; 2018. p. 897-919.
15. Pasmans F, Martel A, Jacobson ER. Bacterial diseases of reptiles. In: Jacobson, ER, Garner, MM, editors. *Infectious Diseases and Pathology of Reptiles*. 2nd ed. Boca Raton: CRC Press; 2020. p. 705-94.
16. Sfeir M, Walsh M, Rosa R, Aragon L, Liu SY, Cleary T, Worley M, Frederick C, Abbo LM. *Mycobacterium abscessus* complex infections: a retrospective cohort study. *Open Forum Infect Dis*. 2018 Feb 09;5(2):ofy022.
17. Soldati G, Lu ZH, Vaughan L, Polkinghorne A, Zimmermann DR, Huder JB, Pospischil A. Detection of mycobacteria and chlamydiae in granulomatous inflammation of reptiles: a retrospective study. *Vet Pathol*. 2004;41(4):388-97.
18. Stacy BA, Pessier AP, Ossiboff RJ. Host Response to infectious agents and identification of pathogens in tissue sections. In: Jacobson, ER, Garner, MM, editors. *Infectious Diseases and Pathology of Reptiles*. 2nd ed. Boca Raton: CRC Press; 2020. p. 375-422.
19. Turenne CY. Nontuberculous mycobacteria: Insights on taxonomy and evolution. *Infect Genet Evol*. 2019;72:159-168.
20. Ullmann LS, das Neves Dias-Neto R, Cagnini DQ, Yamatogi RS, Oliveira-Filho JP, Nemer V, Teixeira RH, Biondo AW, Araújo JP Jr. *Mycobacterium genavense* infection in two species of captive snakes. *J Venom Anim Toxins Incl Trop Dis*. 2016;22:27.