



## Case Report

# Pleural lipoma in a horse

Crísan Smaniotto<sup>1\*</sup>, Vinicius Dahm<sup>1</sup>, Amália Ferronato<sup>1</sup>, Alessandra da Cruz<sup>1</sup>,  
 Lorena dos Santos Pinheiro<sup>1</sup>, Pietra Malu Franzener Detoni<sup>1</sup>, Bianca De Fátima Dallo<sup>2</sup>,  
 Maristela de Cassia Seudo Lopes<sup>3</sup>, Aline de Marco Viott<sup>3</sup>

<sup>1</sup> Veterinary Pathology Laboratory, Universidade Federal do Paraná (UFPR), Palotina, PR, Brazil

<sup>2</sup> Large Animal Medical and Surgical Clinic, Universidade Federal do Paraná (UFPR), Palotina, PR, Brazil

<sup>3</sup> Department of Veterinary Sciences, Universidade Federal do Paraná (UFPR), Rua Pioneiro, 2153, Jardim Dallas, 85950-000, Palotina, PR, Brazil

\*Corresponding author: [crisan.smaniotto@ufpr.br](mailto:crisan.smaniotto@ufpr.br)

Submitted: April 3<sup>rd</sup>, 2023. Accepted: August 28<sup>th</sup>, 2023.

### Abstract

Lipoma is a benign neoplasia originating from adipocytes. It is frequently diagnosed in veterinary medicine and usually presents as cutaneous nodules but can also occur inside body cavities in less common cases. There are several reports of abdominal cavity neoplasia in horses, an important cause of colic in these animals. No cases of neoplasia in the thoracic cavity have been reported for this species. Therefore, the aim of this study was to report an intrathoracic lipoma located in the visceral pleura of an American Quarter Horse. The equine was euthanized after relapses of surgically resolved colic and unresponsive visceral pain. At necropsy, we observed fibrinous peritonitis, adherence of intestinal loops in its abdominal cavity, and hemomelasma ilei in several intestine segments. In the thoracic cavity, a whitish, firm, pendulous structure with a regular surface measuring approximately 4.0 cm x 3.0 cm was observed in the pleura of the right caudal lung lobe—and diagnosed by histopathology as lipoma. Due to the rarity of this type of lipoma presentation and considering the absence of reports of its occurrence in horses, this report is essential to list this neoplasia as a differential in pleural masses in the species.

**Keywords:** adipocytes, intrathoracic tumor, mesenchymal neoplasia.

### Introduction

Lipoma is a benign neoplasia of mesenchymal origin characterized by the proliferation of well-differentiated adipocytes. It is most often found in the subcutaneous tissue of middle-aged to elderly dogs, although other species, such as horses and cats, can also develop this type of neoplasia. In atypical manifestations, lipoma can also develop outside the subcutaneous tissue and occur in the chest wall, abdominal cavity, medullary canal, vulva, and vagina (6, 7).

This neoplasia is often reported as an important cause of colic syndrome in horses, especially in cases of intestinal strangulation due to the development of mesentery-originated pedunculated lipomas (3). Affected animals tend to present acute clinical signs due to blood vessel compression and

blood flow restriction, followed by hypoxia, ischemia, and intestinal necrosis (5).

Intrathoracic lipomas can originate from the bronchi, lung, mediastinum, diaphragm, and chest wall, which are considered uncommon manifestations (11). It can develop in the submesothelial layers of the parietal pleura but can also extend into the subpleural, pleural, or extra-pleural spaces (4). This study aims to report a rare intrathoracic lipoma located in the visceral pleura of an equine.

### Case description

A male American Quarter Horse, five years old and 400 kg heavy, was referred to the Veterinary Hospital exhibiting acute abdomen, with surgical outcome.

Significant changes in the intestinal loops were observed during the exploratory celiotomy due to a twisting of the ileum, displacement of the cecum, and pelvic flexure impaction. Although bowel motility returned after the twist was corrected, the prognosis was reserved due to the high risk of postoperative adherence. Therapy was instituted according to the clinical signs. After ten days, the animal presented acute and severe pain that did not respond to potent drugs, which led to a receliotomy – when the hypothesis of intestinal loop adhesion was confirmed. All reasonable maneuvers were performed, but after recovery from anesthesia, the clinical signs of severe pain persisted—even under strong analgesia. Thus, euthanasia and necropsy were performed.

Fibrinous peritonitis and moderate hemorrhagic foci in the omentum, mesentery, and serosa of the small and large intestines were observed during the necropsy. The omentum, mesentery, and serosal layers of the cecum were intensely hyperemic. There were multiple elevated irregular areas, 1.0 to 2.0 cm in diameter, showing a blackish-red appearance with a whitish center in the serosa of the duodenum, jejunum, ileum, and cecum. Histopathological evaluation of these lesions revealed the presence of lymphohistiocytic inflammatory infiltrate, proliferation of fibrous connective tissue, hemosiderosis, and hemorrhagic areas compatible with hemomelasma ilei.

In the chest cavity's macroscopic evaluation, the lung was moderately hyperemic, with areas of emphysema near the edges and a large amount of pulmonary edema. A pendulous structure, whitish, firm, with a regular surface, and measuring approximately 4.0 cm x 3.0 cm (Fig. 1A), was observed in the pleural region of the right caudal lung lobe. This structure was firm and heterogeneous, with whitish edges and a yellowish center. On microscopic evaluation, dense connective tissue was highly diffused in the structure's periphery. In the center,

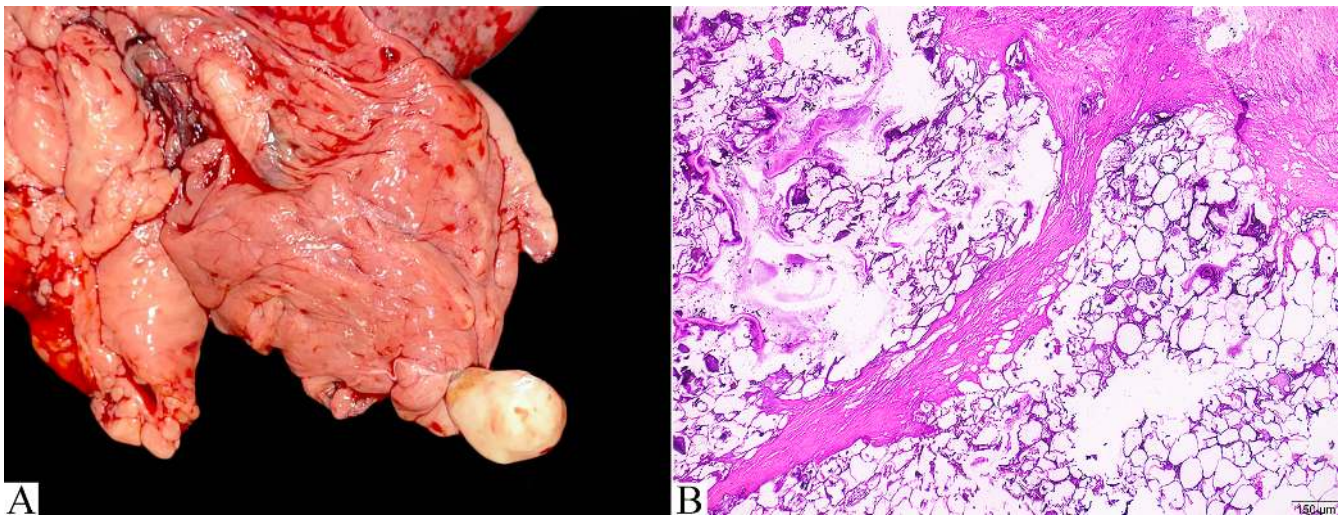
there were well-differentiated adipocytes with granular, amorphous, basophilic, and vitreous (mineralized) material and eosinophilic amorphous material with intermingled nuclear remnants (necrosis) (Fig. 1B).

## Discussion

Intracavitary lipomas are not commonly reported in veterinary medicine. Moreover, the underdiagnosis of this condition is also frequent, likely due to the absence of clinical signs when the lipomas do not interfere with the functionality of adjacent organs (10). There are many reports of intra-abdominal lipomas in horses (1, 8, 12). However, we found no report in the literature describing this intrathoracic neoformation in the species.

Coughing, dyspnea, and lethargy are commonly described clinical manifestations in cases of intrathoracic lipoma in other species, such as dogs and cats. Some reports describe relatively large lipomas in the thoracic cavity of these animals, reaching up to 18.0 cm, alongside clinical respiratory manifestations (2, 9, 10). The clinical picture observed in these cases was likely a consequence of lung compression and the resulting decrease in the organ's capacity to expand. Nevertheless, the patient in this study was referred for care due to a gastrointestinal disturbance, with no clinical manifestations related to intrathoracic neoplasia. Furthermore, the reported mass was small, well-delimited, and located in the distal portion of the visceral pleura of the right caudal lobe.

Lipoma diagnosis is easily performed, primarily through histopathological evaluation, where the proliferation of well-differentiated adipocytes can be observed, as in the present case report. The macroscopic appearance of



**Figure 1.** Lung, lipoma, equine. **A-** Presence of a peduncular whitish structure on the pleural surface of the right caudal lung lobe. **B-** Histological section of the lung neoformation, marked by the proliferation of well-differentiated adipocytes, which sometimes exhibit mineralized areas and necrosis, surrounded by a thick layer of fibrous connective tissue. HE, obj. 4.2x.

the reported mass is somewhat atypical and different from the common manifestation, where well-circumscribed, soft, non-encapsulated formations, ranging from whitish to yellowish, are to be expected (6). Because it is a peduncular mass, strangulation and consequent tissue necrosis and fibrosis can occur, as observed in other cases of intra-abdominal lipoma.

The anatomopathological findings described in this report were essential for the diagnosis, in addition to being crucial and sufficient to list lipoma as a differential diagnosis in cases of intrathoracic masses in horses. Finally, diagnosing these tumors is important, in order to clarify their low prevalence or underdiagnosis.

### Conflict of Interest

The authors declare no competing interests.

### Acknowledgments

The authors would like to thank the Academic Publishing Advisory Center (*Centro de Assessoria de Publicação Acadêmica*, CAPA – [www.capa.ufpr.br](http://www.capa.ufpr.br)) of the Federal University of Paraná (UFPR) for assistance with English language translation and developmental editing.

### References

1. Bauck AG, Graham AS, Smith A, Rapp HJ, Freeman DE. Mesenteric strangulation by pedunculated lipomas without involvement of associated intestine in four horses. *Equine Vet. Educ.* 2020;32(8):141-6.
2. Costa PRS. Lipoma intratorácico em cão. *Rev Bras Ciênc Vet.* 2003;10(1):59-60.
3. Freeman DE, Schaeffer DJ. Age distributions of horses with strangulation of the small intestine by a lipoma or in the epiploic foramen: 46 cases (1994–2000). *J Am Vet Med Assoc.* 2001;219(1):87-9.
4. Gaerte SC, Meyer CA, Winer-Muram HT, Tarver RD, Conces DJ Jr. Fat-containing lesions of the chest. *Radiographics.* 2002;22(1):61-78.
5. Gelberg HB. Alimentary system and the peritoneum, omentum, mesentery, and peritoneal cavity. In: Zachary JF, editor. *Pathologic Basis of Veterinary Disease*. St. Louis, Missouri: Elsevier; 2017. p. 371-86.
6. Hendrick MJ. Mesenchymal tumors of the skin and soft tissues. In: Meuten DJ, editor. *Tumors in Domestic Animals*. Ames, Iowa: John Wiley & Sons, INC; 2017. p. 158-9.
7. Jark PC, Filho NPR, Ferreira MGPA, Ramos CS, Pascoal ALC. Sarcomas de tecidos moles cutâneos e subcutâneos em cães. In: Daleck CR, De Nardi AB, editores. *Oncologia em cães e gatos*. Rio de Janeiro: Guanabara Koogan LTDA; 2016. p. 757-75.
8. Mair TS, Smith LJ. Survival and complication rates in 300 horses undergoing surgical treatment of colic. Part 1: Short-term survival following a single laparotomy. *Equine Vet J.* 2005;37(4):296-302.
9. Miles J, Clarke D. Intrathoracic lipoma in a Labrador retriever. *J Small Anim Pract.* 2001;42(1):26-8.
10. Nickel J, Mison M. Intrathoracic lipoma in a cat. *J Am Anim Hosp Assoc.* 2011;47(6):127-30.
11. Politis J, Funahashi A, Gehlsen JA, DeCock D, Stengel BF, Choi H. Intrathoracic lipomas. Report of three cases and review of the literature with emphasis on endobronchial lipoma. *J Thorac Cardiovasc Surg.* 1979;77(4):550-6.
12. Verwilghen D, Hernlund E, Ekman S, Pringle J, Johnston C, Van Galen G. A giant nonstrangulating mesenteric lipoma as a cause of recurrent colic in a horse. *Equine Vet Educ.* 2013;5(9):451-5.