






## Case Report

# Marked systemic necrotizing disease in a *Leptodactylus vastus* (Anura: Leptodactylidae) from an urban reserve in northeastern Brazil

Roberta da Rocha Braga<sup>1\*</sup> , Bruna Kassia Nunes Eleutério<sup>1,2</sup> ,  
Renan Carlos de Souza Lima<sup>1,2</sup>, Tatiana Feitosa Quirino<sup>1</sup> 

<sup>1</sup> Núcleo Regional de Ofiologia, Universidade Federal do Ceará, Avenida Humberto Monte, Campus do Pici, Bloco 905, Fortaleza, CE, Brazil.

<sup>2</sup> Centro Universitário FAMETRO, Rua Liberato Barroso, 1391, Fortaleza, CE, Brazil.

\*Corresponding author: [robertarocha@ufc.br](mailto:robertarocha@ufc.br)

Submitted: April 9<sup>th</sup>, 2023. Accepted: September 1<sup>st</sup>, 2023.

## Abstract

The decline of amphibian populations concerns scientists worldwide and has been related to the spreading infectious diseases, among other environmental factors. Acute mass mortality with hemorrhagic and necrotic lesions has been described and associated with wild amphibian viruses. These diseases were first recorded in Central America and Australia in the early 1990s and later in Brazilian Atlantic Forest fragments. Epizootiological data on these infections must be included in other Brazilian phytogeographic regions and domains. This work aimed to report a systemic necrotic morbid state in a native *Leptodactylus vastus* from an urban reserve in northeastern Brazil, describing clinical and pathological findings and discussing its importance and likely etiologies. An adult *L. vastus* presented an erythematous oral cavity with multifocal point-like erosions, sublingual congested vessels, oropharyngeal edema, and mild esophageal mucosal prolapse. After therapeutic protocol, the patient showed no improvement; then, he was humanely euthanized. Necropsy demonstrated moderate to marked multicentric chronic necrotizing lesions. Histopathology revealed diffuse necrotic tissues with a few intracytoplasmic amphophilic inclusions in cellular remnants, with minor hemoparasites, helminths, and bacterial granulomatous coinfections. Clinical and pathological findings suggested a major chronic viral infection with minor coinfections. In the current case, confirmation of etiology struggled with financial and logistic limitations. Future partnerships will enable definitive diagnostics. This is the first record of systemic necrotizing disease in a wild frog in Ceará state, northeastern Brazil, and it is a red flag to emerging infectious diseases surveillance in this geographic area.

**Keywords:** necrosis, infectious diseases, Leptodactylidae

## Introduction

According to the latest International Union for Conservation of Nature's Red List of Threatened Species, 41% of amphibian species are threatened with extinction (17). The worldwide decline of amphibian populations concerns environmental scientists and has been related to climate change, natural habitat fragmentation, invasive species introduction, and the spreading infectious diseases (2).

In Brazil, agents of emerging infectious diseases were already detected in Atlantic Forest remnants (6, 28) and in commercial vivaria facilities in the center-west (19), southeast (24) and south regions (26). Marked diffuse hyperkeratosis indicates chytridiomycosis (27), while acute mass mortality with hemorrhagic lesions or chronic systemic necrotic lesions suggests Ranaviral infection (21). Epizootiological data on these infections must be included in other Brazilian phytogeographic regions and domains.

This work aimed to report a systemic morbid state in a native *Leptodactylus vastus* from Ceará state, northeastern Brazil, describing the clinical and pathological findings and discussing its importance and likely etiologies.

### Case description

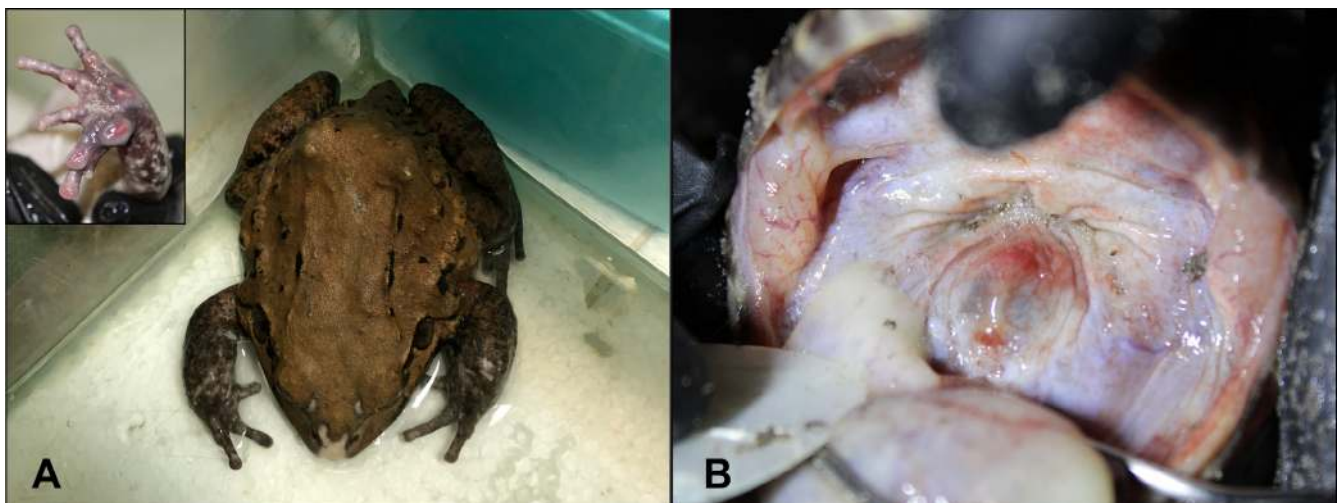An anuran health survey was performed in the Pici Woods Urban Reserve (PWUR) from June to August 2022. PWUR is a law-protected area of residual coast vegetation circumjacent to the Federal University of Ceará (3°44'51.4"S, 38°34'38.6"W), in Fortaleza, CE, northeastern Brazil. Procedures and ethics were authorized by the National Biodiversity Authorization System (SisBio n° 82318) and Committee for Ethics in Animal Experimentation (CEUA-UFC n°9036080322). An adult male northeastern pepper frog (*Leptodactylus vastus* Lutz, 1930; Anura: Leptodactylidae), snout-vent length 122 mm, body mass 253 g, presented an erythematous oral cavity with multifocal point-like erosions, sublingual congested vessels, oropharyngeal edema, and mild esophageal mucosal prolapse (Fig. 1). The alimentary tract held no palpable food content. The patient was carried to the Herpetology and Ophiology Laboratory (NUROF-UFC). It was kept in a 30-liter glass aquarium at room temperature, filled with dechlorinated shallow water. The initial hematology findings revealed hemoparasite infection and suggested leukopenia and regenerative anemia, with eventual spherocytes and microcytes. Glucose index was 18mg/dL.

According to the clinical findings, the patient was assessed to be in an acute stomatitis/esophagitis. The general state was initially treated with an amphibian Ringer-Lactate fluid immersion over 30 minutes (29), and parenteral enrofloxacin 5.0mg/kg and meloxicam 0.1mg/kg every 24 hours. Baby mice and insects were offered as food but

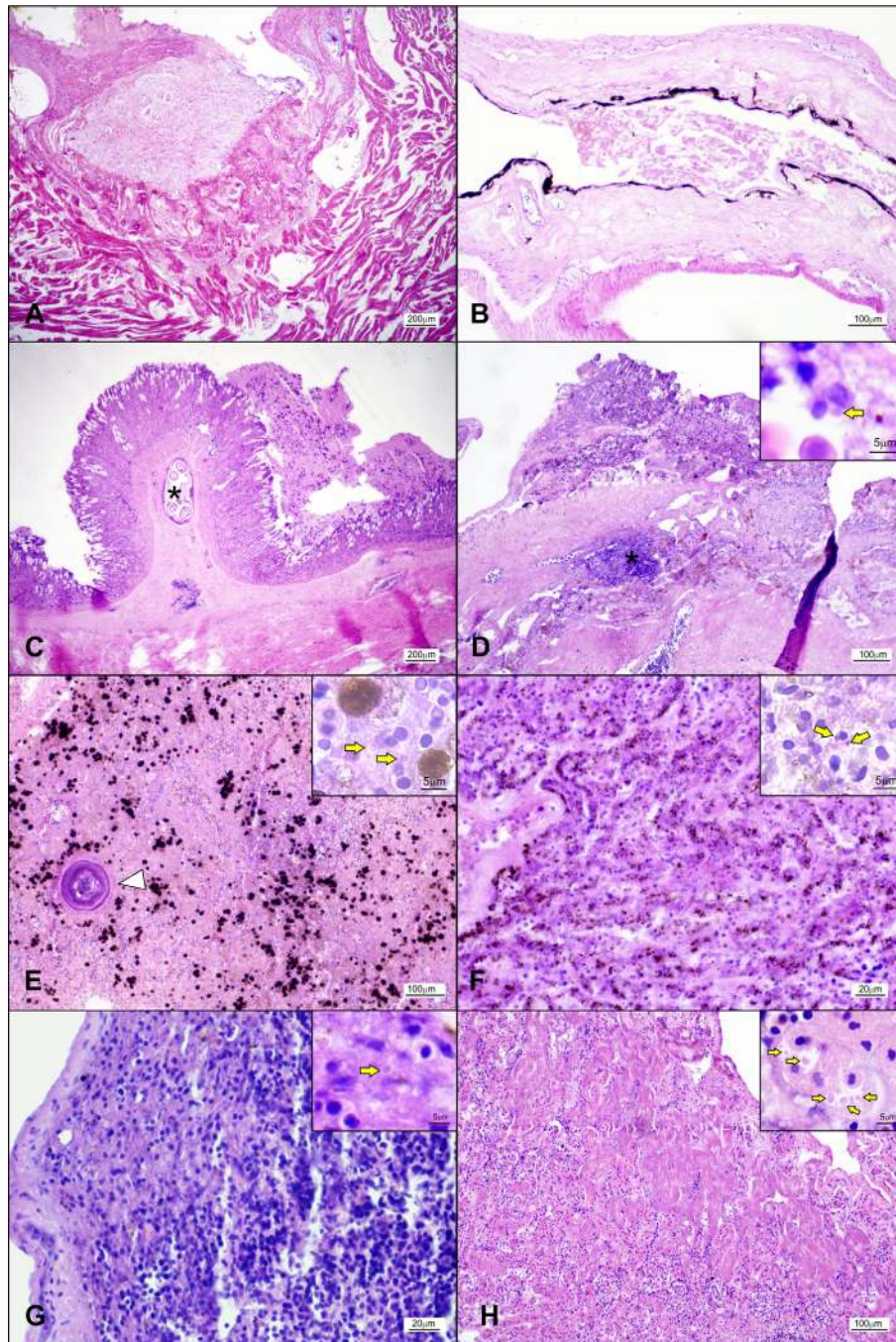
rejected. Ten days later, the patient showed 10% weight loss, weakness, and anorexia, developing rostral, dorsal, and forelimbs locally extensive palmar hemorrhagic ulcers. Cutaneous imprint cytology showed neutrophilic-histiocytic inflammatory exudate, and bacterioscopy resulted in *Enterococcus* sp. and *Pseudomonas* sp. infection. After 13 days of treatment, the patient presented enlarged to coalescent cutaneous ulcers and no improvement in overall health. The follow-up hematological results showed no enhancement. Due to these facts, euthanasia was performed by intrathecal Lidocaine hydrochloride 30mg/kg (4, 7). Necropsy revealed moderate to marked multicentric chronic necrotizing lesions, including hypertrophic and congested stomach, with eroded mucosal folds and cystic submucosal helminth (thin-walled collagen capsulated nematode, measuring 450 x 200µm, and absent to mild inflammation infiltrate); dilated and thin-walled colon; friable and enlarged liver; pale, friable, and shrunken pancreas and spleen, and pale, enlarged, and hyperemic kidneys. Histopathological analysis (Fig. 2) demonstrated diffuse hepatic, splenic, pancreatic, renal, hematopoietic, and lymphoid necrosis, presenting occasional intracytoplasmic amphophilic inclusion bodies in parenchymal cells. Moderate ulcerative necrosis was observed in stomach and colon, and diffuse degenerated epithelium and fibrosis of lamina propria in oropharynx. Focal marked myocardial necrosis was observed. Cystic helminths and microgranulomas were observed and considered minor findings.

### Discussion

According to the World Organisation for Animal Health, the presented clinical and pathological findings are



**Figure 1.** Clinical findings in an urban *Leptodactylus vastus*. A- *L. vastus* patient showing rostral and palmar (detail on top right) ulcers. B- Oral cavity showing pale mucosa with multifocal point-like erosions, mild esophageal mucosal prolapse, with erythema and edema.



**Figure 2.** Histopathology main findings, intracytoplasmic amphophilic inclusion bodies in parenchymal cells (arrows, details on top right) in an urban *Leptodactylus vastus*. A- Heart, focal marked myocardial degeneration/necrosis. HE, bar = 100 µm. B- Pharynx, diffuse marked degenerated epithelium and fibrosis of lamina propria. HE, bar = 200 µm. C- Stomach, moderate locally extensive mucosal necrosis, moderate to marked lymphocytic exudate with cell debris in the lumen, multifocal necrosis of the gastric glands, cystic helminth in the submucosa (asterisk). HE, bar = 200 µm. D- Colon, diffuse moderate to marked mucosal ulcerative necrosis, lymphoid nodule necrosis (asterisk), submucosal fibrosis. HE, bar = 100 µm and 5 µm. E- Liver, diffuse moderate to marked parenchymal necrosis, melanomacrophage hyperplasia, hematopoietic necrosis, focal caseating granuloma. HE, bar = 100 µm and 5 µm. F- Pancreas, diffuse moderate parenchyma necrosis. HE, bar = 20 µm and 5 µm. G- Spleen, Diffuse moderate lymphoid hyperplasia, multifocal to coalescent lymphoid necrosis. HE, bar = 20 µm and 5 µm. H- Kidney, diffuse marked tubular degeneration/necrosis, with interstitial multifocal moderate lymphocytic inflammatory infiltration. HE, bar = 100 µm and 5 µm.

convergent and strongly suggestive of Ranavirus infection (30), once no other virus types have been associated with similar pathological findings (2, 11, 25). Minor findings contained focal caseating microgranulomas in the liver, spleen, and kidneys, suggesting *Mycobacteria*, already reported in the same geographic region (3, 23), and cystic gastric helminths, suggesting *Physaloptera* sp. (12).

Erythema, edema and multifocal punctiform erosions in the oropharynx, empty stomach, and low glucose index indicated anorexia and likely gastrointestinal changes, confirmed by pathological findings. Ulcerative necrotizing dermatitis and gastroenterocolitis, necrotizing nephritis/pancreatitis/splenitis, lymphoid depletion, and hemorrhagic erosions on palmar/plantar surfaces were widely compiled as Ranavirus infection findings (20, 21).

Outbreaks worldwide, associated with massive die-offs of ectothermic vertebrate species, have been reported since the 1980s (9). Among a wide range of possible hosts, amphibians seem to be the most susceptible ones from which Ranavirus was first isolated (15). The infection is highly transmissible among tadpoles and post-metamorphic individuals, resulting in acute clinical signs and sudden death, and usually produces variable sensitivity in molecular tests. The infection may persist subclinically among the surviving individuals and result in viral reservoirs (16, 21). Diagnostic methods to confirm etiology include polymerase chain reaction/sequencing, viral isolation culture, antigen-capture ELISA, immunoperoxidase stain, and immunoelectron transmission microscopy (30). Unfortunately, none of these were locally available to confirm the etiology of the current findings.

Most records revealed no severe or chronic pathological changes in their findings. The reported injuries include mild to moderate hemorrhagic and necrotizing lesions in the kidneys, alimentary tract, liver, and skin (21). Experimentally based descriptions of Ranavirus pathology followed the disease course at a maximum of 21 days post-infection (1, 13, 14) and presented acute/subacute mild and moderate inflammatory features. Therefore, the current case represented a chronic disease course and might have involved a non-lethal virulence virus strain or an adapted host species. Some authors highlighted that wild strains have shown less virulence than captivity-isolated ones (5). The current report comprised marked necrosis of several organs that would obviously have led to kidney and liver failure if the morbid process had continued spontaneously. Skin ulcers rapidly progressed during the therapeutic protocol, consistent with reports of later deaths by secondary infection breakdown (8, 10, 18, 22).

Clinical and pathological findings suggested major chronic viral infection, most likely Ranavirus, with minor hemoparasites, helminths, and bacterial granulomatous coinfections. In the current case, confirmation of etiology struggled with financial and logistic limitations. However, future partnerships will enable definitive diagnostics. This is the first record of systemic necrotizing disease in a wild frog in

Ceará, northeastern Brazil, and it is a red flag to implement the surveillance of emerging infectious diseases in this geographic area. Active biomonitoring and blood sampling are in progress.

### Conflict of Interest

The authors declare no competing interests.

### References

1. Alfaia SR, Cândido M, Sousa RLM, Harakava R, Casiano LL, Martins AMCRP da F, Ferreira, CM. Experimental Frog Virus 3 infection using Brazilian strain: amphibians' susceptibility. *Braz J Vet Res Anim Sci.* 2020;57(4): e169134.
2. Blaustein AR, Urbina J, Snyder PW, Reynolds E, Dang T, Hoverman JT, Han B, Olson DH, Searle C, Hambalek NM. Effects of emerging infectious diseases on amphibians: A review of experimental studies. *Diversity.* 2018;10(3):81.
3. Braga RR, Bezerra CH, Lopes CEB, Araújo DV, Hissa DC. Systemic mycobacteriosis: incidental findings in a wild *Leptodactylus vastus* (Amphibia-Anura:Leptodactylidae) in Ceará, Brazil. *Braz J Vet Pathol.* 2020;13(1):365-6.
4. Brasil. Conselho Nacional de Controle de Experimentação Animal (CONCEA). Resolução Normativa nº 37, de 15 de fevereiro de 2018. Brasília. Conselho Nacional de Controle de Experimentação Animal. Diretrizes da prática de eutanásia. 2018;49.
5. Brunner JL, Storfer A, Gray MJ, Hoverman JT. Ranavirus Ecology and Evolution: From Epidemiology to Extinction. In: Gray MJ, Chinchar VG, editors. *Ranaviruses.* Cham: Springer; 2015. p. 71–104.
6. Carnaval ACOQ, Puschendorf R, Peixoto OL, Verdade VK, Rodrigues MT. Amphibian Chytrid Fungus Broadly Distributed in the Brazilian Atlantic Rain Forest. *Ecohealth.* 2006;3(1):41-8.
7. Chatigny F, Kamunde C, Creighton CM, Stevens ED. Uses and doses of local anesthetics in fish, amphibians, and reptiles. *J Am Assoc Lab Anim Sci.* 2017;56(3):244-53.
8. Cheng K, Jones M, Jancovich J, Burchell J, Schrenzel M, Reavill D, Imai DM, Urban A, Kirkendall M, Woods LW, Chinchar VG, Pessier AP. Isolation of a Bohle-like iridovirus from boreal toads housed within a cosmopolitan aquarium collection. *Dis Aquat Organ.* 2014;111(2):139-52.
9. Chinchar VG, Hyatt A, Miyazaki T, Williams T. Family Iridoviridae: poor viral relations no longer. *Curr Top Microbiol Immunol.* 2009; 328:123-70.
10. Cunningham A, Hyatt A, Russell P, Bennett P. Emerging epidemic diseases of frogs in Britain are dependent on the source of Ranavirus agent and the route of exposure. *Epidemiol Infect.* 2007;135(7):1200-12.
11. Densmore CL, Green DE. Diseases of amphibians. *ILAR J.* 2007;48(3):235-54.

12. Felix-Nascimento G, Vieira FM, Gomes ECA, Albinati ACL, Muniz-Pereira LC, Moura GJB, Ribeiro LB, Oliveira JB. Morphological description of infective larval stage of *Physaloptera* (Spirurida: Physalopteridae), and histological lesions in the paratenic host *Leptodactylus macrosternum* (Anura: Leptodactylidae) in Caatinga biome, Brazil. *Rev Mex Biodivers*. 2022;93: e933772.
13. Forzán MJ, Jones KM, Ariel E, Whittington RJ, Wood J, Markham RJF, Daoust PY. Pathogenesis of Frog Virus 3 (Ranavirus, Iridoviridae) infection in Wood Frogs (*Rana sylvatica*). *Vet Pathol*. 2017;54(3):531-548.
14. Forzán MJ, Jones KM, Vanderstichel RV, Wood J, Kibenge FSB, Kuiken T, Wirth W, Ariel E, Daoust PY. Clinical signs, pathology and dose-dependent survival of adult wood frogs, *Rana sylvatica*, inoculated orally with frog virus 3 Ranavirus sp., Iridoviridae. *J Gen Virol*. 2015;96(5):1138-49.
15. Granoff A, Came P, Breeze D. Viruses and renal carcinoma of *Rana pipiens*: I. The isolation and properties of virus from normal and tumor tissues. *Virology*. 1966;29(1):133-48.
16. Green DE, Converse KA, Schrader AK. Epizootiology of sixty-four amphibian morbidity and mortality events in the USA, 1996-2001. *Ann NY Acad Sci*. 2002;969(1):323-39.
17. International Union for Conservation of Nature (IUCN). The IUCN Red List of Threatened Species. Version 2022-2. <https://www.iucnredlist.org/es/>. Accessed on 3 Apr, 2023.
18. Jancovich J, Davidson E, Morado J, Jacobs B, Collins J. Isolation of a lethal virus from the endangered tiger salamander *Ambystoma tigrinum stebbinsi*. *Dis Aquat Organ*. 1997;31(3):161-7.
19. Mazzoni R, Mesquita AJ, Fleury LFF, Brito WMED, Nunes IA, Robert J, Morales H, Coelho ASG, Barthasson DL, Galli L, Catroxo MHB. Mass mortality associated with a frog virus 3-like Ranavirus infection in farmed tadpoles *Rana catesbeiana* from Brazil. *Dis Aquat Organ*. 2009;86(3):181-91.
20. Miller D, Gray M, Storfer A. Ecopathology of Ranaviruses infecting amphibians. *Viruses*. 2011;3(11):2351-73.
21. Miller DL, Pessier AP, Hick P, Whittington RJ. Comparative pathology of Ranaviruses and diagnostic techniques. In: Gray MJ, Chinchar VG, editors. *Ranaviruses*. Cham: Springer; 2015. p. 171-208.
22. Miller DL, Rajeev S, Brookins M, Cook J, Whittington L, Baldwin CA. Concurrent infection with Ranavirus, *Batrachochytrium dendrobatidis*, and *Aeromonas* in a captive anuran colony. *J Zoo Wildl Med*. 2008;39(3):445-9.
23. Morais D, Rodrigues M, Ávila R, Silva R. Visceral mycobacteriosis in amphibians from the Brazilian Caatinga region. *Dis Aquat Organ*. 2021;145:139-44.
24. Neves PHV. Presença de Ranavirus em Rãs-Touro, *Lithobates catesbeianus*, provenientes de ranários da região sudeste do Brasil [Dissertação]. [São Paulo]: Instituto de Pesca, Programa de Pós-Graduação em Aquicultura e Pesca; 2012. 67p.
25. O'Rourke DP, Rosenbaum MD. Biology and diseases of amphibians. In: Fox JG, Anderson LC, Otto GM, Pritchett-Corning KR, Whary MT, editors. *Laboratory Animal Medicine*. St. Louis: Elsevier; 2015. p. 931-65.
26. Ruggeri J, Ribeiro LP, Pontes MR, Toffolo C, Candido M, Carriero MM, Zanella N, Sousa RLM, Toledo LF. Discovery of wild amphibians infected with Ranavirus in Brazil. *J Wildl Dis*. 2019;55(4):897.
27. Scheele BC, Pasmans F, Skerratt LF, Berger L, Martel A, Beukema W, Acevedo AA, Burrowes PA, Carvalho T, Catenazzi A, De La Riva I, Fisher MC, Flechas SV, Foster CN, Frias-Alvarez P, Garner TWJ, Gratwicke B, Guayasamin JM, Hirschfeld M, Kolby JE, Korsh TA, La Marca E, Lindenmayer DB, Lips KR, Longo AV, Maneyro R, McDonald CA, Mendelson III J, Palacios-Rodriguez P, Parra-Olea G, Richards-Zawacki CL, Rodel MO, Rovito SM, Soto-Azat C, Toledo LF, Voyles J, Weldon C, Whitfield SM, Wilkinson M, Zamudio KR, Canessa S. Amphibian fungal panzootic causes catastrophic and ongoing loss of biodiversity. *Science*. 2019;363(6434):1459-63.
28. Toledo LF, Britto FB, Araújo O, Giasson L, Haddad C. The occurrence of *Batrachochytrium dendrobatidis* in Brazil and the inclusion of 17 new cases of infection. *South Am J Herpetol*. 2006;1(3):185-91.
29. Whitaker BR, McDermott CT. Amphibians. In: Carpenter JW, Marion CJ, editors. *Exotic Animal Formulary*. 5th ed. St. Louis: Elsevier; 2018. p. 53-80.
30. WOA - World Organization for Animal Health. *Manual of Diagnostic Tests for Aquatic Animals*. 8th ed. Paris: World Organization for Animal; 2021. 589p.