



Diagnostic exercise

From The Latin Comparative Pathology Group and the Davis-Thompson Foundation

Subungual squamous cell carcinoma with metastasis to the femur, multiple lymph nodes, adrenal glands, and lungs

de Cecco B^{1,2}, de Oca PVM³, Langohr IM^{1,2,5}, Boudreaux B⁴, Sasaki E^{1,2}

¹Louisiana Animal Disease Diagnostic Laboratory, Baton Rouge, LA, United States;

²Department of Pathobiological Sciences (PBS), School of Veterinary Medicine, Louisiana State University, Baton Rouge, LA, US

³Departamento de Patología, Facultad de Medicina Veterinaria y Zootecnia, Universidad Nacional Autónoma de México, Ciudad de Mexico, Mexico

⁴Department of Veterinary Clinical Sciences, School of Veterinary Medicine, Louisiana State University, Baton Rouge, LA, USA

⁵Global Discovery Pathology, Translational Models Research Platform, Sanofi, Cambridge, MA, USA

*Corresponding author: emi@lsu.edu

Clinical History:

A 9-year-old intact male Rottweiler with clinically suspected prostatic mass had difficulty climbing stairs. The dog was also favoring the left hind limb. The owners mentioned that he had started to act quieter and exhibit declining appetite with weight loss over the course of 2 weeks, in addition to having hematuria. Numerous pulmonary nodules and an abdominal mass with displaced urinary bladder and colon were evident on radiographs. In addition, lytic bone, with cortical bone disruption, was identified in the mid-diaphyseal region of the left femur. Marked lymphadenomegaly of the left popliteal and inguinal nodes was identified on physical examination. A year prior to the onset of these clinical signs, the patient had undergone amputation of digit 5 of its left hind limb due to a severely ulcerated lesion, diagnosed histologically as a subungual malignant neoplasm. An oral tumor between teeth 206 and 207 was also removed; however, this mass was not evaluated histologically.

**The Diagnostic Exercises are an initiative of the Latin Comparative Pathology Group (LCPG), the Latin American subdivision of The Davis-Thompson Foundation (DTF). These exercises are contributed by members and non-members from any country of residence. Consider submitting an exercise! A final document containing this material with answers and a brief discussion will be posted on the DTF website (<https://davisthompsonfoundation.org/diagnostic-exercise/>).*



Davis-Thompson
Foundation

*Editor-in-chief for this Diagnostic Exercise: Claudio Barros
Associate Editor for this Diagnostic Exercise: Ingeborg M. Langohr*

Gross Images:

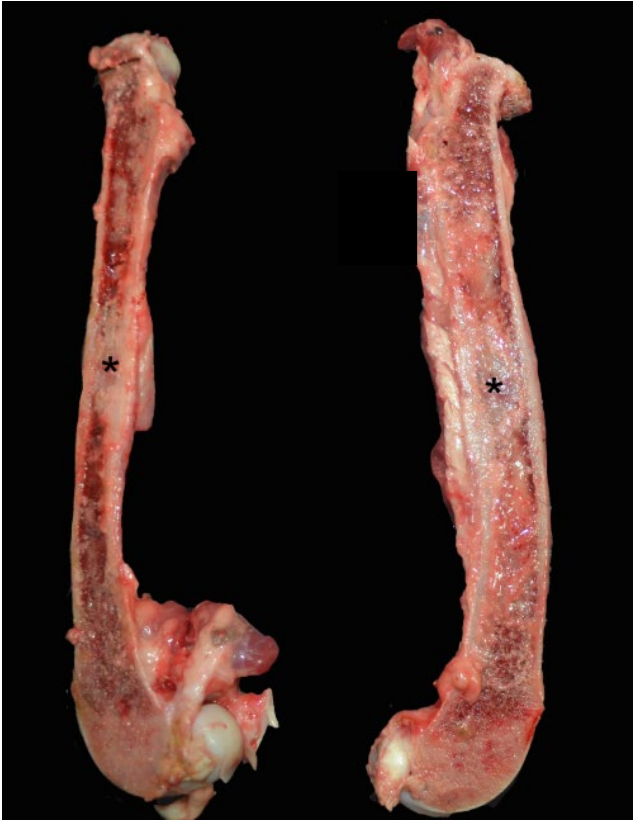

Figure 1. Left femur, cut surface: The bone marrow was replaced by white-gray areas that disrupted the cortical bone and elevated the periosteum at the mid-diaphysis (asterisks).

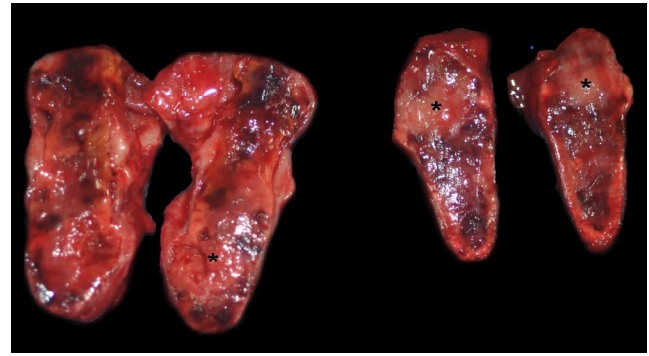


Figure 3. Adrenal glands, cut surface: Both glands were enlarged by white, firm nodules (asterisks) interspersed by multifocal to coalescing dark red areas.

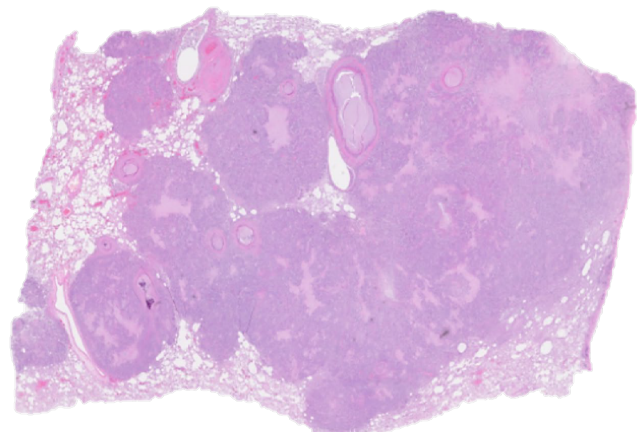


Figure 4. Lung. Hematoxylin and eosin (H&E), sub gross photomicrograph. The parenchyma was partially replaced by multifocal to coalescing neoplastic nodules.

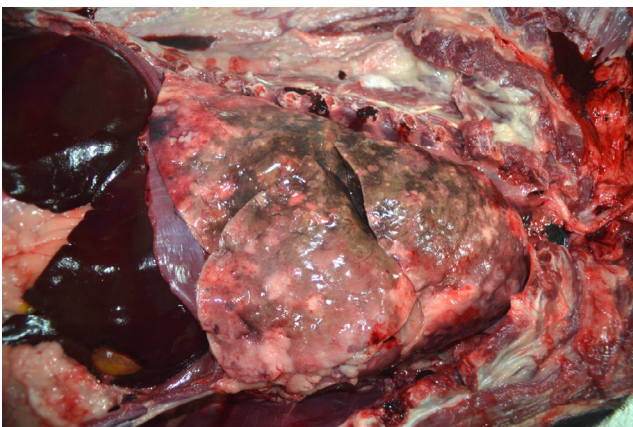


Figure 2. Thoracic and cranial abdominal cavities: The pulmonary parenchyma was disrupted by numerous multifocal to coalescent white nodules in all lobes.

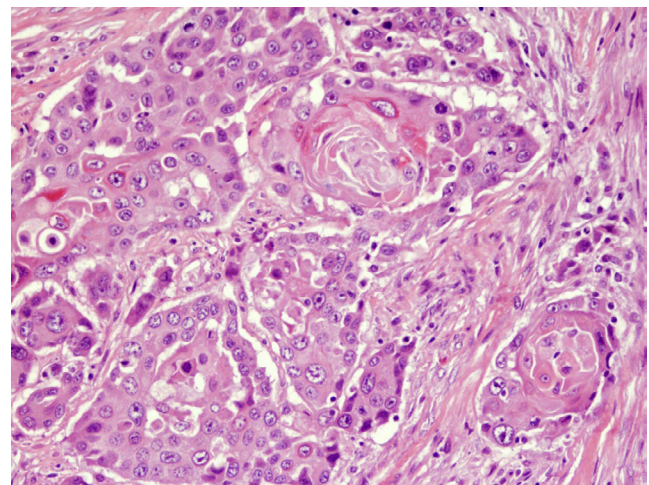


Figure 5. Lung. H&E, 20x. The neoplasm consisted of pleomorphic squamous epithelial cells arranged in nests and branching trabeculae.

Follow-up questions:

- *Gross features*
- *Morphologic diagnosis*
- *Differential diagnoses*

Answers

Gross Findings:

In the mid-diaphyseal region of the left femur, white firm tissue replaced a 5.0x2.0x2.5 cm area of the bone marrow (Fig. 1). The overlying cortical bone was focally disrupted 1 cm in length, with the white tissue extending from the marrow space into the overlying periosteum (bone lysis). The lungs were diffusely mottled dark red and brown, with numerous 0.5 cm to 3 cm diameter, firm, white nodules embedded throughout the pulmonary parenchyma in all lobes (Fig. 2). The adrenal glands were bilaterally enlarged: the left adrenal gland measured 4.5x1.5x2.0 cm and the right adrenal gland measured 4.0x1.0x1.0 cm. On cut surface, multifocal to coalescing, up to 0.5 cm diameter, white, firm nodules were interspersed by multifocal to coalescing dark red areas (Fig. 3). The prostate was markedly enlarged, measuring 7x8x5 cm. On cut surface, it was soft and diffusely tan with scattered, up to 1 cm, dark green to brown areas. Multiple lymph nodes, including the left popliteal, inguinal and those of the iliosacral center were markedly enlarged, in particular the left medial iliac lymph node, which measures 12x3x2 cm. The affected nodes were firm and white, with loss of the corticomedullary differentiation and scant white fluid oozing on the cut surface. Digit 5 of the left hind limb was absent.

Histologic Findings:

Corresponding to the firm white nodules noted grossly, the left femoral bone marrow, multiple lymph nodes (including the left popliteal, left medial iliac, tracheobronchial, and cranial mediastinal lymph nodes), adrenal parenchyma, and pulmonary parenchyma (Fig. 4) were effaced by multifocal to coalescing, well-demarcated masses composed of neoplastic squamous epithelial cells (Fig. 5). The neoplastic cells were polygonal and arranged in nests and branching trabeculae embedded in dense fibrovascular stroma infiltrated by few lymphocytes and plasma cells. The neoplastic cells had variably distinct cell borders, abundant eosinophilic to amphophilic cytoplasm, and round to oval nuclei with finely stippled chromatin and prominent nucleoli. Anisocytosis and anisokaryosis were marked. Occasional binucleated cells were present. Thirty-eight mitotic figures were counted per 2.37 mm² (equivalent to 10 FN22/400X fields or 10 high power fields). There were also multifocal necrotic and a few, small, keratinized areas. The prostate was uniformly

expanded by hyperplastic glands lined by tall columnar epithelium that frequently formed intraluminal papillary projections (not shown).

Morphologic Diagnosis:

Left femur, multiple lymph nodes, adrenal glands, and lungs: Disseminated metastatic squamous cell carcinoma.

Clinical/Gross Differential Diagnoses:

Metastatic prostatic adenocarcinoma and melanoma

Comments:

Squamous cell carcinomas (SCC) arising from the nailbed epithelium are the most common digital neoplasms of dogs, representing up to 49.6% of all digital neoplasms (1). These tumors occur primarily in medium to large breed dogs with a completely or predominantly black hair coat, including Rottweilers (as in this case), Giant Schnauzers, and black Standard Poodles, with a mean age of 10 years at the time of the diagnosis (1,2, 4). The reason for the relationship between the hair coat color and the predisposition to subungual SCC remains unclear. Regardless, masses in multiple digits in a black-coated breed should raise suspicion of SCC (8). The metastatic rate of subungual squamous cell carcinoma is estimated to be up to 24%, with metastases first observed between 3 months and 5 years after the initial diagnosis (2). In our case, the metastases were noted one year after the primary diagnosis of SCC in digit 5 of the left hind limb.

Clinically, a metastatic prostatic neoplasm was the top differential diagnosis; however, the prostatic enlargement was histologically determined to be due to prostatic hyperplasia instead. Prostatic neoplasms are uncommon in dogs (6). Interestingly, intact males (as was this dog) appear to have a reduced incidence of prostatic neoplasms when compared to neutered males (7). This suggests a potential protective role of androgens via anti-proliferative effects on prostatic ductal or transitional epithelial cells (7). Neoplasms of the canine prostate are frequently malignant epithelial neoplasms composed of glandular or acinar structures and are therefore usually classified as adenocarcinomas (5). Other prostatic neoplasms include transitional cell carcinoma and undifferentiated carcinoma (5). The prostatic carcinomas in dogs are aggressive neoplasms, frequently inducing lumbar vertebral and/or pelvic bone metastasis. The lack of a screening test for the identification of dogs with early-stage prostatic cancer further limits successful treatment (5).

Metastatic melanoma is another differential diagnosis to consider in a dog with a metastatic subungual neoplasm. Melanomas are the second most common digital neoplasm

in dogs. Black-coated dogs seem to be again overrepresented (3). Subungual (nailbed) melanomas usually involve multiple digits and have aggressive behavior, with frequent metastases in regional lymph nodes and lungs. Prognosis is, therefore, worse than for subungual SCCs, with a 1-year survival rate of dogs following amputation of the digit of only approximately 50% (8).

Poorly differentiated tumors may require immunohistochemistry. In particular, amelanotic and spindle cell variants of melanomas can be difficult to diagnose and may require immunohistochemical staining with markers such as Melan-A, PNL2, TRP-1, and TRP-2 (6). Nonetheless, histologic features are sufficient to reach the diagnosis in well-differentiated tumors, as in this case.

References:

1. Belluco S, Brisebard E, Watrelot D, Pillet E, Marchal T, Ponce F. Digital squamous cell carcinoma in dogs: Epidemiological, histological, and immunohistochemical study. *Vet Pathol.* 2013; 50(6):1078-82.
2. Chiu O, Wilcock BP, Wilcock AE, Edwards AM. Breed predilections and prognosis for subungual squamous cell carcinoma in dogs. *Can Vet J.* 2022; 63(11):1129-34.
3. Gillard M, Cadieu E, De Brito C, Abadie J, Vergier B, Devauchelle P, Degorce F, Dréano S, Primot A, Dorso L, Lagadic M, Galibert F, Hédan B, Galibert M-D, André C. Naturally occurring melanomas in dogs as models for non-UV pathways of human melanomas. *Pigment Cell Melanoma Res.* 2014; 27(1):90-102.
4. Grassinger JM, Floren A, Müller T, Cerezo-Echevarria A, Beitzinger C, Conrad D, Törner K, Staudacher M, Aupperle-Lellbach H. Digital lesions in dogs: A statistical breed analysis of 2912 cases. *Vet Sci.* 2021; 8(7):136.
5. Leroy BE, Northrup N. Prostate cancer in dogs: Comparative and clinical aspects. *Vet J.* 2009; 180(2):149-62.
6. Meuten JD. *Tumors in Domestic Animals.* 5th Ed. Oxford: Willey-Blackwell; 2016. p. 97-9, 132-3.
7. Teske E, Naan EC, van Dijk EM, Van Garderen E, Schalken JA. Canine prostate carcinoma: Epidemiological evidence of an increased risk in castrated dogs. *Mol Cell Endocrinol.* 2002; 29:197(1-2):251-5.
8. Wobeser BK, Kidney BA, Powers BE, Withrow SJ, Mayer MN, Spinato MT, Allen AL. Diagnoses and clinical outcomes associated with surgically amputated canine digits submitted to multiple veterinary diagnostic laboratories. *Vet Pathol.* 2007; 44(3):355-61.