



Original full paper

Astrocyte intermediate filaments are important markers in olfactory bulb of bovine *Herpesvirus* type 5 natural infections

Deriane E. Gomes¹, Heitor F. Ferrari², Flávio T.L.B. Roncatti¹, Fernanda Paes¹, Livia S. Cardoso¹, Silvia H. V Perri^{1,2}, Adriana H. C. Nogueira³, Maria Cecília R. Luvizotto², Tereza C. Cardoso¹

¹Laboratório de Virologia Animal, Unesp - Universidade Estadual Paulista, Araçatuba, SP-Brazil

²Laboratório de Patologia Animal, UNESP, Araçatuba, SP-Brazil

³Instituto Biológico, São Paulo, Brazil

*Corresponding author: Tereza C. Cardoso - Departamento de Apoio, Produção e Saúde Animal - Unesp, Curso de Medicina Veterinária - Rua Clóvis Pestana, 793.- CEP 16050-680 Araçatuba, SP, Brazil.

E-mail: tcardoso@fmva.unesp.br

Submitted October 30th 2009, Accepted January 5th 2010

Abstract

Astroglial cells are the most abundant cells in the mammalian central nervous system, yet our knowledge about their function in bovine *Herpesvirus* type 5 (BoHV-5) has been limited. The aim of this study was to detect by immunohistochemistry assay the reactive astrocytes for glial fibrillary acidic protein (GFAP) and vimentin (VIM), considered intermediate filaments of the cytoskeleton, localized in olfactory bulb from natural acute cases of BoHV-5 infection. All samples were submitted to virus isolation, real-time polymerase chain reaction (RT-PCR) and *in situ* hybridization (ISH) technique to confirm the virus transcription and respective genome. Samples were classified into four groups according to the severity of histological lesions. Groups III and IV, which histological lesions were classified as alacia, gliosis, satellitosis, neuronophagia and neuronal necrosis, 35% (\pm 1.8-2.1) of the inflammatory mononuclear cells, corresponded to CD3 positive lymphocytes. In the same group, 35% (\pm 1.8) of astrocytes were described as reactive to GFAP and VIM proteins. An agreement of $r = 1.0$ ($P < 0.0001$) was found between histological lesions, intermediate filaments expression, viral DNA and transcription and CD3 lymphocytes. However, samples with mild histological lesions, 10.8 to 14.2% of astrocytes were classified as reactive to GFAP and VIM filaments. Our findings suggest that GFAP and VIM reactive astrocytes, in primary site of virus replication, seems to play an important role in neurovirulence, in spite of many questions concerning the virus immunopathology remains unclear.

Key Words: Bovine Hesperivirus, BoHV-5, Neuropathology, GFAP, VIM.

Introduction

Bovine *Herpesvirus* type 5 (BoHV-5) is member of the family *Herpesviridae*, sub-family *Alphaherpesvirinae*, and is primary etiological agent of non-suppurative meningoencephalitis, described as a cause of significant economic losses to beef cattle in Latin America (2, 10). Outbreaks of BoHV-5-associated encephalitis have been reported worldwide, however most of field cases are localized in South of America (6, 24, 26).

Several pathways have been proposed for virus invasion into the nervous system however none of them has been conclusive in this topic. The most important biological properties is a lifelong latent infection in sensory nerve ganglia after acute infection, whereas the infection is manifested by occasional reactivation of

virus providing an adequate means of transmission and spread, generally only detected by outbreaks (14, 26). Moreover, it has been suggested that olfactory pathway was the main route of BoHV-5 infection (7, 8, 9, 14, 16, 17, 19, 31), as demonstrated also for others *Alphaherpesvirus* (18, 25).

Rabbit models of BoHV-1 and BoHV-5 infections have been extensively applied, essentially to determine the molecular basis of neuropathogenicity (7, 8, 9, 17). In spite of neuropathological patterns has been established, these patterns remains controversial due to the difficulty to recover the virus from respective host (14, 19, 23). Besides, it has been also demonstrated that BoHV-5 isolation depends on different stages of the disease: acute, latency and re-activation of virus infection (14, 19).

Most of the cytoskeletal proteins and mediators are expressed by various types of brain cells. However, astrocytes can undergo dramatic changes in their morphology accompanied by subcellular redistribution of most cytoskeletal proteins but not of quantitative modifications of amount of the respective proteins (27). The classical view that all astrocytes are differentiated glial cells belonging to a lineage separate from that of neurons has been considered controversial (12, 33). Astrocytes have been described able to express three types of intermediate filaments (IF), including glial fibrillary acidic protein (GFAP), vimentin (VIM) and nestin. In addition, nestin and VIM filaments are considered the main proteins of immature astroglial cells, whereas mature and adult astrocytes express VIM (3). In addition, GFAP and VIM over expression is observed in activated astrocytes of reactive gliosis, oncogenic process and neurodegenerative disorders affecting the central nervous system. Moreover, GFAP and VIM expression are required for glial scar, constituting one of the mechanical and chemical barriers that block nerve regeneration (28). In resume, neuromodulation is a fundamental process in the brain and astrocytes play crucial role in the control and induction of homeostatic plasticity of neurons (12).

The aim of this study was to evaluate the astrocyte reactivity to GFAP and VIM intermediate filaments and also to establish a possible association between viral DNA and lymphocyte CD3 population, in olfactory bulb tissues collected from natural cases of BoHV-5 infections. For this purpose, an immunohistochemical study was conducted to evidence the reactive astrocytes and characterize the lymphocytes, and an *in situ* hybridization, targeting the Us9 gene, to establish the viral DNA distribution.

Material and Methods

Samples and general procedures

This study involves brain samples (n=40) obtained from veterinarians associated to the Laboratory of Animal Virology, University of São Paulo State (UNESP), firstly confirmed for BoHV-5 infection by methods described previously (5, 13). The whole brain was sampled, sagittally sectioned into two halves, separated the olfactory bulb region (OB), one half for histopathology and immunohistochemistry search and another for virus isolation and polymerase chain reaction (PCR) to confirm the virus infection (5, 13). The OB fragments were fixed in buffered formalin for 24 h and embedded in paraffin wax with a melting point of 55-57°C. Three- to four-micrometer sections cut and stained with hematoxylin-eosin (HE) method. Negative controls (n=50) were normal brains collected from a slaughtered house with no macroscopic signs of any apparent encephalopathy.

Histology classification

The positive samples (n=40) were divided into 4 groups (n=10 each) based on microscopic lesions: group I – mild inflammatory areas with low focal lymphocyte infiltration and no neuronal necrosis and

satellitosis; group II – mild inflammatory areas with diffuse lymphocyte infiltration associated to moderate gliosis and satellitosis; group III – moderate diffuse inflammatory areas with intense lymphocytic infiltration and mild neuronal necrosis and edema; group IV – severe inflammatory reaction with diffuse lymphocyte infiltration associated to diffuse gliosis and frequent variable-size cuffs around blood vessels (23, 24).

Preparation of biotin labeled probe

Probe was generated based on products obtained from BoHV-5 DNA (13) Us9 gene (9) produced by polymerase chain reaction (PCR). The product of 435- base pairs (bp) was generated by primary PCR primers forward gI+ (5'- GTG CTC TTC TCC ATC GCC-3') and reverse gI- (5'-GCG GAG GAG GAG TTG TCG G-3'), (Invitrogen®, Brazil). After purification from an agarose gel, the PCR product was linked into the TA-vector (pGEMTEasy, Promega, Madison, WI, USA) and ligation products were introduced into *E. coli* by heat shock. Positive colonies were confirmed by DNA sequencing. A confirmed positive colony was cultured and plasmid DNA was prepared using a commercially available kit (Promega Mini- Prep, Promega, Madison, WI, USA). The probe was generated by PCR reaction targeting the Us9 gene localized in the plasmid as described before, using the biotin labeled reverse primer (Invitrogen®, Brazil).

In situ hybridization

Briefly, tissue sections were cut (4-mm thick) from the same paraffin-embedded tissue samples as used for histopathology and IHC and mounted on charged glass slides (Superfrost/Plus, Fisher Scientific). Slides were deparaffinized and rehydrated as previously described, and then treated with proteinase K (10µg/ml) for 10 min. Postfixation was carried out in 4% paraformaldehyde for 10 min after washing in PBS. A 435-bp biotin denatured probe was applied in 2µL (≅ 2 ng/ml) plus 98µl of pre-hybridization buffer (50% formamide, 5% bovine soroalbumin [Sigma-Aldrich], 1% N-lauroylsarcosine and 0.02% sodium dodecyl sulphate) was incubated at 42°C for overnight under a plastic cover slip in a humidified chamber. Excess probe was removed by washing three times in PBS for 10 min at room temperature and was followed by 2 washes in PBS for 3 min each. After incubation with 10% of defatted milk and with Biotin Blocking System (DakoCytomation) for 1 h, the sections were incubated with 100µl (1:200) mouse anti-biotin antibody for 2 h. After 2 separate washes with PBS, the sections were treated with streptavidin peroxidase conjugate for 20 min at room temperature. After, equal volumes of 0.02% hydrogen peroxide and 0.6mg DAB (3,3'-diaminobenzidine tetrahydrochloride, Gibco BRL □ cat # 15972-011), were added to the slides for 30 min at room temperature. Sections were counterstained with Hematoxylin. Positive and negative controls were from the same sources as those used for the IHC procedure. Staining was observed by examination under a light

microscope and brownish deposits were considered positive.

Immunohistochemistry Assay (IHC)

In order to detect, astrocytes immunoreactive to GFAP and VIM filaments, a standard method of avidin-biotin-peroxidase complex was performed (ABC, DakoCytomation, CA, USA). The presence of lymphocyte T among inflammatory infiltration slides were performed using a monoclonal antibody anti-human T cell CD3 peptide raised in rabbits (cat # C7930, Sigma-Aldrich, St Louis, USA). For immunohistochemical studies, the sections were mounted on glass slides coated with pure 0.1% poly (L-lysine) solution. After, the sections were submitted to heat in citrate buffer (pH 6.1) for 15 min to antigen retrieval. After deparaffination and rehydration, blockage of the endogenous peroxidase activity was performed by incubation in 50% methanolic hydrogen peroxide (1h) and the endogenous biotin blockage performed by Biotin Blocking system (DakoCytomation) according to manufacture's instructions. The sections were then washed 3 times in phosphate-buffered saline (PBS) added by 0.1% Tween 80. The optimum primary antibody dilution used was, 1:100 for GFAP (rat anti-GFAP, cat # 13-0300, Zymed[®] Laboratories, CA, USA,) and 1:20 for VIM (mouse anti-Vimentin V9, cat # V 6630, Sigma-Aldrich). Slides were covered by 200µl of diluted antibody overnight at 4°C in a humidified chamber. After 5 washes, 100µl/slide of streptavidin-peroxidase complex (DakoCytomation) was added and the slides incubated for 1h at 37°C. In addition, substrate made fresh in the dark, by mixing equal volumes of 0.02% hydrogen peroxide and 0.6mg DAB (3,3'-diaminobenzidine tetrahydrochloride, Gibco BRL[®] cat # 15972-011), was added to the slides for 30 min at room temperature. The reaction was stopped by washing with tap water and counterstained with Hematoxylin. An intense brownish deposit was considered positive. Negative controls consisted of sections of non-infected brain were submitted to the same procedure.

Micrographs Analysis

Estimation of the number of GFAP and VIM-reactive astrocytes, CD3 positive lymphocytes and BoHV-5 positive infected cells was separately counted under light Axio Imager A.1 microscope connected to AxioCam MRc (Carl Zeiss Oberkochen, Germany). The micrographs were processed with Axiovision 4.7 software (Carl Zeiss). For each slide, at least 7-10 microscopic fields were randomly chosen and the percentage of positive signals was calculated on the number of total analyzed slides, 50 slides for each sample (29).

Statistical analysis

Results are presented as the mean \pm standard deviation. Statistical analysis was conducted with the Mann-Witney U test. To assess significant correlations, the Pearson or Spearman correlations were calculated

when the data had a normal or not normal distribution, respectively. The Kruskal Wallis test followed by multiple analysis comparisons were applied to estimate the inter groups variations. *P* values < 0.01 were regarded as statistically significant.

Results

Brain histology

The diagnosis of nonsuppurative meningoencephalitis was confirmed for BoHV-5 infection in all cases used in this study. Histological, lesions were characterized mostly as inflammatory mononuclear cells (mostly plasmatic cells and lymphocytes), malacia and degrees of gliosis, satellitosis, neuronophagia and neuronal necrosis (results not shown). The distribution of four different groups was performed at mean distance from each lesion. Neither BoHV-5 nor respective subtypes were detected in this study.

In situ hybridization achieves

The viral DNA was detected by the ability of the probe to hybridize the US9 gene of BoHV-5 as illustrated in Fig. 1d. The positive signals were characterized by inclusions and brownish deposits in the cytoplasm (Fig. 1d), respectively. Interesting, viral DNA was considered significantly frequent in groups III and IV (35.2-35%; \pm 1.8), same results observed for GFAP, VIM and lymphocytes CD3 search (Fig. 3a, b, c and d). The probe was unable to hybridize the negative controls (Fig. 2b).

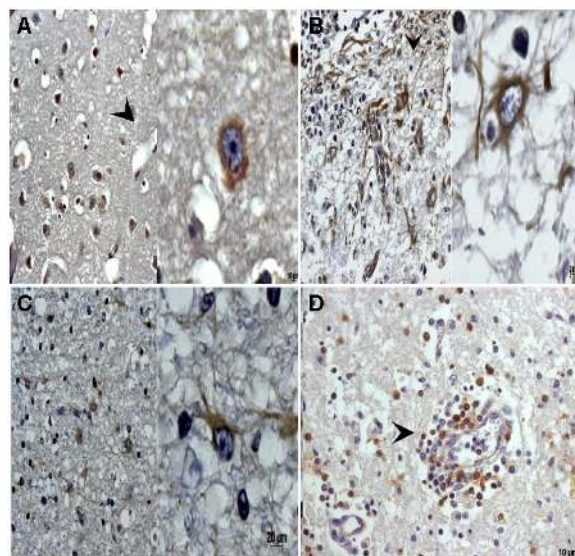


Figure 1 - Histological sections from olfactory bulb of natural cases of BoHV-5 infection subjected to immunohistochemistry and *in situ* hybridization assay. (A) In situ hybridization for US9 gene of BoHV-5 virus. Arrow indicates positive brownish deposits; (B) Reactive astrocyte to vimentin filament (VIM); (C) Reactive astrocyte to glial fibrillary acidic protein (GFAP); (D) CD3- positive lymphocytes near to perivascular cuffing.

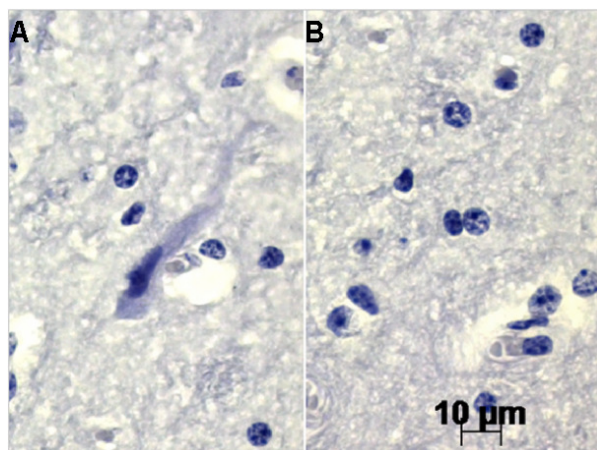


Figure 2 - Histological sections from olfactory bulb of negative animals submitted to the same search as positive samples. (A) No signal observed for GFAP and VIM intermediate filaments; (B) In situ hybridization negative result for Us9 gene of BoHV-5 virus.

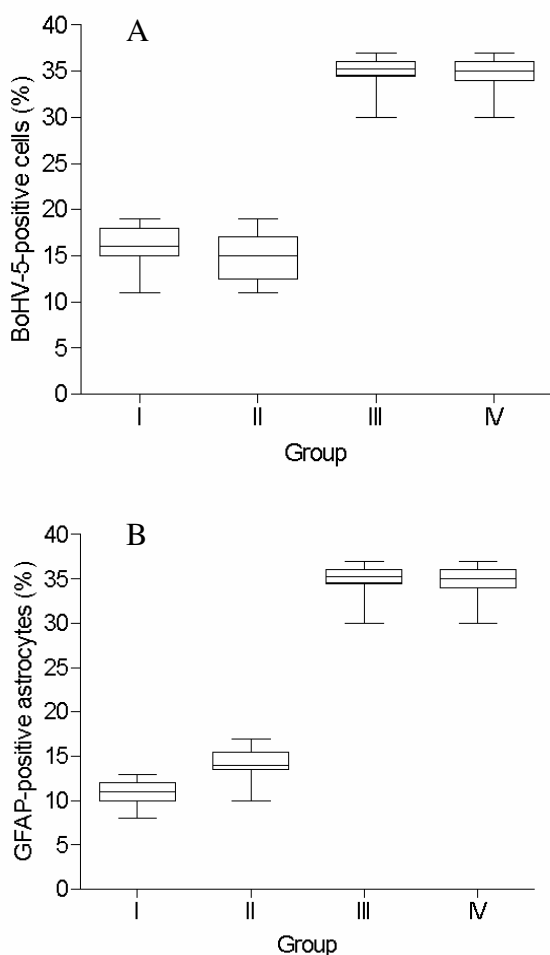


Figure 3 - Box plots of intensity of histological lesions in OB (group I, II, III and IV) versus BoHV-5 positive signals (A); versus VIM-positive astrocytes (B); versus GFAP-positive astrocytes; versus lymphocytes CD3-positive cells.

Immunohistochemistry achieves

With respect to the distribution of GFAP and VIM-reactive astrocytes, 10.8 to 14.2% (± 1.3 -2.0) were considered positive (Fig. 1b and c), in both groups I and II. However, in the III and IV groups, this number increased significantly, 35.2% to 35% (± 1.8) (Fig. 3b and c). A total of 35.2 to 35% (Fig. 3d) of mononuclear cells was considered CD3 positive lymphocytes (Fig. 1d), localized nearby to perivascular cuffing. This percentage increased significantly according to the number of GFAP and VIM-reactive astrocytes (Fig. 3d). By box plots analysis, percentages of GFAP, VIM and CD3 positive cells were superior in group III and IV (Fig. 3a, b and c), directed associated to viral DNA detection by in situ hybridization (Fig. 1a). No signal could be detect in slides prepared from negative samples (Fig. 2a).

Relationships of IHC, in situ hybridization and histology parameters

An inverse correlation was found between the percentage of GFAP and VIM-reactive astrocytes observed in groups I and II ($r = -0.059$; $r = -0.111$), and between viral DNA and both filaments ($r = -0.175$; $r = 0.083$; $r = -0.187$; $r = -0.007$, respectively). No correlation could be found for GFAP and VIM expression and CD3 positive cells in the same analysed groups. However, a direct correlation ($r = 1.0$) was found for viral DNA, GFAP and VIM expression and CD3 positive cells ($P < 0.0001$) in groups III and IV. No correlation was found between groups I and II in respect to groups III and IV. In contrast, strong correlation could be found between groups III and IV ($r = 0.999$; $P < 0.0001$).

Discussion

All samples included in the present study were field BoHV-5 cases detected by an experimental survey performed in São Paulo State, Brazil (13). Additionally, the lesions described here would indicate that all these cases were at an early stage of the disease, demonstrated by intense inflammatory reaction associated to any degenerative areas. Moreover, to facilitate the interpretation of disease progress, in this study, the samples were classified into four groups according to previous studies (24). Although, many reports have described mild to severe perivascular cuffing, necrosis and inclusion bodies as suggestive of virus infection, these lesions remains unclear (19).

In addition, our results were focussed and discussed by analysis of olfactory bulb that seems to be a route by BoHV-5 is assumed to reach the brain (9). However, it is important to remark that BoHV-5 infections are also classified as latent and reactivated form, which can provide different patterns of histological lesions (24). In fact, knowledge of early BoHV-5 infection process could provide interesting information about the neuropathogenesis of alphaherpesvirus infections, with special relevance to HSV-1 encephalitis (9, 24, 31).

It was possible to infer that acute phase of BoHV-5 infection has a pattern for tissue damage, even being described as a high level of variability by others studies (31). Reactive astrocytes to GFAP and VIM were quantified and 35% of them were considered positive with high percentage of positively marked cells for BoHV-5 DNA (14). Moreover, the perivascular cuffing classified in group III and IV as intense, showed predominantly CD3 positive lymphocytes.

Several reports have demonstrated the difficulty to found BoHV-5 DNA and/or infective virus at the site of infection (14). In this study, high correlation was found between viral DNA, DNA copies and astrocytes expressing GFAP and VIM, which can indicate an interesting association to the viral pathogenesis. Moreover, the pattern described by others studies, demonstrated that GFAP-reactive astrocytes are more vulnerable to virus infection in the case of *Paramyxovirus* (15). It has been described acute encephalopathy cases with an increase in number of astrocytes close related to the infection site. Moreover, It is known, in response to essentially any CNS pathology, astrocytes undergo a characteristic change in appearance, normally referred to as reactive gliosis (22). This phenomenon was also observed in our study, confirmed by several focus of gliosis in group III and IV, whereas astrocytes were expressing GFAP and VIM filaments.

The exact functions of the reactive astrocytes are not completely understood but the available data seem to indicate that reactive cells may contribute to the CD3 lymphocytes recruitment, induced by BoHV-5 infection. This statement could be explained by higher viral DNA copies in groups III and IV, whereas intense inflammatory event was observed. Finally, BoHV-5 replication seems to display a cellular interaction that induces a neuronal necrosis, frequently detected in both group III and IV, confirmed by high viral transcription.

In addition, astrocytes, a major population of glial cells in the brain, play previously unrecognized functions in neuronal modulation. For example, recent findings show that astrocytes have the potential to control neuronal excitability and synaptic plasticity (12, 21). The emerging picture is highly interesting and it suggests that GFAP and VIM expressed by astrocytes in acute natural cases of BoHV-5 infections are of fundamental importance in BoHV-5 pathogenesis. Furthermore, understanding how all the different effects, generated by reactive astrocytes which are different pathway of infection and mechanism of host defense represents the current challenge in filed cases of BoHV-5.

The comparative analysis of BoHV-5 infections with regard to neurovirulence could provide interesting information about neuropathogenesis of alphaherpesvirus infections, with a special relevance to herpes simplex virus (HSV) which leads in 75% of the cases to necrotizing encephalitis (32). The results obtained here indicate that an increase of microscopic lesions is directly related to virus replication activating astrocytes intermediate filaments with intense lymphocytes recruitment.

Acknowledgements

Financial support from CNPq - Conselho Nacional de Desenvolvimento Científico e Tecnológico (CNPq n° 472226/2007-0) and FAPESP (2008/03802-2).

References

1. BAKER, CA., MANUELIDIS, L.. Unique inflammation RNA profiles of microglia in Creutzfeldt-Jakob disease. *Proc. Natl. Acad. Sci. U.S.A.*, 2003, 100, 675-679.
2. BELKNAP, EB., COLLINS, J.K., AYERS, VK., SCHULTHEISS, P.C. . Experimental infection of neonatal calves with neurovirulent bovine herpesvirus type 5 (BHV-5). *Vet. Pathol*, 1994, 31,358-365.
3. BIGNAMI, A., RAJU T., DAHL, D. . Localization of vimentin, the nonspecific intermediate filaments protein, in embryonal glia and in early differentiating neurons. In vivo and in vitro immunofluorescence study of the rat embryo with vimentin and neurofilaments antisera. *Dev. Biol.*, 1982, 91, 286-295.
4. CARD, JP., RINAMAN, L., LYNN, RB., LEE, BH., MEADE, RP., MISELIS, RR., ENQUIST, LW. . Pseudorabies virus infection of the rat central nervous system: ultrastructural characterization of viral replication, transport and pathogenesis. *J. Neurosci.*, 1993, 13, 2515-2539.
5. CARDOSO, TC., FERRARI, HF., LUVIZOTTO, MCR., ARNS, CW. . Bio-safety technology in production of Bovine Herpesvirus type 5 (BoHV-5) using an alternative serum-free medium. *Am. J. Biochem. Biotechnol.*, 2007, 3, 125-130.
6. CARRILLO, BJ., AMBROGI, A., SCHUDEL, AA., VASQUEZ, M., DAHME, E., POSPICHIL, A. . Meningoencephalitis caused by an IBR virus in calves in Argentina. *J. Vet. Med. B.*, 1983, 30, 327-332.
7. CHOWDHURY, SI., LEE, BJ., MOISER, D., SUR, JH., OSORIO, FA., KENNEDY, G., WEISS, ML. . Neuropathology of bovine herpesvirus type 5 (BHV-5) meningo-encephalitis in a rabbit seizure model. *J. Comp. Pathol.*, 1997, 117, 295-310.
8. CHOWDHURY, SI., LEE, BJ., ONDERIC, M., WEISS, MI., MOSIER, D. . Neurovirulence of glycoprotein C(gC)-deleted bovine herpesvirus type-5 (BHV-5) and BHV-5 expressing BHV-1 gC in a rabbit seizure model. *J. Neurovirol.*, 2000, 6, 284-295.
9. CHOWDHURY, SI., ONDERICI, M., BHATTACHARJEE, PS., AI-MUBARAK, A., WEISS, ML., ZHOU, Y. . Bovine herpesvirus 5 (BHV-5) Us9 is essential for BHV-5 neuropathogenesis. *J. Virol.*, 2002,76, 3839-3851.

10. D'OFFAY, JM., MOCK, RE., FULTON, RW. . Isolation and characterization of encephalitic bovine herpesvirus type 1 isolates from cattle in North America. *Am. J. Vet. Res.*, 1993, 54, 534-539.
11. DELHON G., MORAES MP., AFONSO CL, FLORES E.F, WEIBLEN R, KUTISH GF, ROCK DL., . Genome of Bovine Herpesvirus 5. *J. Virol.*, 2003, 77,10339 -10347.
12. FELLIN, T. . Communication between neurons and astrocytes:relevance to the modulation of synaptic and network activity. *J. Neurochem.*, 2009, 108, 533-544.
13. FERRARI, HF., LUVIZOTTO, MCR., RAHAL, P., CARDOSO, TC. . Detection of bovine Herpesvirus type 5 in formalin-fixed, paraffin-embedded bovine brain by PCR: a useful adjunct to conventional tissue-based diagnostic test of bovine encephalitis. *J. Virol. Meth.*, 2007, 146, 335-340.
14. FLÔRES FS., FLÔRES V., CARON L., FLORES EF., WEIBEN R., WINKELMANN ER., MAYER SV., BASTOS RG. . Distribution of Bovine Herpesvirus type 5 DNA in the central nervous systems of latently experimentally infected calves. *J. Clin. Microbiol.*, 2003, 41, 4512-4520.
15. HOWARD, JM., ECKERT, BS., BOUGUIGNON LYM. . Comparison of cytoskeletal organization in canine distemper virus-infected and uninfected cells. *J. Gen. Virol.*, 1983, 64, 2379-2385.
16. LEE, BJ., WEISS, ML., MOISER, D., CHOWDHURY, SI. . Spread of bovine herpesvirus type 5 (BHV-5) in rabbits brain after intranasal inoculation. *J. Neurovirol.*, 1999, 5, 474-484.
17. MAYER SV., QUADROS VL., VOGEL FSF., WINKELMANN ER., ARENHART S., WEIBLEN R., FLORES, E.F. . Dexamethasone-induced reactivation of bovine herpesvirus type 5 latent infection I experimentally infected rabbits results in a boarder distribution of latent viral DNA in the brain. *Braz. J. Med. Biol. Res.*, 2006, 39,335-343.
18. METTENLEITER, TC. . Pathogenesis of neurotropic herpesviruses: role of viral glycoproteins in neuroinvasion and transneuronal spread. *Virus Res.*, 2003, 92, 197-206.
19. MEYER G., LEMAIRE M., ROS C., BELÁK K., GABRIEL A., CASSART D., COIGNOUL E., BELÁK S., THIRY E. . Comparative pathogenesis of acute and latent infections of calves with bovine herpesvirus types 1 and 5. *Arch. Virol.*, 2001, 146, 633-652.
20. MUYLKENS, B., THIRY, J., KIRTEN, P., SCHYNTS, F., THIRY, E. . Bovine herpesvirus infection and infectious bovine rhinotracheitis. *Vet. Res.*, 2007, 38, 181-209.
21. OVANESON, MV., AYHAN, Y., WOLBERT, C., MOLDOVAN, K., SAUDER, C., PLETNIKOV, M . Astrocytes play a key role in activation of microglia by persistent Borna disease virus infection. *J. Neuroinflammation* 2008, 5, 50-64.
22. PEKNY, M., PEKNA, M. . Astrocytes intermediate filaments in CNS pathologies and regeneration. *J. Pathol.*, 2004, 204, 428-437.
23. PEREZ, SE., BRETSCHEIDER, G., LEUNDA, MR., OSORIO, FA., FLORES, EF., ODEÓN, AC. . Primary infection, latency, and reactivation of Bovine Herpesvirus type 5 in bovine nervous system. *Vet. Pathol.*, 2002, 39, 437-444.
24. PEREZ, SE., BRETSCHEIDER, G., LEUNDA, MR., OSORIO, FA., FLORES, EF., ODEÓN, AC. . Primary infection, latency, and reactivation of bovine herpesvirus type 5 in the bovine nervous system. *Vet. Pathol.*, 2002, 39, 437-444.
25. POMERANZ, LE., PEYNOLDS, AE., HENGARTNER, CJ. . Molecular biology of pseudorabies virus: impact on neurovirology and veterinary medicine. *Micobiol. Moll. Biol. Rev.*, 2005, 69, 462-500.
26. RISSI, DR., PIEREZAN, F., SILVA, MS., FLORES, EF., BARROS, CSL. . Neurological disease in cattle in southern Brazil associated with Bovine herpesvirus infection. *J. Vet. Diagn. Invest.*, 2008, 20, 346-349.
27. SAFAVI-ABBASI, S., WOLFF, JR., MISSLER, M. Rapid morphological changes in astrocytes are accompanied by redistribution but not by quantitative changes of cytoeskeletal proteins. *Glia*, 2001, 36, 102-115.
28. SEEHUSEN, F., ORLANDO, EA. . Vimentin-positive astrocytes in canine distemper: a target for canine distemper virus especially in chronic demyelinating lesions? *Acta Neuropathol.*, 2007, 114, 597-608.
29. THOMPSON, KA., BLESSING, WW., WESSELINGH, SL. . Herpes simplex replication and dissemination is not increased by corticosteroid treatment in a rat model of focal Herpes encephalitis. *J. Neurovirol.*, 2000, 6, 25-32.
30. VIDAL E., MÁRQUEZ, M., TORTOSA, R., COSTA, C., SERAFÍN, A., FUMAROLA, M. . Immunohistochemical approach to the pathogenesis of bovine spongiforme encephalopathy i its early stages. *J. Virol. Meth.*, 2007, 134, 15-29.
31. VOGEL, FSF., CARON, L., FLORES, EF. . Distribution of bovine herpesvirus type 5 in the central nervous systems of latently, experimentally infected calves. *J. Clin. Virol.*, 2003, 77,10339-10347.
32. WADA K., MIZOGUCHI S., ITO Y., KAWADA, J-I., YAMAGUCHI, Y., MORISHIMA, T.,

MISHIYAMA, Y., KIMURA, H. . Multiplex real-time PCR for simultaneous detection of herpes simplex virus, human herpesvirus 6 and human herpesvirus 7. *Microbiol. Immunol.*, 2009, 53, 22-29.

33. ZHU, H., DAHLSTRÖM, A. . Glial fibrillary acidic protein-expressing cells in the neurogenic regions in normal and injured adult brains. *J. Neurosc. Res.*, 2007, 85, 2783-2792.