Braz J Vet Pathol, 2024, 17(1), 39-45
DOI: https://10.24070/bjvp.1983-0246.v17i1p39-45

BJVP
Brazilian Journal of Veterinary Pathology
ISSN 1983-0246

Case Report

Periarticular histiocytic sarcoma in a French Bulldog

Mayra Cunha Flecher[1,*], Nathalia Teixeira Nascimento[1], Marina Possa dos Reys[1], Leonardo Lima Gorza[2], Mayara Coutinho Carlos de Souza[3], Rodrigo dos Santos Horta[4]

[1]Department of Veterinary Medicine, Universidade Vila Velha, Vila Velha, ES, Brazil
[2]Departament of Veterinary Medicine, Universidade Federal de Minas Gerais, Belo Horizonte, MG, Brazil
[3]Veterinarian, Oncoduo Veterinary Oncology, Vila Velha, ES, Brazil
[4]Departament of Veterinary Medicine and Surgery, Universidade Federal de Minas Gerais, Belo Horizonte, MG, Brazil

***Corresponding author:** mayra.flecher@uvv.br
Submitted: September 3rd, 2023. Accepted: November 14th, 2023.

Abstract
Histiocytic sarcoma is a neoplasm originating from the dendritic cell lineage and presents an aggressive biological behavior and poor prognosis due to its increased metastatic rate. It can be localized, such as the articular and periarticular forms, or disseminated to several organs. Histopathological examination associated with immunohistochemistry can lead to a definitive diagnosis. The treatment of choice is surgical excision, chemotherapy, radiotherapy, or combination. Here, we report a case of periarticular histiocytic sarcoma involving the left knee joint in a female French Bulldog. The animal showed signs of lameness, a mass in the left pelvic limb, and radiographic findings suggestive of neoplasia. After cytological examination suggesting malignant mesenchymal neoplasia, the limb was amputated, and histiocytic sarcoma was diagnosed by histopathological examination and positive immunohistochemistry for CD18 and IBA1. After amputation, multimodal chemotherapy was instituted, and the animal survived for nine months from the start of chemotherapy treatment. However, the patient presented metastasis to the lungs, right pelvic limb, and superficial inguinal and popliteal lymph nodes.

Keywords: bone, joint, histiocyte, immunohistochemistry, CD18, IBA1.

Introduction

Histiocytic disorders are composed of cells originated from CD34+ stem cells that differentiate into monocytes and numerous lineages of dendritic cells, such as Langerhans cells (LC) and interstitial dendritic cells (DC) (19, 21). Histiocytic sarcoma (HS) is one of the most aggressive and fatal tumors originating from antigen-presenting myeloid dendritic cells (6, 8, 21). It can occur in the localized form, affecting mainly the skin and subcutaneous tissue, periarticular tissue, lungs, and spleen (32), or in the disseminated form (6, 12, 19). Despite the lack of knowledge about the etiopathogenesis of HS, the identification of genetics copy number aberrations (CNA) is frequent in Bernese Mountain Dog (BMD) and Flat-Coated Retriever (FCR), among them the loss of important chromosomal regions that can lead to the malignant transformation of histiocytes (11, 29, 32). This neoplasm affects dogs from 2 to 13 years old (2, 18) and has a higher occurrence in BMD (14) and FCR (10), but there are reports in several breeds (6, 17).

Clinical signs include anorexia, weight loss, lethargy, and others depending on the organs affected by the neoplasm (6, 19). The diagnosis can be performed by cytological and histopathological analysis; however, the confirmation of the histiocytic lineage can only be achieved by immunohistochemistry (19, 22, 23). Histologically, it is characterized by large, round to spindle pleomorphic cells, atypical multinucleated giant cells, and frequent numerous bizarre mitotic figures. Immunohistochemistry reveals that neoplastic histiocytes usually express surface molecules characteristic of

interstitial lineage, which include CD1a, MHC-II, CD11c, and CD18 (1, 25, 26).

This neoplasm is commonly reported in large dog breeds (6, 21). However, in this case, we report a case of periarticular HS in a French Bulldog that presented pulmonary metastasis after a long period of chemotherapy.

Case Description

An 11-year-old female French Bulldog, weighing 11.9 kg, was presented with lameness for about seven months and was indefinitely medicated with Amoxicillin with Potassium Clavulanate (12.5 - 25 mg/kg, orally twice a day). The patient was seen at the Veterinary Hospital of Universidade Vila Velha (UVV, Vila Velha, ES, Brazil). During the physical examination, a mass was identified in the left knee joint, showing painful sensitivity to palpation. Ipsilateral popliteal lymph node was markedly enlarged and firm. The radiographic examination of that limb showed the presence of bone proliferation in the lateral condyle of the femur and the tibial crest with soft tissue enlargement, loss of trabecular bone, and osteolysis (Fig. 1A). An incisional biopsy was performed for histopathological evaluation, and a mild neutrophilic and lymphoplasmacytic inflammatory process was identified. Fine needle aspiration was also performed for cytological evaluation of the left inguinal lymph node, which suggested a diagnosis of malignant mesenchymal neoplasia. At re-check, the patient presented enlargement of both left popliteal and superficial inguinal lymph nodes. Abdominal ultrasound revealed hypogastric and medial iliac lymphadenopathy with a heterogeneous hypoechoic aspect, compatible with metastasis. Three-view chest radiographs were performed and showed no alterations. An amputation of the left pelvic limb was performed due to the worsening of the injury.

The amputated limb presented an intradermal, firm, lobulated, yellowish-white to brownish mass, extending from the femur to the tibia and infiltrating the skeletal muscles and tibial medulla (Fig. 1B). Microscopically, it was characterized by a neoformation infiltrating the subcutaneous tissue, muscles, bone tissue and bone marrow with high cell density; fusiform, stellate and sometimes round, highly pleomorphic cells, between a scarce fibrovascular tissue. Eosinophilic and sparse cytoplasm, high nucleus: cytoplasm ratio, oval, eventually reniform, and eccentric nucleus; coarse chromatin, eventually multinucleated cells, and karyomegaly. Single to double, large, and evident nucleolus; 12 mitosis figures in 2.37mm². The diagnosis was suggestive of HS (Fig. 2). The neoplastic cells immunoexpressed IBA1 and CD18 (Fig. 3) and were negative for S100, 1A4, Desmin, HHF35, AE1, AE3, and E-Cadherin, reaching the conclusion of HS.

Chemotherapy treatment was instituted, first with lomustine (40 mg/m², orally) every 21 days for four months, and later with a modification of the University of Wisconsin-19 protocol (7,16), including vincristine (0.7 mg/m²/IV), doxorubicin (1 mg/kg/IV), lomustine (40 mg/m²/PO), and

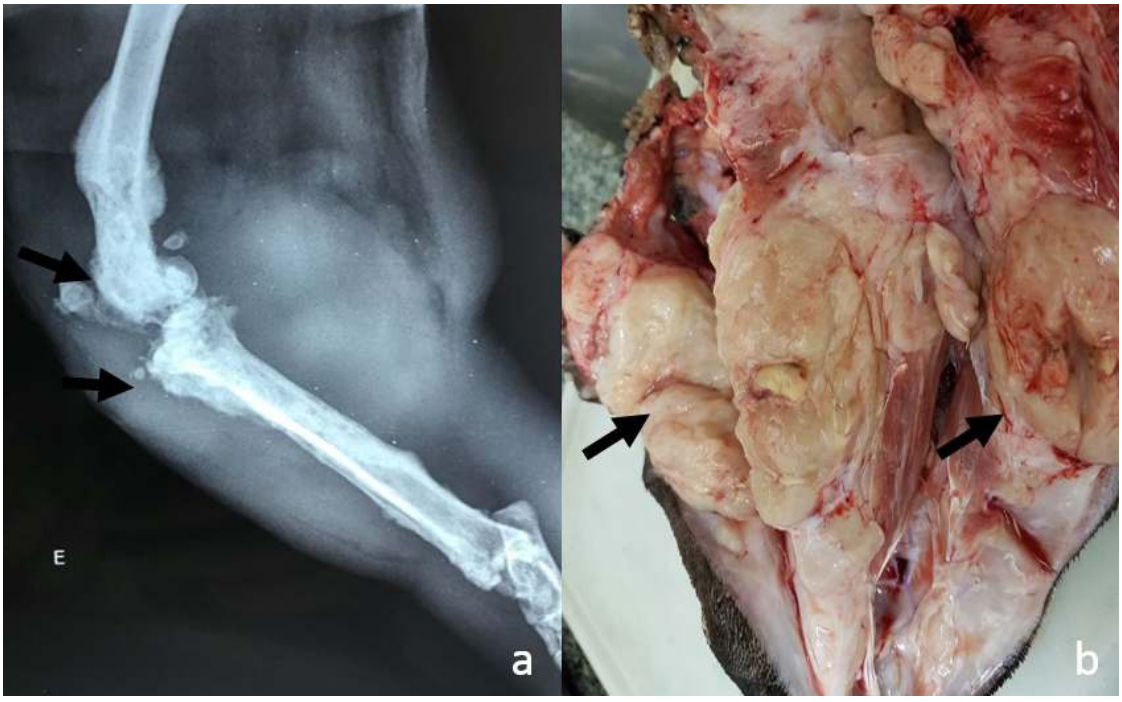

Figure 1. French Bulldog, 11-year-old, left pelvic limb, periarticular histiocytic sarcoma. A- Radiographic aspects: mediolateral radiographic projection showing new bone formation in the distal femur and proximal tibia with soft tissue enlargement (arrow). B- A firm, yellowish-with mass infiltrating the subcutaneous tissue and muscle adjacent to the femur and tibia (arrow).

prednisolone (40 mg/m²/q 24h for seven days, followed by 25 mg/m²/q m² q 24h for 30 days and 25 mg/ m² q 48h for another 60 days) (Table 1). However, after 276 days (since the surgery was performed and the chemotherapy protocol started), the disease progressed, and there was a worsening of the clinical condition, and euthanasia was performed.

In the post-mortem examination, it was observed a lobulated, firm, and white mass of approximately 10 cm extended from the inguinal region to the right knee joint (Fig. 4A). The inguinal and right popliteal lymph nodes presented nodules that caused a total loss of nodal architecture (Fig. 4B and 4C), beyond that, it was observed marked subcutaneous edema, and multifocal pulmonary nodules (Fig. 4D). Microscopically, the mass in the inguinal region up to the right knee joint, inguinal and popliteal lymph nodes, and pulmonary nodules had characteristics like those observed in the left pelvic limb, but with a greater amount of rounded and multinucleated cells.

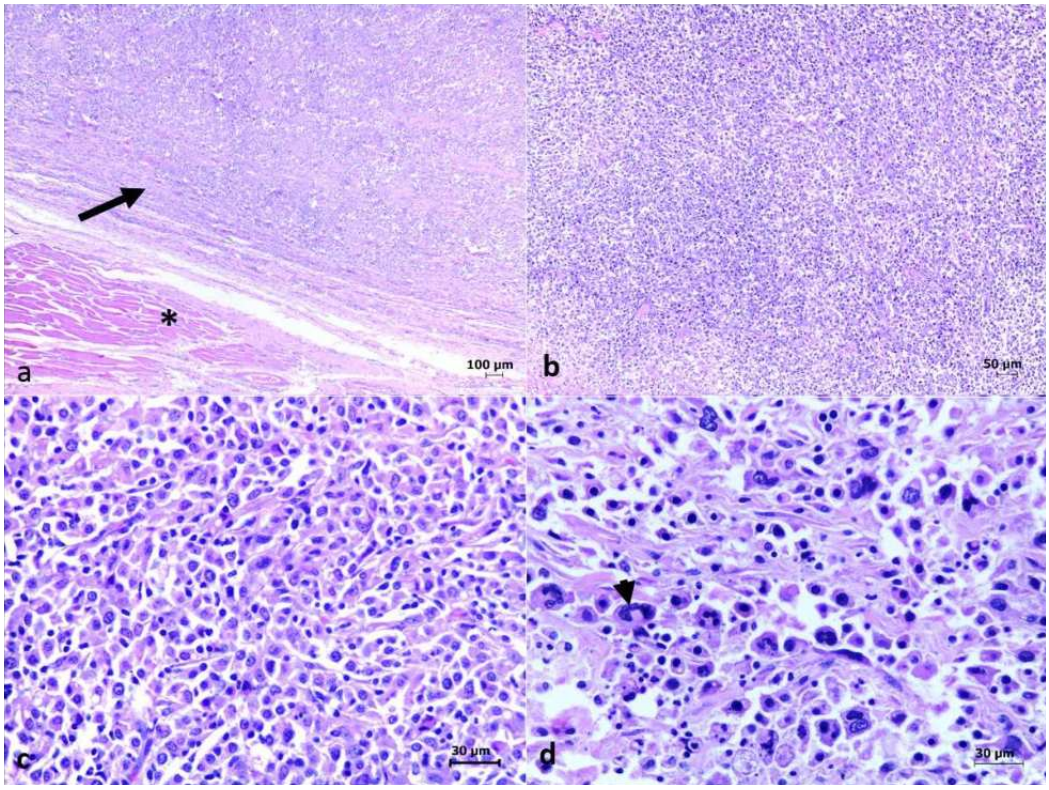

Figure 2. French Bulldog, 11-year-old, left pelvic limb, periarticular histiocytic sarcoma morphological characteristics. A- Neoplastic proliferation (arrow) adjacent to the skeletal muscle (*). B- Highly cellular neoplasm with sparse stroma. C- Pleomorphic cells ranging from fusiform to round, eosinophilic cytoplasm, oval and reniform nucleus. D- Round cells with eccentric nuclei and multinucleated cells (arrowhead).

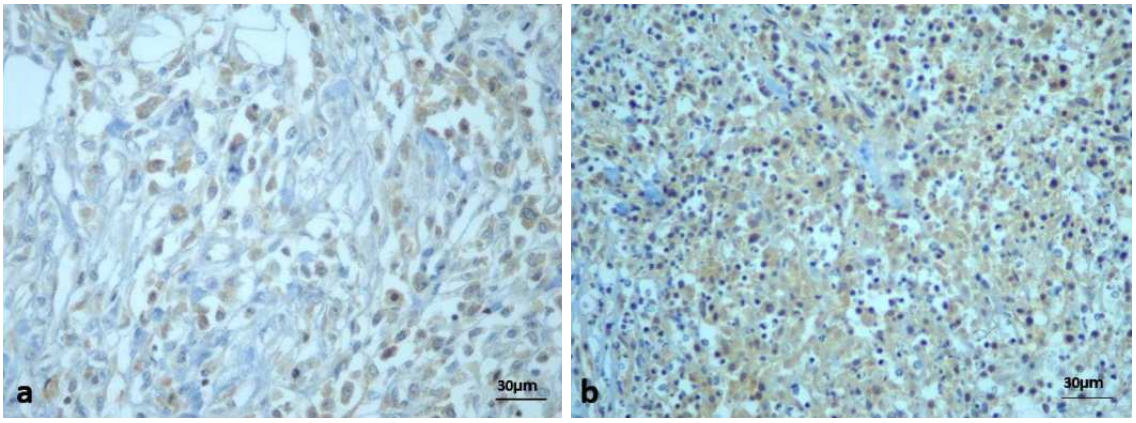

Figure 3. French Bulldog, 11-year-old, left pelvic limb, periarticular histiocytic sarcoma Immunohistochemistry of the neoplasm. A- Cytoplasmic labeling of CD18 in neoplastic histiocytes. B- IBA1 labeling in histiocytes.

Discussion

Periarticular HS comprises those that originated superficially in the joint or the metaphysis and epiphysis of long bones (18). In the reported case, at the time of diagnosis, the neoplasm was present in the knee joint, compromising the adjacent bone tissue. The elbow and knee joints are the most affected by this neoplasm, respectively (6, 18).

Table 1. Modified UW-19 (University of Wisconsin-19) chemotherapy protocol.

Weeks	Drug and dose
Week 1	Vincristine 0.7 mg/m² IV
Week 2	Doxorubicin 1 mg/kg IV
Week 3	Vincristine 0.7 mg/m² IV
Week 4	Lomustine 40 mg/m² orally
Week 5	Break
Repeat 4x totaling 19 weeks of chemotherapy Prednisolone 40 mg/ m²/ q 24h for 7 days, followed by 25 mg/ m² q 24h for 30 days and 25 mg/ m² q 48h for another 60 days	

According to the literature, neoplasms of histiocytic origin have a high incidence in a restricted group of large dog breeds, especially BMD, Flat-coated retrievers, and rottweilers (9, 10, 18, 27). This suggests a genetic influence and hereditary risk that may influence HS initiation and progression (11,17). Somatic mutations were observed in the gene for non-receptor protein tyrosine phosphatase 11 (PTPN11) in dogs with HS, with the replacement of glutamic acid by lysine. PTPN11 is responsible for encoding SHP-2, which performs signaling in several signal transduction pathways associated with cell proliferation, differentiation, and migration, acting as an oncoprotein in different types of round cell neoplasia in humans, including four reported cases of HS (30). In a survey with HS in dogs, mutations of PTPN11 were identified in 43% (41/96) of BMD and 23% (3/23) of Golden Retrievers (29).

This neoplasm unusually affects small breed dogs, being reported in Miniature Schnauzers and Pembroke Welsh

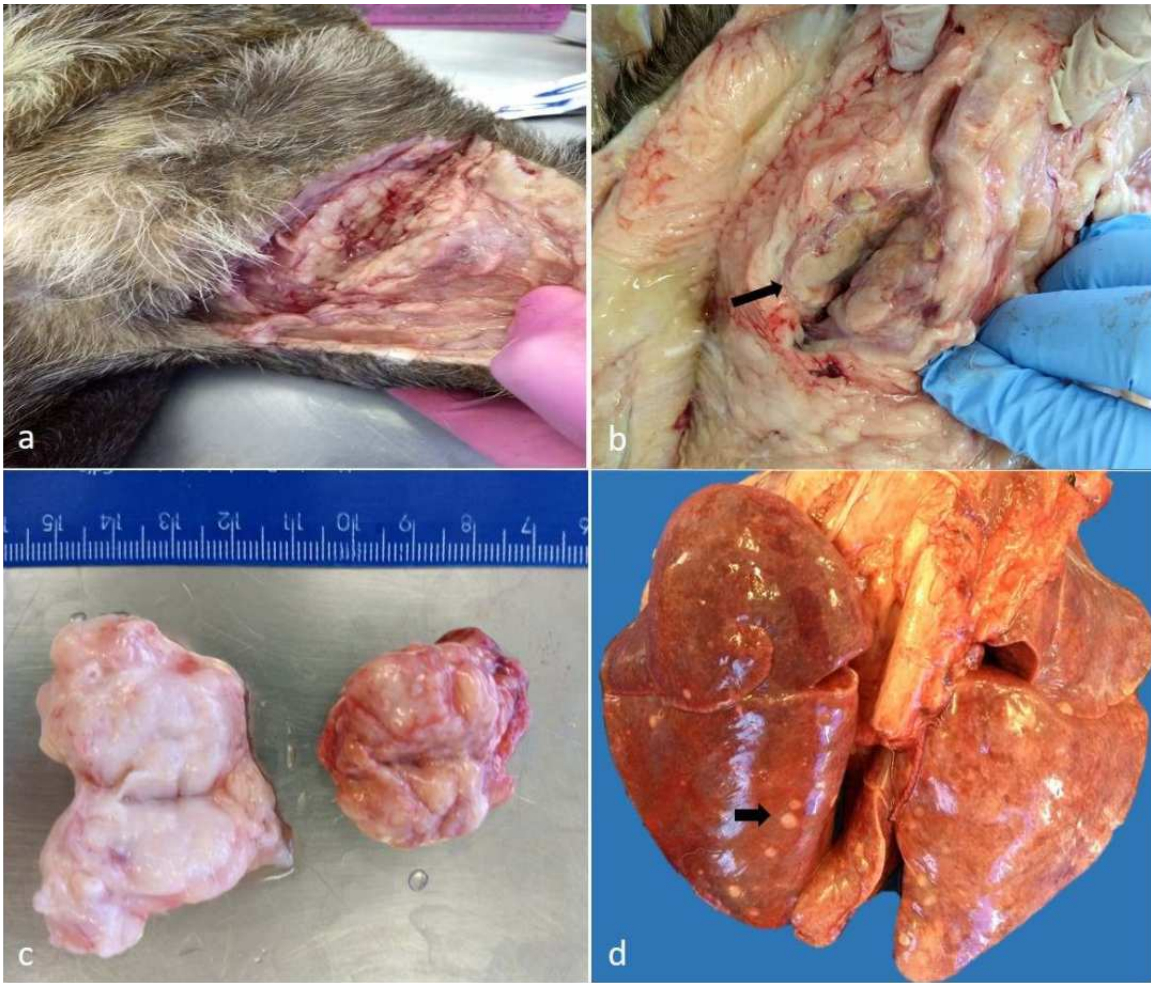

Figure 4. French Bulldog, 11-year-old, disseminated histiocytic sarcoma at necropsy, macroscopic findings. A- Whitish mass in the right pelvic limb. B and C- Yellowish-white right popliteal lymph node with loss of architecture. D- Multifocal pulmonary metastatic nodules.

Corgi (12, 13, 15). However, there is a hypothesis that the occurrence of HS in Miniature Schnauzers is limited to a lineage in the southeastern United States, where dogs exhibit a close degree of relatedness (siblings) (15). To date, there are no reports or studies of HS in French bulldogs, although this breed is commonly affected by neoplastic diseases.

In the present report, the patient was 11 years old at the time of onset of clinical signs. In reports of this neoplasm in dogs, the average age is 10 years for Pembroke Welsh Corgi and Schnauzers and 7 to 8 years for BMD (1, 9, 12, 17, 20). The clinical signs were initially non-specific, but as the clinical condition evolved, lameness was observed due to an extensive and firm mass in the left knee joint and an increased popliteal lymph node. The knee joint is one of the regions with the highest occurrence of HS, which causes lameness, pain, swelling, and lymphadenopathy that can be identified by physical examination or imaging exams (14, 19, 22, 27).

In a study of dogs with periarticular HS, lameness was present in over 90% of dogs, with a median duration of 60 days (18). In the reported case, the period between the appearance of clinical signs and the diagnosis was seven months, probably because the enlargement of the limb was only noticed on physical examination and initiation of treatment for infection without a definitive diagnosis. Localized HS usually presents an interval of an average of 42 days between the onset of clinical signs and the diagnosis (6). Osteolysis may occur in dogs with HS, making the differentiation from other bone and cartilaginous neoplasms difficult. On the other hand, osteosarcoma classically occurs in the diaphysis-metaphysis of long bones (31), unlike the findings of this report. The radiographic findings were compatible with the alterations identified in 19 dogs diagnosed with skeletal lesions related to HS (27). However, other mesenchymal malignancies in the joint, such as fibrosarcoma, myxosarcoma, and synovial sarcoma, are differential diagnoses of HS (26, 27).

Some more specific cytologic characteristics for SH, such as large mononuclear cells, moderate to abundant cytoplasm, nuclei ranging from round, oval to reniform with prominent nucleoli, and giant cells (8), help identify malignancy. However, this neoplasm may exhibit round to fusiform cells with characteristics of mesenchymal cells, limiting the diagnosis to a mesenchymal neoplasm. Sometimes, multinucleated giant cells that resemble anaplastic giant cell sarcoma are seen (3).

The incisional biopsy led to a diagnosis of inflammation, and no neoplastic cells were seen, so it is important to emphasize that the quality and quantity of the sample are essential for the diagnosis. The histopathological examination of the neoplastic mass of both pelvic limbs showed pleomorphic fusiform to round cells, sometimes multinucleated, with a reniform nucleus, corroborating the findings in the literature (22). In a study carried out in BMD, fusiform cells were more frequently seen in localized HS compared to disseminated HS (8), and in this report, the cells were highly pleomorphic, with a format varying from fusiform, stellate to round. Lesions composed solely of spindle cells may resemble spindle cell sarcomas, such as fibrosarcoma (4, 5, 21). When the cells are markedly pleomorphic or undifferentiated, immunohistochemistry (IHC) is necessary to exclude other neoplasms and confirm the histiocytic origin (22).

The identification and differentiation of histiocytic disorders is based on CD18 expression and the absence of CD3 and CD79 expression, excluding T and B cell lymphoma, respectively (1, 19, 24). In this report, the neoplastic cells expressed IBA1 and CD18. The IBA1 molecule is specific for histiocytic disorders such as canine cutaneous histiocytoma and histiocytic sarcoma, therefore excluding differential diagnoses such as melanoma, plasmacytoma, cutaneous lymphomas, and mast cell tumors (23, 24). In addition to the previously mentioned differential diagnoses, the absence of immunoexpression of S100, 1A4, Desmin, HHF35, AE1, and AE3 allowed the exclusion of other neoplasms, such as muscle neoplasms, carcinomas, and neurogenic tumors. The lack of E-cadherin expression allowed the exclusion of other histiocytic cell proliferations (Cutaneous Langerhans cell histiocytosis and cutaneous histiocytoma) (25).

The treatment involves systemic chemotherapy with a single agent or multimodal treatment (22, 27), achieving higher survival rates when used in conjunction with radical surgical resection and radiotherapy (10,14). Lomustine at a dose of 40 mg/m²/VO was the chemotherapy drug chosen after amputation and is considered an effective drug for the treatment of HS, promoting an increase of 200 days in survival time (especially when associated with radiotherapy), with the administration of minimum three doses set on an interval of 3 to 4 weeks between doses (10, 28). Dogs with unresectable or disseminated disease have a median survival time of four months when treated with chemotherapy (23), but that can range from 6 to 19 months (17).

Dogs diagnosed with localized HS had an average survival of 398 days compared to the disseminated HS and 180 days when metastasis was present (6). The dog in this report obtained a survival of approximately 276 days (about nine months) after the surgery. However, it must be considered that the disease was locally advanced, and the clinical onset started seven months before our investigation. The involvement of lymph nodes and other organs observed in the necropsy corroborates with the metastatic rate of 91% identified in dogs with articular HS after amputation (1,4,28). When localized HS spreads to lymph nodes and other locations, as occurred in this report, the HS is classified as disseminated (18,26).

Although the occurrence of HS is more usual in large dog breeds, this is a report of a periarticular HS in a French Bulldog, in which the histopathological evaluation was important for the diagnosis, later confirmed by immunohistochemical analysis. It is important to carry out the differential diagnosis for other neoplasms that affect long bones and joints, such as sarcomas, and for inflammatory diseases. Despite the poor prognosis, the association of surgery and chemotherapy contributed to the patient reaching nine months of survival after surgery.

Conflict of Interest

The authors declare no competing interests.

References

1. Abadie J, Hédan B, Cadieu E, De Brito C, Devauchelle P, Bourgain C, Parker HG, Vaysse A, Margaritte-Jeannin P, Galibert F, Ostrander EA, André C. Epidemiology, pathology, and genetics of histiocytic sarcoma in the Bernese Mountain dog breed. J Hered. 2009;100(Supp 1): S19-27. doi: 10.1093/jhered/esp039.
2. Affolter VK, Moore PF. Localized and disseminated histiocytic sarcoma of dendritic cell origin in dogs. Vet Pathol. 2002;39(1):74-83. doi: 10.1354/vp.39-1-74.
3. Barger AM. Musculoskeletal System. In: Raskin RE, Meyer DJ, Boes KM. Canine and Feline Cytopathology. A Color Atlas and Interpretation Guide. 4ed. St. Louis: Elsevier; 2023.p.2001-2092.
4. Craig LE, Julian ME, Ferracone JD. The diagnosis and prognosis of synovial tumors in dogs: 35 cases. Vet Pathol. 2002;39:66-73.
5. Craig LE, Thompson KG. Tumors of Joits. In: Meuten DJ. Tumors in Domestic Animals. 5ed. Ames, Iowa: John Wiley & Sons Inc.; 2017. p. 337-355.
6. Dervisis NG, Kiupel M, Qin Q, Cesario L. Clinical prognostic factors in canine histiocytic sarcoma. Vet Comp Oncol. 2017;15(4):1171-1180. doi: 10.1111/vco.12252.
7. Elliott J, Baines S. A Retrospective Study of Multiagent Chemotherapy including either Cyclophosphamide or Lomustine as Initial Therapy for Canine High-grade T-cell Lymphoma (2011-2017). Aust Vet J. 2019;97(9):308-315. doi: 10.1111/avj.12847.
8. Erich SA, Constantino-Casas F, Dobson JM, Teske E. Morphological Distinction of Histiocytic Sarcoma from Other Tumor Types in Bernese Mountain Dogs and Flatcoated Retrievers. In Vivo. 2018;32(1):7-17. doi: 10.21873/invivo.11198.
9. Erich SA, Rutteman GR, Teske E. Causes of death and the impact of histiocytic sarcoma on the life expectancy of the Dutch population of Bernese mountain dogs and Flat-coated retrievers. Vet J. 2013;198(3):678-83. doi: 10.1016/j.tvjl.2013.09.062.
10. Fidel J, Schiller I, Hauser B, Jausi Y, Rohrer-Bley C, Roos M, Kaser-Hotz B. Histiocytic sarcomas in flat-coated retrievers: a summary of 37 cases (November 1998-March 2005). Vet Comp Oncol. 2006;4(2):63-74. doi: 10.1111/j.1476-5810.2006.00090.x.
11. Hedan B, Thomas R, Motsinger-Reif A, Abadie J, Andre C, Cullen J, Breen M. Molecular cytogenetic characterization of canine histiocytic sarcoma: A spontaneous model for human histiocytic cancer identifies deletion of tumor suppressor genes and highlights influence of genetic background on tumor behavior. BMC Cancer. 2011; 26;11:201. doi: 10.1186/1471-2407-11-201.
12. Hirako A, Sugiyama A, Sakurai M, Ozaki K, Sakai H, Takeuchi T, Morita T, Moore PF. Cutaneous histiocytic sarcoma with E-cadherin expression in a Pembroke Welsh Corgi dog. J Vet Diagn Invest. 2015;27(5):589-95. doi: 10.1177/1040638715604185.
13. Kagawa Y, Nakano Y, Kobayashi T, Asano K, Takagi S. Localized pulmonary histiocytic sarcomas in Pembroke Welsh Corgi. J Vet Med Sci. 2016;77(12):1659-61. doi: 10.1292/jvms.15-0284.
14. Klahn SL, Kitchell BE, Dervisis NG. Evaluation and comparison of outcomes in dogs with periarticular and nonperiarticular histiocytic sarcoma. J Am Vet Med Assoc. 2011;239(1):90-6. doi: 10.2460/javma.239.1.90.
15. Lenz JA, Furrow E, Craig LE, Cannon CM. Histiocytic sarcoma in 14 miniature schnauzers - a new breed predisposition? J Small Anim Pract. 2017;58(8):461-467. doi: 10.1111/jsap.12688.
16. MacDonald VS, Thamm DH, Kurzman ID, Turek MM, Vail DM. Does L-asparaginase influence efficacy or toxicity when added to a standard CHOP protocol for dogs with lymphoma? J Vet Intern Med. 2005;19(5):732-6. doi: 10.1892/0891-6640(2005)19[732:dlieot]2.0.co;2.
17. Marconato L, Sabattini S, Buchholz J, POlton G, Finotello R, Martano M, Willman M, Massari F, Agnoli C, Gedon J, Cancedda S, Campigli M, Bley CR. Outcome comparison between radiation therapy and surgery as primary treatment for dogs with periarticular histiocytic sarcoma: An Italian Society of Veterinary Oncology study. Vet Comp Oncol. 2020;18(4):778-86. doi: 10.1111/vco.12609.
18. Moore PF. A Review of Histiocytic Diseases of Dogs and Cats. Vet Pathol. 2014;51: 167. doi: 10.1177/0300985813510413.
19. Moore PF, Rosin A. Malignant histiocytosis of Bernese Mountain dogs. Vet Pathol. 1986;23:1–10. doi: 10.1177/030098588602300101.
20. Moore, PF. Canine and Feline Histiocytic Diseases. In: Meuten DJ. Tumors in Domestic Animals. 5ed. Ames, Iowa: John Wiley & Sons Inc. 2017. p. 322-336.
21. Mullin C, Clifford CA. Histiocytic Sarcoma and Hemangiosarcoma Update. Vet Clin North Am Small Anim Pract. 2019;49(5):855-879. doi: 10.1016/j.cvsm.2019.04.009.
22. Nielsen LN, McEvoy F, Jessen LR, Kristensen AT. Investigation of a screening programme and the possible identification of biomarkers for early disseminated histiocytic sarcoma in Bernese Mountain dogs. Vet Comp Oncol. 2012;10(2):124-34. doi: 10.1111/j.1476-5829.2011.00285.x.
23. Pierezan F, Mansell J, Ambrus A, Rodrigues Hoffmann A. Immunohistochemical expression of ionized calcium binding adapter molecule 1 in cutaneous histiocytic proliferative, neoplastic and inflammatory disorders of dogs and cats. J Comp Pathol. 2014;151(4):347-51. doi: 10.1016/j.jcpa.2014.07.003.

24. Ramos-Vara José A, Borst Luke B. Immunohistochemistry: Fundamentals and Applications in Oncology. In: Meuten DJ. Tumors in Domestic Animals. 5ed. Ames, Iowa: John Wiley & Sons Inc.2016. p. 44-87.
25. Roccabianca P, Schulman FY, Avallone G, Foster RA, Scruggs JL, Dittmer K, Kiupel M. Tumors of Soft Tissue. In: Kiupel M. Surgical Pathology of Tumors of Domestic Animals. Davis Thompson Foundation. 2020. p. 262-265.
26. Schultz RM, Puchalski SM, Kent M, Moore PF. Skeletal lesions of histiocytic sarcoma in nineteen dogs. Vet Radiol Ultrasound. 2007;48(6):539-43. doi: 10.1111/j.1740-8261.2007.00292.x.
27. Skorupski KA, Clifford CA, Paoloni MC, Lara-Garcia A, Barber L, Kent MS, LeBlanc AK, Sabhlok A, Mauldin EA, Shofer FS, Couto CG, Sørenmo KU. CCNU for the treatment of dogs with histiocytic sarcoma. J Vet Intern Med. 2007;21(1):121-6. doi: 10.1892/0891-6640(2007)21[121:cfttod]2.0.co;2.
28. Takada M, Smyth LA, Thaiwong T, Richter M, Corner SM, Schall PZ, Kiupel M, Yuzbasiyan-Gurkan V. Activating Mutations in PTPN11 and KRAS in Canine Histiocytic Sarcomas. Genes (Basel). 2019;4;10(7):505. doi: 10.3390/genes10070505.
29. Thaiwong T, Sirivisoot S, Takada M, Yuzbasiyan-Gurkan V, Kiupel M. Gain-of-function mutation in PTPN11 in histiocytic sarcomas of Bernese Mountain Dogs. Vet Comp Oncol. 2018;16(2):220-228. doi: 10.1111/vco.12357.
30. Thompson KG, Dittmer KE. Tumors of Bone. In: Meuten DJ. Tumors in Domestic Animals. 5ed. Ames, Iowa: John Wiley & Sons Inc. 2017. p. 356-424.
31. Thongtharb A, Uchida K, Chambers JK, Kagawa Y, Nakayama H. Histological and immunohistochemical studies on primary intracranial canine histiocytic sarcomas. J Vet Med Sci. 2016; 3;78(4):593-9. doi: 10.1292/jvms.15-0627.
32. van Kuijk L, van Ginkel K, de Vos JP, Brearley MJ, Butinar J, Gielen I, van Garderen E, Chiers K, Verhoeven PS. Periarticular histiocytic sarcoma and previous joint disease in Bernese Mountain Dogs. J Vet Intern Med. 2013;27(2):293-9. doi: 10.1111/jvim.12059.