








## Case Report

# Late diagnosis of Bowenoid *in situ* carcinoma in two cats: the importance of identifying mild and superficial lesions

Nadiene Alves Martins<sup>1</sup> , Reiner Silveira de Moraes<sup>2</sup> , Alana Flávia Romani<sup>1</sup> ,  
Gustavo Henrique Marques Araujo<sup>1</sup> , Didier Quevedo Cagnini<sup>3,\*</sup> 

<sup>1</sup> School of Veterinary Medicine and Animal Bioscience, Federal University of Jataí (UFJ), Jataí, GO, Brazil

<sup>2</sup> São Paulo State University (Unesp), School of Veterinary Medicine and Animal Science, Botucatu, SP, Brazil

<sup>3</sup> Institute of Bioscience, Federal University of Jataí (UFJ), Jataí, GO, Brazil

\*Corresponding author: [didiercagnini@ufj.edu.br](mailto:didiercagnini@ufj.edu.br)

Submitted: November 30<sup>th</sup>, 2023. Accepted: December 22<sup>nd</sup>, 2023.

## Abstract

Cutaneous neoplasms have a significant representation in the casuistry of neoplasms in felines, emphasizing squamous cell carcinoma and basal cell carcinoma. Thus, clinical knowledge is necessary for the correct diagnostic and curative approach to the patient. This study aimed to report two cases of late diagnosis of Bowenoid carcinoma in adult cats (> one year) admitted at the Veterinary Teaching Hospital of the Federal University of Jataí in order to collaborate with the existing literature and help veterinarians in the knowledge of associated lesions. At macroscopy in the hospital admission, both cats presented lesions on the head in the bilateral supraorbital frontal region that slowly evolved into erosions and crusted ulcers with purulent exudation, in addition to lesions in the perilabial region (case 1). In microscopy, findings revealed Bowenoid carcinoma *in situ*. Supraorbital lesions revealed the abrupt formation of epidermal plaques, including follicular infundibulum continuous with the acanthotic epidermis with loss of normal stratification. Focal orthokeratosis and marked atypia of keratinocytes (macrokaryosis, macronucleosis, macrocytosis, anisokaryosis, and anisocytosis) were also observed. Early diagnosis through clinical analysis combined with histopathological evaluation is of fundamental importance to ensure therapeutic success, improving the patient's prognosis, a condition not achieved in the cases presented mainly due to late diagnosis.

**Keywords:** Bowen's disease, early diagnosis, mild lesions, phototherapy.

## Introduction

Cutaneous tumors represent from 4.4 to 9.6% of the casuistry of neoplasms in cats (6, 7), emphasizing squamous cell carcinoma (SCC) and basal cell carcinoma (BCC) as they comprise most of the non-melanocytic cutaneous neoplasms (NCNM) described in cats. SCC is characterized by the uncontrolled proliferation of neoplastic suprabasal keratinocytes, whereas BCC originates from non-keratinized cells in the epidermis basal layer (2). Neoplastic lesions accounted for 93.4% of skin lesion cases in cats, balancing between benign (47.6%) and malignant (52.7%) neoplasms (6). In cats younger than 12 months, basal cell tumor (22.6%) was the

most commonly observed, followed by fibrosarcoma (19.5%) and SCC (11.4%), with highlight to the low prevalence of multicentric SCC *in situ* and bowenoid *in situ* carcinoma (BISC) diagnosed in less than 1% (9).

BISC is a type of squamous cell carcinoma (SCC) described in humans as a slow-growing, progressive pre-malignant dermatosis that, if left untreated, can progress to squamous cell carcinoma. In animals, BISC is considered rare in dogs and infrequent in cats. The macroscopic diagnosis is based on identifying yellowish and well-demarcated lesions with erythematous and scaly characteristics. At microscopy, the non-invasion of the basement membrane is observed, with neoplastic cells confined in the epithelium of the epidermis

or in the hair follicles (5). The histopathological lesions are representative, and cytology is not very useful in these cases. Despite this, the diagnosis of BISC can be delayed because the initial dermatological lesions are mild and similar to other dermatopathies in cats, such as eczema, actinic keratosis (mainly in animals with light fur), and feline viral plaques (1).

BISC treatment may include surgical excision of the lesion, an invasive technique recommended for cases of NCNM, which may not be applicable depending on the location of the lesions. Therefore, non-invasive techniques such as electrochemotherapy (ECT) and photodynamic therapy (PDT) are recommended (5). ECT is a therapeutic modality consisted of administrating antineoplastic drugs together with applying electrical pulses in the injured regions. This facilitates the entry of the antineoplastic into the plasma membrane of the tumor cell, enhancing its cytotoxic effect (10). ECT has discreet side effects, and the location of the lesion may be a limiting factor for its use. For lesions located in the head, ECT may cause damage to the retina due to the inability of the tear to facilitate the distribution of electrical pulses (11).

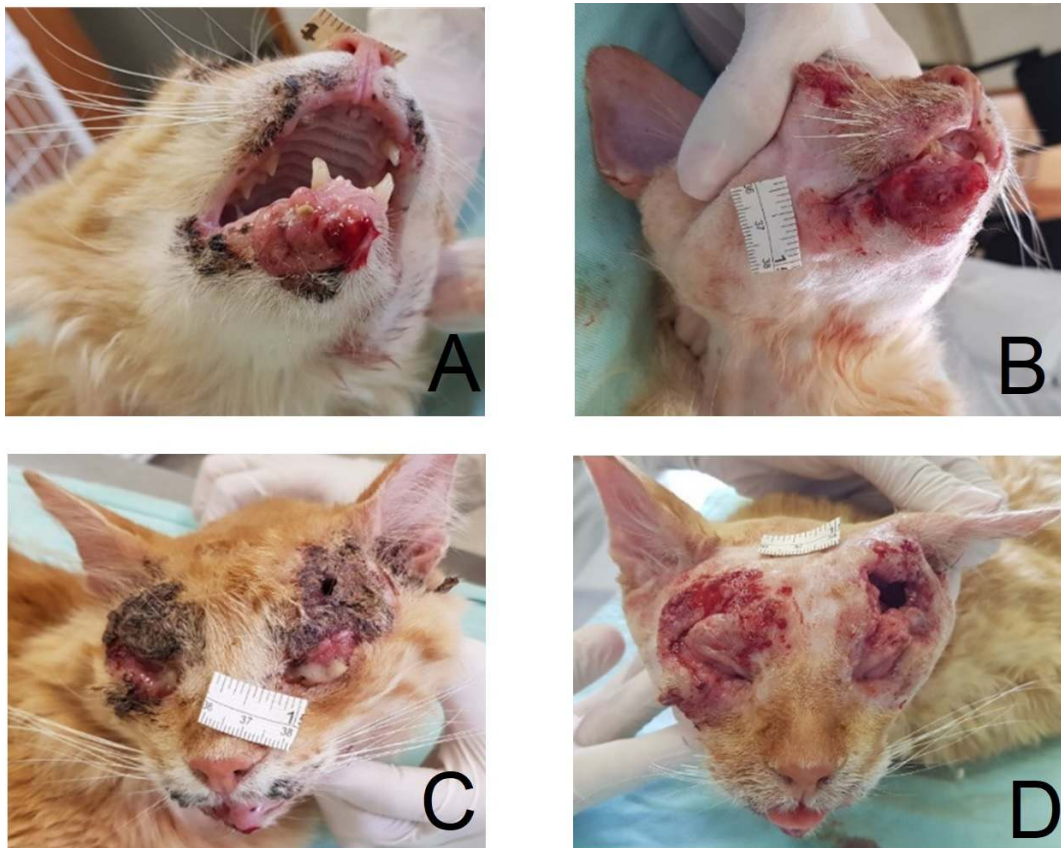Conversely, PDT has shown beneficial results for BISC through topical or systemic administration of photosensitizing drugs in the tumor tissue, such as 5-aminolevulinic acid (ALA) and its methyl ester (MAL) (5). The drug

activation at specific wavelengths causes selective destruction of atypical keratinocytes without causing damage to adjacent tissues. PDT is indicated for patients at surgical risk, immunosuppressed, with large lesions, or undergoing treatment for multiple lesions (4, 8), as seen in cats of this report. This study aimed to report two cases of late diagnosis of BISC in cats admitted and treated at the Veterinary Dermatology Service of the Federal University of Jataí between 2018 and 2019. Also, this study aimed to highlight the importance of an early diagnosis in order to make the treatment a valuable option for these patients.

## Case Description

### Case 1

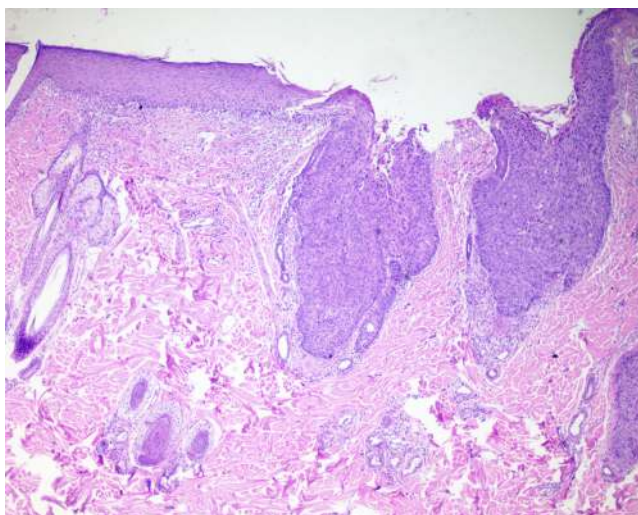
Male cat, yellow coat, adult, weighing 3.95 kg. At admission, the cat showed cutaneous spots in the bilateral supraorbital frontal region that evolved into erosions and crusted ulcers with purulent exudation, and crusted lesions in the perilabial region (Figure 1). Cardiovascular and



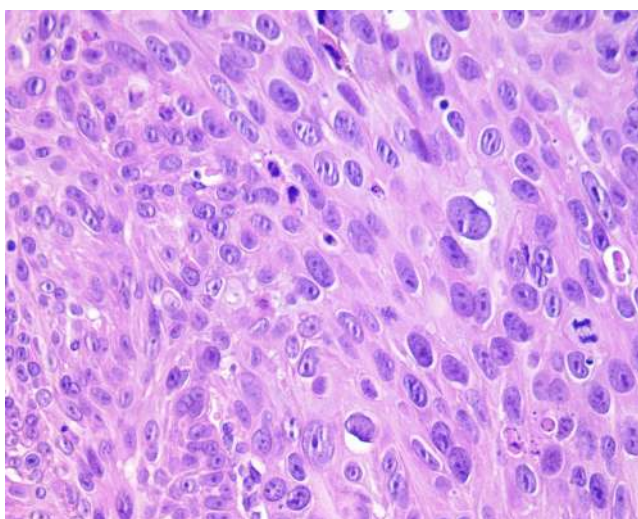
**Figure 1.** A- Erosive, ulcerative, crusted, and exudative lesion in the perilabial region. B- Lesion in the perilabial region shown in A after handling and removal of crusts. C- Large bilateral, crusted, erosive, and ulcerative periocular lesion. D- Periocular lesion shown in C after management and removal of crusts.

respiratory parameters were within the reference interval for the species. Complete blood count (CBC) and biochemistry tests showed no alterations. The skin scraping was negative, and the cat was feline immunodeficiency virus (FIV) positive and FeLV negative.

The cat underwent general anesthesia for the lesions debridement and biopsy using a 4.0 mm Punch. The biopsy specimens were fixed in 10% buffered formaldehyde and submitted for analysis. Microscopy of the supraorbital lesions revealed abrupt formation of epidermal plaques and follicular infundibulum continuous with the acanthotic epidermis (Figure 2). Follicular plaques and infundibulum showed loss of normal stratification (Figure 3) and marked atypia of



**Figure 2.** Bowenoid *in situ* carcinoma in a cat with the acanthotic epidermis forming proliferative and dysplastic lesions with mild ulceration. HE, 100x.



**Figure 3.** Bowenoid *in situ* carcinoma in a cat. The epidermis shows loss of normal stratification and marked atypia of keratinocytes. HE, 400x.

keratinocytes (macrocariniasis, macronucleosis, macrocytosis, anisokaryosis, and anisocytosis). Also, there were focal orthokeratosis and parakeratosis, erosions, and neutrophilic crusts. The dermis had a mixed inflammatory infiltrate (mast cells, neutrophils, and perivascular plasmacytes). Finally, the diagnosis was BISC. A biopsy of the perilabial area revealed SCC.

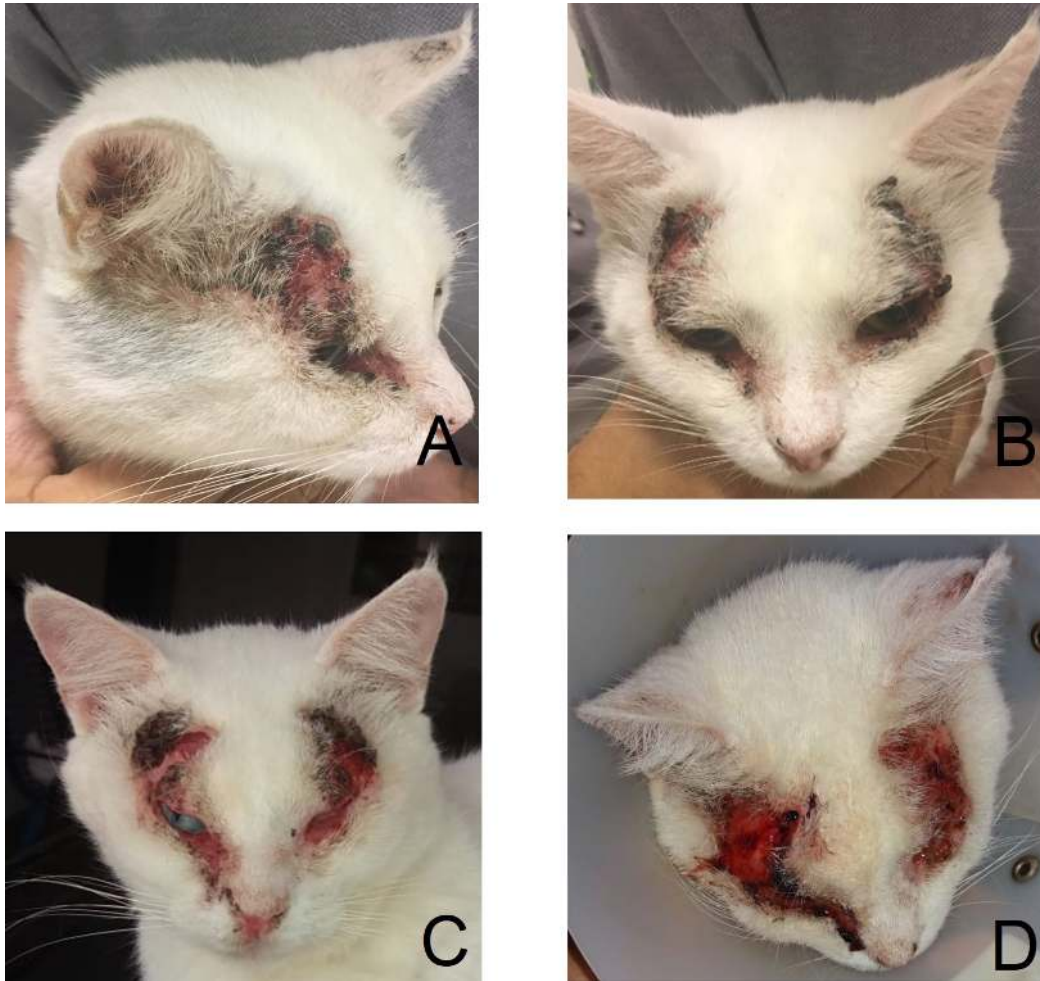
Abdominal ultrasonography (US) and chest X-ray were requested. At US evaluation, a small hyperechogenic nodule (0.5 cm) formed an acoustic shadow in the spleen caudal third. On chest X-ray, no changes were observed. Treatment included prednisolone (0.5 mg/kg, BID/10 days), amoxicillin with clavulanic acid (15 mg/kg, BID/10 days), use of Elizabethan collar, and daily cleaning of the wounds with saline solution and chlorhexidine solution. Although the late diagnosis culminated in very severe lesions, PDT was indicated. However, the socioeconomic characteristics and lack of confidence of the owner towards the animal's recovery hindered the recommended management and periodic returns of the patient. The patient died four months after the diagnosis.

#### Case 2

Male feline, white coat, six years old, weighing 4.15 kg. At admission, the cat presented facial crusted lesions (frontal region) about one year before with progression towards the eyes (Figure 4). Cardiovascular and respiratory parameters were found to be within the reference interval for the species. A bilateral periocular exudative alopecic lesion was observed in the physical examination. CBC, biochemistry, skin parasitology, and fungal culture were requested. Thrombocytopenia, leukocytosis due to neutrophilia, eosinophilia, and lymphocytosis were identified. Additionally, a slight increase in ALT was verified. Skin parasitological tests and fungal culture presented negative.

Due to the progression of the lesion in the follow-up procedure and negative results in the parasitological tests, direct skin scrapings for oncological cytology and the removal of four tissue specimens from the affected area for biopsy were requested. The oncological cytology result was suggestive of SCC, and the biopsy report indicated BISC with areas of invasion. There were areas of abrupt formation of epidermal plaques, including the follicular infundibulum continuous with the acanthotic epidermis, with loss of normal stratification and marked atypia of keratinocytes (macrocariniasis, macronucleosis, macrocytosis, anisokaryosis, and anisocytosis). Focal orthokeratosis was also noted. In some areas, an incipient invasion by rare nests of epithelial cells in the deep dermis associated with desmoplastic reaction and mixed superficial dermatitis was observed.

At the initial stages of clinical care, prednisolone (0.3 mg/kg, BID/10 days) was prescribed with a mild improvement in the erythematous aspect of the facial lesions. New CBC and biochemistry were performed, maintaining the status of thrombocytopenia and leukocytosis due to neutrophilia. Due



**Figure 4.** A- Crusted, alopecic, and partially erythematous lesion in the periocular region more pronounced in the supraorbital portion (lateral view). B- Bilateral crusted, alopecic, and partially erythematous lesion in the supraorbital portion (frontal view). C- Bilateral supraorbital, erosive, ulcerative, and crusted lesion affecting the infraorbital portion (frontal view). D- Bilateral, erythematous, and exudative supraorbital lesions approaching the base of the pinna (dorsal view).

to late diagnosis and the impossibility of excising the lesions, PDT was indicated considering the location and good results in cases of BISC. Two PDT sessions were regularly held. However, the treatment could not be carried out as recommended due to the owner's non-attendance to the scheduled sessions, so the effectiveness of this treatment modality could not be evaluated.

## Discussion

In the present study, both cats presented a history of slowly progressive lesions, similar to the presentation in humans. Several predisposing factors may be associated with these patients, among which excessive exposure to ultraviolet light can be mentioned. This inference is associated with the fact that these cats are free-living and semi-domesticated animals residing in the Midwest region of Brazil, an area with a high incidence of ultraviolet radiation throughout the year.

Other factors such as age, gender, breed, coat, and exposure to some types of viruses may be linked (3).

Although the etiology of BISC is still unknown, there are indications of viral involvement, either by papillomavirus or others, according to hypotheses presented by Conceição *et al.* (3). In case report 1, the feline was FIV positive, a condition associated with low immunity, in addition to the loss of regulatory control over cell multiplication, leading to morpho-functional changes in cells that conferred dorsoventrally elongated nuclei, inclined in the same direction (wind-blow) and atypical, multilobular nucleoli, with clusters of chromatin that may or may not be present. Additionally, the interactions between the animal genetics and carcinogenic agents, whether chemical or physical, in cells infected by feline papillomaviruses (FcaPVs), can have their proliferation stimulated, tending to malignancy. FcaPVs show tropism for mucous membranes and squamous epithelium, and this may be linked to the occurrence of BISC, as it already has an established relationship with the appearance of SCC.

Therefore, the evaluation through immunohistochemistry for papillomaviruses, and FIV and FeLV tests are necessary and justifiable, even in the case of bowenoid histological characteristics or koilocytosis are present (12). In the animals of this report, immunohistochemistry was not performed, and FIV and FeLV tests, only in the cat of case 1.

Both cases described in this report are of adult feline patients whose lesions had an evolution course of at least one year until the animals were referred to the Veterinary Dermatology Service for investigation and diagnosis. In this scenario, the late diagnosis made impossible the investigation of the initial mild and superficial lesions presented by the cats, evolving to extensive lesion without margins for surgical excision. This elapsed time is considered essential for decision-making regarding the best treatment option and prognosis. Contrary to the age of the cats in this study, in a study with cats younger than one year of age, BISC was diagnosed in less than 1% out of over 200 animals, being, therefore, of rare occurrence. Meanwhile, Conceição *et al.* (3) identified Bowen's disease in elderly animals (> 10 years). Thus, the occurrence of BISC can be verified in cats of any age.

The cats in this study were in an advanced state of progression of the lesions, making surgical excision impossible, mainly due to their location. The lesions' location in areas with little hair and in the head region make the surgical approach difficult due to the lack of margin for the procedure (3, 5). Therefore, non-invasive techniques become treatment options. In humans, PDT is considered a treatment of choice with satisfactory results for BISC (4). Both cats had PDT recommended; however, the effectiveness of the technique could not be assessed due to owners' non-compliance with previously scheduled sessions. Solely one session was performed in the cat of case 2, in which PDT was recommended with at least three serial sessions for the lesion's progression evaluation. Yet, the advanced stage and appearance of the lesions are believed to be factors that made owners resistant to following the treatment according to what was recommended.

When left untreated, BISC can progress to SCC (4). Case 1 corroborates this statement, as the lesions in the perilabial region were consistent with invasive and moderately differentiated SCC. Yet, a small hyperechoic nodule forming an acoustic shadow was observed in the spleen caudal third at US evaluation. Although not punctured to determine its composition, the possibility of having neoplastic characteristics is not excluded. If confirmed, the case would corroborate with what is described in the literature (4, 6).

## Conclusion

The identification of mild and superficial lesions must be rigorously monitored and evaluated periodically so that the early definitive diagnosis can be established and the best therapeutic measure implemented, aligned to a better prognostic, differently from the cases reported in this study.

At macroscopic examination, chronic crusted, erosive, focal, or multifocal lesions in the head with a bilateral pattern in the pinna and labial commissure should be included as a differential diagnosis for BISC in cats. Furthermore, the involvement of thoracic limbs should be considered in the clinical evaluation after excluding other suspicions. Although a higher prevalence may be linked to adult and elderly animals, cats can be affected at any age.

## Conflict of Interest

The authors declare no competing interests.

## References

- Attili SK, Ibbotson SH. How we treat Bowen's disease with topical photodynamic therapy in Dundee. *Photodiagn Photodyn Ther.* 2009;6(1):41-5. doi: 10.1016/j.pdpdt.2009.04.001
- Azimi A, Kaufman KL, Ali M, Arthur J, Kossard S, Fernandez-Penas P. Differential proteomic analysis of actinic keratosis, Bowen's disease and cutaneous squamous cell carcinoma by label-free LC-MS/MS. *J Dermatol Sci.* 2018;91(1):69-78. doi: 10.1016/j.jdermsci.2018.04.006
- Conceição LG, Camargo LP, Costa PRS, Kuwabara PA, Fonterrada CO. Squamous cell carcinoma (Bowen's disease) *in situ* in three cats. *Arq Bras Med Vet Zootec.* 2007;59(3):816-820. doi: 10.1590/S0102-09352007000300039
- Fernández-Guarino M, Morales MLG, Bernal I, Adrada AIS, Ugia SP, Garde JB. Immunohistochemical investigation of predictors or response or aggressivity of Bowen disease after photodynamic therapy. *Photodiagn Photodyn Ther.* 2018;22:14-6. doi: 10.1016/j.pdpdt.2018.02.004
- Gómez C, Cobos M, Alberdi E. Methyl aminolevulinate-based photodynamic therapy of Bowen's disease: observational study of 21 lesions. *Photodiagn Photodyn Ther.* 2019;26:295-99. doi: 10.1016/j.pdpdt.2019.04.011
- Ho NT, Smith KC, Dobromylskyj M. Retrospective study of more than 9000 feline cutaneous tumors in the UK: 2006–2013. *J Feline Med Surg.* 2018;20(2):128-34. doi: 10.1177/1098612X17699477
- Miller MA, Nelson SL, Turk JR, Pace LW, Brown TP, Shaw DP, Fischer JR, Gosser HS. Cutaneous neoplasia in 340 cats. *Vet Pathol.* 1991;28(5):389-95. doi: 10.1177/030098589102800506
- O'Connell K, Okhovat JP, Zeitouni NC. Photodynamic therapy for Bowen's disease (squamous cell carcinoma *in situ*) current review and update. *Photodiagn Photodyn Ther.* 2018;24:109-14. doi: 10.1016/j.pdpdt.2018.09.009
- Schmidt JM, North SM, Freeman KP, Ramiro-Ibañez F. Feline paediatric oncology: retrospective assessment

- of 233 tumours from cats up to one year (1993 to 2008). *J Small Anim Pract.* 2010;51(6):306-11. doi: 10.1111/j.1748-5827.2010.00915.x
10. Silveira LMG, Cunha FM, Brunner CHM, Xavier JG. Utilização de eletroquimioterapia para carcinoma de células escamosas tegumentar em felino [The use of chemotherapy in tegumentar squamous cell carcinoma in feline]. *Pesq Vet Bras.* 2016;36(4):297-302. doi: 10.1590/S0100-736X2016000400008
  11. Spugnini EP, Baldi A. Electrochemotherapy in veterinary oncology: from rescue to first line therapy. *Methods Mol Bio.* 2014;1121:247-56. doi: 10.1007/978-1-4614-9632-8\_22
  12. Yamashita-Kawanishi N, Sawanobori R, Matsumiya K, Uema A, Chambers JK, Uchida K, Shimakura H, Tsuzuki M, Chang C-Y, Chang H-W, Haga T. Detection of *felis catus* papillomavirus type 3 and 4 DNA from squamous cell carcinoma cases of cats in Japan. *J Vet Med Sci.* 2018;80(8):1236-40. doi: 10.1292/jvms.18-0089