Braz J Vet Pathol, 2024, 17(2), 104-107
https://doi.org/10.24070/bjvp.1983-0246.v17i2p104-107

BJVP
Brazilian Journal of Veterinary Pathology
ISSN 1983-0246

Case Report

First report of melanophoroma in *Salvator merianae*

Sofia Silva La Rocca de Freitas[1], Lucas de Paula Pereira[2], Maria Estela Mendes da Silva[3], Karina Harumi Chinen[4], Márcio de Barros Bandarra[5]*

[1] Master's degree in animal sciences, Universidade de Brasília, Brasília, DF, Brazil
[2] Capixaba Institute of Education, Research and Innovation (ICEPi) - Multiprofessional Residency in Public Health, Vitória, ES, Brazil
[3] Wild animal pathology - Multiprofessional Residency, UNESP, Jaboticabal, SP, Brazil
[4] Animal pathology, UFU - Uniprofessional Residency , Uberlândia, MG, Brazil
[5] Wild animals hospital, UFU, Uberlândia, MG, Brazil

***Corresponding author:** bandarramb@ufu.br
Submitted: May 20th, 2024. Accepted: June 28th, 2024.

Abstract
Cutaneous neoplasms have been described in the class Reptilia, and many of them are related to the inadequate management of these animals in captivity. In Brazil, there are few reports of cutaneous neoplasms in *Iguana iguana*, but no reported cases in *Salvator merianae*. Therefore, the objective of this work was to report a case of a melanophoroma diagnosed in a *Salvator merianae*. A tegu with a skin nodule located in the dorsal region, close to the right scapula, measuring 1 cm, in diameter, blackish, elevated, firm in consistency, well defined, non-ulcerated and non-adherent, was surgically removed and sent to histopathology analysis, witch revel melanophoroma. The animal in this report had a follow up for eight months after the procedure, and was discharged without signs of other skin nodules. The present report seeks to add to the literature on reptile medicine by describing a histopathological diagnosis of melanophoroma in *Salvator merianae*, in addition to the clinical-surgical treatment and its respective clinical follow-up.

Keywords: cutaneous neoplasms, chromatophoromas, reptiles.

Introduction

Cutaneous neoplasms have been described in different orders within the class Reptilia. Many of them are related to the inadequate management of these animals in captivity, such as high humidity, solar radiation and inappropriate enclosures. The fundamental morphological aspects of the skin of these animals must be known so that their changes can be understood (3, 10).

The integument of reptiles is composed of the epidermis and the dermis. The epidermis consists of three layers, the inner layer is called stratum germination containing cuboidal cells that produce keratin in two forms: alpha-keratin, which is flexible and located between the scales, and beta-keratin, which provides strength and hardness. In addition, it has an intermediate layer with a water-proving barrier, containing a membrane rich in lipids and the outermost layer, stratum corneum, highly keratinized, where scales are formed (1, 9).

The dermis contains a conjunctival portion that comes from the underlying mesoderm, rich in collagen, blood vessels, sensory receptors, nerves, fibroblasts, histiocytes, plasma cells, reticulocytes and chromatophores, obtaining a primary function of nourishing the epidermis and adhering to the skin. musculature through connective tissue. The chromatophores present in the dermis are a group of cells histologically analogous to melanocytes in mammals, containing pigments and light reflectors inside and are divided into melanophores, xanthophores, iridophores and erythrophores (1, 2).

Cutaneous neoplasms in reptiles are commonly reported as isolated cases, among current reports, squamous cell carcinoma stands out as the most common, followed by papilloma and chromatophoromas (5). Chromatophoromas

are neuroectodermal tumors, often presented as raised, pigmented masses, reported most frequently in snakes, followed by lizards, chelonians and crocodilians, being classified according to cellular origin as melanophoromas (melanin-producing cells), iridophoromas (crystalline purine-producing cells containing reflecting granules of guanine, adenine, hypoxanthine or uric acid) and xanthophoromas (carotenoid or pteridine-producing cells). Macroscopically, melanophoromas are usually dark brown to black, iridophoromas are often described as white, while xanthophoromas could be yellow, orange, or red (7).

In Brazil, there are few reports of cutaneous neoplasms in lizards, with two reports of cases of melanophoroma in the species *Iguana iguana* (4, 6), but no reported cases in *Salvator merianae* (11,12, 13).

Therefore, the objective of this work was to report a case of a melanophoroma diagnosed in a *Salvator merianae*.

Case description

A tegu (*Salvator merianae*), with approximately 5 years old, weighing 2.95 kg, with a skin nodule located in the dorsal region, close to the right scapula, measuring 1 cm, in diameter, blackish, elevated, firm in consistency, well defined, non-ulcerated and non-adherent, was treated in the Wild Animals Sector of the Veterinary Hospital of the Federal University of Uberlândia.

A cytological examination was carried out using fine needle aspiration, stained with Panoptic, where microscopically it was observed that the sample was made up of discrete cellularity, composed of cells arranged in isolation. Medium-sized cells, elongated shape, sometimes indistinct cytoplasmic boundaries, containing blackish granules in varying quantities. The nuclei, when visible, were elongated, sometimes rounded, with finely dotted chromatin and indistinct nucleoli. Anisocytosis and anisokaryosis were discrete, with discrete cellular pleomorphism. In the background, rare red blood cells and a moderate amount of blackish granules. Therefore, the cytological diagnosis was suggestive of melanophoroma.

A pre-surgical ultrasound was performed, with no signs of metastasis. Thus, the animal underwent general anesthesia for the nodulectomy surgical procedure, and the removed fragment was placed in 10% formalin. The tissue was embedded in paraffin, sectioned at 3µm thickness and stained with hematoxylin and eosin.

In histopathology, it was possible to observe a fragment of scaly skin presenting a poorly delimited neoplastic proliferation in the epidermis and deep dermis composed of round cells arranged in small isolated groups (objective 40x). The cells have a round and sometimes oval shape, medium size and poorly defined boundaries, with a moderately eosinophilic cytoplasm sometimes filled with brownish granules. The nuclei were round to oval, central to paracentral location, with coarse chromatin, nucleoli sometimes evident and single (objective 100x). Moderate cellular pleomorphism characterized by anisocytosis and moderate anisokaryosis. There were three mitotic figures in 10 high power fields (field of view 2.37mm 2) and with free margins (400x objective) with free margins (Figure 1, 2). There was no junctional activity, lentiginous spread or pagetoid spread in the sample analyzed, parameters commonly used to assess degree of malignancy.

In this way, it was possible to confirm the diagnosis of melanophoroma. The animal in this report had a follow up for eight months after the procedure, and was discharged without signs of other skin nodules.

Discussion

The aspects observed in cytology and histology in the present report were conclusive for the diagnosis of melanophoroma, as well as the case described by Irizarry-Rovira (4).

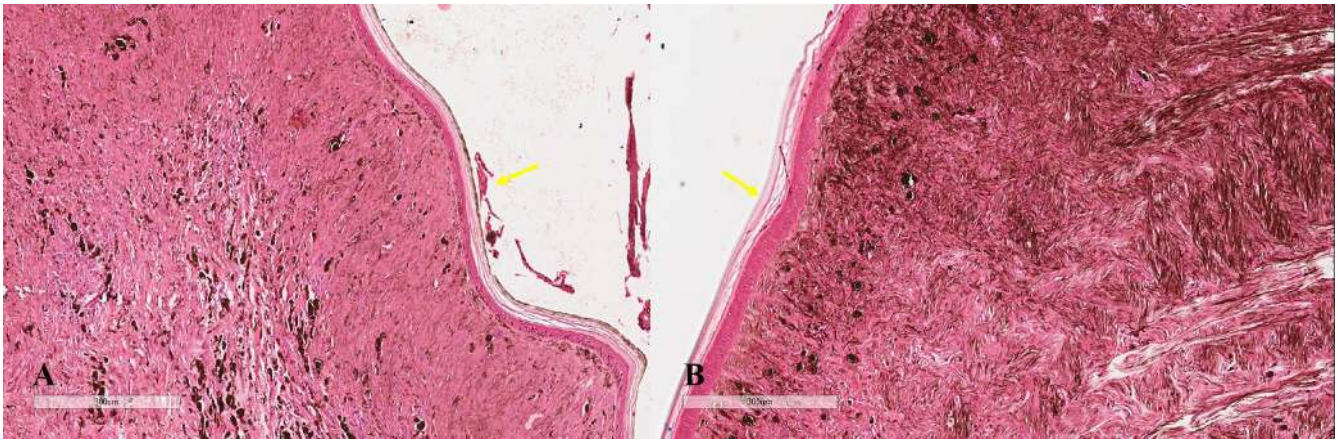

Figure 1. A- and B- Cutaneous melanoma in *Tupinambis merianae*. Round cells, sometimes oval in shape, medium in size and poorly defined boundaries. Cytoplasms are moderate and filled with brownish granules (circles and arrow). (H.E., bar = 100 µm).

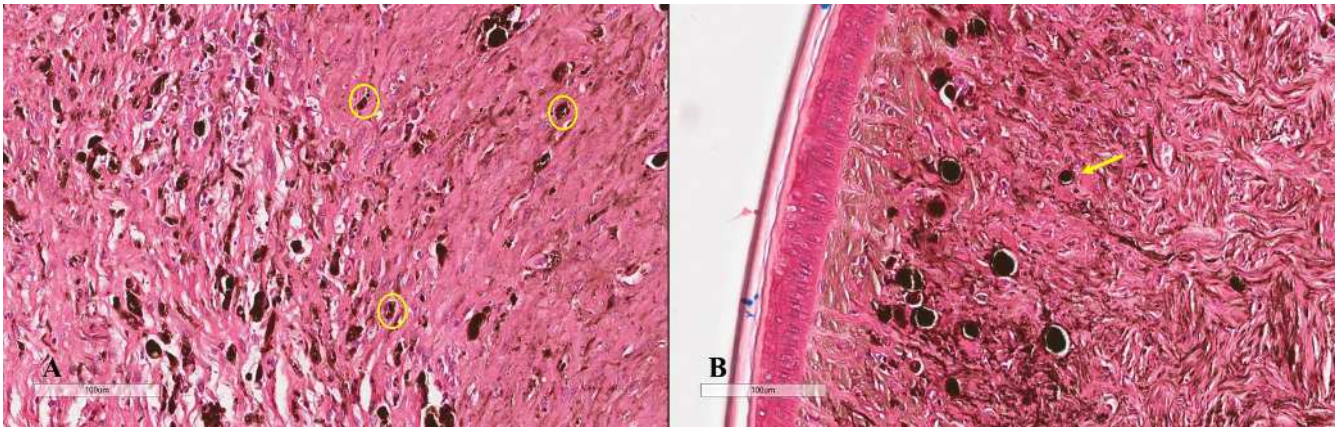

Figure 2. A and B: Cutaneous melanoma in *Tupinambis merianae*. Round cells, sometimes oval in shape, medium in size and poorly defined boundaries. Cytoplasms are moderate and filled with brownish granules (circles and arrow). (H.E., bar = 100 µm).

In a study carried out by Monohan (8), histomorphologic features were adequate to diagnose chromatophoromas in bearded dragons, especially when the neoplasms had some degree of pigmentation to confirm chromatophore origin. The use of immunohistochemistry showed no degree of melan A immunoreactivity in none of the neoplasms, nor the normal dermal melanocytes were immunoreactive for melan A. Based on results with bearded dragons and with snakes, the sensitivity of melan A in reptiles seems to be low. IHC was not found to aid differentiation of the different subsets of chromatophoromas, even though IHC for S100 and potentially PNL2 may aid in the diagnosis of poorly pigmented or nonpigmented chromatophoromas (8), but, in cases that the tumor isn't pigmented, ideally electron microscopy must be performed for better differentiation (7). Hence, since the tumor in the present work was well pigmented, the IHC was not performed.

Chromatophoromas, in general, can have a malignant behavior, which highlights the importance of careful postoperative monitoring, in addition to being extremely important to remove the tumor with free margins, as carried out in the present study (2). According to a retrospective study by Kubiak (6), the most common skin neoplasm in lacertids is squamous cell carcinoma, and melanophoroma is in seventh place, with a 3.9% rate of incidence. In the study by Hackers (2), which specified only tumors originating from chromatophores, melanophoroma was the most common. Although it has not been reported in *Salvator merianae*, the most affected species was a lacertidae, *Pogona vitticeps*. Of the 20 cases of melanophoroma in this study, 17 were infiltrative in the muscles, and 11 were metastatic. In only 5 cases, the tumor did not recur after surgical excision, with veterinary follow-up lasting between 7 months and 7 years. The animals that presented recurrence occurred within a period of up to seven months after the operation.

Although such a tumor has been reported in some species of lacertids, there is still no knowledge of its occurrence in tegus. Monitoring the animal, compatible with the time observed by Heckers (2), did not reveal signs of metastasis or other changes in the animal's skin.

The present report seeks to add to the literature on reptile medicine by describing a histopathological diagnosis of melanophoroma in *Salvator merianae*, in addition to the clinical-surgical treatment and its respective clinical follow-up.

Conflict of Interest

The authors declare no competing interests.

References

1. Abreu-Silva AL, Silva JA, Souza KR, Santos DM, Pereira JG, Carvalho RC, Ambrosio CE, Miglino MA. Estudo histológico e histoquímico da pele de jurará Kinosternon scorpioides scorpioides (Testudines: Kinosternidae). Pesqui Vet Bras. 2014;34(9):911-6. doi: 10.1590/s0100-736x2014000900017.
2. Heckers KO, Aupperle H, Schmidt V, Pees M. Melanophoromas and iridophoromas in reptiles. J Comp Pathol. 2012;146(2-3):258-68. doi: 10.1016/j.jcpa.2011.07.003.
3. Hellebuyck T, Scheelings T F. Dermatology - Skin. In: Mader DR, Divers SJ, Stahl SJ. *Mader's reptile and amphibian medicine and surgery*. Elsevier Inc; 2020;699-712.
4. Irizarry-Rovira AR, Wolf A, Ramos-Vara JA. Cutaneous melanophoroma in a green iguana (Iguana iguana). Vet Clin Pathol. 2006;35(1):101-5. doi: 10.1111/j.1939-165x.2006.tb00096.x.
5. Kubiak M, Denk D, Stidworthy MF. Retrospective review of neoplasms of captive lizards in the United Kingdom. Vet Rec. 2020;186(1):28. doi: 10.1136/vr.105308.

6. Macêdo IL, Sousa DER, Hirano LQL, Name KPO, Báo SN, Castro MB. Nasal melanophoroma in a captive green iguana (Iguana Iguana). Top Companion Anim Med. 2020;41:100463. doi: 10.1016/j.tcam.2020.100463
7. Monahan CF, Garner MM, Kiupel M. Chromatophoromas in reptiles. Vet Sci. 2022;9(3):115. doi: 10.3390/vetsci9030115.
8. Monahan CF, Meyer A, Garner MM, Kiupel M. Gross, histologic, and immunohistochemical characteristics of cutaneous chromatophoromas in captive bearded dragons. J Vet Diagn Invest. 2021;33(5):932-8. doi: 10.1177/10406387211025651.
9. O'Malley B. Chapter 4 - Lizards. In: O'Malley B, *Clinical anatomy and physiology of exotic species: structure and function of mammals, birds, reptiles and amphibians*. W.B. Saunders. 2005;47-75. doi.org/10.1016/B978-070202782-6.50007-7
10. Paré JA, Jacobson ER. Mycotic Diseases of Reptiles. In: Jacobson ER, *Infectious Diseases and Pathology of Reptiles*. CRC Press; 2007;(1)541-84. Available in: https://doi.org/10.1201/9781420004038-16
11. Ramos P, Victor P, Branco S. Spontaneous melanotic lesions in axillary seabream, Pagellus acarne (Risso). J Fish Dis. 2013;36(9):769-77. doi: 10.1111/jfd.12031.
12. Rivera S, Crane MM, McManamon R, Gregory CR. Surgical treatment of pulmonary melanophoroma in a beaded lizard (Heloderma horridum exaperatun). J Zoo Wildl Med. 2015;46(2):397-9. doi: 10.1638/2014-0188R2.1.
13. Thompson KA, Campbell M, Levens G, Agnew D. Billaterally symmetrical oral amelanotic melanoma in a Boa constrictor constrictor. J Zoo Wildl Med. 2015 Sep;46(3):629-32. doi: 10.1638/2015-0028.1.