Braz J Vet Pathol, 2024, 17(2), 132-135
https://doi.org/10.24070/bjvp.1983-0246.v17i2p132-135

BJVP
Brazilian Journal of Veterinary Pathology
ISSN 1983-0246

Diagnostic Exercise
From the Latin Comparative Pathology Group and the Davis-Thompson Foundation:

Poisoning by *Baccharis coridifolia* in cattle

Adriana L. Stigger[1], David Driemeier[2], Saulo P. Pavarini[2], Welden Panziera[2], Fernanda F. Perosa[2], Milena C. Paz[2], Claudio S.L. Barros[3]

[1]Laboratory of Veterinary Pathology, Centro Universitário da Região da Campanha (Urcamp), Alegrete, RS, Brazil
[2]Branch of Veterinary Pathology, Faculdade de Medicina Veterinária, Universidade Federal do Rio Grande do Sul (UFRGS), Porto Alegre, RS, Brazil.
[3]Laboratório de Anatomia Patológica, Universidade Federal de Mato Grosso do Sul, Campo Grande, MS, Brazil.

Corresponding author: claudiobarros1945@gmail.com

Clinical History:

In mid-November (springtime), a farmer bought 17 bovines at a livestock fair. The group comprised 11 pregnant cows aged eight months and six heifers aged 16 months. The cattle were then transported by truck to a farm 300 km away from the site of purchase. Upon arrival, the farmer released them into a pasture where a particular weed was abundant (Fig.1). Approximately 24 hours after being introduced into this weed-invaded field, the first deaths occurred and continued for three days (Fig. 2). Eleven cattle died, comprising seven pregnant cows and four yearling heifers. One of the cows was found recumbent with a fever and lying in an area of waterlogged pasture (Fig. 2B). The cow presented clinical signs of restlessness, continuous



Figure 1. **A.** Weed photographed in October (the sprouting period in the springtime) during the outbreak of the disease in cattle. **B.** Weed photographed in March (blooming period in the fall).

*The Diagnostic Exercises are an initiative of the Latin Comparative Pathology Group (LCPG), the Latin American subdivision of The Davis-Thompson Foundation (DTF). These exercises are contributed by members and non-members from any country of residence. Consider submitting an exercise! A final document containing this material with answers and a brief discussion will be posted on the DTF website: https://davist- hompsonfoundation.org/diagnostic-exercise/

Editor-in-chief: *Claudio Barros*
Associate Editor for this Diagnostic Exercise: *Daniel Rissi*



Figure 2. **A.** Acute mortality in cattle recently introduced in a weed-invaded pasture. Several deaths occurred in within 36 hours. Similar degrees of postmortem emphysema indicate a short interval between fatalities. **B.** This cow had a fever, was drooling, and could not stand. It was euthanized and necropsied. Several specimens of the weed shown in Fig. 1 in the background.

lying down and getting up, sometimes with instability of the pelvic limbs, muscle tremors, dry snout, and sialorrhea. It was then euthanized and necropsied; the necropsy and histopathological features provided in this report are from this cow. A botanical investigation of the weed shown in Fig. 1 identified it as Baccharis coridifolia. Subsequent field investigations on both farms demonstrated that B. coridifolia was absent on the property from which the 17 cattle were purchased.

Necropsy findings: Necropsy findings included dehydration, a large volume of liquid content in the rumen, and varying degrees of reddening of the mucosae of the pre-stomachs, particularly the rumen (Fig. 3). The mesenteric lymph nodes were swollen, moist, and red. Marked subendocardial hemorrhages were seen in the left ventricle.

Follow-up-Questions.

- *Morphologic diagnosis?*
- *Etiologic diagnosis?*
- *Etiology?*
- *Name of the condition?*

ANSWERS

Microscopic Description: There were degenerative and necrotic changes evident in the epithelial lining of the rumen and reticulum (Fig. 4.) Multiple ruminal epithelial lining cells had hydropic degeneration, and many were necrotic (Fig. 4). In segmental areas of the loose connective tissue of the lamina propria-submucosa was infiltrated by mixed inflammatory cell or were frankly necrotic. In the affected



Figure 3. Multifocal areas of moderate reddening of the ruminal mucosa.

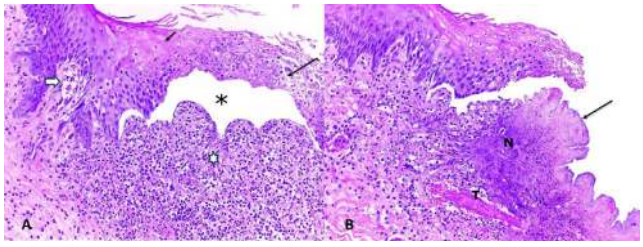

Figure 4. *Baccharis coridifolia* poisoning in a cow. Rumen. **A.** Epithelial lining cells are swollen (*small black arrow*), vacuolated, or necrotic (*large black arrow*). Changes in the connective tissue of the lamina propria-submucosa include hyperemia (*white arrow*) and mixed cellular inflammatory infiltration (*white star*). The stratified cornified ruminal epithelium over the lamina propria-submucosa was detached in these areas, leaving a cleft (*asterisk*). **B.** The focal loss of the stratified cornified ruminal epithelium left a denuded and necrotic lamina propria-submucosa (*N*); aggregates of coccoid bacteria appeared to adhere to the denuded lamina propria-submucosa (*large black arrow*). A thrombus (*T*) is noticed in a blood vessel in the lamina propria-submucosa.

areas, the stratified cornified ruminal epithelium was detached from the underlying lamina propria-submucosa, resulting in a cleft where coccoid bacteria aggregates appeared to adhere to the denuded lamina propria-submucosa. Additionally, vessels

within the lamina propria-submucosa were congested and occasionally presented thrombosis. Moreover, necrosis of lymphoid tissue (not represented in the pictures) occurred in the gastrointestinal lymph nodes and lymphoid aggregates.

- *Morphologic diagnosis*:
  Necrotic ruminitis, diffuse, acute, severe.

- *Cause*:
  Poisoning by *Baccharis coridifolia* (macrocyclic trichothecenes containing plant).

- *Etiologic diagnosis:*
  Phytotoxic ruminitis.

- *Differentials:*
  Other plants containing macrocyclic trichothecenes, poisoning by *Baccharis alternaria*, ruminal acidosis, poisoning by arsenic and fluorosilicates.

Comments: Epidemiological data, associated with the clinical course and lesions observed favored the diagnosis of *B. coridifolia* poisoning in the current case. *B. coridifolia* is one of the most recognized toxic plants in southern Brazil, where it grows in the states of Rio Grande do Sul, Santa Catarina, and Paraná (1). The plant is also found in the southeastern Brazilian state of São Paulo, and in large areas of Uruguay, northern Argentina, and Paraguay (1). It is a dioecious plant that sprouts in the spring (from October to November) and blooms in late summer and early fall (from the end of February to April). *B. coridifolia* is 4 to 8 times more toxic when flowering. Doses as low as 0.25–0.5 g/kg/bodyweight of the green flowering plant may cause deaths in cattle. In the sprouting period, 2 g/kg/body weight is required for the same effect (10). However, toxicosis can occur at any time of the year, and heavy cattle losses have been reported in the spring (1), as observed in the outbreak involving the cow in this report.

Although poisoning by *B. coridifolia* may occur in several livestock species, it mainly affects cattle; important aspects of epidemiology, clinical course, and lesions of this toxicosis to consider for the diagnosis are (1):

- Typically, the intoxication occurs when cattle raised in zones free of the plant are transported and released into pastures infested with *B. coridifolia*. The risk of intoxication increases considerably if, during transport, animals undergo prolonged transportation, stress, hunger, and thirst.
- The toxicosis runs a peracute or acute and usually fatal clinical course. In fatal cases in cattle, the clinical signs begin, respectively, 5–29 h and 2–42 h after the onset of the signs.

The clinical signs are generally non-specific and include loss of appetite, mild-to-moderate bloat, hind limbs instability, muscle tremors, dry muzzle, ocular secretion, lack of rumination, and colic (the animal lies down repeatedly, kicking the abdomen and groaning). Lethality is high.

Data on morbidity and mortality ratios of *B. coridifolia* poisoning are scarce in the literature. Many cases probably are not reported to diagnostic laboratories due mainly to two factors: most farmers and veterinary practitioners recognize the disease without the aid of the laboratory, and the incidence of the poisoning has decreased in the face of awareness about prophylactic measures. However, when data are available, mortality rates of 20% and 50%, respectively, have been reported 72 and 30 hours after cattle were introduced into pastures heavily infested with *B. coridifolia* (1). Similar or even higher percentages have been informally reported, although not documented.

In affected cattle, the main lesions consist of degeneration and necrosis of the lining epithelium of the pre-stomachs, as well as necrosis of the lymphoid tissue (1).

Macrocyclic trichothecenes, including roridins, are responsible for the toxic effects of *B. coridifolia* (2) and three other *Baccharis* species (*B. megapotamica, B. weirii*, and *B. artemisioides*) (1,4,8). Trichothecenes are a broad group of fungi-produced terpenes–mycotoxins known to be associated with human and livestock diseases. There are two theories regarding the trichothecenes' source in *Baccharis* plants: (*i*) *Baccharis* plants biosynthesize trichothecenes, or (*ii*) the toxic species of *Baccharis* have associated endophyte(s) that synthesize the plant-derived trichothecenes (8).

An outbreak of poisoning by *Baccharis vulneraria* (formerly *Baccharidastrum triplinervium*) in dairy cows was reported in southern Brazil; the disease was clinically and pathologically like that caused by other species of *Baccharis,* but no macrocyclic trichothecenes were detected in this plant (5). *Baccharis pteronioides* is a North American species of *Baccharis* that grows in clusters in gravelly soil across Texas, New Mexico, Arizona, and northern Mexico. Although it has been associated with cattle poisoning for near a century, there is no convincing evidence to support a definitive association between the ingestion of the plant with mortalities in cattle. The attempts to reproduce the toxicosis in hamsters feeding large doses of *B. pteronioides* resulted in a disease characterized histologically by severe necrotizing vasculitis with vascular thrombosis of hepatic and renal vessels, a condition that resembles bacterial endotoxin-produced vasculitis and infarction (9). Other North American species, such as *B. halimifolia* and *B. glomeruliflora*, are also suspected of being toxic to livestock. Still, their association with livestock losses remains unclear (1).

The mechanisms underlying death in livestock poisoned by species of *Baccharis* containing macrocyclic trichothecenes are not fully understood. It is suggested that dehydration, electrolyte imbalance and septicemia derived from bacterial invasion due to rupture to of the GI tract epithelial lining with consequent disseminated intravascular coagulation may participate (6).

Differential diagnosis should include intoxication by other species of *Baccharis*, that share the same toxic principle (macrocyclic trichothecenes) i.e., *B megapotamica, B. weirii*, and *B. artemisioides* (6,8). Epidemiological data and the presence of the plant at the site of the deaths should help to conclude the diagnosis. Poisoning by *B. vulneraria* has some similarities *B. coridifolia* poisoning, but is uncommon, much milder, with low mortality rates and does not cause necrosis in lymphoid organs (5). Lesionwise, *B. coridifolia* poisoning resembles ruminal acidosis by carbohydrate overload (7), arsenic (3), and fluorosilicate (7) poisoning. Some aspects of the history and gross or microscopic lesions might help to differentiate those from *B. coridifolia* poisoning. Ruminal acidosis in cattle has a history of excessive carbohydrate intake in a change of diet in non-adapted animals or of an abrupt introduction of an excessive amount of carbohydrates in already adapted animals. Arsenic poisoning generally has a history associated with the application of arsenic-based herbicides to pastures (3); the lesions are more severe than those of *B. coridifolia* toxicosis, and prominent vascular lesions occur (3). Due to the remarkable similarity between *B. coridifolia* poisoning and acute fluoride poisoning in cattle, the presence of the plant on the property is essential to confirm the diagnosis; also, an important distinguishing feature of *B. coridifolia* poisoning in cattle is the occurrence of the disease in animals from areas where the plant does not exist, and that was recently (a few hours previously) introduced into fields infested by this weed (7).

References

1. Barros CSL, Jarvis BB. Livestock Intoxication by *Baccharis*. In: Fernandes GW, Oki Y, Barbosa M, editors. *Baccharis*: From Evolutionary and Ecological Aspects to Social Uses and Medicinal Applications. Cham, Switzerland: Springer; 2021, p.383-98.
2. Busam L, Habermehl GG. 1982. Accumulation of mycotoxins by *Baccharis coridifolia:* a reason for livestock poisoning. Naturwissenschaften 1982; 69:391-3.
3. Gonçalves MA, Cruz RAS, Reis MO, Pavarini SP, Sonne L, Driemeier D. Vascular injury in spontaneous subacute toxicosis caused by organic arsenic in cattle. Pesq Vet Bras. 2017; 37(7): 676-80.
4. Kupchan SM, Jarvis BB, Dailey Jr, RG Bright W, Bryan R, Shizuri Y. Baccharin, a novel potent antileukemic trichothecene triepoxide from *Baccharis megapotamica*. J Am Chem Soc. 1976; 98:7092–3
5. Langohr IM, Gava A, Barros CSL. Intoxicação por *Baccharidastrum triplinervium* (Asteraceae) em bovinos. Pesq Vet Bras. 2005; 25:235–238
6. Oliveira-Filho JC, Carmo PMS, Lucena RB, Pierezan F, Barros CSL. *Baccharis megapotamica* var. *weirii* poisoning in water buffalo (*Bubalus bubalis*). J Vet. Diagn Invest. 2011;23(3):610-4.
7. Panziera W. Schwertz CI, da Silva FS, Taunde PA, Pavarini SP, David D. Intoxicação aguda por fluossilicato de sódio em bovinos [Acute sodium fluorosilicate poisoning in cattle] Acta Sci Vet. 2018; 46:1-5. Portuguese.
8. Rizzo I, Varsavky E, Haidukowski M, Frade H. Macrocyclic trichothecenes in Baccharis coridifolia plants and endophytes and *Baccharis artemisioides* plants. Toxicon 1997; 35:753–7
9. Stegelmeier BL, Sani Y, Pfister JA. *Baccharis pteronioides* toxicity in livestock and hamsters. J Vet Diagn Investig. 2009; 21:208–13
10. Tokarnia CH, Döbereiner J. Intoxicação experimental em bovinos por "mio-mio" *Baccharis coridifolia*. Pesq Agrop Bras. 1975; 10:79–97