Braz J Vet Pathol, 2024, 17(3), 230-232
DOI: https://10.24070/bjvp.1983-0246.v17i3p230-232

BJVP
Brazilian Journal of Veterinary Pathology
ISSN 1983-0246

Diagnostic Exercise
From the Latin Comparative Pathology Group and the Davis-Thompson Foundation:

Choledocholithiasis and associated hepatopathy in a horse

Estefania Montero[1], Eileen Henderson[2], Javier Asín[2], and Francisco A. Uzal[2]

[1]Veterinary Pathology Service. School of Veterinary Medicine, Department of Animal Production and Health, Public Veterinary Health and Food Science and Technology, Universidad Cardenal Herrera-CEU, CEU Universities, Valencia, Spain.
[2]California Animal Health and Food Safety Laboratory System, San Bernardino Branch, School of Veterinary Medicine, University of California-Davis, San Bernardino, CA, USA.

***Corresponding author:** estefania.montero@uchceu.es

Clinical history:

An 11-year-old bay Warmblood mare with a long-standing history of liver disease was presented to the submitting veterinarian with a three-day history of colic and fever. Initial tests revealed an elevated PCV and leukopenia, accompanied by increased lactate and creatinine levels. Clinically, the horse exhibited swollen limbs and mucosal petechiae. After initial treatment, including intravenous fluids and anti-inflammatory medications, the horse improved briefly but subsequently deteriorated, showing signs of ataxia. Because of the poor prognosis, the horse was euthanized, and a full necropsy was performed.

Autopsy and histopathological findings:

The liver was enlarged, firm and displayed an acinar pattern and orange-yellow discoloration. The common hepatic duct was markedly distended and contained an ~ 6-7 cm diameter round, semi-soft, dark-yellow choledocholith (Fig. 1). At cross section, there was a marked marked acinar pattern and orange-yellow discoloration(Fig. 2). Histopathological aspects of the liver are shown in Figs 3-4.

Follow-up questions:

- *Histological description:*
- *Morphologic diagnoses:*
- *Name of the condition:*

**The Diagnostic Exercises are an initiative of the Latin Comparative Pathology Group (LCPG), the Latin American subdivision of The Davis-Thompson Foundation (DTF). These exercises are contributed by members and non-members from any country of residence. Consider submitting an exercise! A final document containing this material with answers and a brief discussion will be posted on the DTF website: https://davist- hompsonfoundation.org/diagnostic-exercise/*

Editor-in-chief for this Diagnostic Exercise: *Claudio Barros*
Associate Editor for this Diagnostic Exercise: *Francisco Uzal*

Braz J Vet Pathol, 2024, 17(3), 230-232
DOI: https://10.24070/bjvp.1983-0246.v17i3p230-232

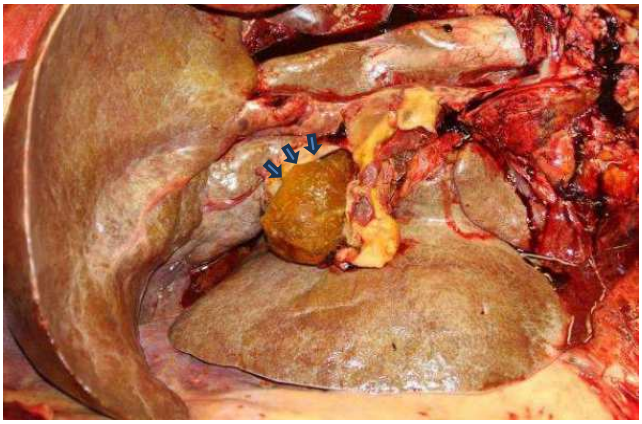

Figure 1. Liver, horse. The liver is enlarged, firm and displays an acinar pattern and orange-yellow discoloration. The common hepatic duct is markedly distended and contains an ~ 6-7 cm diameter round, semi-soft, dark-yellow choledocholith (arrows).



Figure 2. Liver; cross section. Marked acinar pattern and orange-yellow discoloration.

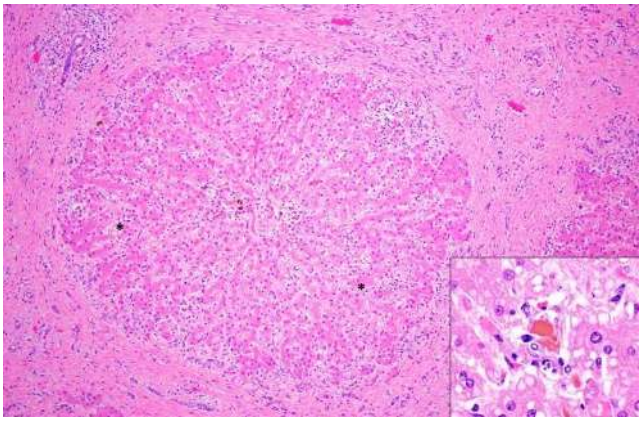

Figure 3. Liver. Severe, diffuse bridging periportal fibrosis and bile duct hyperplasia. The hepatocytes adjacent to the portal tracts (asterisks) exhibit degeneration, with vacuolated cytoplasm and brown pigment. Inset: bile microgranuloma with bile stasis, surrounded by macrophages, lymphocytes and neutrophils. HE.

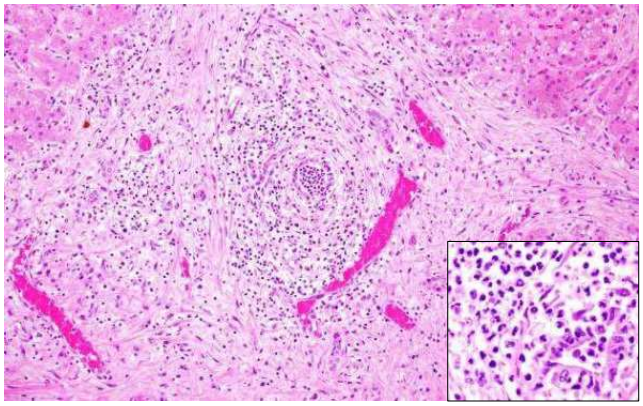

Figure 4. Liver. Inflammatory infiltrate composed of neutrophils, lymphocytes and plasma cells inside and around the bile ducts in portal areas. There is also fibrosis and bile duct hyperplasia. Inset: higher magnification of inflammatory infiltrate. HE.

ANSWERS

Histological description

Diffusely, the normal hepatic architecture is disrupted, and portal areas are expanded by bridging tracts of fibrous connective tissue surrounding hepatocytes, resulting in a multinodular appearance. There are numerous embedded bile duct profiles of variable size admixed with many neutrophils, lymphocytes and plasma cells. Multifocally, bile ducts are dilated by green, brown pigment, and are frequently surrounded by foamy macrophages. The hepatocytes adjacent to the portal tracts are markedly swollen with a clear vacuolated cytoplasm and there is single cell death characterized by hypereosinophilic cytoplasm and nuclear pyknosis, karyorrhexis or karyolysis.

Morphologic diagnoses

1- Choledocholithiasis with complete obstruction of common hepatic duct by a choledocholith.
2- Hepatopathy, with:
   i) bridging portal fibrosis, multinodular, diffuse, severe.
   ii) bile stasis, multifocal, severe, with bile microgranulomas.
   iii) bile duct hyperplasia, multifocal, severe.
   iv) cholangiohepatitis, neutrophilic and lymphoplasmacytic.

Name of the condition: Choledocholithiasis

Comments

In contrast to other domestic species, the hepatobiliary system of horses is devoid of a gall bladder.

Consequently, bile is discharged through the common hepatic duct, which is formed by the convergence of the right and left hepatic ducts (1,6). This anatomical distinction has functional implications: unlike domestic ruminants and carnivores, horses experience continuous bile flow due to their lack of bile storage capacity.

Choledocholithiasis is a relatively rare condition in horses (1, 6). Calculi typically form simultaneously in the biliary ducts and in the common hepatic duct, and are referred to as choleliths and choledocholiths, respectively (9). The latter are the most common cause of biliary obstruction in horses (7). When the obstruction of the common hepatic duct is complete, like in this case, hepatopathy ensues. This is characterized by severe bridging fibrosis with biliary duct hyperplasia (3, 2). Secondary biliary hepatic fibrosis associated with cholelithiasis is commonly linked to liver enlargement (9).

In this case, fibrosis was considered to be secondary to the presence of a choledocholith in the lumen of the common hepatic duct, which obstructed bile flow and excretion. These findings suggest intermittent biliary obstruction over an extended period (1). Additional supporting findings included hydropic change occurring in hepatocytes suffering prolonged cholestasis (3), and multifocal bile microgranulomas, which have also been described as indicative of cholestasis both within the sinusoids (9, 5) and in and around the centrilobular zone (3).

The etiopathogenesis of cholelithiasis involves increased concentration and precipitation of unconjugated bilirubin (2), which occurs due to heightened hepatic, biliary, pancreatic, and/or bacterial enzymatic activity. Enteric organisms such as *Salmonella* spp., *Escherichia coli*, *Aeromonas* spp., *Citrobacter* spp., and *Streptococcus* spp. (4, 5), are frequently isolated from the liver of horses with cholelithiasis (9). No bacterial cultures were performed in this case, however.

The risk of developing biliary calculi increases with age, with most affected horses being older than 9 years (2). The severity of the condition is also more severe in older horses. Cholelithiasis is often found incidentally during necropsy, but it may also present as a clinical condition with progressive weight loss due to hepatic fibrosis (4), anorexia, jaundice, fever, depression (7, 8), and intermittent colic caused by partial obstruction of the duodenal lumen by biliary calculi pressing on the major duodenal papilla (6, 2). Leukocytosis, hyperbilirubinemia with elevated direct bilirubin, alkaline phosphatase, aspartate aminotransferase, gamma-glutamyl transferase, creatine phosphokinase, lactate dehydrogenase, and fibrinogen levels may be observed in cases of cholelithiasis due to biliary obstruction (8, 9).

The underlying cause of the neurologic clinical signs observed terminally in this horse was not determined. It was initially suspected that the severe liver disease led to hepatic encephalopathy; however, no brain lesions indicative of this condition were observed.

References:

1. Bianchi M, Santos de Mello L, Lorenzett MP, Soares da Silva F, Panziera W, Konradt G, Driemeier D, Petinatti S. Secondary biliary hepatic fibrosis caused by cholelithiasis in two horses. J Equine Vet Sci 2017; 56:52-6.
2. Carr EA, Caron JP, Peroni JP. Endoscopic diagnosis of choledocholithiasis of the common bile duct in a horse. Equine Vet Educ 2004; 16:68-71.
3. Cullen JM, Stalker MJ. Liver and biliary system. In: Maxie MG, editor. Jubb, Kennedy & Palmer's Pathology of Domestic Animals. 6th ed. Philadelphia: Elsevier; 2016. p. 259-352.
4. Da Silva VCM, Magalhães JF, Ecco R, Faleiros RR, Carvalho RM, Guedes RM. Pathological findings of cholelithiasis in two horses. Braz J Vet Pathol; 2014; 7:35-7.
5. Gerros TC, Mcguirk SM, Biller DS, Stone WS, Ryan J. Choledocholithiasis attributable to a foreign body in a horse. J Am Vet Med Assoc 1993; 202:301-3.
6. Pearson EG. Liver disease in the mature horse. Equine Vet Educ 1999; 11:87-96.
7. Peek SF, Divers TJ. Medical treatment of cholangiohepatitis and cholelithiasis in mature horses: 9 cases (1991-1998). Equine Vet J 2000; 32:301-6.
8. Reef VB, Johnston JK, Divers TJ, Acland H. Ultrasonographic findings in horses with cholelithiasis: eight cases (1985–1987). J Am Vet Med Assoc; 1990; 196:1836-40.
9. Ryu S, Bak U, Lee C, Lee YL. Cholelithiasis associated with recurrent colic in a Thoroughbred mare. J Vet Sci 2004; 5:79-82.