BJVP
Brazilian Journal of Veterinary Pathology

Original full paper

Diagnostic significance of mitotic index and AgNOR count in canine mammary tumours

Pawan Kumar[1], Ram Kumar[1], Rajvir S. Pawaiya[1] and Madhu B. Puttaswamy[2]

[1]Division of Veterinary Pathology Indian Veterinary Research Institute, Izatnagar- 243122, Uttar Pradesh, India
[2] Veterinary officer, Karnataka, India
Corresponding author: R.V.S. Pawaiya, Izatnagar - 243122, Uttar Pradesh, India

Submitted February 23th 2010 Accepted April 5th 2010

Abstract

The present study was designed to investigate the significance of mitotic index and AgNOR count in canine mammary tumours. Samples from 74 grossly suspected cases of bitches for mammary tumour were collected from different veterinary hospitals in 10% buffered formalin, of which 65 were confirmed as tumours on histopathological examination. Among them, 11 (16.92%) were benign and 54 (83.08%) were malignant tumours. Benign tumours included benign mixed mammary tumour (36.36%), fibroadenoma (27.27%), duct papilloma (18.18%) and simple adenoma (18.18%). The malignant mammary tumours comprised of papillary adenocarcinoma (27.78%), malignant mixed mammary tumour (25.92%), solid carcinoma (18.52%), squamous cell carcinoma (5.56%), fibrosarcoma (5.56%), infiltrative adenocarcinoma (3.7%), mucinous carcinoma (3.7%) and each (1.54%) of osteochondrosarcoma, carcinosarcoma, myxosarcoma, intraductal carcinoma and spindle cell carcinoma (malignant myoepithelioma). Mitotic index and AgNOR counts were significantly ($P<0.05$) differ for benign and malignant mammary tumours. Among malignant mammary tumours mitotic index ranged from 1.08 to 4.19 with solid carcinoma showing the highest index (4.197±1.570) and osteochondrosarcoma the lowest (1.08±0.0) while in benign mammary tumours, it ranged from 0.63 t0 0.9. AgNOR counts were significantly lower (2.57± 0.68) in benign mammary tumours than malignant (3.38±1.01). From this study it was concluded that mitotic index and AgNOR count was a good indicator of transformation of tumours towards the malignancy.

Introduction

Spontaneously occurring canine mammary tumours had been studied extensively worldwide compared with all other tumours of canines and it observed to be the most frequent of all neoplasia (52%) occurring in bitches (13). Canine mammary glands appear to be more susceptible to develop tumours compared with other animals. The incidence of canine mammary tumours varies from 198 to 622.6 cases per 100,000 dogs per year (2, 9, 14, 20). Malignant types of canine mammary tumours are more frequent than benign ones (17, 18).It is difficult to determine the biologic behavior of tumour by microscopic examination alone, so biological parameters such as tumour ploidy, cell proliferation, different hormonal receptors and other markers are important additives in its diagnosis as well as prognosis. The commonly used proliferative markers in diagnosis are mitotic figures count, argyrophilic nucleolar organizer regions (AgNORs), thymidine-labeling index, Ki-67 and proliferating cell nuclear antigen (PCNA) (1, 11).

AgNOR, a molecular marker used to study the rapidity of cell proliferation in various types of tumours (4). Nucleolar organizer regions (NORs) are loops of DNA present in the nucleoli. They contained genes that code for ribosomal RNA (rRNA) which are transcribed by RNA polymerase I (7). Certain argyrophilic proteins, called NOR-associated proteins (NORAPs), were associated with this gene. These argyrophilic nuclear organizer region proteins said to accumulated in highly proliferating cells of tumours due to its segregation during transcription which could be demonstrated as black dots with silver staining on routine histopathological sections and called as argyrophilic nucleolar organizer regions (AgNORs) (3). The number of interphase AgNORs in continuously proliferating cells had been strictly related to the rapidity of cell proliferation (19). Most convenient, economic and easy way to measure cell proliferation

 All rights reserved 2007.

rate is by counting the mitotic figures in haematoxylin and eosin stained sections and AgNOR counting. As both mitotic index and AgNOR count related to proliferative activity of cells in a tumours, the present study designed to evaluate the diagnostic importance of these markers in canine mammary tumours.

Materials and methods

Collection of samples:

A total of 74 suspected cases of spontaneously occurring canine mammary tumours collected from different Veterinary Hospitals. The tumour samples preserved in 10% neutral buffered formalin for histopathological examination immediately after surgical removal along with case history including age, sex, breed and location of tumour.

Histopathology:

For histopathological examination, representative tissue pieces from the formalin fixed tumour specimens were taken and processed to obtain haematoxylin and eosin (H&E) staining for histopathological study (12). The histopathological classification of tumours was performed according to the standard classification (14).

Mitotic count:

Mitotic index was determined by counting mitotic figures in 30 random high power fields (1 hpf = 0.159 mm^2) in H&E stained sections of tumours following method of Yu *et al.* (21). Areas of tumour section having highly cellular activity were selected to count mitotic figures.

AgNOR count:

After histopathological examination, the sections showing characteristic features of a tumour type were utilized for AgNOR staining following the method described by Crocker *et al.* (3) with suitable modifications. All the AgNOR dots in nuclei were counted without trying to resolve the intranucleolar dots. AgNORs in 100 consecutive nuclei were counted and mean number of AgNOR dots per nucleus was calculated for each tumour.

Results and Discussion

Histopathological examination confirmed 65 out of 74 cases as mammary tumours and among them 11 (16.92%) were benign and 54 (83.08%) malignant tumours. Benign tumours found were benign mixed mammary tumour (4; 36.36%), fibroadenoma (3; 27.27%), duct papilloma (2; 18.18%) and simple adenoma (2; 18.18%). The malignant mammary tumours comprised majority of papillary adenocarcinoma (15; 27.78%) followed by malignant mixed mammary tumour (14; 25.92%), solid carcinomas (10; 18.52%), squamous cell carcinoma (3; 5.56%), fibrosarcoma (3; 5.56%), infiltrative adenocarcinoma (2; 3.7%), mucinous carcinoma (2; 3.7%) and one each case (1.54%) of osteochondrosarcoma, carcinosarcoma, myxosarcoma, intraductal carcinoma in situ and spindle cell carcinoma (malignant myoepithelioma).The age group at which mammary tumours occurred most frequently was 8-10 years (22 cases; 33.85%), followed by 6-8 years (19 cases; 29.23%), 10-12 years (14 cases; 21.54%), ≤6 years (6 cases; 9.23%) and >12 years (4 cases; 6.15%). Dorn *et al.* (6) and Moulton *et al.* (15) observed that mammary gland tumours occurred rarely in female dogs younger than 2 years of age and incidence increases after 5th year of the age with its peak at the age of 10 years and subsequent decrease after 12 years of age which corroborated the present findings of most tumour cases (45/65) being in 5-10 years.

Mitotic indices and AgNOR counts were significantly higher in the malignant tumours than benign (Table-1). The counts of mitotic figures has been used in histological grading of the tumours. Generally, mitotic figures are rarely seen in benign tumours in contrast to their malignant counterparts. In the present study, among malignant mammary tumours mitotic index ranged from 1.08 to 4.19 per high power field (hpf), with solid carcinoma showing the highest index (4.197±1.570) and osteochondrosarcoma the lowest (1.08±0.0). In benign mammary tumours, mitotic index ranged from 0.63 to 0.9 per hpf. The higher mitotic count in malignant tumours indicated more number of proliferating cells in M-phase of cell division than the benign.

The AgNOR count was considered to be a highly reliable histochemical marker for cell proliferation as well as in diagnostic and prognostic aid (8, 10). In the present study, AgNOR counts per nuclei were significantly ($P<0.05$) lower in benign mammary tumours (2.57±0.68) than malignant (3.38±1.01), which conformed to the earlier similar observations (2, 5, 16). Myxosarcoma (6.15±0.0) had highest AgNOR count followed by mucinous carcinoma (5.43±0.33), carcinosarcoma (4.92±0.0), spindle cell carcinoma (malignant myoepithelioma) (4.75±0.0), solid carcinomas (4.21±0.87), squamous cell carcinoma (3.71±0.73), malignant mixed mammary tumour (3.45±0.87), osteochondrosarcoma (3.32±0.0), infiltrative adenocarcinoma (3.14±0.03), fibrosarcoma (3.0±0.13), papillary adenocarcinoma (2.89±0.61), and intraductal carcinoma in situ (2.42±0.0). Among benign tumours, highest count was observed in adenoma (3.38±0.37) followed by benign mixed (2.75±0.89), fibroadenoma (2.18±0.27) and lowest in papillary adenoma (2.09±0.07).The higher AgNOR count in malignant tumours could be attributed to high concentration of interphase AgNOR proteins synthesized in rapidly proliferating cells (3, 19). Therefore it was concluded that mitotic index and AgNOR count are significantly ($P<0.05$) higher in the malignant tumours than benign mammary tumours and can be related with the malignant nature of the canine mammary tumours.

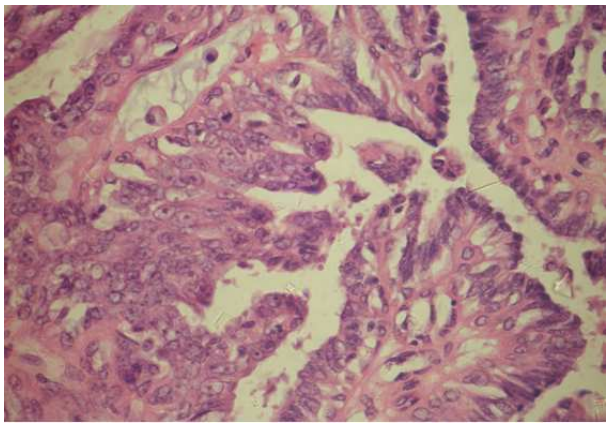

Fig.1 Papillary adenocarcinoma- Proliferating neoplastic epithelial cells in the form of papillary projections and presence of mitotic figures. H&E × 400

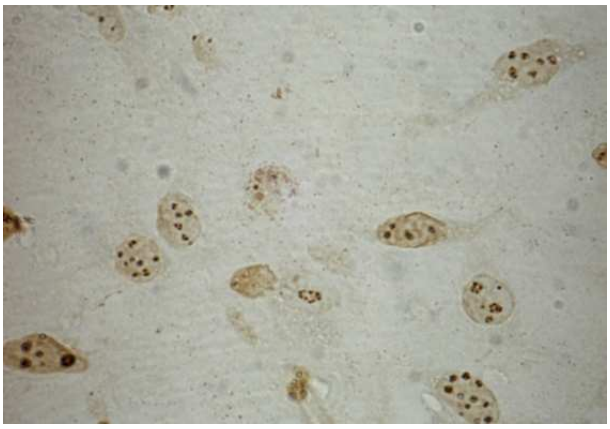

Fig.4 Myxosarcoma- Tumour cell showing numerous fine AgNOR dots dispersed in the nuclei. AgNOR × 1000

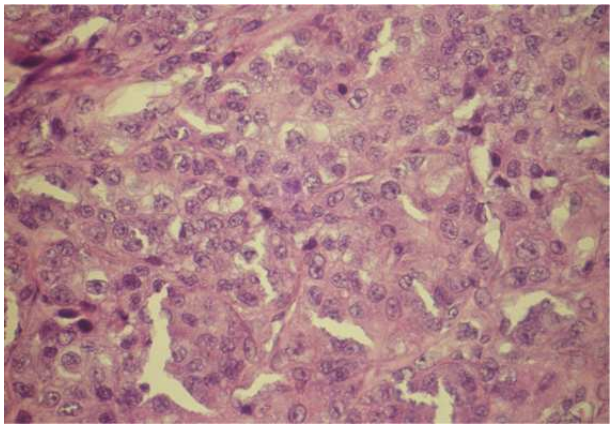

Fig.2 Solid carcinoma- Atypical neoplastic cells with hyperchromatic nuclei showing mitotic figures H&E×1000

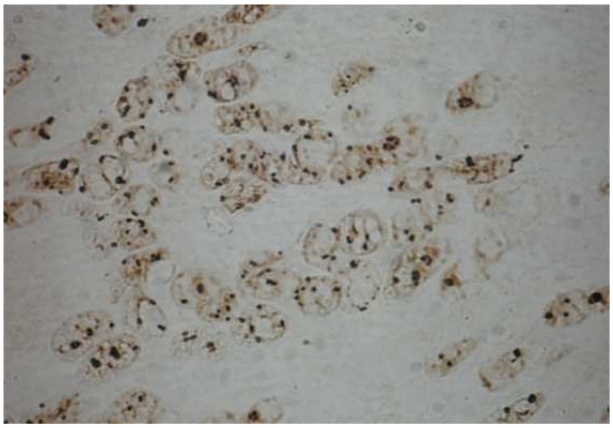

Fig.5 Intrductal carcinoma- Neoplastic cells containing several fine AgNOR dots. AgNOR × 1000

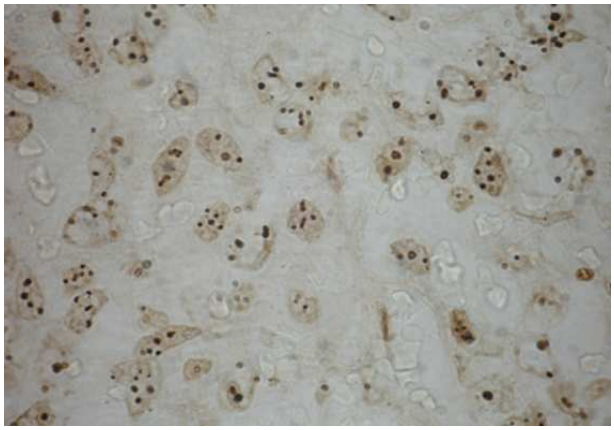

Fig.3 Solid carcinoma- Numerous AgNOR dots scattered throughout the nuclei of neoplastic cell. AgNOR×1000

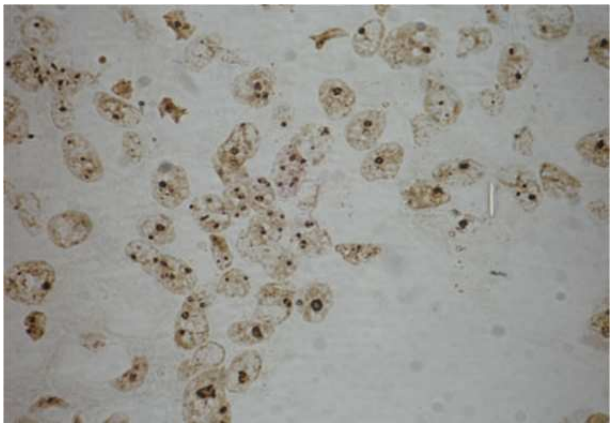

Fig.6 Mucinous carcinoma-Neoplastic cells showing several AgNOR dots scattered throughout the nuclei. AgNOR × 1000

Brazilian Journal of Veterinary Pathology. www.bjvp.org.br . All rights reserved 2007.

Table 1: Mitotic index and AgNOR counts in spontaneous canine mammary tumours (Mean value ± Standard deviation)

TYPE OF TUMOUR	MITOTIC INDEX (per high power field = 0.159 mm^2)	AgNOR COUNTS (dots/nuclei)
BENIGN TUMOURS		
Adenoma	0.90±0.08	3.38±0.37
Papillary adenoma	0.81±0.18	2.09±0.07
Fibroadenoma	0.63±0.28	2.18±0.27
Benign mixed mammary tumour	0.84±0.31	2.75±0.89
MALIGNANT TUMOURS		
Papillary adenocarcinoma	2.374±0.51	2.89±0.61
Solid carcinoma	4.197±1.57	4.21±0.87
Squamous cell carcinoma	2.40±0.29	3.71±0.73
Mucinous carcinoma	2.61± 0.76	5.43±0.33
Infilterative adenocarcinoma	1.965±0.22	3.14±0.03
Intraductal carcinoma in situ	1.89±0.0	2.42±0.0
Malignant myoepithelioma	2.95±0.0	4.75±0.0
Fibrosarcoma	1.68±0.06	3.0±0.13
Myxosarcoma	3.14±0.0	6.15±0.0
Osteochondrosarcoma	1.08±0.0	3.32±0.0
Carcinosarcoma	1.98±0.0	4.92±0.0
Malignant mixed mammary tumour	2.27±0.39	3.45±0.87

Acknowledgements

The authors are thankful to the Director of the Institute and Head of the Division for providing facilities to carry out the work and first author is grateful to the ICAR for providing Junior Research Fellowship during the course of study.

References

1. BEDROSSIAN CW. Cytopathology in Di-Cy's life time. Diagn. Cytopathol., 1993, 9(1), 1–2.
2. BOSTOCK DE., MORIARTY J., CROCKER, J. Correlation between histologic diagnosis, mean nucleolar organizer region count and prognosis in canine mammary tumors. Vet. Pathol., 1992, 29, 381-385.
3. CROCKER J., BOLDY DAR., EGAN MJ. How should we count AgNORs? Proposals for a standardized approach. J. Pathol., 1989, 158,185-188.
4. CROCKER J., NAR P. Nucleolar organizer regions in lymphomas. J. Pathol., 1987, 151, 111-118.
5. DESTEXHE E., VANMANSHOVEN P., COIGNOUL F. Comparison of argyrophillic nucelolar regions by counting and image analysis in canine mammary tumors. J. Comp. Pathol., 1995, 133(3), 185-187.
6. DORN CR., TAYLOR D., SCHNEIDER R., HIBBARD HH., KLAUBER MR. Survey of animal neoplasms in Almeda and Condra Costa, California. J. Nat. Cancer Inst., 1968, 40,296-305.
7. EGAN MJ., CROCKER J. Review: Nucleolar organizer regions in pathology. Brit. J. Cancer, 1992, 65,1-7.
8. GIRI DD., NOTTINGHAM JF., LAWRY J., DUNDAS SAC., UNDERWOOD JCE. Silver-binding nucleolar organizer regions (AgNORs) in benign and malignant breast lesions: correlations

with ploidy and growth phase by DNA flow cytometry. J. Pathol., 1989, 157, 307-13.

9. GOLDSCHMIDT MH., SHOFER FS., SMELSTOYS JE. Neoplastic lesions of mammary gland. In: Pathobiology of aging dogs, ed. MOHR U., CARLTON WW., DUNGWORTH DL., BENJAMIN SA., CAPEN CC., HAHN F.F. 1st ed., ISU Press/ILSI, Ames, IA, 2001:168-178.
10. KIUPEL M., BOSTOCK DE., BERGMANN RL. A semiquantitative method for the evaluation of AgNORs in canine malignant lymphomas. Eur. J. Vet. Pathol., 1998, 4, 67-71.
11. LOHR CV., TEIFKE J., FAILING K., WEISS E. Characterization of the proliferation state in canine mammary tumors by the standardized AgNOR method with postfixation and immunohistologic detection of Ki-67 and PCNA. Vet. Pathol., 1997, 34, 212-221.
12. LUNA LG. Manual of histologic staining methods of the Armed Forces Institute of Pathology, 3rd ed. W.B. Saunders, Philadelphia, 1972.
13. MACEWEN EG., WITHROW S.J. Soft tissue sarcomas. In : Small animal clinical oncology. 2nd edition, W.B. Saunders Company, Philadelphia, 1996: 211-226.
14. MISDORP W. Tumours of mammary gland. In: Tumours in domestic animals, ed. Meuten DJ, 4th ed., Iowa State Press, Ames, IA, 2002: 575-606.
15. MOULTON JE., TAYLOR D., DORN CR., ANDERSON A. Canine mammary tumours. Vet. Pathol., 1970, 7, 289-320.
16. PAWAIYA RVS. Pathology of chemically induced neoplasms and evaluation of molecular markers in diagnosis of animal tumors. Indian J. Vet. Pathol., 2005, 29(1), 63.003.
17. REDDY GBM. Pathology and evaluation of tumour markers in spontaneous canine skin and mammary tumours. M.V.Sc. Thesis submitted to Indian Veterinary Research Institute, Izatnagar, 2007.
18. SHEKHAR CS., VIJAYSARATHI SK., GOWDA RNS., SUGUUNA R., RAO, S. An epidemiology study on canine mammary tumors. Indian Vet. J., 2001, 78(2),107-109.
19. TRERE D. AgNOR staining and quantification. Micron, 2000, 31, 127-131.
20. VAIL DM., MACEWEN, EG. Spontaneously occurring tumours of companion animals as models for human cancer. Cancer Invest., 2000, 18: 781-792.
21. YU CCW., FLETCHER CDM., NEWMANN PL. GOODLAND JR., BURTON JC, LEVISON. DA. A comparison of proliferating cell nuclear antigen (PCNA) immunostaining, nucleolar organizer region (AgNOR) staining, and histological grading in gastrointestinal stromal tumors. J. Pathol., 1992, 166, 147-15.

 All rights reserved 2007.