Braz J Vet Pathol, 2025, vol. 18, Suppl. 1, e018S105
DOI: https://doi.org/10.24070/bjvp.1983-0246.018S105

BJVP
Brazilian Journal of Veterinary Pathology
ISSN 1983-0246

Diagnostic Exercise
From the Latin Comparative Pathology Group and the Davis-Thompson Foundation

Granulomatous disease associated with *Halicephalobus* sp. in a horse

João Paulo da Silva Cavasani[1], Wuglenya Daislla Martins da Silva[1], Lucas Avelino Dandolini Pavelegini[1], Edson Moleta Colodel[1], Fernando Henrique Furlan[1]*

[1]Veterinary Pathology Laboratory, Veterinary Hospital, Federal University of Mato Grosso, Brazil.

Corresponding author: fernando.furlan@ufmt.br

History:

An 18-year-old English thoroughbred gelding was evaluated because of incoordination, circling, and head pressing. The horse died 5 days after the clinical signs started.

Necropsy findings:

Small, pinpoint red areas in the cerebellopontine region and in the medulla oblongata (Fig. 1). In the myocardium there were firm, yellow nodules (1-3 cm diameter) (Fig. 2). Samples of the heart (Figs. 3 and 4) and medulla oblongata (Figs. 5 and 6) were collected for histology.

Follow-up questions:

- *Morphologic diagnosis:*
- *Etiology:*
- *Name the disease:*

ANSWERS

Histologic description:

Heart and CNS: There were areas of extensive granulomatous inflammation interspersed with large amounts of fibrous connective tissue. The inflammation was composed of numerous epithelioid macrophages and multinucleated giant cells

*The Diagnostic Exercises are an initiative of the Latin Comparative Pathology Group (LCPG), the Latin American subdivision of The Davis-Thompson Foundation and published in cooperation with the Brazilian Journal of Veterinary Pathology. These exercises are contributed by members and non-members from any country of residence. Consider submitting an exercise! A final document containing this material with answers and a brief discussion will be posted on the CL Davis website: https://davisthompsonfoundation.org/diagnostic-exercise/

Editor-in-chief for this Diagnostic Exercise: *Claudio Barros*
Associate Editor for this Diagnostic Exercise: *Saulo Pavarini*

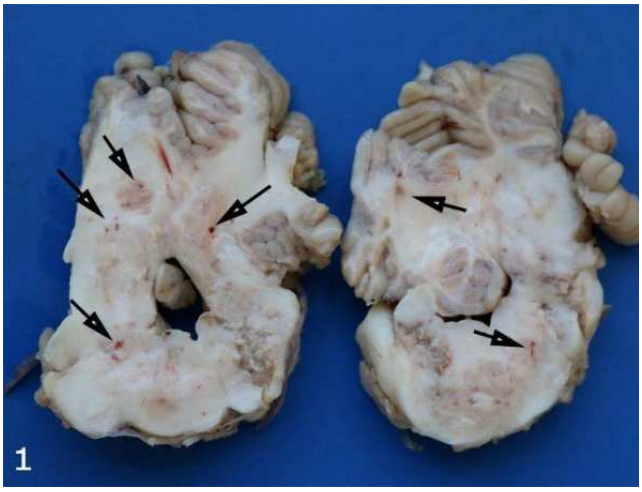

Figure 1. Cerebellum and medulla oblongata, horse. Small, pinpoint red areas in the white matter (arrows).



Figure 2. Heart, horse. Irregular, yellow area in the myocardium (arrows).

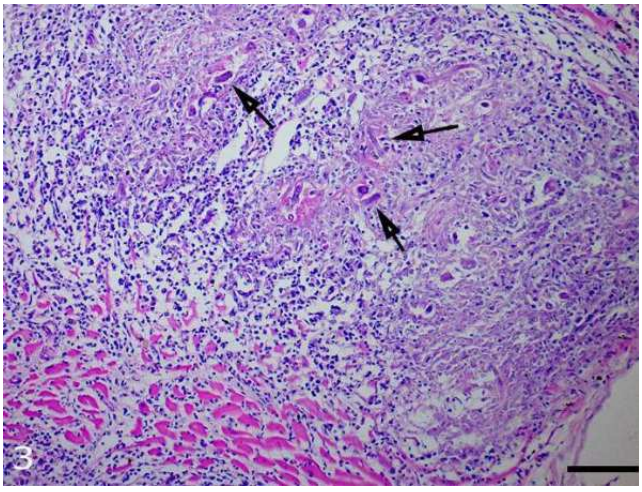

Figure 3. Heart, horse. Extensive granulomatous inflammation surrounds sections of nematode eggs, larvae, and adults (arrows).

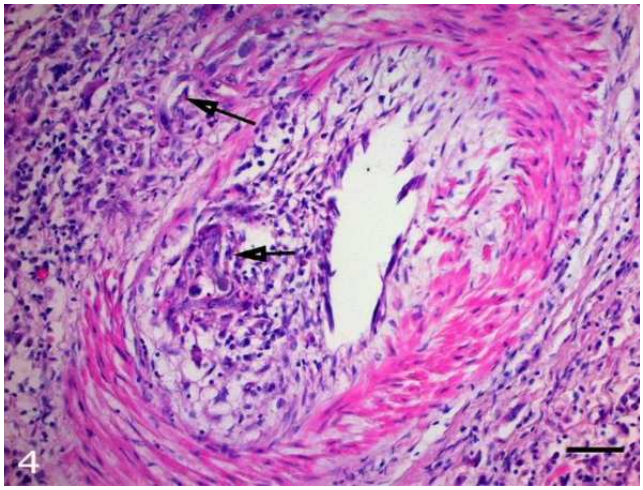

Figure 4. Heart vessel, horse. Granulomatous inflammation surrounds sections of nematode larvae and adults along the tunica intima, media, and adventitia.

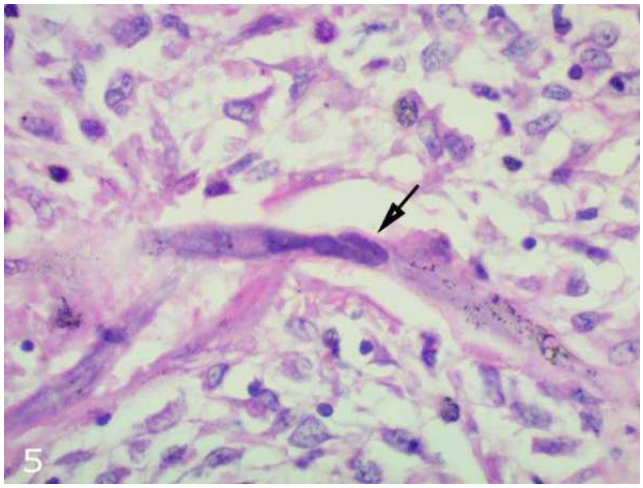

Figure 5. Cerebellum, horse. Adult nematodes with an uterus containing a dorsiflexed ovary (arrow).

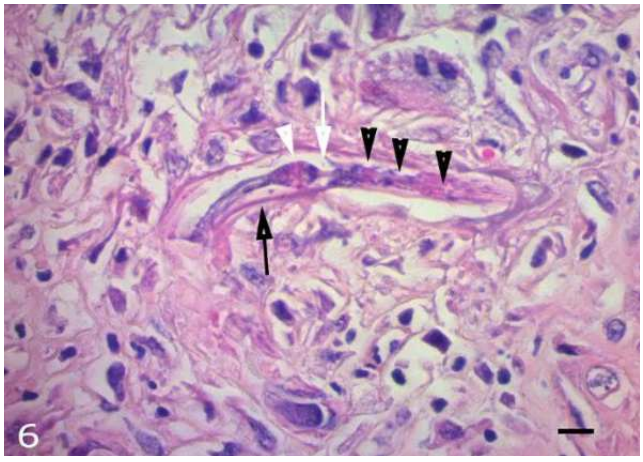

Figure 6. Cerebellum, horse. Adult nematodes have a smooth cuticle (black arrow) and rhabditiform esophagus composed of a corpus (black arrowhead), isthmus (white arrow), and terminal bulb (white arrowhead).

Braz J Vet Pathol, 2025, vol. 18, Suppl. 1, e018S105
DOI: https://doi.org/10.24070/bjvp.1983-0246.018S105

surrounding transverse and cross sections of nematodes eggs, larvae, and adults (Fig 3). Inflammatory cells also surrounded and infiltrated vessel walls (fig. 4). The nematodes had a uterus containing a dorsiflexed ovary (Fig 5), a smooth cuticle, platymyarian-meromyarian musculature, and a rhabditiform esophagus with a distinct corpus, isthmus, and terminal bulb (Fig. 6).

Morphologic diagnosis:

1. Granulomatous myocarditis, focally extensive, chronic with nematodes and nematode eggs.
2. Granulomatous encephalitis, multifocal, chronic with nematodes and nematode eggs.
3. Granulomatous vasculitis, transmural, multifocal, chronic with nematodes and nematode eggs.

Etiology:

Halicephalobus gingivalis

Comments:

Aberrant migration of helminth and fly larvae through the CNS of horses and donkeys is a rare but important cause of severe neurologic disease. Parasites that have been reported to affect the brain and spinal cord of horses include nematodes *(Halicephalobus gingivalis, Strongylus vulgaris, S. equinus, Angiostrongylus cantonensis, Parelaphostrongylus tenuis, Elaphostrongylus panticolam E. rangifera, Draschia megastoma, Setaria digitata*, and other *Setaria* spp.), cestodas (*Coenurus cerebralis*), and warble fly larvae (*Hypoderma* spp.) (2,6). Halicephalobiasis is a helminthic infection caused by *H. gingivalis* that has a worldwide distribution with the majority of cases in horses and humans. The genus *Halicephalobus* is classified in the order Rhabditida, which includes free-living saprophytic nematodes found in soil and decaying organic matter. There are eight members of this genus: *H. limuli; H. similigaster; H. minutum; H. parvum; H. palmaris; H. intermedia; and H. laticauda* and *H. gingivalis.* The latter, under certain circumstances, may become an opportunistic parasite capable of causing infections that affects horses, donkeys, zebras, cattle, and humans (6).

In the past, knowledge about the *Halicephalobus* spp. infection in horses was limited due to the low number of reported cases and presumably because infection is rarely diagnosed antemortem. However, the growing number of reported cases in the recent years has created a clearer picture of the route of infection and the distribution pattern of nematodes in horses. It remains speculative as to how *H. gingivalis* enters the host; however, several studies suggest that penetration of mucosal membranes or skin is the most likely portal of entry. Horses likely acquire *H. gingivalis* by the oral route, most probably by the uptake of free-living female adult or larval stages found on plant material. Once in the gastrointestinal tract, organisms spread hematogenously to various organs. The clinical signs associated with *H. gingivalis* infection depend on the localization and severity of the lesions. The most affected organs are the brain, spinal cord, and nerves. Horses with neurological signs have a rapid and progressive neurological deterioration (5,6,8). Heart lesions, like we observed in this case, are uncommon (3,7). A definitive clinical diagnosis of halicephalobosis is difficult to confirm in the absence of accessible granulomatous lesions for biopsies and morphologic identification of nematodes by histology. The migration of the nematodes through the tissue causes proliferative, firm, grey-white granulomatous lesions in parenchymatous organs or thickened and nodular lesions in the skin. The histologic findings include replacement of normal tissue architecture by dense collagen and fibroblasts with infiltration by lymphocytes, plasma cells, epithelioid macrophages, multinucleated giant cells, eosinophils, and nematodes or nematode eggs (6,8). The parasite has a smooth, thin cuticle; a platymyarian-meromyarian musculature; a pseudocoelom; a rhabditiform esophagus composed of a corpus, isthmus, and bulb; and an intestinal tract composed of single nucleated low cuboidal cells. There is a single genital tube containing only one mature egg. The ovary is dorsiflexed, and the uterus is ventroflexed at the vulva. Larvae are around 10 µm in diameter and have rhabditiform esophagi. Adults and larvae have slender tails that tapered to a point. The eggs are oval, and average size is 15 x 35 µm in diameter. The rhabditiform esophagus, flexion of the ovary and uterus, and tapered tail are morphologic features used to identify the parasite as a member of the genus *Halicephalobus.* Other nematodes (e.g., *Strongyloides* or *Cephalobus* spp.*)* have rhabditiform esophagi, but only *Halicephalobus* has a reflexed ovary and a pointed tail (1,4).

References:

1. Anderson RC, Linder KE, Peregrine AS. *Halicephalobus gingivalis* (Stefanski, 1954) from a fatal infection in a horse in Ontario, Canada with comments on the validity of *H. deletrix* and a review of the genus. Parasite. 1998 5(3):255-61.
2. Cantile C, Youssef S. Nervous system. In: Maxie, MG. Ed. Jubb, Kennedy and Palmer's pathology of domestic animals. 6th ed. St. Louis, Missouri: Elsevier; 2016; v.1:250-406.
3. Cunha BM, França T do N, Miranda IC, Santos AM, Seixas JN, Pires AP, et al. Granulomatous myocarditis in a horse by *Halicephalobus gingivalis* (*H. deletrix*) - Case report. Braz. J. Vet. Med. 2016 38(Supl.2):113-6.

4. Dunn DG, Gardiner CH, Dralle KR, Thilsted JP. Nodular granulomatous posthitis caused by Halicephalobus (syn. Micronema) sp. in a horse. Vet Pathol. 1993 30(2):207-8.
5. Henneke C, Jespersen A, Jacobsen S, Nielsen MK, McEvoy F, Jensen HE. The distribution pattern of *Halicephalobus gingivalis* in a horse is suggestive of a haematogenous spread of the nematode. Acta Vet Scand. 2014 19;56(1):56.
6. Hermosilla C, Coumbe KM, Habershon-Butcher J, Schöniger S. Fatal equine meningoencephalitis in the United Kingdom caused by the panagrolaimid nematode *Halicephalobus gingivalis*: case report and review of the literature. Equine Vet J. 2011 43(6):759-63.
7. Lepri E, Beccati F, Miglio A, Passamonti F, Veronesi F, Mandara MT. Pathology in Practice. J Am Vet Med Assoc. 2017 15;251(10):1153-1156.
8. Onyiche TE, Okute TO, Oseni OS, Okoro DO, Biu AA, Mbaya AW. Parasitic and zoonotic meningoencephalitis in humans and equids: Current knowledge and the role of Halicephalobus gingivalis. Parasite Epidemiol Control. 2017 29;3(1):36-42.