Braz J Vet Pathol, 2025, vol. 18, Suppl. 1, e018S106
DOI: https://doi.org/10.24070/bjvp.1983-0246.018S106

BJVP
Brazilian Journal of Veterinary Pathology
ISSN 1983-0246

Diagnostic Exercise
From the Latin Comparative Pathology Group and the Davis-Thompson Foundation

Gastric pythiosis in a dog

Yanca G.S. Soares[1], Laynaslan A. Soares[1], Glauco J.N. Galiza[1], Franklin Riet-Correa[1].
Laboratório de Patologia Animal, Universidade Federal de Campina Grande (UFCG), Patos, PB, Brazil.

***Corresponding author:** yancagoes@hotmail.com

Clinical history:

A 10-month-old dog with a history of vomiting with blood and diarrhea after ingesting plastic bags. An ultrasound examination revealed peritonitis and multiple gastric ulcers. The dog was referred for surgery. During the surgical procedure, extensive ulcers were observed in the stomach mucosa. A gastrectomy of the affected region was performed. The dog didn't recover from the surgical procedure.

Necropsy findings:

The mucous membranes had noticeable pallor, and the body condition was cachectic. A surgical suture wound measuring approximately 20 cm was present in the ventral region of the abdomen. Upon opening the abdominal cavity, a moderate amount of reddish fluid was observed, along with a diffusely reddish omentum. The serosa of the stomach appeared diffusely thickened, exhibiting a focally extensive and well-defined greenish-yellow, friable area lined with fibrin, extending from the body region to the pyloric antrum (Fig. 1A). A surgical wound sutured with nylon thread was noted around this area. The adjacent serosa displayed reddish multifocal areas. The stomach mucosa was diffusely reddened and thickened, with a loss of the gastric folds. In the body and pyloric antrum regions, a focally extensive, well-defined grayish to blackish, friable area was observed, corresponding to the area of the surgical wound (Fig. 1B). The stomach wall was diffusely thickened and firm, featuring whitish strictures interspersed with multifocal yellowish nodules extending from the mucosa to the muscular layer (Fig. 2). Cytological examination revealed numerous septate and branched tubular structures with parallel walls among the inflammatory cells (Fig. 2, inset). The hepatogastric lymph nodes were enlarged.

**The Diagnostic Exercises are an initiative of the Latin Comparative Pathology Group (LCPG), the Latin American subdivision of The Davis-Thompson Foundation (DTF). These exercises are contributed by members and non-members from any country of residence. Consider submitting an exercise! A final document containing this material with answers and a brief discussion will be posted on the DTF website: https://davisthompsonfoundation.org/diagnostic-exercise/*

Editor-in-chief for this Diagnostic Exercise: *Claudio Barros*
Associate Editor for this Diagnostic Exercise: *Saulo Pavarini*

Braz J Vet Pathol, 2025, vol. 18, Suppl. 1, e018S106
DOI: https://doi.org/10.24070/bjvp.1983-0246.018S106

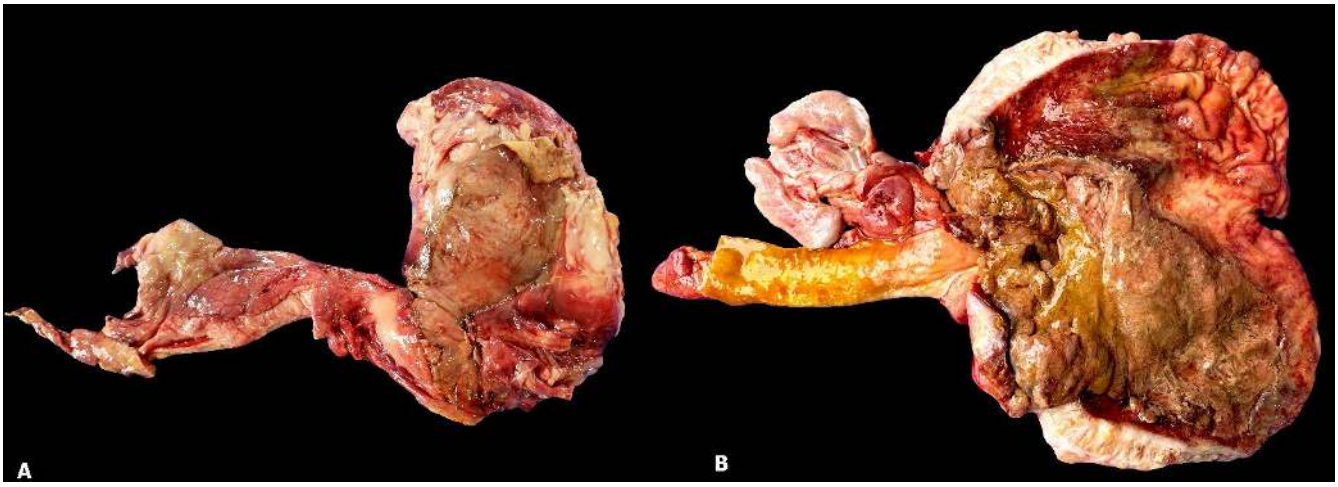

Figure 1. Canine, Stomach. **A.** The serosa has focal extensive and well-delimited green-yellow and friable area lined with fibrin that extends from the region of the body to the pyloric antrum; this area is associated with the sutured surgical wound. **B.** The mucosa is diffusely reddish and thicken with effacement of the gastric folds. Focally extensive, irregular, friable and grayish to blackish area on the body and pyloric antrum.

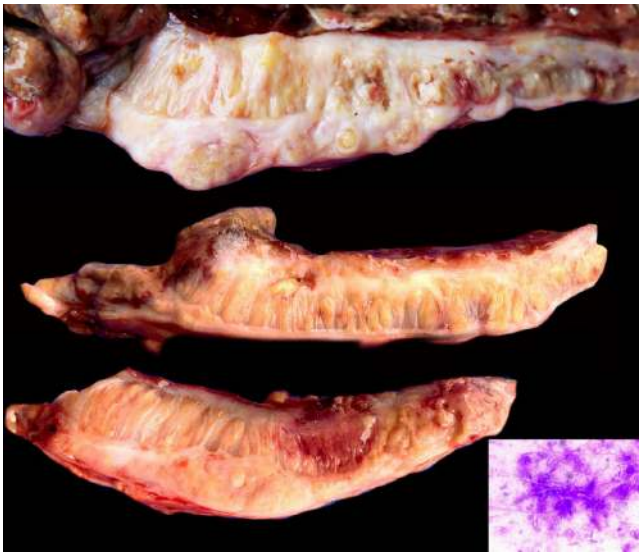

Figure 2. Canine, Stomach, traverse sections. The gastric wall is diffusely thickened with a whitish and irregular surface containing yellow nodular areas. *Inset*: an imprint of the gastric walls showing unstained tubular images on Fast Panoptic.

Follow-up questions:

- *Histologic description*
- *Morphologic diagnosis*
- *Name the disease*
- *Differential diagnoses*

ANSWERS

Histologic Description:

In the stomach, multiple pyogranulomas were observed, characterized by an inflammatory infiltrate consisting of neutrophils, eosinophils, macrophages, plasma cells, lymphocytes, epithelioid macrophages, and multinucleated giant cells, all surrounded by fibrous connective tissue (Figs. 3 and 4A). This infiltrate extended into the muscular layer of the mucosa. Amidst the inflammatory infiltrate and areas of necrosis, tubular structures were observed in transverse and longitudinal sections. These structures were unstained, non-septate, and sometimes exhibited parallel walls with rare irregular branches (Fig. 4B). The tubular formations were compatible with hyphae, measuring approximately 5 to 8 μm in diameter. Hyphae were also identified within the cytoplasm of multinucleated giant cells (Fig. 4B, *inset*). In PAS, hyphae were stained pink (Fig. 4C), while in GMS staining, they were strongly stained black, showing non-parallel walls and infrequent branching (Fig. 4D). Additionally, a mixed inflammatory infiltrate associated with thrombus and unstained tubular images was observed in the walls of some blood vessels (a change not evident in the images).

Immunohistochemically, the hyphae showed strong immunostaining with an anti-*Pythium insidiosum* antibody (Fig. 4D, *inset*).

Morphologic diagnosis:

Stomach, gastritis pyogranulomatous eosinophilic and fibrosing, focally extensive, transmural, marked, associated with hyphae of *Pythium insidiosum*.

Braz J Vet Pathol, 2025, vol. 18, Suppl. 1, e018S106
DOI: https://doi.org/10.24070/bjvp.1983-0246.018S106

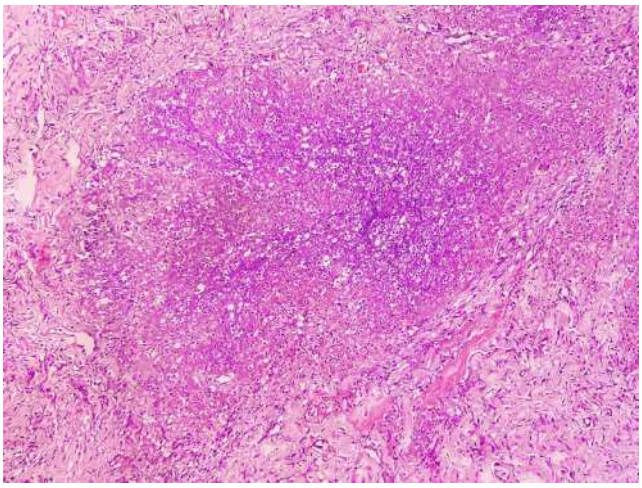

Figure 3. Canine, Stomach with pyogranuloma characterized by a central area of necrosis surrounded by mixed inflammatory infiltrate. Pyogranulomas extend from the mucosa to the muscular layer. H&E. Obj. 10x.

Name of the disease:

Pythiosis

Differential diagnoses:

Gastric neoplasms: adenocarcinoma, alimentary lymphoma and leiomyosarcoma.

Infections caused by *Lagenidium* spp.

Gastric zygomycosis and aspergillosis.

Comments:

Pythiosis is a chronic pyogranulomatous disease caused by the aquatic oomycete *Pythium insidiosum*, a protist member of the class Oomycetes, which is evolutionarily more closely related to algae than to true fungi (6).

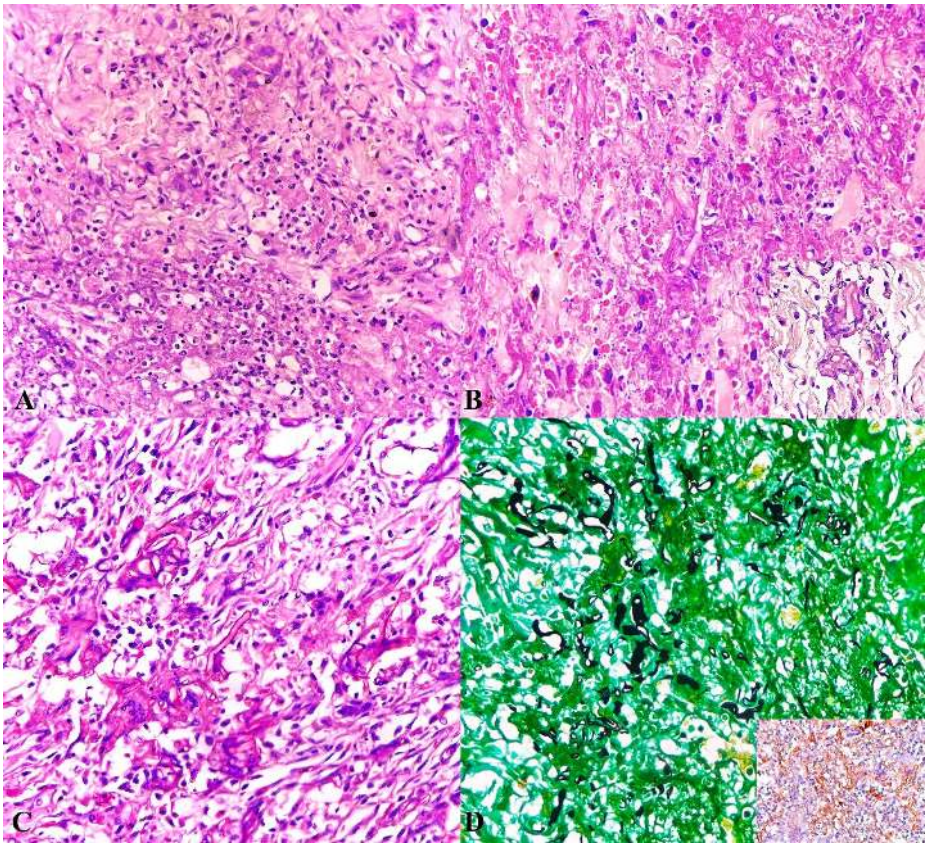

Figure 4. Canine, Stomach: **A** and **B.** Pyogranulomas are characterized by an inflammatory infiltrate composed of neutrophils, eosinophils, macrophages, plasma cells, lymphocytes, epithelioid macrophages and multinucleated giant cells surrounded by fibrous connective tissue. In the middle of the areas of necrosis, tubular structures can be observed in transverse and longitudinal sections. H&E Obj. 40x. *Inset*: hyphae were identified within the cytoplasm of multinucleated giant cells. **C.** In PAS, hyphae were stained pink. Periodic acid-Schiff (PAS) Obj. 40x. **D.** In GMS, the hyphae were strongly stained black, showing non-parallel walls and infrequent branching. Grocott methenamine silver (GMS). Obj. 40x. *Inset*: strongly immunostaining hyphae with an anti-*Pythium insidiosum* antibody, DAB.

Braz J Vet Pathol, 2025, vol. 18, Suppl. 1, e018S106
DOI: https://doi.org/10.24070/bjvp.1983-0246.018S106

The disease has a worldwide distribution, mainly in swampy areas of tropical, subtropical and temperate regions (6). In South America, Brazil has a high incidence of pythiosis in animals, being considered an endemic disease in the Northeast region, affecting different species such as horses, sheep, dogs, mules, cattle, cats, goats, donkeys and ostriches (10).

In dogs, the disease occurs mainly with changes in the gastrointestinal tract, characterized by transmural thickening of the esophagus, stomach or intestines (small or large) resulting in the formation of expansive masses that can compress and cause adhesions with adjacent organs (9). In cases involving the stomach, it is believed that pre-existing gastric lesions and ingestion of water contaminated with *P. insidiosum* zoospores promote invasion of the submucosal layer and colonization with progressive development of the mass (3). The cutaneous form in dogs is characterized by ulcerated wounds that do not heal, mainly affecting the chest, abdomen, limbs and external genitalia. The main clinical signs observed in gastric pythiosis in dogs include weight loss, vomiting, diarrhea, hematochezia, abdominal pain and tenesmus (5).

In a case of esophageal and gastric pythiosis, the walls of the distal segment of the esophagus, cardia and fundus of the stomach were markedly thickened by an irregular, firm and reddish intramural annular mass with hemorrhage and transmural esophageal fistula. Furthermore, the mediastinal and gastric lymph nodes were markedly enlarged and firm, sometimes containing irregular, whitish masses on the cut surface (9). In cases involving other portions of the gastrointestinal tract, irregular and firm nodular thickenings are observed, mainly affecting the intestine, pancreas and lymph nodes. When cut, these thickenings are characterized by multifocal to coalescent yellowish, granular and irregular areas surrounded by whitish, smooth and shiny tissue, interspersed with brownish areas (5).

Microscopically, the lesions are characterized by granulomatous or pyogranulomatous and eosinophilic inflammatory infiltrate with areas of necrosis surrounded by reactive fibroblasts, abundant collagen matrix and neovascularization (9). In areas of necrosis, numerous tubular images are observed, sometimes with weakly basophilic walls (10). Special histochemical techniques can be employed to aid visualization of the hyphae, such as Grocott methenamine silver (GMS), in which the hyphae are heavily impregnated with black, and Periodic acid-Schiff (PAS) in which the hyphae do not stain or they have a discreet pink color on the wall (5). As well as other diagnostic means, such as immunohistochemistry, cultivation of the agent and molecular tests can be used (10). Techniques such as imprinting the cut surface of lesions suggestive of pythiosis in dogs can be stained by Fast Panoptic to visualize the agent. Just as direct examination with 10% potassium hydroxide of lesions allows the identification of tubular structures with parallel walls and branches.

The prognosis and treatment of pythiosis is reserved and challenging, and successful therapy depends on the extent and location of the lesion, since when early diagnosis is made, therapy can be successful with a combination of itraconazole and terbinafine, which has shown satisfactory results. during the 12 months of administration and immunotherapy for 2.5 months (7).

Macroscopically, the differential diagnoses associated with transmural thickening of the stomach are adenocarcinomas, lymphomas and leiomyosarcomas (2, 4, 8). Microscopically, infections by other oomycetes, such as *Lagenidium* spp., or Entomophthorales and Mucorales fungi, should be considered as differential diagnoses due to the similarity of the inflammatory response and morphological and staining characteristics of the agents (1).

References:

1. Alves RC, Ferreira JS, Alves AS, Maia LA, Dutra V, Souza AP, Galiza GJN, Dantas AFM. Systemic and gastrohepatic mucormycosis in dogs. J Comp Pathol 2020;75:90-94.
2. Favero SL, Thomé S, Cesca PH, Bialoso ODO. Linfoma Alimentar Canino–Relato de caso. Vet Zootec 2022;29:001-008.
3. Fernandes CP, Giordani C, Grecco FB, Sallis ESV, Stainki DR, Gaspar LFJ, Ribeiro CLG, Nobre MO. Gastric pythiosis in a dog. Rev Iberoam Micol 2012;29:235–237.
4. Fonda D, Gualtieri M, Scanziani E. Gastric carcinoma in the dog: A clinicopathological-Study of 11 cases. J Small Anim Pract 1989;30:353–360.
5. Frade MT, Diniz PV, Olinda RG, Maia LA, Galiza GJN, Souza AP, Nobrega Neto PI, Dantas AFM. Pythiosis in dogs in the semiarid region of Northeast Brazil. Pesq Vet Bras 2017;37:485-490.
6. Gaastra W, Lipman LJA, Cock AWAM, Exel TK, Pegge RBG, Scheurwater J, Vilela R, Mendoza L. *Pythium insidiosum*: an overview. Vet Microbiol 2010;146:1-16.
7. Pereira DIB, Botton SA, Azevedo MI, Motta MA, Lobo RR, Soares MP, Fonseca AOS, Jesus FPK, Alves SH, Santurio JM. Canine gastrointestinal pythiosis treatment by combined antifungal and immunotherapy and review of published studies. Mycopathologia 2013;176:309-315.
8. Prado LOC, Franco GG, Legatti E, Ranzani JJT, Quitzan JG, Siqueira EGM, Souza JAL, Minto BW, Brandão CVS. Leiomiossarcoma gástrico associado a hérnia de hiato em cão da raça Shar-pei: relato de caso. Arq Bras Med Vet Zootec 2017;69:111–116.
9. Silva EMS, Martins KPF, Pereira AHB, Gris AH, Maruyama FH, Nakazato L, Colodel EM, Oliveira LGS, Boabaid FM. Esophageal and gastric pythiosis in a dog. Cienc Rural 2023;54:e20230272.
10. Souto EPF, Kommers GD, Souza AP, Neto EGM, Assis DM, Riet-Correa F., Galiza GJN, Dantas AFM. A retrospective study of pythiosis in domestic animals in Northeastern Brazil. J Comp Pathol 2022;195:34-50.