



Original Full Paper

Detection of *Helicobacter*-like organisms in Thoroughbred horses from Venezuela

Abelardo Morales B.¹, Francisco Garcia¹, Victor Bermudez¹

¹Department of Veterinary Pathology, Faculty of Veterinary Science
Central University of Venezuela Maracay, Aragua State - Venezuela.
Department of Veterinary Pathology, Faculty of Veterinary Science
Central University of Venezuela Maracay, Aragua State - Venezuela

Corresponding author: Abelardo Morales Briceño
Email: aamorales13@gmail.com

Submitted January 9th 2010, Accepted March 30th 2010

Abstract

The aim of this study was to detect the presence of *Helicobacter* infection in Thoroughbred in Venezuela. One hundred and thirty six Thoroughbreds with signs for Equine gastric ulcer syndrome (EGUS) were studied in the National Race Track La Rinconada Caracas Venezuela. Necropsies were performed in all horses and samples of gastric tissue were collected. The tissue samples were fixed in formalin and processed by conventional H&E techniques. Additionally, the special staining procedure of Warthin-Starry, Giemsa and Blue Toluidine were also carried out. Ureasa test: rapid ureasa test (commercial kit) was performing of gastric tissue. The damage of the gastric mucosae in the animals was categorized as 2/136 Grade 0 Epithelium is intact throughout; no hyperemia, no hyperkeratosis. Grade 1 Mucosa is intact but there are areas of hyperemia and/or hyperkeratosis 26/136. Grade 2 small, single or multi-focal erosions or ulcers 38/136. Grade 3 Large, single or multi-focal ulcers, or extensive erosions and sloughing 36/136. Grade 4 Extensive ulcers, with areas with deep submucosal damage 34/136. Using the Warthin-Starry special stain, Giemsa and Blue Toluidine with spiral-shaped bacteria were evidenced found in 52, Grade 1: 13/52, Grade 2: 10, Grade 3: 16, Grade 4: 13. There seemed to be no association between Warthin-Starry, Giemsa and Blue Toluidine stain with the grade and location of lesions. Urease activity was then demonstrated in fifty-two equine. To conclude, we detected the presence of *Helicobacter* Like Organisms in the gastric mucosa from thoroughbred horses with EGUS.

Key Words: *Helicobacter*, gastric ulcer, equine gastric ulcer syndrome, horse, Thoroughbred horse

Introduction

Equine gastric ulcer syndrome (EGUS) is characterized by ulceration in the terminal esophagus, proximal (squamous) stomach, distal (glandular) stomach, and proximal duodenum (2, 15). *Helicobacter* spp (other than *H. pylori*) have been isolated from humans and a variety of animals suffering from gastric ulcers and gastritis (6). Recently, a new enterohepatic *Helicobacter* species, *H. equorum*, was isolated from fecal samples of two clinically healthy horses.(4, 11) Also, *H. equorum* DNA was found in the feces of two of seven (28.6%) foals less than 1 month old and 40 of 59 (67.8%) foals 1 to 6 months old (12). Furthermore, *Helicobacter*-like DNA was detected in the stomach of 10 Thoroughbred horses in Venezuela.(2, 4, 10) In this study, DNA from *Helicobacter*-like species was detected in two of seven horses with gastric ulcers, three of five horses with gastritis, five of six horses

with both disorders, and one horse with normal gastric mucosa (2, 4). Furthermore, 10 of 11 of the horses infected with *Helicobacter* had either gastric ulcers or gastritis or both pathologies. However, 39% of the horses in this study did not have gastric lesions, so multiple causes are likely (15). The aim of this study was to detect the presence of *Helicobacter* infection in Thoroughbred in Venezuela.

Materials and Methods

A total of 136 Thoroughbred horses were studied in the National Race Track "La Rinconada" Caracas Venezuela during 2008-2009. All stomachs were examined by necropsy, grossly scored using a standard lesion classification (8). Approximately 1cm tissue samples from the cardiac, fundic and pyloric areas of the stomach were taken using a sterile blade for each stomach. For histological examination, samples

were fixed in 10% formalin, embedded in paraffin and cut to 5µm sections (1, 3). The slides were stained with Warthin-Starry stain using as control an equine gastric tissue infected with *Helicobacter* genus by PCR. Additionally the special staining procedure Giemsa and Blue Toluidine were also carried out (3, 10). Ureasa Test: the rapid ureasa tests (commercial kit) were performed for gastric tissue.

Results

Ninety nine per cent of horses (134/136) present gastric lesions. The damage of the gastric mucosa in the animals was categorized (table 1) as Grade 0 - epithelium is intact throughout, no hyperemia, no hyperkeratosis: 1,5% (2/136). Grade 1 - mucosa is intact but there are areas of hyperemia and/or

hyperkeratosis: 19% (26/136). Grade 2 - small, single or multi-focal erosions or ulcer: 28% (38/136). Grade 3 - large, single or multi-focal ulcers (Figure 1), or extensive erosions and sloughing: 26% (36/136). Grade 4 - extensive ulcers (Figure 2), with areas with deep submucosal damage: 25% 34/136. Bacteria observed in the gastric mucosa were morphologically similar to *Helicobacter* genus (HLO) around 7µm of length and spiral shaped, allocated mainly in the lumen of the gastric foveolas. A total of 38% (52/136) were positive in the Warthin-Starry special stain (Figures 3 and 4), Blue Toluidine (Figure 5) 36% (49/136) and Giemsa (Figure 6) 36% (49/136) (Table 1). Ninety-two horses had gastritis and gastric ulcers around the *margo plicatus*, Forty horses also presented lesion only in the glandular region. Urease activity only was demonstrated in 52 horses (Table 1).

Table 1. Results of detection of the genus *Helicobacter* of equine with gastric ulcer syndrome include score (classification of Merrit, 2003), macroscopic lesion, histology lesion, Warthin-Starry, Toluidine Blue, Giemsa and urease test.

Score Lesions EGUS (Merrit 2003)	Macroscopic lesion	Histology lesion	WS (+)	TB (+)	GIEMSA (+)	Urease Test (+)
Grade 0	2	2	0	0	0	0
Grade 1	26	26	13	13	12	13
Grade 2	38	38	10	10	10	10
Grade 3	36	36	16	15	15	16
Grade 4	34	34	13	11	12	13
Total	136	136	52	49	49	52

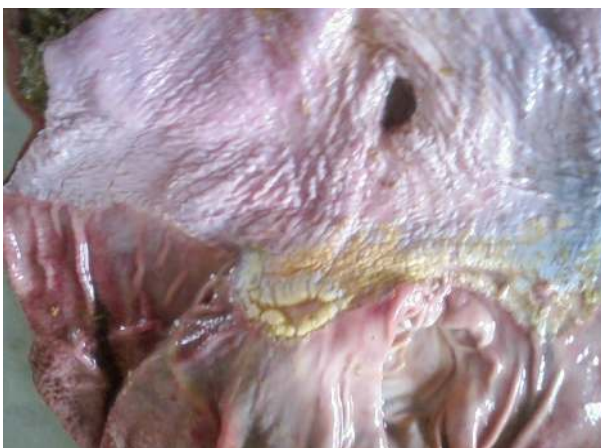

Figure 1. Gastric mucosa of horse with Equine Gastric ulcer syndrome Grade 3. Large, single or multi-focal ulcers, or extensive erosions.

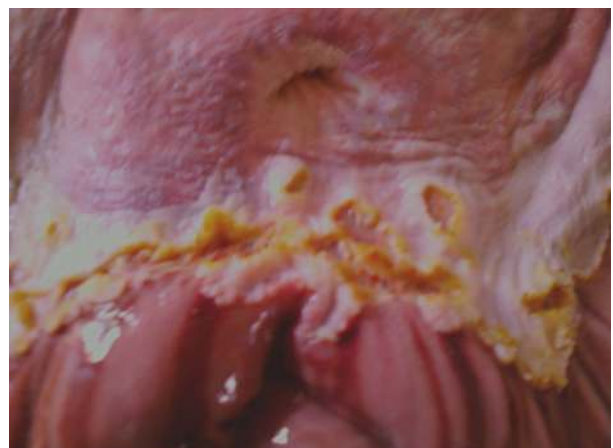

Figure 2. Gastric mucosa of horse with Equine Gastric ulcer syndrome Grade 4. Extensive ulcers, with areas of deep submucosal penetration.

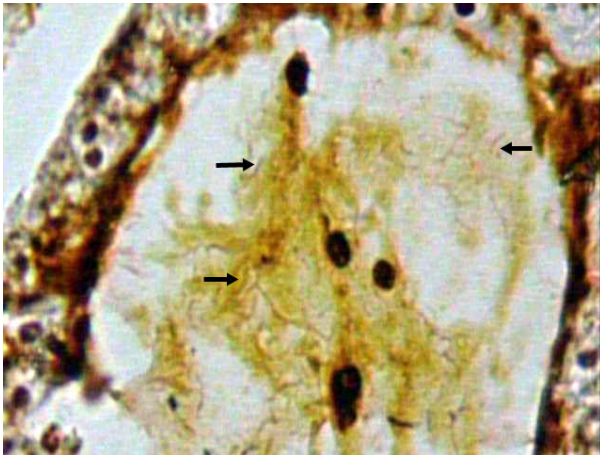


Figure 3. Gastric mucosa of horse with Equine Gastric ulcer syndrome Grade 4. Special staining Warthin-Starry showed spiral-shaped bacteria (arrows) (Warthin-Starry obj.40x).

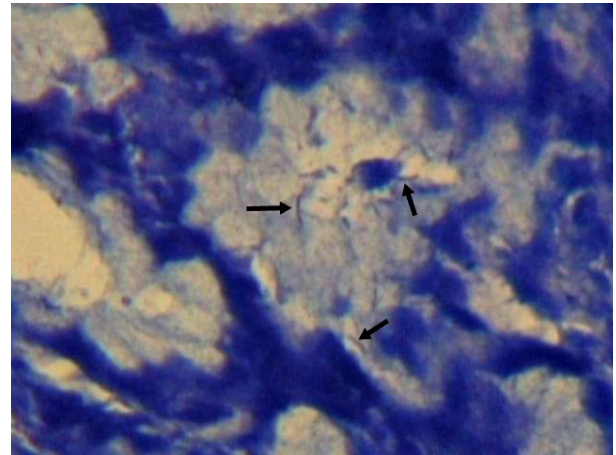


Figure 6. Gastric mucosa of horse with Equine Gastric ulcer syndrome Grade 4. Special staining Warthin-Starry showed spiral-shaped bacteria (arrows) (Giemsa obj. 40x).

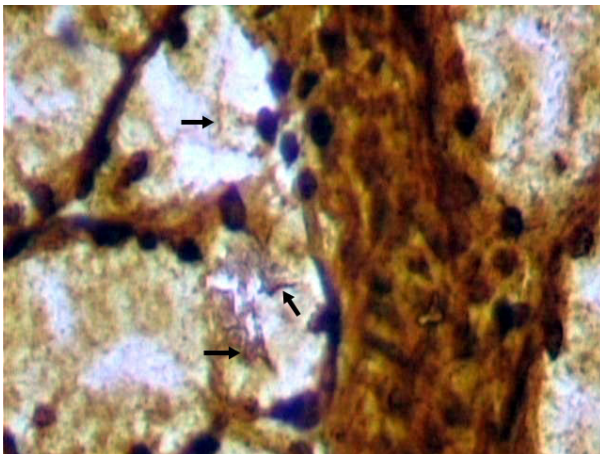


Figure 4. Gastric mucosa of horse with Equine Gastric ulcer syndrome Grade 4. Special staining Warthin-Starry showed spiral-shaped bacteria (arrows) (Warthin-Starry obj. 40x).

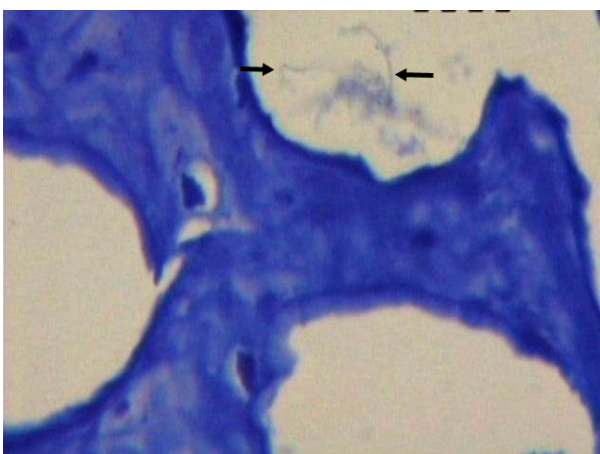


Figure 5. Gastric mucosa of horse with Equine Gastric ulcer syndrome Grade 4. Special staining Warthin-Starry showed spiral-shaped bacteria (arrows) (Toluidina Blue obj. 40x).

Discussion

The EGUS refers to several ailments, which include inflammatory and ulcerous mucosal diseases. A high prevalence (90%) of ulcers and gastritis was found in Thoroughbred racehorses during our study and gastrointestinal disorders at the time of their euthanasia. This agrees with other earlier studies reporting the occurrence of gastric ulcers in 80 to 90% of Thoroughbred racehorses. The greatest proportion of such lesions appear on the squamous mucosa region close to the *margo plicatus*, with fewer lesions on the glandular mucosa portion (5, 7, 9, 13, 14). However, our results show that the gastric ulcers as well as the gastritis were present on both mucosal regions. The EGUS is multifactor and is caused by exposure of the stomach to inorganic compounds, feed, management stress and non-steroidal anti-inflammatory drugs such as corticosteroids which all act synergistically increasing acid production which in turn leads to gastric ulcers (2, 13, 14). Another possible cause of EGUS is the presence of species of *Helicobacter* in the stomachs of horses, but the relevance of this genus on EGUS has not yet been demonstrated (2). Although diverse species of *Helicobacter* have been linked to ulcers and to non-ulcerative gastritis in other animals (6), none has been cultured from stomach horses. To date, only two studies have reported the presence of *Helicobacter*-specific DNA in the squamous and glandular mucosa of horses (2, 4, 11, 12, 15) and one new species of *Helicobacter* named *H. equorum* was isolated from the faeces of the two asymptomatic horses (11). Thirty-eight percent (52/136) of the horses infected by *Helicobacter* examined in this study showed gastric mucosal lesions expressed as ulcers, gastritis or both lesions, with no apparent association between the degree or localization of the lesions within their stomachs. All horses with *Helicobacter* were urease positive. This suggests that *Helicobacter* species are present in stomach of Thoroughbred horses with EGUS.

These results are consistent with those reported in other studies where the prevalence of EGUS is 80-90% of Thoroughbred horses in race (2, 13, 14). The special stains showed the presence of bacteria with morphology of spiral type, and short bacilli coccobacillus; morphology could be appreciated in greater detail in the special Warthin-Starry staining. The 38% percent (52/136) of horses infected with *Helicobacter* in this study showed gastric mucosal lesions associated with gastritis, ulcers and /or the two conditions without apparent association with the degree and location of the lesion in their stomachs. Diagnosis of *Helicobacter* sp can be done as follows: study for serological and immunological response (formation of immunoglobulins by specific IgG antibodies) for the evaluation of sucrose. The isolation and bacterial culture is the ideal method but it is limited by bacteria difficult to grow, the methods of molecular biology, specifically chain reaction polymerase chain reaction (PCR), the study by macroscopic and histopathological staining special silver salts described in this paper and immunohistochemical study. To conclude we detected the presence of *Helicobacter* Like Organisms in the gastric mucosa with EGUS of Thoroughbred. The *Helicobacter* presence could be an important risk factor of EGUS. Furthermore, the cultures and subsequent bacterial identifications are still a requisite to establish the effects of *Helicobacter* spp on Thoroughbred gastric mucosa.

Acknowledgements

This work was supported by the PG 11-00-6631-06 CDCH Central University of Venezuela.

References

1. ALUJA A., CONSTANTINO C. Technical of Necropsy in domestic animals. 2nd ed. Mexico: Manual Moderno. 2002, 103-104.
2. BANKS W. Veterinary Applied Histology. 2nd ed. México. Manual Moderno, 1996, 487-492.
3. CONTRERAS M., MORALES A., GARCIA-AMADO M.A., DE VERA M., BERMUDEZ V., GUENEAU P. Detection of *Helicobacter*-like DNA in the gastric mucosa of Thoroughbred horses. Lett. Appl. Microbiol., 2007, 45, 553-7.
4. DONALD M. Special Veterinary Pathology. 3.ed. USA: Mosby, 1996, 24-29.
5. FOX, J.G., LEE, A. The role of *Helicobacter* species in newly recognized gastrointestinal tract diseases of animals. Lab. Anim. Sci. 1997, 47: 222-255.
6. FOX JG. The non-*H. pylori* *Helicobacters*: their expanding role in gastrointestinal and systemic disease. Gut, 2002, 50, 273-83.
7. JUBB KVF., KENNEDY PC., PALMER N. Domestic animal pathology. Charter 1, Vol. II, 3.ed. Uruguay: Hemisferio Sur, S.R.L. 1984, 50-90.
8. MERRITT, A. The equine stomach: A personal perspective (1963-2003). In 49 Annual Convention of the American Association of Equine Practitioners, New Orleans, Louisiana. 2003.
9. MCCLURE S, GLICKMAN L, GLICKMAN N. Prevalence of gastric ulcers in show horses. J. Am. Vet. Med. Assoc., 1999, 215, 1130-3.
10. MORALES A, BERMUDEZ V, DE VERA M, CONTRERAS M, GARCIA M, GUENEAU P. A multidisciplinary study of gastric ulcers in Thoroughbreds of Venezuela. Vet. Pathol., 2006, 43, 822.
11. MOYAERT H, DECOSTERE A, VANDAMME P, DEBRUYNE L, MAST J, BAELE M, CELEN L, HAESBROUCK F. *Helicobacter equorum* sp. nov., a urease-negative *Helicobacter* species isolated from horse faeces. Int. J. Syst. and Evol. Microbiol.. 2007, 57, 213-8.
12. MOYAERT H, HAESBROUCK F, DEWULF J, DECOSTERE A, VANDAMME P, DEBRUYNE L, MAST J, BAELE M, CELEN L., *Helicobacter equorum* is highly prevalent in foals. Vet. Microbiol., 2009, 133, 190-2.
13. MURRAY MJ. Gastric ulcers in adult horses. The Compendium. 1994, 16, 792-7.
14. MURRAY M.J., SCHUSSER GF., PIPERS FS., GROSS S.J. 1996. Factors associated with gastric lesions in thoroughbred racehorses. Equine Vet. J., 1996, 28, 368-74.
15. VIDELA, R., ANDREWS, F. New Perspectives in Equine Gastric Ulcer Syndrome. Veterinary clinics of North America. 2009, 25, 287-8.