Braz J Vet Pathol, 2025, vol. 18, Suppl. 1, e018S109
DOI: https://doi.org/10.24070/bjvp.1983-0246.018S109

BJVP
Brazilian Journal of Veterinary Pathology
ISSN 1983-0246

Diagnostic Exercise
From the Latin Comparative Pathology Group and the Davis-Thompson Foundation

Arterial calcification in a rabbit

Carmen García-Romero,[1]* Elena Colombino,[1] Arturo Oliver-Guimera,[1] Agustín Barragán,[1] David Viana,[1] Juan Manuel Corpa,[1] Joaquín Ortega,[1] Laura Selva,[1] Francisco A. Uzal,[2] Estefania Montero.[1]

[1]Veterinary Pathology Service. School of Veterinary Medicine, Department of Animal Production and Health, Public Veterinary Health and Food Science and Technology, Universidad Cardenal Herrera-CEU, CEU Universities, Valencia, Spain.
[2]California Animal Health and Food Safety Laboratory System, San Bernardino Branch, School of Veterinary Medicine, University of California-Davis, San Bernardino, CA, USA.

***Corresponding author:** carmen.garciaromero@uchceu.es

History:

A 6.5-year-old spayed female domestic toy rabbit (*Oryctolagus cuniculus*) presented with a history of apathy, weight loss for approximately 2 weeks and paralysis of both hind limbs. Due to the worsening of its condition and poor prognosis, the rabbit was euthanized.

At necropsy there was thickening, stiffness and hardening of aorta subclavian artery, brachiocephalic trunk, external and internal iliac arteries. The heart was globose du to dilatation of the tight ventricle (Figs. 1,2, and 3).

Follow-up questions:

- *Histological description*
- *Morphologic diagnoses*
- *Name of the condition*
- *Special stains you would use for diagnosis*

ANSWERS

Histological description:

There is systemic mineralization characterized by the presence of abundant basophilic granular material in several organs. In the aorta and in arteries of kidney and lungs (Figure 4,5b,6), there is a thickening of the tunica media. In the

**The Diagnostic Exercises are an initiative of the Latin Comparative Pathology Group (LCPG), the Latin American subdivision of The Davis-Thompson Foundation (DTF). These exercises are contributed by members and non-members from any country of residence. Consider submitting an exercise! A final document containing this material with answers and a brief discussion will be posted on the DTF website: https://davisthompsonfoundation.org/diagnostic-exercise/*

***Editor-in-chief for this Diagnostic Exercise:** Claudio Barros*
***Associate Editor for this Diagnostic Exercise:** Francisco Uzal*

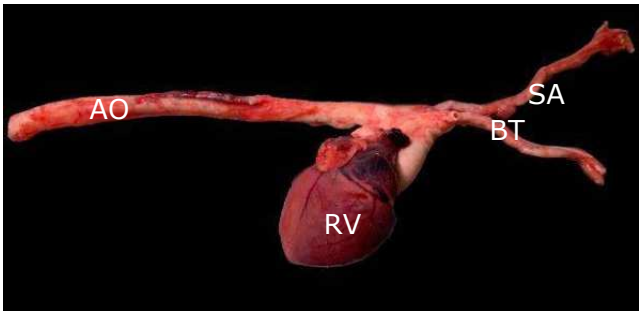

Figure 1. Heart and large vessels. Thickening, stiffness and hardening of aorta (AO), subclavian artery (SA) and brachiocephalic trunk (BT). RV, right ventricle.

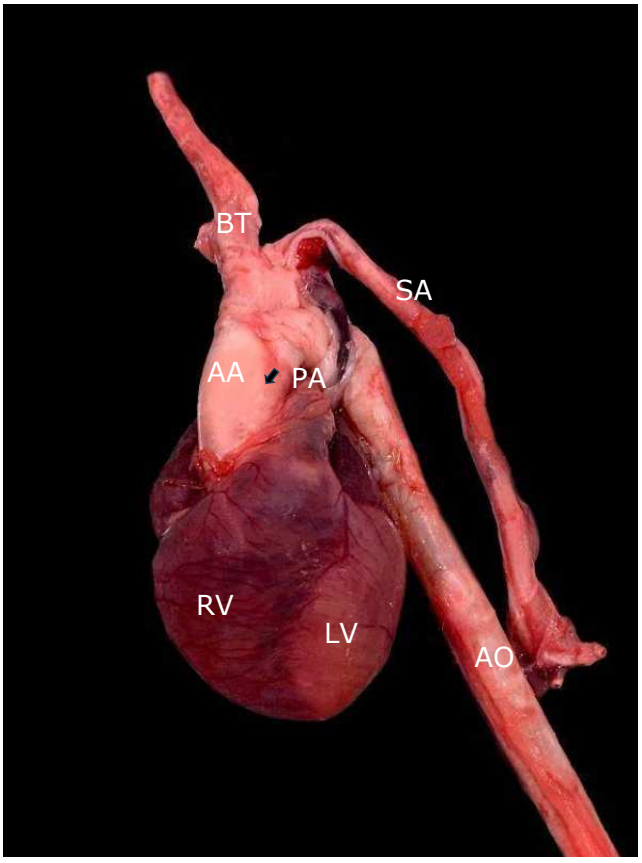

Figure 2. Heart and large vessels/arteries. Dilatation of the right ventricle with globular appearance (RV). Thickening and stiffening of the aortic arch (AA) with peripheral nerves, there is mineral deposition in the axons and expansion of the myelin sheath (Figure 5a). In the lung, there is mineral deposition in the alveolar space, originating from the alveolar basement membranes, presence of ectatic blood vessels (congestion) and abundant proteinaceous fluid within alveoli (edema). Multiple contiguous alveoli coalesce and are expanded by clear spaces (emphysema), or have colapsed alveolar walls (atelectasis) (Figure 5b). The kidney shows mineralization of tubules, glomeruli, and vessels. The inflammatory infiltrate is primarily composed of lymphocytes and plasma cells. Multifocally, glomeruli,

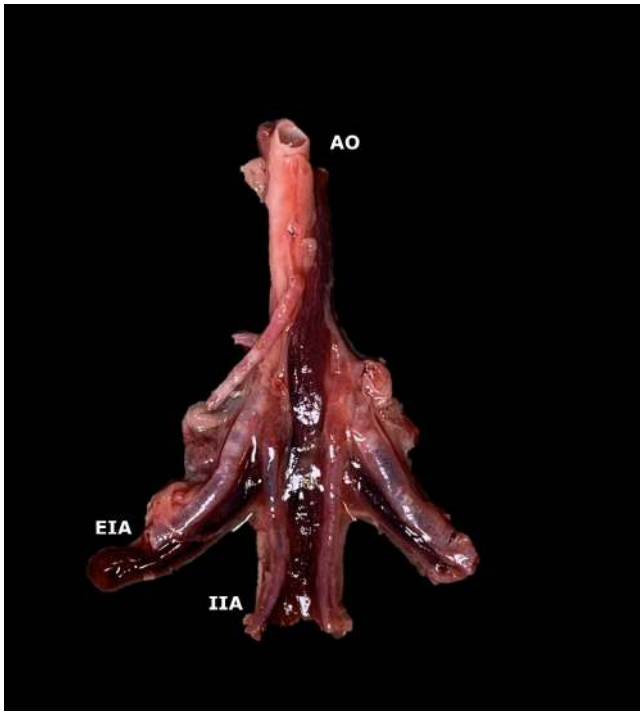

Figure 3. Iliac arteries. Thickening of the external iliac arteries (EIA) and internal iliac arteries (IIA). AO, Aorta.

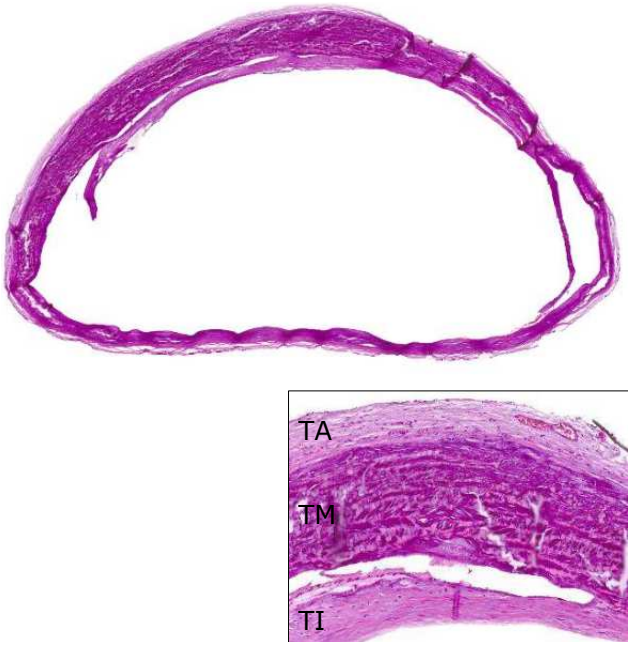

Figure 4. Aorta. Presence of a complete ring of mineralization with separation between tunica media (TM) and tunica intima (TI). Inset: Thickening of the tunica media (TM) and deposition of prominent, granular basophilic material (mineral). TA, tunica adventitia. Hematoxylin and eosin.

tubules, and vessels in both cortex and medulla are widely separated, surrounded, and replaced by fibroblasts and abundant collagen (fibrosis) (Figure 6).

Morphologic diagnoses:

1- Artery/aorta: Mineralization severe, chronic, diffuse.
2- Lung: Mineralization multifocal, moderate, chronic, with congestion, edema, emphysema and atelectasis multifocal, moderate.
3- Kidney: Tubular and glomeruli mineralization, moderate, chronic, multifocal, with interstitial nephritis and fibrosis.
4- Peripheral nerve: Mineralization, multifocal, moderate, chronic.

Name of the condition:

Medial arterial calcification.

Special stains you would use for diagnosis:

Von Kossa (Figure 7)

Comments

In all species, dietary calcium absorption follows two processes. On the one hand, passive paracellular diffusion depends on the concentration gradient between the intestinal lumen and the blood. On the other, active transcellular transport is dependent on vitamin D (2) In rabbits, calcium metabolism has evolved to meet high physiological demands, driven by the continuous eruption and growth of teeth, as well as the ability of does to gestate large litters and lactate concurrently. Unlike other species, passive absorption is the main mechanism of intestinal calcium uptake (2,3). A consequence of this mechanism is that calcium absorption from the gut is proportional to the calcium content of the diet. This efficient passive calcium absorption is due to the need to meet the high calcium demand in rabbits, resulting in higher serum total calcium concentrations compared to other domestic mammals. This may account for the rabbit's propensity for rapid dystrophic calcification (2,3). In other mammalian species, hypercalcemia may cause kidney damage or soft tissue calcification. However, rabbits appear to tolerate relatively high levels of calcium without experiencing such damaging effects. Nevertheless, persistently elevated blood calcium levels can result in soft tissue calcification in rabbits. In one case, a rabbit that presented with seizures and hypercalcemia was subjected to a postmortem examination, which revealed extensive mineralization of the aorta, brachiocephalic trunk, left subclavian artery, both iliac arteries, common carotid arteries, and renal arteries (6).

Medial arterial calcification is a type of arteriosclerosis. This is a common lesion in animals with endocardial

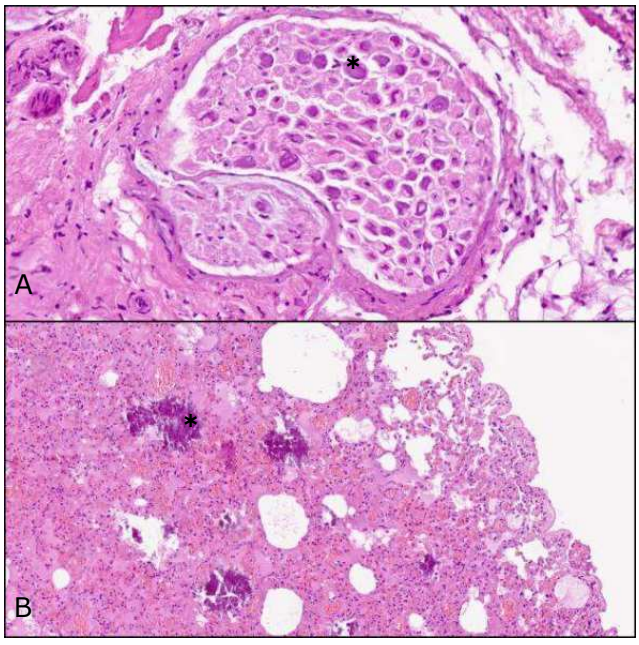

Figure 5. Multiple metastatic mineralization in inner organs (asterisk). A) partially mineralization of myelin sheaths affecting multiple axons. B) Multiple foci of mineralization in the lung parenchyma, with prominent congestion, alveolar edema, emphysema and atelectasis. HE.

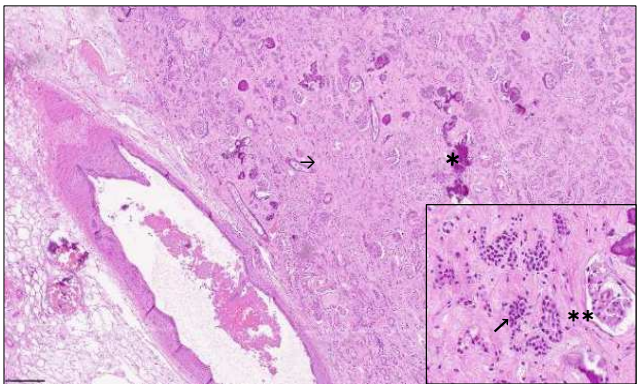

Figure 6. Kidney. Tubules, glomeruli and vessels with abundant basophilic granular material (mineral) (asterisk). There is a large amount of fibrous connective tissue replacing the renal parenchyma (interstitial fibrosis) (arrow). Inset: lymphoplasmacytic inflammatory infiltrate in the interstitium (interstitial nephritis) (arrow) and interstitial fibrosis (double asterisks). HE.



Figure 7. Aorta. This technique stains mineral deposits a brownish-black color (asterisk). Von Kossa.

mineralization and affects elastic and muscular arteries (4,5). Macroscopically, it has a unique appearance in the arteries, displaying solid and dense tubular structures with elevated, white, solid intimal plaques. Microscopically, in the media of elastic arteries, basophilic granular mineral deposits can be found, and in the media of muscular arteries, they may form a complete ring of mineralization (3). These findings were observed in the present case at the time of necropsy as well, severe mineralization of the iliac arteries, which was a probable cause of the paralysis of both hind limbs. Among the most common causes of medial arterial calcification are carcinogenic plant toxicosis, renal failure, and vitamin D toxicosis, which occasionally occurs in domestic rabbits fed an improperly formulated diet (1,7). In rabbits, medial arterial calcification can also occur spontaneously (5,7).

Considering the observed renal lesions (fibrosis and mineralization), rabbits regulate calcium output into the urine instead of regulating calcium input from the intestine. Thus, the kidneys play an important role in maintain calcium homeostasis. Nephrocalcification is often associated with ectopic calcification of other tissues, especially arteries and arterioles. It is often associated with hypercalcemia or hyperphosphatemia (or both). Calcification is localized in the cortical and corticomedullary tubules. The main causes are chronic renal failure, vitamin D toxicity (leading to renal and other tissue calcification) and high dietary Ca levels. The latter cause is more prevalent in laboratory rabbits that are force-fed high levels of calcium. However, in domestic rabbits, blood calcium levels are not high enough to induce renal calcification. A recent study failed to induce ectopic calcification by feeding high calcium, so other contributing factors such as impaired renal function, reduced water intake and calcium-phosphorus imbalance are suspected (2). In this case, the cause of the generalized metastatic calcification was not identified, but dietary imbalances and the age of the animal could be contributing factors in this process.

References

1. Percy DH. Pathology of laboratory rodents and rabbits. 3ªed. Ames, Iowa: Blackwell Pub.; 2007. 325 p.
2. Harcourt-Brown FM. Diagnosis of renal disease in rabbits. Vet Clin North Am Exot Anim Pract. 2013 Jan;16(1):145–74
3. Harcourt-Brown FM. World Small Animal Veterinary Association World Congress Proceedings; 2010
4. Jones TC, Hunt RD, King NW. Blood vessels and lymphatic vessels In: Veterinary Pathology. 6th ed. Baltimore: Williams & Wilkins; 1997:997-1002.
5. BSAVA Manual of Rabbit Medicine. Meredith A, Lord B, editors. British Small Animal Veterinary Association; 2014. p. 212.
6. Redrobe S. Calcium metabolism in rabbits. Seminars in Avian and Exotic Pet Medicine. 2002;11(2):94–101.
7. Zachary JF. Pathologic Basis of Veterinary Disease. 6th ed. St. Louis: Elsevier; 2017. p. 600.