BJVP
Brazilian Journal of Veterinary Pathology

Case report

Primary brain T-cell lymphoma in a cat

Fabiano J. F. de Sant'Ana[1], Janildo L. Reis Junior[2], Corrie C. Brown[2], Ingeborg M. Langohr[3], Claudio S. L. Barros[1*]

[1]Laboratory of Veterinary Pathology, Federal University of Santa Maria (UFSM), Santa Maria, RS, Brazil.
[2]Department of Pathology, College of Veterinary Medicine, The University of Georgia, Athens, GA, USA.
[3]Diagnostic Center for Population and Animal Health, Michigan State University, Lansing, MI, USA
***Corresponding author:** Claudio S. L. Barros, Department of Pathology, UFSM, 97105-900, Santa Maria, RS, Brazil.
E-mail: claudioslbarros@uol.com.br.

Submitted January 30th 2010, Accepted March 22nd 2010

Abstract

A 10-year-old, female, mixed-breed cat was presented for necropsy with history of incoordination, circling and nystagmus or fixed gaze. Grossly, slight asymmetry was observed in the right telencephalic hemisphere, mainly in the pyriform lobe. Histologically, sheets of small round neoplastic cells were observed in the pons, midbrain, thalamus and in the subcortical white matter of the parietal, occipital and pyriform lobes. Neoplastic cells were strongly labeled with anti-CD3 antibody by means of immunohistochemistry. Anti-BLA36, CD79a and MAC387 failed to label the neoplastic cells. Based on the histopathological findings and on the immunohistochemical results, a diagnosis of primary brain T-cell lymphoma was made.

Key Words: cat diseases; T-cell lymphoma; CNS neoplasia; neuropathology.

Introduction

Intracranial tumors are less common in cats than in dogs (14). Lymphoma in cats is commonly associated with feline leukemia virus (FeLV) and feline immunodeficiency virus (FIV) infections (2) but is infrequently described in nervous system (CNS) of this species (4, 8, 10, 13). Lymphomas affecting the CNS usually are part of a multicentric disease in dogs and cats (14). An association between immunosuppressive disorders and primary brain lymphomas has been recognized in humans (5). In cats and humans, most primary CNS lymphomas are B-cell tumors (3, 9, 10, 13) and T-cell neoplasms are rarely described (4, 8). Age, breed and sex predilections have not been determined (6).

Case report

This report describes the pathological and immunohistochemical findings of a primary brain T-cell lymphoma in a 10-year-old, female, mixed-breed cat submitted for necropsy with a clinical history of seven days of incoordination, circling and nystagmus or fixed gaze.

Grossly there was slight asymmetry of the right telencephalic hemisphere, mainly in the pyriform lobe. Additionally, the natural and cut surfaces of the liver presented numerous white punctiform areas. Samples of multiple organs, including brain, spinal cord, lung, heart, spleen, liver, kidney and mesenteric and mediastinal lymph nodes, were sampled and fixed in 10% buffered formalin. The tissues were processed by routine methods for histopathological evaluation and stained with hematoxylin and eosin. In order to establish a final diagnosis of the neoplasm, the following antibodies were applied in appropriate dilutions on the brain sections: CD3 (polyclonal, 1:200) (Anti-human T cell and anti-human CD79αcy [M7051] antibody, Dako, Glostrup, Denmark), CD79a[a] (monoclonal, 1:50) (Anti-human T cell and anti-human CD79αcy [M7051] antibody, Dako, Glostrup, Denmark), BLA36 (monoclonal, 1:200) (Anti-B Lymphocyte [A0452] antibody from ascites fluid, Biogenexm, San Ramon, CA, USA), MAC387 (monoclonal, 1:200) (Anti-human myeloid/histiocyte [M0760] antibody, Dako, Carpinteria, CA, USA), FeLV (monoclonal, 1:200) (Anti-FeLV gp70 [C11D8] antibody, Custom Monoclonal Antibodies, Sacramento, CA, USA) and feline infectious peritonitis (FIP) virus (monoclonal, 1:1000) (Anti-FIP [FIPV3-70] antibody, Custom Monoclonal Antibodies, Sacramento, CA, USA). Immunohistochemistry (IHC) sections were counterstained with Mayer's hematoxylin. Positive

 All rights reserved 2007.

controls for IHC consisted of normal cat lymph nodes for the round cell markers (CD3, CD79a, BLA36 and MAC387) and lymph nodes of cats infected with FeLV and FIP virus. For negative controls, the primary antibodies were replaced with PBS. AP polymer (UltraVision ONE Large Volume Detection System, Thermo Scientific, Fremont, CA, USA) and alkaline phosphatase (Vector Red Alkaline Phosphatase, Vector Laboratories, Burlingame, CA, USA) were used as the detection system. In addition, formalin-fixed paraffin-embedded sections of the brain were submitted for identification of FeLV viral particles by real-time PCR as previously described (12).

Microscopically, aggregates of small neoplastic round cells expanded areas of the pons, midbrain, thalamus and subcortical white matter of the parietal, occipital and pyriform lobes (Fig. 1). These cells presented typical lymphoid or plasmacytoid morphology. In some regions, neoplastic cell aggregates coalesced to form extensive sheets. In these areas, some arterioles presented moderate fibrinoid degeneration (Fig. 2). The neoplastic cells had moderate pleomorphism, scant cytoplasm and hyperchromatic nuclei. One to three mitoses were observed per high power field. Neoplastic lymphocytes were also present in multiple layers in the perivascular spaces and around the mesencephalic aqueduct and third ventricle. Except for the liver, which showed marked centrilobular degeneration of hepatocytes, the other tissue samples were unremarkable and signs of the neoplastic infiltration were found nowhere other than the brain. At IHC evaluation, the neoplastic cells had strong diffuse cytoplasmic labeling for CD3 (Fig. 3). There was no labeling in the tumor cells for CD79a (Fig. 4), BLA36, MAC387, FIP viral and FeLV antibodies. PCR for FeLV was negative.

Based on the morphologic and immunohistochemical findings, a diagnosis of primary brain T-cell lymphoma was made.

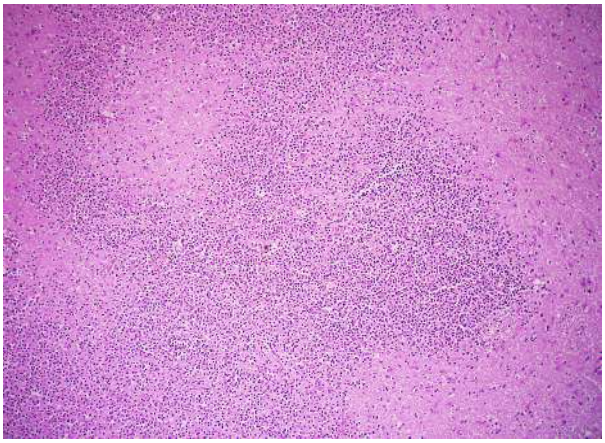

Fig. 1. Thalamus, cat, primary brain T-cell lymphoma. Multifocal to coalescent aggregates of neoplastic round cells. Hematoxylin and eosin, 10X.

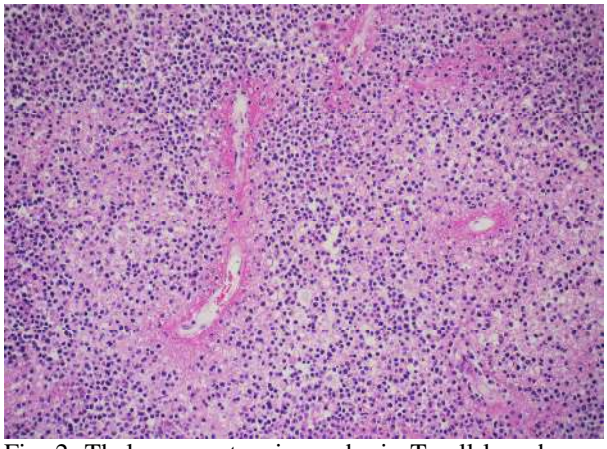

Fig. 2. Thalamus, cat, primary brain T-cell lymphoma. Arterioles present moderate fibrinoid degeneration in an area with marked neoplastic infiltration. Hematoxylin and eosin, 20X.

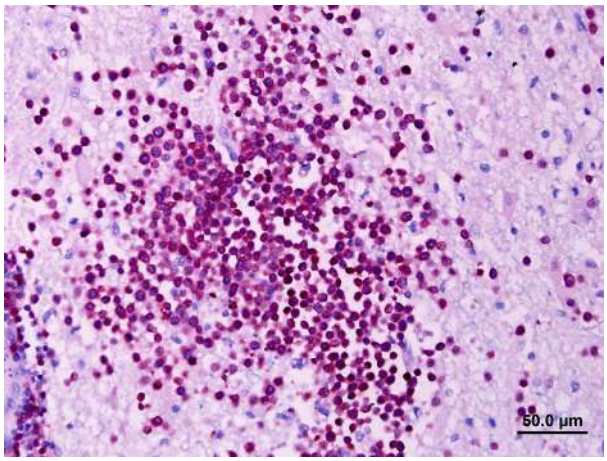

Fig. 3. Thalamus, cat, primary brain T-cell lymphoma. Neoplastic cells are strongly immunoreactive for CD3. Mayer's hematoxylin counterstain. Bar = 50 µm.

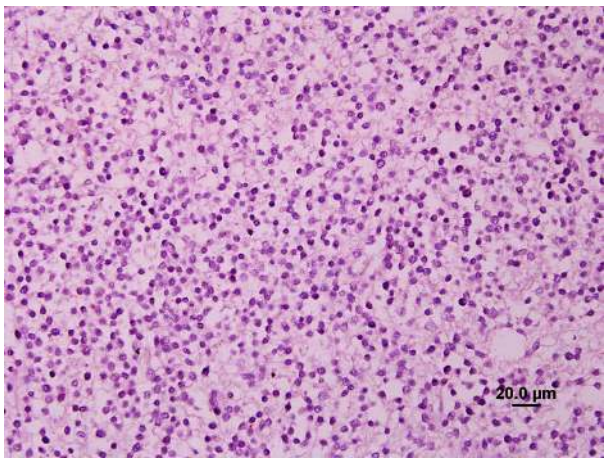

Fig. 4. Thalamus, cat, primary brain T-cell lymphoma. Neoplastic cells are negative for CD79a. Mayer's hematoxylin counterstain. Bar = 20 µm.

Discussion

The diagnosis of brain tumors can be challenging in cats. Clinical signs are variable, dependent on the location of the neoplasm and frequently have an insidious onset (4). In the cat of this report, the anatomic location of the tumor was likely responsible for the clinical signs observed since the parietal and occipital lobes of the cortex and brain stem were affected. The microscopic pathologic findings described in this report may be related to the visual and locomotion disturbances observed clinically; incoordination, circling, nystagmus and fixed gaze can be associated with tumor lesions in telencephalus or diencephalus, brain stem or telenchephalus, brain stem and midbrain, respectively (7).

In some of the previously published cases of primary CNS lymphoma, gross lesions were absent or at least not grossly appreciated (4), as in the present report. In other descriptions, masses or nodules were observed in thalamus (9), parietal lobe (10) or spinal cord (14). Dilations of the central canal of the spinal cord and lateral and third ventricles were observed in a primary CNS T-cell lymphoma with periventricular spread (8). Microscopically, lymphomas of the CNS in cats affect both the spinal cord (2, 14) and brain including leptomeninges, thalamus, hypothalamus, telencephalon, olfactory bulb and mesencephalic aqueduct (4, 9, 14). In the present case, the neoplasm affected the telencephalic lobes, diencephalon and brain stem. Fibrinoid degeneration was observed in arterioles in the areas heavily infiltrated by neoplastic lymphocytes. This microscopic finding has not been previously described in primary CNS lymphomas of animals. Vascular lesions have been associated with CNS lymphomas in human. In these cases, lymphomas exhibiting angiotropic characteristics have been observed in both acquired immunodeficiency syndrome (AIDS) and non-AIDS populations (1, 11).

Main differential diagnoses included multicentric lymphoma with metastasis to the brain and CNS infectious diseases of cats such as those seen with FIP virus or FeLV infection. Absence of neoplastic lesions in lymphoid organs such as spleen or lymph nodes excluded the diagnosis of multicentric lymphoma. Metastatic lymphomas generally affect the leptomeninges, choroid plexus and epidural space (6). These regions were not affected in the present case. Additionally, non-suppurative encephalomyelitis, degenerative myelopathy and vasculitis with pyogranulomatous inflammation of ventricles, ependyma, meninges, choroid plexus and adjacent tissues suggestive of FIV, FeLV and FIP infections, respectively, were not observed.

In the present report, a rare case of primary brain T-cell lymphoma in a cat is described. Although some microscopic findings such as the presence of plasmacytoid cells in the sheets of neoplastic cells were suggestive of B-cell lymphoma, the IHC results were consistent with brain T-cell lymphoma. The immunohistochemical evaluation was essential to confirming the diagnosis.

Acknowledgements

The authors thank Dr. Matti Kiupel and Dr. Roger Maes and their staff for the technical assistance with the IHC for FeLV and FIP virus and with the real-time PCR for FeLV, respectively.

References

1. ALTAVILLA G., CUSATELLI P., SALMASO R., GARDIMAN M. Primary central nervous system lymphomas: clinico-pathologic and immunohistochemical analysis of 30 cases. *Tumori*, 1999, 85, 19-27.
2. CALLANAN JJ., JONES BA., IRVINE J., WILLETT BJ., McCANDLISH IA., JARRETT O. Histologic classification and immunophenotype of lymphosarcomas in cats with naturally and experimentally acquired feline immunodeficiency virus infection. *Vet. Pathol.*, 1996, 33, 264-72.
3. FERRACINI R., PILERI S., BERGMANN M., SABATTINI E., RIGOBELLO L., GAMBACORTA M., GALLI C., MANETTO V., FRANK G., GODANO U. Non-Hodgkin lymphomas of the central nervous system. Clinico-pathologic and immunohistochemical study of 147 cases. *Pathol. Res. Pract.*, 1993, 189, 249-60.
4. FONDEVILA D., VILAFRANCA M., PUMAROLA M. Primary central nervous system T-cell lymphoma in a cat. *Vet. Pathol.*, 1998, 35, 550-3.
5. HALDORSEN IS., KRAKENES J., GOPLEN AK., DUNLOP O., MELLA O., ESPELAND A. AIDS-related primary central nervous system lymphoma: a Norwegian national survey 1989-2003. *BMC Cancer*, 2008, 8, 225.
6. KOESTNER A., HIGGINS RJ. *Tumors of the nervous system*. MEUTEN DJ. Eds. *Tumors in domestic animals.* 4.ed., Iowa: Iowa State Press, 2002: 697-738.
7. LORENZ MD., KORNEGAY JN. *Neurologia Veterinária.* 4.ed., Barueri: Manole, 2006. 467p.
8. MORITA T., KONDO H., OKAMOTO M., PARK CH., SAWASHIMA Y., SHIMADA A. Periventricular spread of primary central nervous system T-cell lymphoma in a cat. *J. Comp. Pathol.*, 2009, 140: 54-8.
9. MORRISON JA., FALES-WILLIAMS A. Hypernatremia associated with intracranial B-cell lymphoma in a cat. *Vet. Clin. Pathol.*, 2006, 35: 362-5.
10. NAKAMOTO Y., OZAWA T., UCHIDA K., OMORI K., HASE K., NAKAICHI M.. Primary intra-axial B-cell lymphoma in a cat. *J. Vet. Med. Sci.*, 2009, 71: 207-10.

11. ROITBERG BZ., COCHRAN EJ., THORNTON J., CHARBEL FT. Giant anterior communicating artery aneurysm infiltrated with a primary cerebral lymphoma: case report. *Neurosurgery*, 2000, 47: 458-62.

12. TANDON R., CATTORI V., GOMES-KELLER MA., MELI ML., GOLDER MC., LUTZ H., HOFMANN-LEHMANN R. Quantitation of feline leukaemia virus viral and proviral loads by TaqMan® real-time polymerase chain reaction. *J. Virol. Methods*, 2005, 130: 124-32.

13. VERNAU KM., HIGGINS RJ., BOLLEN AW., JIMENEZ DF., ANDERSON JV., KOBLIK PD., LECOUTEUR RA. Primary canine and feline nervous system tumors: intraoperative diagnosis using the smear technique. Vet. Pathol., 2001, 38: 47-57.

14. ZAKI FA., HURVITZ AI. Spontaneous neoplasms of the central nervous system of the cat. J. Small Anim. Pract., 1976, 17: 773-82.