Braz J Vet Pathol, 2026, vol. 19, e019019
DOI: https://doi.org/10.24070/bjvp.1983-0246.019019

BJVP
Brazilian Journal of Veterinary Pathology
ISSN 1983-0246

Case Report

Extragonadal mature teratoma in a 6-months-old kitten

Rayane Chitolina Pupin[1]*, Jhony Ferreira Marcari[2], Danilo Carloto Gomes[1], Gabriela de Souza Silva[2]*, Larissa Correa Hermeto[3], Igor Ribeiro Santos[4], Saulo Petinatti Pavarini[4]

[1]Laboratório de Anatomia Patológica, Faculdade de Medicina Veterinária e Zootecnia, Universidade Federal de Mato Grosso do Sul, Campo Grande, MS, Brazil
[2]Programa de Residência Multiprofissional, Faculdade de Medicina Veterinária e Zootecnia, Universidade Federal de Mato Grosso do Sul, Campo Grande, MS, Brazil
[3]Setor de Clínica Cirúrgica de Pequenos Animais, Faculdade de Medicina Veterinária e Zootecnia, Universidade Federal de Mato Grosso do Sul, Campo Grande, MS, Brazil
[4]Setor de Patologia Veterinária, Faculdade de Veterinária, Universidade Federal do Rio Grande do Sul, Porto Alegre, RS, Brazil

*Corresponding author: rayane.pupin@ufms.br
Submitted: November 10th, 2025. Accepted: May 11th, 2026.

Abstract
Germ cell tumors can be classified as teratoma, embryonal carcinoma, yolk sac carcinoma, dysgerminomas and seminomas. Teratomas are composed by well-differentiated cells from at least two of the three embryonic layers, and are more commonly in ovaries or testicles, but can occur extragonadal. This case describes a subcutaneous mature teratoma in a 6-month-old kitten. Macroscopically, the tumor was multilobulated and firm, measuring 11 x 6,5 x 5cm; on cut surface, multiple cystic cavities, solid white areas and hard portions. Histologically, cells derived from the three layers were present – hair follicles and glands, nervous tissue, odontogenic epithelium, respiratory epithelium, and different mesenchymal cells (bone, adipocytes, muscle fibers and fibrous tissue). Immunolabeling for pancytokeratin, vimentin, GFAP and p40 were strong in the different types of cells, and no immature tissue was seen. So, the tumor was classified as a mature extragonadal teratoma. The mass was completely excised and no recurrence was seen.

Keywords: cat, cutaneous tumors, extragonadal teratoma germ cell tumors.

Introduction

Germ cell tumors (GCT) are those derived from the cells that give rise to sperm and eggs (5), and are more commonly found in the ovaries or testicles. They are classified as teratoma, embryonal carcinoma, yolk sac carcinoma, dysgerminomas (ovary) and seminomas (testicles) (1).

Extragonadal germ cell tumors occur outside the gonads, without a primary gonadal tumor (16). The etiopathogenesis is not clearly understood, but it is believed that a failure occurs during the migration of the germ cells to the gonads (13, 16, 18). Since this migration occurs through the midline of the body, these tumors can occur anywhere – from the brain to the coccyx - but are more common in the mediastinum, retroperitoneum, and brain (16).

Teratomas are composed of neoplastic cells from at least two of the three embryonic layers. Most are classified as mature, have benign behavior, and show well-differentiated tissues (1, 2, 19). Immature teratomas can be malignant, potentially metastatic, and show less-differentiated tissues (1, 2, 9, 15).

In cats, teratomas have been described affecting the ovaries (2, 9, 17), testicles (10), skin and subcutaneous tissues (7, 14, 18, 19), retrobulbar region (20), oral cavity (12) and intracranially (4). They have also been described in dogs (15, 21), cattle (3), horses (8), sheep (13), and birds (6, 11).

The aim of this paper is to describe the histological and immunohistochemical aspects of an extragonadal mature teratoma in a 6-month-old kitten affecting skin and subcutaneous tissues of the periauricular region.

Case description

A 3-month-old kitten was presented for veterinary evaluation due to a periauricular nodule measuring 7 x 5 cm, with progressive growth. The mass was firm, irregular, and non-painful (Fig. 1A). The animal underwent a computed tomography (CT) scan, which revealed cystic and mineralized areas within the mass. Cytology was performed, and the diagnosis was squamous cell carcinoma. Surgery was recommended but the owners did not agree to do it. A punch biopsy was performed and sent to histopathological evaluation, and the diagnosis was undifferentiated sarcoma. After three months, the kitten showed reduced nasal sensitivity and decreased menace reflex on the right side. Due to the increase in the size of the mass (Fig. 1B), the owners agreed to perform surgery. Preoperative examinations showed no evidence of metastasis. Given the cytological and histopathological diagnosis, the mass was completely removed and electrochemotherapy was performed perioperatively.

Macroscopically, the tumor measured 11 x 6,5 x 5cm, was multilobulated and firm; on cut surface, multiples cystic cavities filled with clear, viscous content were observed, intermixed with solid white areas and hard portions. In one of the sections, hair shafts were visible (Fig. 2).

Histologically, the mass contained a heterogenous cellular population, well-differentiated, originating from the three embryonic layers. The predominant component was ectodermal – well differentiated hair follicles, occasionally hyperplastic, surrounded by sebaceous and apocrine glands (Fig. 3A). Multiple foci of nervous tissue, composed of



Figure 1. (a) Three-month-old cat, note the tumor located in the right pre-retroauricular region measuring 7 x 5 cm. (b) After 3 months of evolution, a significant increase in mass can be noted.



Figure 2. Extragonadal teratoma in a kitten. (A) The mass is multilobulated, firm, in the periauricular cutaneous tissue. (B) On cut section, there are cystic and solid areas. *Inset*: hair shafts can be seen.

neuropil, neurons, ganglia, and nerves were also present (Fig. 3B-3C). Odontogenic epithelium forming multiple nests (Fig. 3D). From the endoderm, respiratory epithelium was present, sometimes surrounded by cartilage and bronchial glands (Fig. 4A). From the mesoderm, mesenchymal cells of various types were observed – adipocytes (Fig. 4B), bone tissue (Fig. 4C), muscle fibers, and fibrous tissue. Based on these histopathological findings, a diagnosis of extragonadal mature teratoma was made.

Serial sections of the tumor were submitted to immunohistochemistry (IHC) for pancytokeratin (panCK), vimentin, p40, and glial fibrillary acidic protein (GFAP). Details of the antibodies, antigen retrievals protocols, and positive controls are provided in Table 1. For all assays, NovoLink HRP-Polymer Detection System (Leica, https://www.leica-microsystems.com) was used as detection system, Romulin AEC (Biocare Medical, https://biocare.net) as chromogen, and hematoxylin as counterstain. As negative control, sections were incubated with Polymer Negative Control Serum (BioCare Medical).

There was strong cytoplasmic staining for pancytokeratin in the squamous stratified epithelium of the hair follicles (Fig. 5A), pseudostratified columnar epithelium of bronchial tree (Fig. 5B), odontogenic epithelium (Fig. 5C), and glandular epithelium (apocrine, sebaceous, and bronchial glands) (Fig. 5A-5B). Strong cytoplasmic staining for vimentin was observed in fusiform mesenchymal cells, adipose tissue (Fig. 5D), cartilage (Fig. 5E), muscle fibers, endothelial cells, nerves (Fig. 5F), osseous tissue (Fig. 5G) and fibrous tissue. There was strong nuclear immunolabeling for GFAP in astrocytes (Fig. 5H-5I) Additionally, positive nuclear immunoexpression of p40 in basal squamous cells of hair follicles (Fig. 6A – arrow), germ cells of sebaceous glands (Fig. 6A – arrow heads), basal cells of the bronchial tree (Fig. 6B) and odontogenic epithelium (Fig. 6C), and myoepithelial cells surrounding tracheobronchial glands.

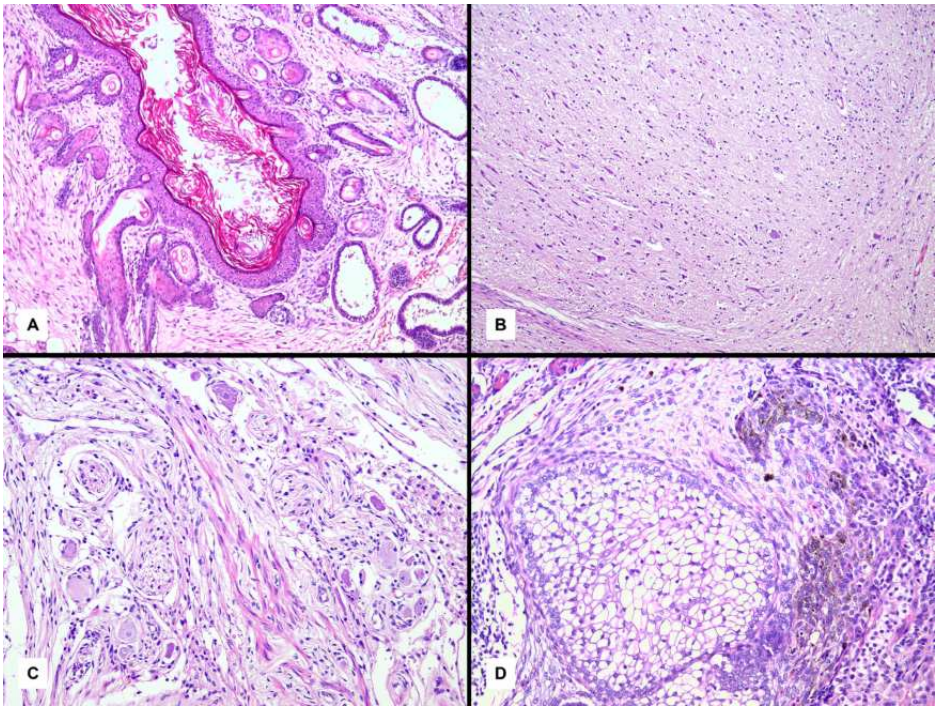

Figure 3. Extragonadal teratoma in a kitten. Histopathological findings – tissues originating from ectodermal embryonic layer. (A) Squamous cell epithelium forming hair follicles, surrounded by apocrine and sebaceous glands. (B-C) Well-differentiated nervous tissue, with neuropil, neurons, ganglia, and nerve fibers. (D) Island of odontogenic epithelium.

Table 1. Details of the antibodies, antigen retrievals, and positive controls used in immunohistochemistry.

Antibody	Antigen retrieval	Positive control
Pancytokeratin (mouse monoclonal, AE1/AE3, ready-to-use, Dako, www.agilent.com)	Citrate buffer, pH6.0 (40min/96°C)	Canine skin
Vimentin (mouse monoclonal, V9, 1:200 dilution, Invitrogen, www.thermofisher.com)	Citrate buffer, pH6.0 (40min/96°C)	Canine skin
p40 (mouse monoclonal, clone BC28, 1:300 dilution, Biocare Medical, https://biocare.net)	Citrate buffer, pH6.0 (40min/96°C)	Canine skin
Glial fibrillary acidic protein (polyclonal rabbit, 1:500 dilution, Dako, www.agilent.com)	Tris EDTA buffer (10min/100°C	Canine brain

Favor citar figura 4 no texto

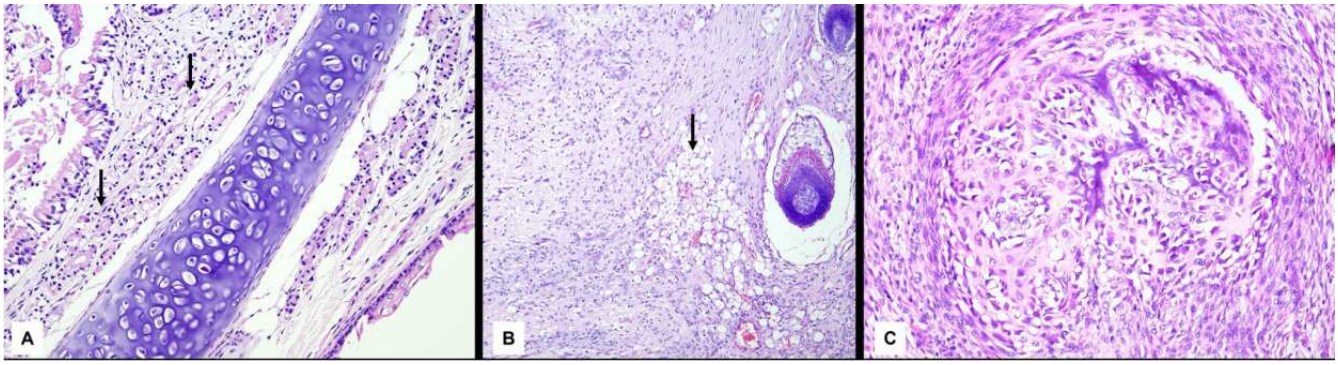

Figure 4. Extragonadal mature teratoma in a kitten. Histopathological findings. (A) From the mesodermal layer, respiratory epithelium surrounded by bronchial glands (arrow) and cartilage. (B) Adipose tissue (arrow) intermixed with a hair follicle (right side) and nervous tissue (left side). (C) From the endodermal layer, osseous tissue with mineralization (arrow).

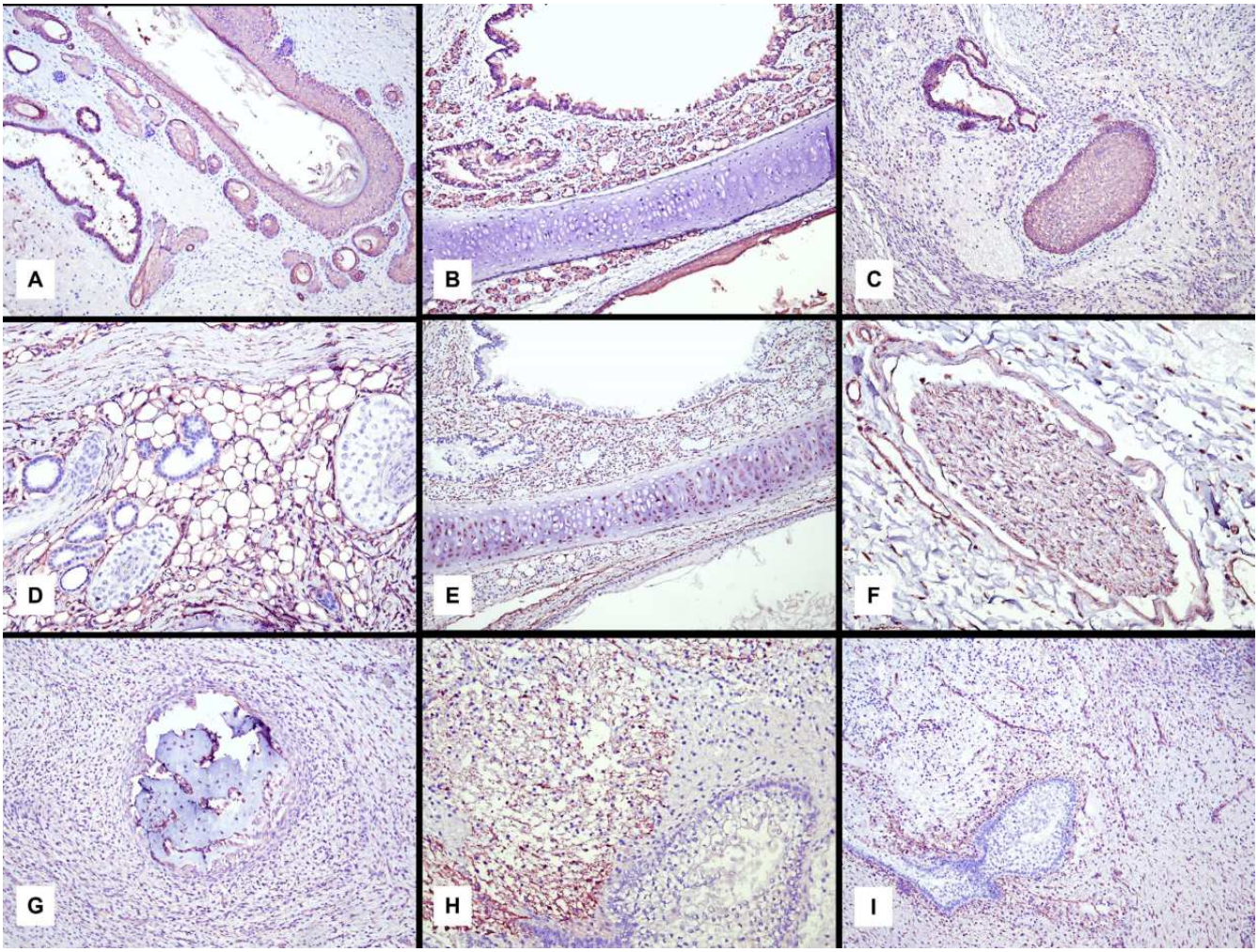

Figure 5. Mature extragonadal teratoma in a kitten. Immunohistochemical labelling (brown color) (A-C) Strong cytoplasmic pancytokeratin immunolabeling in squamous epithelium from hair follicles, apocrine and sebaceous glands (A), bronchial epithelium and bronchial glands (B) and odontogenic epithelium (C). (D-G) Strong cytoplasmic vimentin immunolabeling in adipocytes (D), bronchial cartilage (E), nerve and endothelium cells (F) and osseous tissue (G). (H-I) Strong nuclear GFAP immunolabeling in astrocytes.

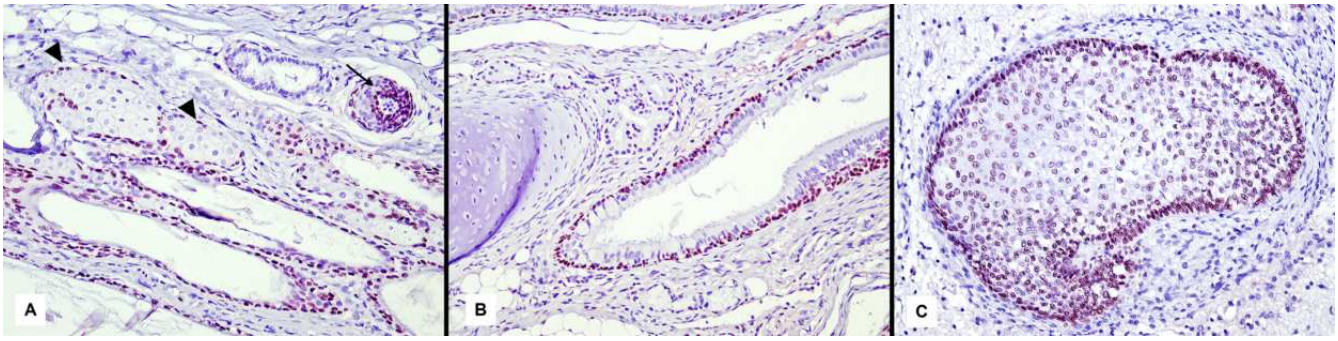

Figure 6. Mature extragonadal teratoma in a kitten. Strong nuclear p40 immunolabeling (brown color) in (A) basal squamous cells of hair follicles (arrow) and in germ cells of sebaceous glands (arrowheads), (B) basal cells of the bronchial tree, and (C) odontogenic epithelium.

Three months after surgery, there was already growth of defenses around the scar, as expected, the patient lost the right eyelid reflex, but had normal corneal reflex and facial movements.

Discussion

The diagnosis was based on histopathological findings, which were confirmed by the immunohistochemistry. The neoplasm was classified as a mature teratoma because it contained well-differentiated cells from all the three embryonal layers, with no histological evidence of immature cells. Furthermore, it was a well-demarcated mass without evidence of adjacent tissue invasion (2, 20).

At the time of the surgery, the kitten was 6-month-old, but by-month-old, the mass had already reached a significant size. Teratomas in cats less than 1 year old have been reported in the gonads (2), brain (4), skin and subcutaneous tissues (7, 14, 18, 19), and oral cavity (12). The occurrence of such tumors in young animals or shortly after puberty supports the hypothesis of fetal development of the neoplasm (1, 3). Although more common in young animals, teratomas have also been described in cats between 2 and 17 years (9, 10, 17, 20), but in most of these cases, the masses were intra-abdominal (affecting ovary or a cryptorchid testicle), which may result in a later diagnosis, as extragonadal tumors are more easily noticed by owners (19).

Macroscopically, the tumor in this case resembled those described in dog, cats and cattle – a multilobulated mass with both solid and cystic areas, sometimes containing hair follicles and keratin (2, 3, 7, 9, 14, 18, 20, 21). Microscopic findings in teratomas can vary widely because cells from two or three embryonal layers may be present (1, 7, 18). In this case, well-differentiated cells from all three layers were observed, with ectodermal component being the most predominant (hair follicles, sebaceous and apocrine glands, odontogenic epithelium, neural tissue), followed by mesodermal cells (adipose tissue, fibrous tissue, bone, muscle fibers and cartilage), and only respiratory epithelium from the endoderm was observed.

The surgical excision is curative in cases of mature teratoma (18) and even in those with immature components (7). Most teratomas exhibit benign behavior, are well-demarcated, and do not invade adjacent tissues, growing in an expansive manner, which make the clinicals signs noticeable only when the mass reaches a sufficient size to cause compression (2, 21). This can occur earlier depending on the location, for example, if the tumor develops in the brain (4). In some cases, especially in ovaries or in livestock teratomas, the tumor may be an incidental finding during reproductive evaluations (3, 8). In this animal, the tumor was not attached to adjacent tissues, and the clinical signs became evident only when the tumor reached a large size. Following removal, there was no recurrence. Due to injury to the facial nerve, the palpebral reflex was absent, but the nictitating membrane performed a protective function. The prescription of sodium hyaluronate 0.1% eye drops thrice a day aimed to protect the cornea. In a similar case, facial nerve injury resulted in the loss of palpebral reflex and the ability to blink (19).

In this case, the cytological diagnosis was squamous cell carcinoma. Although cytology is a common diagnostic tool for tumors, it can be inconclusive in cases of teratomas due to the cellular diversity present (14, 19). Histopathological examination is recommended for a definitive diagnosis; however, immature portions can be sometimes missed if only hematoxylin and eosin staining is used, so immunohistochemistry is helpful in identifying immature cells (7, 18). The immunolabeling in this case revealed only mature tissues.

Extragonadal teratoma should be considered as a differential diagnosis for cutaneous tumors in kittens under 1 year old. Histopathological analysis is usually conclusive, but immunohistochemistry allows for the identification of cellular origin and the detection of immature cells.

Data Availability

All the original contributions presented in this study are included in the article/supplementary material. Further inquiries can be directed to the corresponding author.

Author Contributions

Rayane Chitolina Pupin: Investigation, writing – original draft, writing – review and editing. **Jhony Ferreira Marcari**: investigation, writing – review and editing. **Danilo Carloto Gomes** Investigation, writing – review and editing. **Gabriela de Souza Silva**: investigation, writing – review and editing. **Larissa Correa Hermeto**: investigation, writing – review and editing. **Igor Ribeiro Santos**: investigation, resources. **Saulo Petinatti Pavarini**: investigation, resources. All authors have read and approved the final version of the manuscript.

Conflict of Interest

The authors declare no competing interests.

Generative AI Use Statement

The authors did not use generative artificial intelligence tools or technologies in creating or editing any part of this manuscript.

References

1. Agnew DW, MacLachlan NJ. Tumors of the genital system. In: Meuten DJ, editor. Tumors of domestic animals. 5th ed. Ames, Iowa: John Wiley & Sons Inc; 2017. p. 689-722.
2. Basaraba RJ, Kraft SL, Andrews GA, Leipold HW, Small D. An ovarian teratoma in a cat. Vet Path. 1998; 35: 141-144. doi: 10.1177/030098589803500208
3. Carluccio A, Zedda MT, Contri A, Gloria A, Robbe D, De Amicis I, Pau S. Immature ovarian teratomas in two heifers. Vet Ital. 2017; 53(4): 327-330. doi: 10.12834/VetIt.738.3603.2
4. Chénier S, Quesnel A, Girard C. Intracranial teratoma and dermoid cyst in a kitten. J Vet Diagn Invest. 1998; 10: 381-384. doi: 10.1177/104063879801000417
5. Fujimaki T. Central nervous system germ cell tumors: classification, clinical features, and treatment with a historical overview. J Child Neurol. 2009; 24(11): 1439-1445. doi: 10.1177/0883073809342127
6. Homer BL, Riggs MW. Cranial teratomas in two domestic ducks (Anas platyrynchos domesticus). Avian Dis. 1991; 35(4): 994-998.
7. Kegler K, Kröner B, Baumgärtner W, Wohlsein P. Feline coccygeal teratoma: immunohistochemical characterization of immature tissue components. J Comp Path. 2014; 151: 195-201. doi: 10.1016/j.jcpa.2014.04.016
8. Lefebvre R, Theoret C, Doré M, Girard C, Laverty S, Vaillancourt D. Ovarian teratoma and endometritis in a mare. Can Vet J. 2005; 46:1029-1033.
9. Machida Y, Michishita M, Wada M, Hori T, Kawakami E, Yoshimura H, Ohkusu-Tsukada K, Taya K, Takahashi K. Malignant oestrogen-producing teratoma in a cat. J Comp Path. 2017; 156: 178-182. doi: 10.1016/j.jcpa.2016.11.273
10. Miyoshi N, Yasuda N, Kamimura Y, Shinozaki M, Shimizu T. Teratoma in a feline unilateral cryptorchid testis. Vet Path. 2001; 38:729-730. doi: 10.1354/vp.38-6-729
11. Mutinelli F, Vascellari M. Thoracic teratoma in a White pekin duck (Anas platyrhinchos domesticus). Avian Dis. 2002; 46:493-496. doi: 10.1637/0005-2086.
12. Namiki K, Okada K, Shindo R, Kagawa Y. A case of immature teratoma with nephroblastic components in the oral cavity of a cat. J Vet Med Sci. 2023; 85(4): 420-424. doi: 10.1292/jvms.23-0023
13. Nunes MVL, Nakagaki KYR, Miranda DNP, Mesquita LES, Gomes TA, Moulin MRI, Wouters ATB, Wouters F, Raymundo DL, Varaschin MS. Mature intracranial teratoma with meningocele in a lamb. Cienc Rural. 2020; v.50:12. doi: 10.1590/0103-8478cr20200248
14. Ober CA, Taulescu M, Oana L, Bel L, Catoi C, Farcas L, Pestean C. An unusual case of a mature teratoma on the left perineal region of a young cat: surgical treatment and pathological description. Acta Vet Scand. 2013; 55:51. doi: 10.1186/1751-0147-55-51.
15. Pêgas GRA, Monteiro LN, Cassali GD. Extragonadal malignant teratoma in a dog – case report. Arq Bras. Med Vet Zootec. 2020; 72(1): 115-118. doi: 10.1590/1678-4162-10434
16. Ronchi A, Cozzolino I, Montella M, Panarese I, Marino FZ, Rossetti S, Chieffi P, Accardo M, Facchini G, Franco R. Extragonadal germ cell tumors: not just a matter of location. A review about clinical, molecular and pathological features. Cancer Med. 2019; 8: 6832-6849. doi: 10.1002/cam4.2195.
17. Sato T, Hontake S, Shibuya H, Shirai W, Yamaguchi T. A solid mature teratoma of a feline ovary. J Feline Med Surg. 2003; 5: 349-351. doi: 10.1016/S1098-612X(03)00050-0
18. Sirivisoot S, Siripara N, Arya N, Techangamsuwan S, Rungsisipat A, Kasantikul T. Case report: mature extragonadal teratoma at the proximal part of the tail in a kitten. Front Vet Sci. 2022; 9: 1003673. doi: 10.3389/fvets.2022.1003673.
19. Van Goethem B, Bosmans T, Chiers K. Surgical resection of a mature teratoma of the head of a young cat. J Am Anim Hosp Assoc. 2010; 46: mar/apr, p.121-126. doi: 10.5326/0460121.
20. Wray JD, Doust RT, McConnell F, Dennis RT, Blunden AS. Retrobulbar teratoma causing exophthalmos in a cat. J Feline Med Surg. 2008; 10: 175-180. doi: 10.1016/j.jfms.2007.06.016
21. Yamaguchi Y, Sato T, Shibuya H, Tsumagari S, Suzuki T. Ovarian teratoma with a formed lens and nonsuppurative inflammation in an old dog. J Vet Med Sci. 2004; 66(7): 861-864. doi: 10.1292/jvms.66.861.