Braz J Vet Pathol, 2026, vol. 19, e019011
DOI: https://doi.org/10.24070/bjvp.1983-0246.019011

BJVP
Brazilian Journal of Veterinary Pathology
ISSN 1983-0246

Case Report

Prolonged survival in a dog with unresectable exocrine pancreatic adenocarcinoma treated with toceranib phosphate: a case report

Patrick Antônio Sonaglio Civa[1], Carlos Eduardo Fonseca-Alves[2,3], Denner Santos dos Anjos[4*]

[1]Veterinary Practitioner, Civa Veterinary Oncology, Chapecó, SC, Brazil
[2]Institute of Health Sciences, Universidade Paulista (UNIP), Bauru, SP Brazil
[3]Department of Veterinary Surgery and Animal Reproduction, Universidade Estadual Paulista (UNESP), Botucatu, SP, Brazil
[4]Postdoctoral student, Department of Veterinary Surgery and Animal Reproduction, Universidade Estadual Paulista (UNESP), Botucatu, SP, Brazil

[*]**Corresponding author:** denner.anjosoncology@gmail.com
Submitted: November 12th, 2025. Accepted: March 27th, 2026.

Abstract

Canine pancreatic carcinoma is an uncommon and highly aggressive tumor usually detected at an advanced stage. This case report describes a dog with exocrine pancreatic adenocarcinoma that presented with diarrhea, vomiting, abdominal pain, and anorexia. Computed tomography (CT) revealed pancreatic enlargement with nodular formation in the body and left lobe of the pancreas. Resection was not feasible because of the tumor location, and an incisional biopsy was performed. Histopathology demonstrated large polygonal neoplastic cells arranged in a disorganized manner, forming clusters and acinar structures, consistent with exocrine pancreatic adenocarcinoma. As no effective medical treatment exists for this condition, a multikinase immunohistochemical panel was used to guide therapy. The panel revealed overexpression of the vascular endothelial growth factor receptor (VEGFR, Score 4+) and activation of the mitogen-activated protein kinase (MAPK/Erk1/2) pathway (score 3+). Based on these findings, toceranib phosphate was initiated at 2.75 mg on a Monday, Wednesday, Friday (MWF) schedule. This targeted therapy resulted in a partial response on ultrasound, with the pancreatic lesion decreasing from 2.63 × 2.89 cm to 1.75 × 1.56 cm after 66 days and further reducing to 1.11 × 1.40 cm at 122 days. From day 213 onward, the lesion was no longer detected on the follow-up ultrasound. However, complete remission cannot be confirmed without histopathological reassessment or advanced imaging such as computed tomography. The patient remains alive with a survival time of 484 days under ongoing monitoring. Despite this encouraging outcome, further studies are needed to evaluate the efficacy of tyrosine kinase inhibitors in the managenebt of canine exocrine pancreatic adenocarcinoma.

Keywords: Pancreatic adenocarcinoma, toceranib phosphate, multikinase panel, precision medicine.

Introduction

Canine pancreatic carcinoma is an uncommon (<0.5% of all cancers) and highly aggressive tumor that is frequently detected in the later stages of the disease (24). According to the World Health Organization (WHO), approximately 460,000 deaths due to this tumor occur annually, with 130,000 deaths occurring in Europe (10). Most malignant pancreatic tumors are of epithelial origin, with ductal and acinar carcinomas being the most common in canines and human patients (21). They predominantly affect older female dogs with a median age of eight to nine years and spaniels are overrepresented (3, 21).

The clinical signs are often vague and nonspecific, sometimes mimicking or occurring alongside pancreatitis, which complicates diagnosis (24). Common symptoms include weight loss, anorexia, abdominal pain, vomiting, and paraneoplastic alopecia (observed in cats) (14, 22). The less

common symptoms include abdominal distension, abdominal effusions resulting from peritoneal tumor implantation, and jaundice (14). In dogs, the primary treatment for resectable pancreatic tumors is surgery with partial pancreatectomy recommended for focal lesions, isolated masses, pseudocysts, and abscesses (5). However, tumor excision is not advised when neoplasia involves adjacent organs such as the liver, stomach, or duodenum or in cases of carcinomatosis (5). The effectiveness of adjuvant chemotherapy for pancreatic carcinoma remains unclear, as its infrequent occurrence and limited data in the literature complicate decision-making. Although the role of adjuvant chemotherapy in pancreatic carcinoma remains debatable, it is generally recommended due to the high rates of metastasis observed in cats, humans, and dogs (23).

Recent studies have explored the use of targeted therapies, such as toceranib phosphate (Palladia®), for treating pancreatic cancer in dogs. In a retrospective study involving eight dogs, one patient achieved a partial response, two had stable disease, and one experienced disease progression, resulting in an overall clinical benefit rate of 75% (16).

This study aimed to report a case of a dog diagnosed with unresectable exocrine pancreatic adenocarcinoma that achieved prolonged survival with toceranib phosphate (Palladia®) treatment. The therapeutic approach was guided by a multi-kinase panel, allowing targeted inhibition of the proliferation and angiogenesis pathways involved in tumor progression. This report highlights the potential benefits of precision medicine in veterinary oncology, and the role of tyrosine kinase inhibitors in managing aggressive canine pancreatic tumors.

Case description

The present case involved a client-owned dog, and all diagnostic and therapeutic interventions were performed with the owner´s informed consent. The study complied with the institutional and international guidelines for the care and use of animals in clinical research. Ethical approval was waived, because the case did not involve experimental procedures. A 13-years-old, female spayed Shih-Tzu dog presented with a clinical history of diarrhea, vomiting, abdominal pain, and anorexia. A previous study reported giardiasis, which was treated with fenbendazole treatment at another veterinary center. However, 30 days later, the patient restarted having the same gastrointestinal symptoms and was referred to a specialized service. On clinical examination, the patient exhibited abdominal pain, tachypnea, and 7% dehydration, with a temperature of 39.8 °C. Ultrasound examination revealed gastritis, colitis, bilateral adrenal hyperplasia, hepatomegaly, a splenic nodule consistent with myelolipoma, and a hyperechoic irregular pancreas with a hypoechoic structure in the pancreatic body region. In addition, a reactive mesentery was observed near the pancreas, suggesting pancreatitis. An enzyme-linked immunosorbent assay (ELISA) (Idexx® SNAP test) for Giardia was performed, and the results were negative. Hematological tests were also performed (Bio-2900 Vet; Alara), and the blood count showed a left shift (band neutrophils: 1,179 cells/mm³; reference interval [RI] 0 – 300 cells/mm³) without leukocytosis. The renal and hepatic biochemical panels were within the species-specific reference range.

The patient was hospitalized and received medication for the described abnormalities. Enrofloxacin was prescribed at a dose of 10 mg/kg intravenous (IV) once daily for 7 days, maropitant at a dose of 1 mg/kg subcutaneous (SC), once daily for 5 days, tramadol chloridate at a dose of 4 mg/kg SC three times daily for 5 days, dipyrone (metamizole) at a dose of 25 mg/kg SC three times daily for 5 days, dexamethasone at a dose of 0.2 mg/kg SC once daily, unique dose, and fluid therapy with lactated ringer's IV at replacement rate for two days.

Subsequently, the patient showed no abdominal pain, stable temperature, active behavior, good appetite, and no vomiting or diarrhea, and the left shift normalized (0/mm³ band neutrophils, reference interval RI 0 – 300). A Focused Assessment with Sonography for Trauma (FAST) ultrasound showed positive progression of the inflammatory condition of the pancreas, stomach, and colon.

Ultrasound-guided fine-needle aspiration cytology was performed for a nodular lesion in the body of the pancreas. Cytological examination revealed a population of moderately atypical epithelial cells organized in irregular arrangements, three-dimensional clusters, and a disorganized acinar pattern. On the basis of the observed changes, the primary differential diagnosis was exocrine pancreatic adenocarcinoma. However, given the inflammatory process associated with the pancreas, it cannot be ruled out that these changes are due to pancreatitis, as significant inflammatory processes can induce cellular metaplasia. An abdominal computed tomography (CT) scan showed an enlarged pancreas with two oval hypodense formations (Fig. 1) located in the body and left lobe of the pancreas, causing deformation of the lobe and displacement of the gastric outlet path. The lesions measured approximately 2.63 cm x 2.89 cm x 1.99 cm and 1.97 cm x 1.97 cm x 1.54 cm, respectively. Thoracic radiography revealed no abnormalities.

Considering the clinical presentation, an incisional biopsy of the pancreas was performed using the punch technique on both nodules for diagnostic confirmation via exploratory laparotomy. The pancreas was found to adhere to the stomach and omentum with associated purulent exudates (Fig. 2). The fluid was sent for bacterial culture and the results were negative.

Histopathological examination revealed large polygonal neoplastic cells with centrally located, hyperchromatic, round nuclei, and abundant eosinophilic cytoplasm, which were either vacuolated or contained zymogen granules. The

cells were arranged in a disorganized manner, forming cellular clusters and acinar structures, and the mitotic index was <1 per high-power field (40x). The diagnosis favored acinar exocrine pancreatic adenocarcinoma. Immunohistochemistry (IHC) was performed for diagnostic complementation and showed positive staining for cytokeratin 18 (CK18) and cytokeratin 19 (CK19), confirming the epithelial origin of the neoplasm.

Considering the diagnosis and the impossibility of surgical treatment due to the location of the neoplastic changes, a multikinase panel (Vet Precision®) obtained by IHC was used to assist in selecting the targeted therapy. The panel revealed (Fig. 3) overexpression of vascular endothelial growth factor receptor 2 (VEGFR-2) (score 4+) and the mitogen-activated protein kinase pathway (MAPK) (score 3+), along with reduced expression of platelet-derived growth factor receptor beta (PDGFR-β), human epidermal growth factor receptor (HER-2), and epidermal growth factor receptor (EGFR) (1+). Additionally, c-KIT was not expressed (negative). Based on these results, sorafenib could be the first-choice therapy because of its potential to inhibit MAPK, VEGFR-2, PDGFR-beta, and toceranib phosphate could be the second-choice treatment, acting as a VEGFR-2 and PDGFR-beta pathway inhibitor. For financial reasons, toceranib phosphate (Palladia®) was recommended at a dose of 2.75 mg on a Monday, Wednesday, Friday (MWF) schedule in association with continuous use of clopidogrel at a dose of 2 mg/kg *per os* once daily, given the risk of thrombosis due to the pancreatic tumor. The patient was followed up for 16 months and monitored using ultrasonography. Based on the Response Evaluation Criteria in Solid Tumors (RECIST) (9), the pancreatic lesion located in the body of the pancreas showed an initial partial remission, progressing to an apparent complete remission during follow-up. The baseline CT scan revealed a nodule measuring 2.63 × 2.89 × 1.99 cm, with the largest diameter of 2.89 cm. The first ultrasound, performed 66 days after initiation of toceranib phosphate (Palladia®), demonstrated a reduction to 1.75 × 1.56 cm (Fig. 4), consistent with partial response (PR). At 122 days, the lesion further decreased to 1.11 × 1.40 cm (Fig. 4), confirming sustained partial remission. On the third (213 days after treatment) and fourth ultrasound (346 days after treatment), the nodule in the pancreatic body was no longer visible. Although these findings meet ultrasound criteria for complete remission (CR), definitive confirmation requires histopathological reassessment and advanced imaging such as computed tomography (CT). The left pancreatic lobe is rarely characterized because of gastric gas accumulation, which limits the evaluation of additional lesions. A follow-up CT was not performed due to financial constraints. At the time of manuscript preparation, the patient was alive, with a survival duration of 484 days.

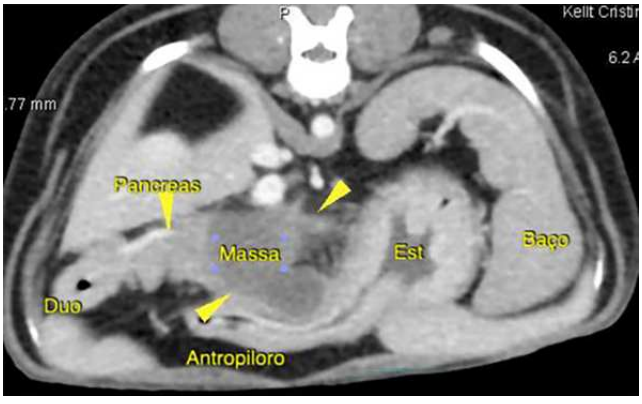

Figure 1. Two oval hypodense formations located in the body and left lobe of the pancreas causing deformation of the lobe and displacing the gastric outlet path, as assessed by CT scan of the abdomen.

Discussion

Exocrine pancreatic carcinoma is considered an aggressive neoplasm with high metastatic potential, with 78% of dogs presenting with metastatic lesions at the time of diagnosis, primarily in the liver and regional lymph nodes (20). However, pancreatic carcinomas can be silent, often presenting with nonspecific clinical signs, most commonly when large (20). This report describes diarrhea, vomiting, tachypnea, abdominal pain, anorexia, and dehydration, confirming non-specific conditions.

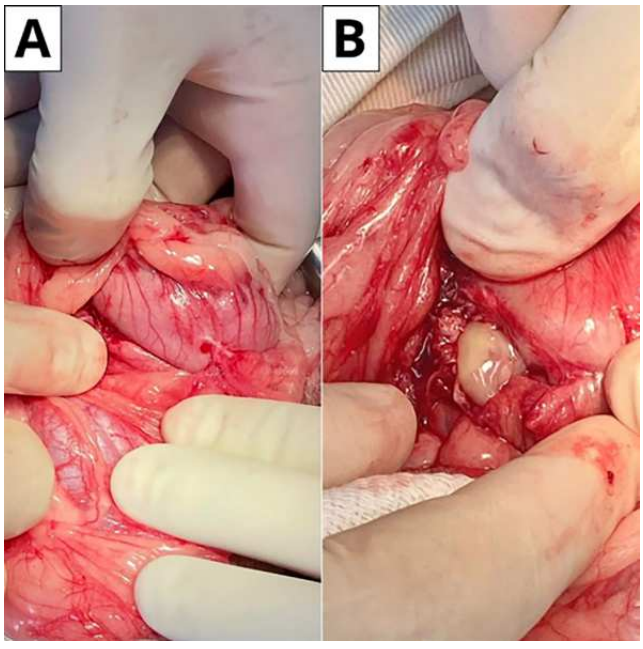

Figure 2. Exploratory laparotomy findings and pancreatic biopsy. (A) Dense adhesions between the pancreas and adjacent stomach/omentum. (B) Purulent exudate overlying a pancreatic nodule, from which incisional punch biopsies were obtained for histopathology.

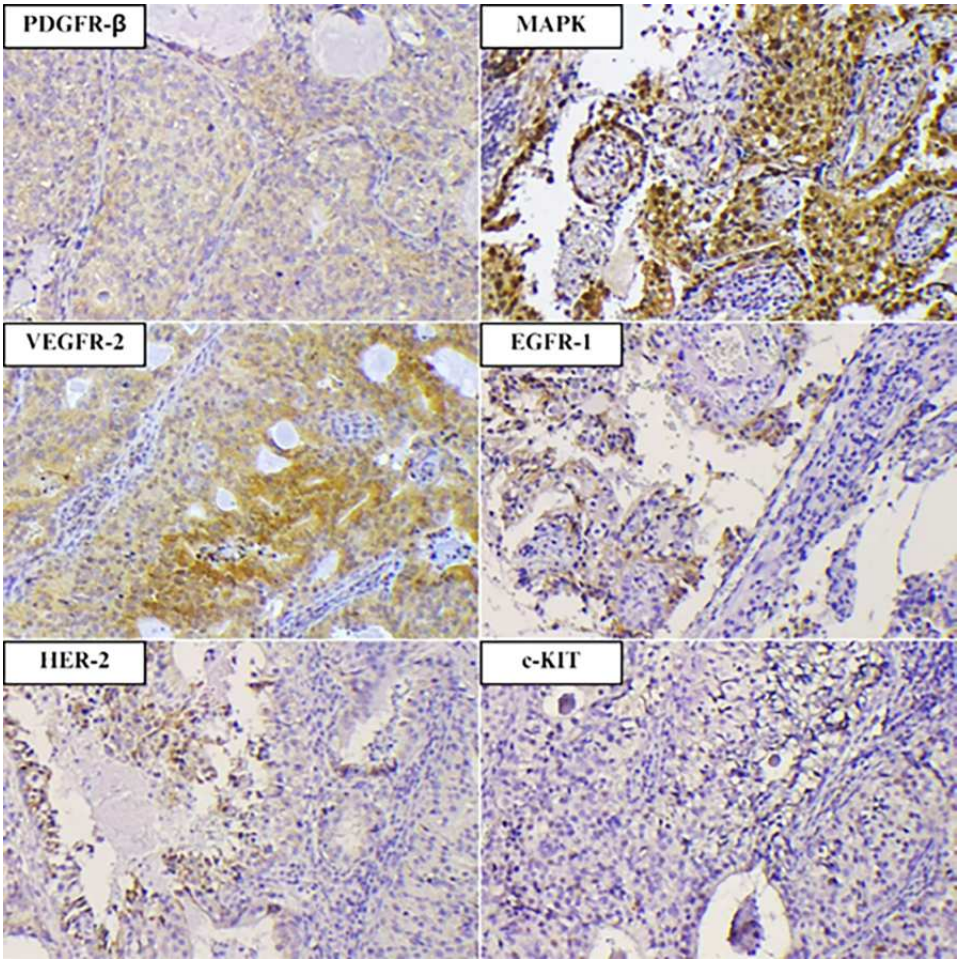

Figure 3. Immunoexpression of the main positive markers in canine exocrine pancreatic adenocarcinoma. Mitogen-activated protein kinase (MAPK) showing strong nuclear and cytoplasmic staining with a score of 3+ in neoplastic cells. Vascular endothelial growth factor receptor-2 (VEGFR-2) with diffuse and intense cytoplasmic staining (score 4+). Platelet-derived growth factor receptor beta (PDGFR-β) showing weak cytoplasmic and membranous staining with a score of 1+. Epidermal growth factor receptor-1 (EGFR-1) with weak membranous and cytoplasmic expression (score 1+) in neoplastic cells. Human epidermal growth factor receptor-2 (HER-2) with weak membranous staining (score 1+). No immunoexpression was observed for c-KIT (score 0).

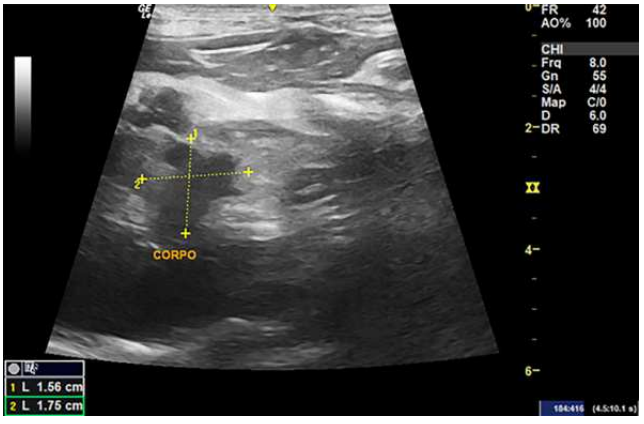

Figure 4. Ultrasonographic assessment of exocrine pancreatic carcinoma, highlighting an amorphous nodule with undefined margins, hypoechoic and irregular, measuring 1.75 x 1.56 cm, showing a partial response.

In cases of hepatic, peritoneal cavity, and regional lymph node involvement, surgery should generally not be performed (17). Total pancreatectomy or pancreaticoduodenectomy (Whipple's procedure) has been described in humans and dogs; however, it is associated with high surgical morbidity and mortality, with no significant improvement in cure rates, and is not advised (17). Despite the high metastatic rates, the patient did not show changes consistent with metastasis. Surgery was not performed because of the tumor's location in the body and the left lateral lobe of the pancreas, which contraindicated the procedure. Overall, pancreatic neoplasms arise predominantly in the right limb of the pancreas (6).

In humans, pancreatic carcinoma treatment includes surgery, chemotherapy, radiation therapy, and targeted therapy, depending on the stage of the disease and whether the mass is resectable (2, 20). In advanced stages, therapeutic options are limited (2). Palliative chemotherapy with gemcitabine and

paclitaxel is the only approved first-line treatment for patients in good general condition without significant comorbidities in humans (8). The role of radiation therapy in unresectable tumors remains controversial and there is no uniform recommendation for its use (8).

Increased expression of various tyrosine kinase receptors and their corresponding activating ligands has been observed in human pancreatic carcinoma, and this overexpression is associated with poor clinical outcomes (16). Notably, elevated EGFR levels are associated with advanced disease stages, reduced survival rates, and increased metastasis (18). Similarly, increased levels of proteins such as VEGF and its receptor VEGFR, as well as PDGF and its receptor PDGFR, have been implicated in tumor progression and resistance to chemotherapy (11, 12). In contrast, tumor expression showed decreased expression of both EGFR and PDGFR-β, which suggesting a less active pathway of progression.

Sunitinib is a tyrosine kinase inhibitor (TKI) that targets multiple receptors involved in tumor growth and angiogenesis, including VEGFR, PDGFR, and c-KIT (25). This drug has been specifically approved for the treatment of pancreatic neuroendocrine tumors, offering a therapeutic option for patients with advanced disease that is not amenable to surgery (25).

In veterinary medicine, toceranib phosphate (Palladia®) is a TKI that functions similarly to sunitinib at the molecular level. Both medications target key receptors involved in tumor growth and angiogenesis, including vascular endothelial growth factor receptor (VEGFR), platelet-derived growth factor receptor (PDGFR), and c-KIT (13, 15). By inhibiting these receptors, toceranib blocks the signaling pathways responsible for the tumor cell proliferation s and the formation of new blood vessels that nourish the tumor. These actions slow down or halt cancer progression (13, 15).

Recent studies have investigated the expression of tyrosine kinase receptors in canine solid tumors to guide targeted therapy. One study analyzed 87 canine tumors, including prostatic carcinomas, soft tissue sarcomas, mammary gland tumors, urothelial bladder carcinomas, and endocrine tumors. Immunohistochemistry was performed to assess the expression of HER-2, EGFR1, VEGFR-2, PDGFR-β, c-KIT, and ERK1/ERK2, which could inform personalized treatment strategies and potential therapeutic responses based on their expression (7).

Another study evaluated the use of toceranib phosphate (Palladia®) as a treatment for canine exocrine pancreatic carcinoma, highlighting its potential effectiveness in managing aggressive and typically chemotherapy-resistant cancers (16). The study involved 8 dogs, resulting in an overall clinical benefit rate of 75%. The median overall survival time for toceranib treatment was 89.5 days, with a range of 14–506 days, similar to our case report, which also reported a survival time of 484 days after treatment.

A retrospective study analyzed 23 dogs with a confirmed diagnosis of exocrine pancreatic carcinoma (20). The median survival time (MST) was only 1 day, with an average of 8 days, largely due to the high rate of euthanasia shortly after diagnosis. Treatment options were limited, with only five dogs undergoing surgery, and two of them received adjuvant therapy (chemotherapy and radiotherapy). None of the patients received toceranib phosphate (Palladia®) as treatment.

This case report showed a significant survival time with no evidence of regional or distant metastasis during the follow-up. However, this study has several limitations that must be considered. These include the study design (case report), the owner's refusal to perform a complete CT scan, and the absence of histopathological reassessment to confirm complete remission. The exclusive reliance on abdominal ultrasound for monitoring is another limitation, as its accuracy may be reduced by gastrointestinal content, small pancreatic size, and echogenicity similar to that of surrounding fat (1). In dogs with exocrine pancreatic disease, sensitivity can be as low as 56% (19). More recently, contrast-enhanced ultrasound has shown improved performance, with 100% sensitivity and 80% specificity for focal pancreatic lesions (4). These findings indicate that the residual or recurrent lesions may have remained undetected in this case. Although these results are promising, further studies are necessary to better assess the benefits of TKIs in the treatment of exocrine pancreatic carcinomas.

This case report demonstrates the potential benefits of targeted therapy with toceranib phosphate for the management of unresectable exocrine pancreatic adenocarcinoma in a dog. The use of a multikinase panel to guide treatment decisions enables personalized therapy, leading to a partial response and prolonged survival. Further studies are needed to validate the efficacy of tyrosine kinase inhibitors in treating pancreatic carcinoma and to explore their role in improving outcomes in dogs with this aggressive neoplasm.

Data Availability

All the original contributions presented in this study are included in the article/supplementary material. Further inquiries can be directed to the corresponding author.

Author Contributions

Patrick Civa, Denner Dos Anjos: Investigation, Data curation, Writing- Original draft preparation. **Patrick Civa, Carlos Fonseca-Alves, Denner Dos Anjos**: Conceptualization, Methodology, Formal analysis. **Patrick Civa, Denner Dos Anjos**: Conceptualization, Supervision, Writing- Reviewing and Editing. All authors have read and approved the final version of the manuscript.

Conflict of Interest

The authors declare no competing interests.

Generative AI Use Statement

The authors did not use generative artificial intelligence tools or technologies in creating or editing any part of this manuscript.

Funding

The authors declare no funding.

References

1. Avante ML, da Silva PDA, Feliciano MAR, Maronezi MC, Simões AR, Uscategui RAR, Canola JC. Ultrasonography of the canine pancreas. Rev MVZ Cordoba. 2018;23(1):6552-63. doi: 10.21897/rmvz.1249.
2. Bazzichetto C, Luchini C, Conciatori F, Vaccaro V, Di Cello I, Mattiolo P, Falcone I, Ferretti G, Scarpa A, Cognetti F, Milella M. Morphologic and molecular landscape of pancreatic cancer variants as the basis of new therapeutic strategies for precision oncology. Int J Mol Sci. 2020;21(22):8841. doi: 10.3390/ijms21228841.
3. Brown PJ, Mason KV, Merrett DJ, Mirchandani S, Miller RI. Multifocal necrotising steatites associated with pancreatic carcinoma in three dogs. J Small Anim Pract. 1994;35(3):129-32. doi: 10.1111/j.1748-5827.1994.tb03913.x.
4. Burti S, Zotti A, Rubini G, Orlandi R, Bargellini P, Bonsembiante F, Contiero B, Banzato T. Contrast-enhanced ultrasound features of focal pancreatic lesions in dogs. Vet Rec. 2022;191(8):e2080. doi: 10.1002/vetr.2080.
5. Cornell K. Pancreas. In: Tobias KM, Johnston SA, editors. Veterinary Surgery: Small Animal Philadelphia: Saunders; 2012. p.1659-73.
6. Dennis MM, O'Brien TD, Wayne T, Kiupel M, Williams M, Powers BE. Hyalinizing pancreatic adenocarcinoma in six dogs. Vet Pathol. 2008;45(4):475-83. doi: 10.1354/vp.45-4-475.
7. Dos Anjos DS, Civa PAS, Werner J, Vicente IST, Fonseca-Alves CE. Immunohistochemistry screening of different tyrosine kinase receptors in canine solid tumors-part i: proposal of a receptor panel to predict therapies. Int J Mol Sci. 2024;25(15):8438. doi: 10.3390/ijms25158438.
8. Ducreux M, Cuhna AS, Caramella C, Hollebecque A, Burtin P, Goéré D, Seufferlein T, Haustermans K, Van Laethem JL, Conroy T, Arnold D; ESMO Guidelines Committee. Cancer of the pancreas: ESMO Clinical Practice Guidelines for diagnosis, treatment and follow-up. Ann Oncol. 2015;26(Suppl 5):v56-68. doi: 10.1093/annonc/mdv295.
9. Eisenhauer EA, Therasse P, Bogaerts J, Schwartz LH, Sargent D, Ford R, Dancey J, Arbuck S, Gwyther S, Mooney M, Rubinstein L, Shankar L, Dodd L, Kaplan R, Lacombe D, Verweij J. New response evaluation criteria in solid tumours: revised RECIST guideline (version 1.1). Eur J Cancer. 2009;45(2):228-47. doi: 10.1016/j.ejca.2008.10.026.
10. Ferlay J, Ervik M, Lam F, Laversanne M, Colombet M, Mery L, Piñeros M, Znaor A, Soerjomataram I, Bray F. Global Cancer Observatory: Cancer Today. Lyon (FR): International Agency for Research on Cancer; 2024 [cited 2026 Apr 17]. Available from: gco.iarc.who.int/today
11. Itakura J, Ishiwata T, Shen B, Kornmann M, Korc M. Concomitant over-expression of vascular endothelial growth factor and its receptors in pancreatic cancer. Int J Cancer. 2000;85(1):27-34. doi: 10.1002/(sici)1097-0215(20000101)85:1<27::aid-ijc5>3.0.co;2-8.
12. Kim DK, Jeong J, Lee DS, Hyeon DY, Park GW, Jeon S, Lee KB, Jang JY, Hwang D, Kim HM, Jung K. PD-L1-directed PlGF/VEGF blockade synergizes with chemotherapy by targeting CD141+ cancer-associated fibroblasts in pancreatic cancer. Nat Commun. 2022;13(1):6292. doi: 10.1038/s41467-022-33991-6.
13. Lai YY, Horta RDS, Valenti P, Giuliano A. Retrospective safety evaluation of combined chlorambucil and toceranib for the treatment of different solid tumours in dogs. Animals (Basel). 2024;14(23):3420. doi: 10.3390/ani14233420.
14. Linderman MJ, Brodsky EM, de Lorimier LP, Clifford CA, Post GS. Feline exocrine pancreatic carcinoma: a retrospective study of 34 cases. Vet Comp Oncol. 2013;11(3):208-18. doi: 10.1111/j.1476-5829.2012.00320.x.
15. London CA, Hannah AL, Zadovoskaya R, Chien MB, Kollias-Baker C, Rosenberg M, Downing S, Post G, Boucher J, Shenoy N, Mendel DB, McMahon G, Cherrington JM. Phase I dose-escalating study of SU11654, a small molecule receptor tyrosine kinase inhibitor, in dogs with spontaneous malignancies. Clin Cancer Res. 2003;9(7):2755-68.
16. Musser ML, Johannes CM. Toceranib phosphate (Palladia) for the treatment of canine exocrine pancreatic adenocarcinoma. BMC Vet Res. 2021;17(1):269. doi: 10.1186/s12917-021-02978-8.
17. Neoptolemos JP, Urrutia R, Abbruzzese JL, Büchler MW, editors. Pancreatic cancer. Berlin: Springer-Verlag; 2010. 1390p.
18. Oliveira-Cunha M, Newman WG, Siriwardena AK. Epidermal growth factor receptor in pancreatic cancer. Cancers (Basel). 2011 Mar 24;3(2):1513-26. doi: 10.3390/cancers3021513.

19. Pelligra T, Puccinelli C, Marchetti V, Citi S. Ultrasonographic findings of exocrine pancreatic insufficiency in dogs. Vet Sci. 2022;9(8):407. doi: 10.3390/vetsci9080407.
20. Pinard CJ, Hocker SE, Weishaar KM. Clinical outcome in 23 dogs with exocrine pancreatic carcinoma. Vet Comp Oncol. 2021;19(1):109-114. doi: 10.1111/vco.12645.
21. Selmic LE. Hepatobiliary neoplasia. Vet Clin North Am Small Anim Pract. 2017;47(3):725-735. doi: 10.1016/j.cvsm.2016.11.016.
22. Tasker S, Griffon DJ, Nuttall TJ, Hill PB. Resolution of paraneoplastic alopecia following surgical removal of a pancreatic carcinoma in a cat. J Small Anim Pract. 1999;40(1):16-9. doi: 10.1111/j.1748-5827.1999.tb03248.x.
23. Weiss LM, Mezzomo DG, Cony FG, Jung J, Sonne L, Driemeier D, Costa DV. Adenocarcinoma pancreático em um gato. Acta Sci Vet. 2023;51(Suppl 1):877. doi:10.22456/1679-9216.125204.
24. Withrow SJ, Vail DM, Page RL. Exocrine pancreatic carcinoma. In: Withrow and MacEwen's Small Animal Clinical Oncology. 5th ed. Elsevier Saunders; 2013. p. 401.
25. Yao JC, Shah MH, Ito T, Bohas CL, Wolin EM, Van Cutsem E, Hobday TJ, Okusaka T, Capdevila J, de Vries EG, Tomassetti P, Pavel ME, Hoosen S, Haas T, Lincy J, Lebwohl D, Öberg K; RAD001 in Advanced Neuroendocrine Tumors, Third Trial (RADIANT-3) Study Group. Everolimus for advanced pancreatic neuroendocrine tumors. N Engl J Med. 2011;364(6):514-23. doi: 10.1056/NEJMoa1009290.