BJVP
Brazilian Journal of Veterinary Pathology

Case Report

Squamous cell carcinoma of ear in an Indian water buffalo *(Bubalus bubalis)*

V. Rama Devi [1 *], G. Veeraiah [2], P. Annapurna [1]and S. Estheru [1]

[1]Department of Veterinary Pathology, NTR College of Veterinary Science, Gannavaram-521102 , A.P , India.
[2] Veterinary Hospital, Jaggaiahpet, A.P, India
***Corresponding author**: V. Rama Devi – Depart. of Veterinary Pathology, NTR College of Veterinary Science, Gannavaram-521102 , A.P , India.
E.mail: vrdpath@yahoo.com

Submitted February 5th 2010, Accepted April 30th 2010

Abstract

A nine years old, Graded Murrah she buffalo was presented to local Veterinary dispensary with clinical signs of raised elevations of growths on the pinna of right ear near its base and lateral aspects showing ulceration, necrosis, scales, crusts and scabs. Histopathologically, the tissue sections from the growth revealed groups, islands or cords of neoplastic squamous epithelium with epithelial pearls at some places. By immunohistochemistry, proliferating epithelial cells were positive for cytokeratin and expressed PCNA. Based on gross, histologic and immunohistochemical findings, the growth was diagnosed as cutaneous squamous cell carcinoma of ear.

Key Words: Indian water buffalo, ear, squamous cell carcinoma, histopathology, immunohistochemistry

Introduction

Squamous cell carcinoma is a malignant tumor of epidermal cells in which the cells show differentiation to keratinocytes. In horses and cattle, squamous cell carcinoma occurs primarily at mucocutaneous junctions, particularly the eyelids (2). In the cat, the most common sites are the pinna, eyelids and planum nasale and in the dog, the tumor most frequently occurs on the head, abdomen, fore limbs, rear limbs, perineum and digits. In sheep the ears are affected (2). Solar radiation is an etiological factor in squamous cell carcinoma in the ears and nose of white cats, on the perineum and ears of Angora goats in Africa and on the eyelids of cattle. Mechanical irritations, injuries and burns can also lead to squamous cell carcinoma (9). There are reports of squamous cell carcinoma of eye (8) and skin at the dorsal area of neck (3) in buffaloes and involving three unusual sites viz. right ischeorectal fossa, left vulval labium and right thoracic skin in cattle (1).

In the present paper, squamous cell carcinoma of skin in an Indian she buffalo *(Bubalus bubalis)* involving the pinna near the base of the right ear is described.

Case Report

A nine years old, Graded Murrah she buffalo was presented to local veterinary dispensary with clinical signs of raised elevations of growths on the pinna of right ear near its base and lateral aspects having ulcerations, necrosis, scales, crusts and scabs (Fig. 1). The animal was treated with streptopenicillin and routine dressing without success. Then part of the ear was removed surgically. However, there was recurrence of growths after 20 days and the animal was culled by the owner. The tissue pieces of growths were sent in 10% formalin for histopathological diagnosis to NTR College of Veterinary Science, Gannavaram and they were processed routinely and the sections were stained with H&E.

Histologically, the tissue sections showed thickening and hyperkeratosis of the epidermis. Extending into the dermis, there were cords, islands or groups of neoplastic epithelial cells having squamous cell differentiation and were separated by fibrous connective tissue. In some areas, there was extensive keratinization with formation of distinct epithelial pearls (Fig. 2). The neoplastic cells had large, hyperchromatic vesicular nuclei with prominent nucleoli and abundant cytoplasm. Mitotic figures were numerous. Few giant cells were also evident. At the

 All rights reserved 2007.

margins of the neoplasm, inflammatory cells mostly neutrophilic infiltration was also noticed. Immunohistochemical staining of the sections with antibody to cytokeratin (N1590, Dako) and PCNA (M0879, Dako) was carried out using Super sensitive polymer -HRP detection kit (Bio-Genex). On immunostaining, the neoplastic cells revealed positive cytokeratin staining (Fig. 3) and also exhibited strongly positive nuclear immunolabelling for PCNA (Fig. 4).



Fig. 1: Water buffalo with squamous cell carcinoma in the ear. Note crusty elevated growths on the pinna of the ear.

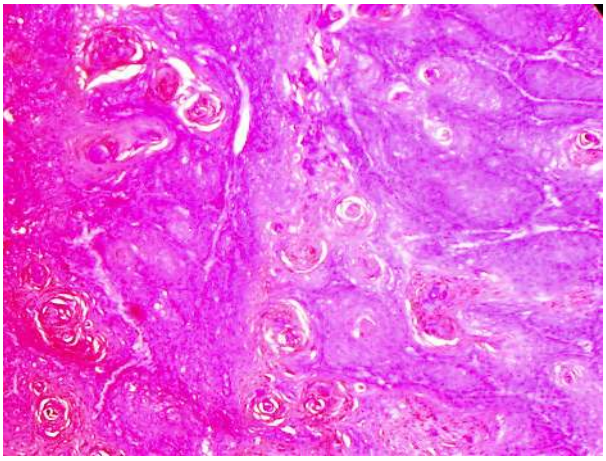

Fig. 2: Squamous cell carcinoma in a water buffalo. Note the neoplastic cells with horn pearls formation. H&E, x100

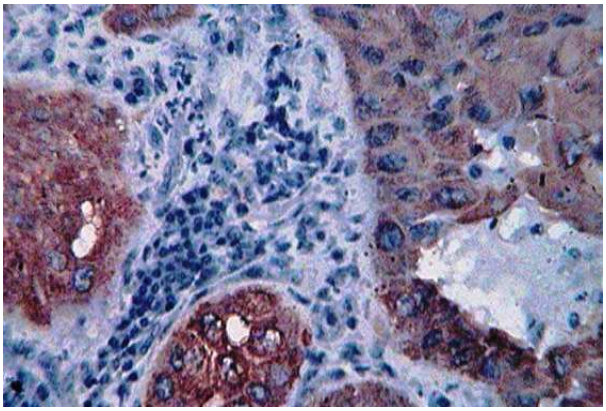

Fig. 3: Squamous cell carcinoma in a water buffalo. Note pancytokeratin positive cells, Immunostaining, x100.

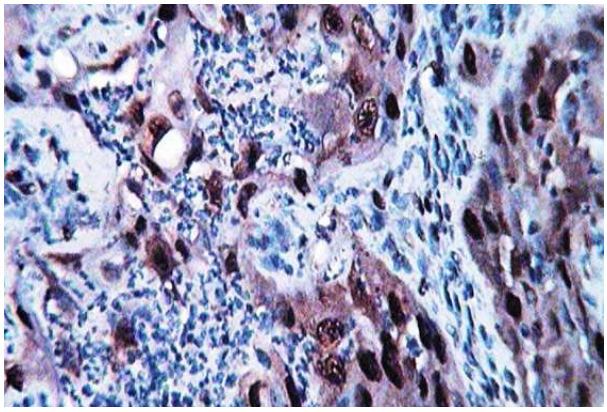

Fig. 4: Squamous cell carcinoma in a water buffalo. Cells positive for PCNA . Immunostaining, x400

Discussion

Squamous cell carcinoma is a common tumor among the cattle in India affecting the horn and the eye (6). It is found on skin of animals in various locations and melanin is protective against the actinic rays of sun. In areas where pigmentation is deficient squamous cell carcinoma has been seen. (6). Solar dermatosis is the first recognizable change at mucocutaneous junctions or on the skin that is sparsely haired and lacks pigment (2). Erythema, edema and scaling are followed by crusting, scaling and thickening of the epidermis with subsequent ulceration. As the tumor becomes invasive of the dermis, the lesion feels more indurated (2). There are reports of squamous cell carcinoma involving various parts of the body in animals (1, 3, 4, 5, 7, 8). There were scanty reports of squamous cell carcinoma of ear in buffaloes, except one reported on vertical ramus of mandible near the base of the left ear in a she buffalo (7). In the present case, the neoplasm specifically involved the pinna near the base of the right ear and to the authors knowledge, this is the first report of its kind in Indian buffaloes. Grossly, the neoplastic growths exhibited ulceration, necrosis and scaling. Microscopically, cords, islands and groups of neoplastic epithelial cells were noticed with distinct epithelial pearls at some places as described by previous authors (2, 6, 7, 8, 9). On immuno-histochemical staining, the cells were found positive to cytokeratin further revealing that the tumor was squamous cell carcinoma and several neoplastic cells expressed positive PCNA staining.

In the present case, solar radiation can be attributable as etiological factor of squamous cell carcinoma of ear in the buffalo.

References

1. FAZILI MR., BUCHOO BA., DARZI MM., BHATTACHARYA HK. Bovine squamous cell carcinoma at unusual sites: a report of 3 cases. *Indian J.Vet.Surg*. 2008,2:139-140.
2. GOLDSCHMIDT MH., HENDRICK MJ. *Tumors of skin and soft tissues.* MEUTEN DJ Ed. *Tumors*

of Domestic animals. 4 ed. Iowa: Iowa State Press, 2002:45-117.

3. KOHLI RN., MASHADI AG. Squamous cell carcinoma in an Iranian buffalo. *Indian Vet.J*.2008, 85:555-556.
4. MARDER MZ., CUMMINGS DW., ZEGARELLI DJ., NEUSCHAEFER K., PULSE CL. Squamous cell carcinoma in an American Bison (Bison bison bison).*Vet.Pathol*.2000,37:343-345.
5. MAYER YH., LINN MN., DICKINSON KA., CARR RM. A dog with squamous cell carcinoma in the middle ear. *Canadian Vet. J*.2008,49:877-879.
6. SASTRY GA. *Veterinary Pathology*. 6ed. CBS Publishers and Distributors, Delhi, 1983:247-249.
7. SINGH NP, RAI RB, VARSHNEY AC, SINGH D. A note on squamous cell carcinoma of ear in a she buffalo. *Indian J. Vet. Surg*.1982, 4:81-82.
8. SIVASEELAN S., BALASUBRANMANIAM GA., SRINIVASAN P., BALACHANDRAN P., DHARMACEELAN S. Squamous cell carcinoma of eye in a she buffalo. *Tamil Nadu J. Vet & Ani. Sci*.. 2008,4:117-118.
9. WEISS E., FRESE K. Tumors of the skin. *Bull. wld. hlth. org*.1974,50:79-100.

Brazilian Journal of Veterinary Pathology. www.bjvp.org.br . All rights reserved 2007.