Braz J Vet Patho, 2026, vol. 19, e019014
DOI: https://doi.org/10.24070/bjvp.1983-0246.019014

BJVP
Brazilian Journal of Veterinary Pathology
ISSN 1983-0246

Case Report

Histological heart lesions resembling myocardial dysplasia in a Guiana Dolphin (*Sotalia guianensis*) necropsied on the coast of Ceará, Brazil

Fernanda Menezes de Oliveira e Silva[1]*, João Ricardo Sales Rocha Filgueiras[1], Vitor Luz Carvalho[2]

[1]Laboratório de Histopatologia Animal, Centro de Ciências da Saúde (CCS), Universidade de Fortaleza (UNIFOR), Fortaleza, CE, Brazil
[2]Programa de Mamíferos Marinhos (PMM), Associação de Pesquisa e Preservação de Ecossistemas Aquáticos (AQUASIS), Caucaia, CE, Brazil

*Corresponding author: fernanda.menezes@unifor.br
Submitted: November 19th, 2025. Accepted: April 17th, 2026.

Abstract
Myocardial dysplasia, also known as arrhythmogenic right ventricular cardiomyopathy (ARVC), is a degenerative condition characterized by the progressive replacement of the myocardium by fibroadipose tissue, impairing cardiac electrical conduction and predisposing to arrhythmias and sudden death. Although well described in humans and in certain canine breeds, such as Boxers, it is rarely reported in veterinary medicine, especially in marine mammals. This study describes a case of a Guiana dolphin (*Sotalia guianensis*), stranded on the coast of Ceará, Brazil, which underwent necropsy and histopathological analysis, revealing replacement of myocardial tissue by adipose and fibroadipose tissue in the free wall of the right ventricle, with extension to the subendocardial region, without signs of myocarditis. Despite sampling limitations, the observed lesion pattern is consistent with ARVC-like changes and should be interpreted with caution, given the possibility of physiological lipomatosis in cetaceans, which has not yet been described in this species. These findings suggest that patterns similar to those observed in other species may occur in cetaceans, contributing to the understanding of cardiac diseases in this group and reinforcing the importance of detailed histopathological evaluation in stranded marine animals. Furthermore, the need for additional studies is highlighted, especially in regions under significant anthropogenic influence.

Keywords: arrhythmogenic dysplasia, cardiomyopathy, cetaceans, dolphin, heart.

Introduction

Myocardial dysplasia, also known as arrhythmogenic right ventricular cardiomyopathy (ARVC) or arrhythmogenic right ventricular dysplasia, is a pathology that can affect both humans and animals. It is characterized as a degenerative disease in which the striated cardiac muscle tissue is gradually replaced by well-differentiated fibroadipose tissue within the myocardial layer of the heart, which may or may not cause cardiomyocyte necrosis or apoptosis (4, 10). In human medicine, ARVC is the leading cause of sudden cardiac death among young Americans (~17%) (22).

This replacement of cardiomyocytes by adipose cells significantly alters the heart's electrical impulses, promoting arrhythmias and impaired contractility, which can lead to systemic effects such as organ hypoperfusion and respiratory distress, potentially resulting in sudden death (3). Because it is rarely reported in veterinary medicine, the pathogenesis of myocardial dysplasia in animals remains unclear. However, it is believed to have an autosomal dominant inheritance pattern. In Boxer dogs aged between two and eight years, this condition is commonly observed and has been associated with genetic traits (3, 10, 12).

Other breeds in which right ventricular cardiomyopathy has been sporadically reported include Shar-Pei, Fila

CC BY

Brasileiro, Siberian Husky, Labrador Retriever, English Bulldog, Bullmastiff, and Dachshund (5, 15, 16, 17, 18, 20).

In marine animals, particularly dolphins of the genus *Tursiops*, cardiac pathologies have been observed, often due to oil exposure. Animals exposed to contaminated areas may develop myocardial fibrosis of varying severity, with the most severe lesions observed in older individuals. Furthermore, in cases of clinical heart failure, moderate to severe interstitial fibrosis is commonly identified upon histopathological examination (11).

Another study on cardiac pathologies was conducted on one bottlenose dolphin (*Tursiops truncatus*) and nine striped dolphins (*Stenella coeruleoalba*) along the northeastern coast of Italy. It described significant macroscopic and microscopic cardiac alterations, along with changes in other organs (21). However, the presence of myocardial dysplasia or ARVC-like lesions in odontocetes of any species has not yet been reported in the literature. Therefore, the aim of the present study is to report the occurrence of lesions consistent with arrhythmogenic right ventricular dysplasia in a Guiana dolphin (*Sotalia guianensis*) and to describe the histopathological alterations observed in the individual.

Case description

A young female Guiana dolphin (*S. guianensis*) was found dead, stranded in the municipality of Fortaleza, Ceará, Brazil. The animal, weighing approximately 40 kg (88.2 lb) and measuring 130 cm (51.2 in) in length, showed signs of desiccation and was not accompanied by any other adult or juvenile individual of its species. There was no known prior history and, after species identification, a necropsy was performed in accordance with all appropriate procedures.

During necropsy, the main anatomopathological finding was multiple small, whitish-yellowish areas distributed throughout the myocardium in the apical region, involving the walls of both the left and right ventricles. For this reason, multiple heart fragments were collected, given the segmental nature of the lesions. Thus, a multi-site sampling of the heart was performed, including the free walls of the right and left ventricles and the interventricular septum, without targeted histological evaluation of the cardiac conduction system structures. Upon sectioning the organ, a change in tissue consistency was observed, with the tissue appearing firmer and paler. The samples were fixed in 10% buffered formalin and sent to the laboratory for histopathological analysis.

The sample was processed using conventional histological techniques: dehydration in increasing concentrations of ethanol (70%, 80%, 95%, and 100%), clearing in xylene, and subsequent infiltration in paraffin heated to 56 °C. After embedding in paraffin, the material was sectioned at 4 µm using a semiautomatic microtome. The histological slides were stained with Hematoxylin and Eosin (H&E) and Masson's Trichrome, enabling evaluation of tissue morphology and cellular structure under the microscope.

Macroscopically, the heart showed the apical region of the ventricles with areas of whitish discoloration and slightly firm texture, interspersed with the remaining myocardium, suggesting partial replacement of the muscular tissue (Figure 1). These alterations were more pronounced in the walls of both the right and left ventricles, forming small islands of abnormal tissue distributed throughout the apical region. The trabeculae carneae were more severely affected than the papillary muscles, with lesions predominantly concentrated in the apex.

Microscopically, hematoxylin and eosin (H&E) staining revealed significant alterations in the subendocardial area and extending to the epicardium, characterized by partial replacement of the myocardium with adipose tissue, consistent with a metaplastic process of striated cardiac muscle (Figure 2A). Masson's trichrome staining (Figure 2B) identified vacuoles consistent with adipocytes interspersed among the remaining cardiomyocytes, without evidence of inflammatory infiltrate or necrosis, suggesting a chronic, non-inflammatory degenerative process, with adipocytes frequently associated with connective fibers. Structures of the conduction system, such as the sinoatrial node and Purkinje fibers, were not identified.

Furthermore, Masson's trichrome staining demonstrated that dense connective tissue associated with adipocytes was distributed throughout the myocardium, forming strands or islands of fibroadipose tissue intercalated among preserved cardiac muscle fibers (Figure 2C). Similar findings were observed with H&E staining, corroborating the extent of the alterations (Figure 2D). These pathological findings are consistent with the morphological features of lesions observed in myocardial dysplasia, particularly the fibroadipose variant, involving the apical region and the right ventricle, with predominance in the subendocardial region.



Figure 1. Heart of *Sotalia guianensis*. Sagittal section showing multiple whitish areas (arrowheads) in the apical region, affecting both ventricular walls and extending toward the interventricular septum. The trabeculae carneae are more severely affected than the papillary muscles, with lesions predominantly located in the apical region.

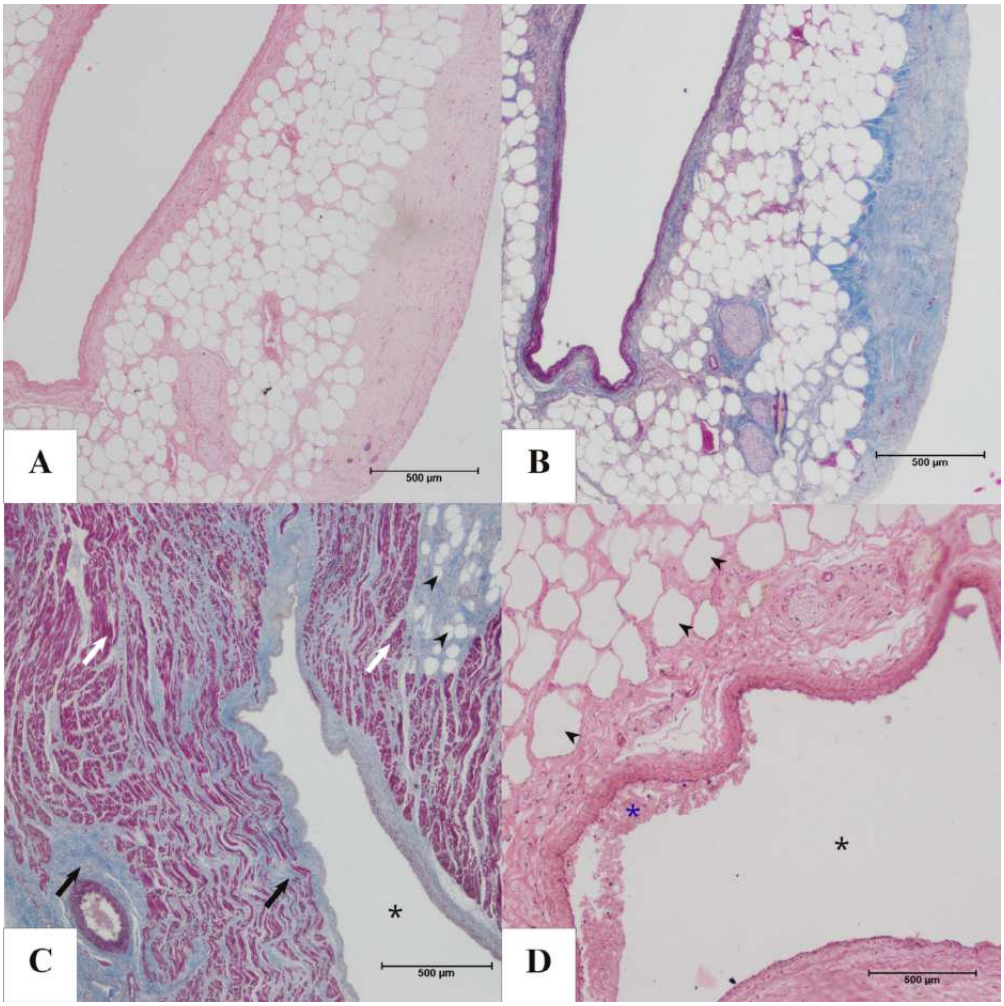

Figure 2. Photomicrographs of the heart of *Sotalia guianensis*. Bar = 500 µm. A) Right ventricle: Disorganization of myocardial fibers and alteration of the usual histological architecture of the myocardium (H&E, 100×). B) Right ventricle: Cardiac muscle showing disorganization of myocardial fibers and loss of the normal histological arrangement of the myocardium (Masson's trichrome, 100×). C) Left ventricle: Presence of fibrous connective tissue (black arrows) interspersed among myocardial fibers (white arrows), forming non-contractile tracts within the myocardium, among which adipose tissue mixed with fibrous tissue is observed (arrowheads) (Masson's trichrome, 100×). D) Septum: Presence of adipose tissue (arrowheads). Adherent clots are observed on the endocardium (blue asterisk) and free blood material within the lumen (black asterisk) (H&E, 200×).

Discussion

Histopathological findings revealed involvement of the apical region of both ventricles, characterized by replacement of myocardial tissue with dense fibrous connective and adipose tissue, predominantly affecting the subendocardial region with variable extension toward the epicardium. The presence of fibrofatty tissue was also observed in the trabeculae carneae, with no evidence of an inflammatory process indicative of myocarditis. The altered tissue identified microscopically corresponded to the pale areas observed macroscopically during the animal's necropsy. Taken together with the anatomical and microscopic findings and the distribution of the lesions, the condition is compatible with arrhythmogenic cardiomyopathy with apical predominance or myocardial dysplasia (3, 4, 10, 15, 16).

The replacement of striated cardiac muscle tissue by fibroadipose tissue, as observed in ARVC, creates islands of non-contractile tissue that disrupt electrical conduction, frequently leading to arrhythmias. In this pathology, physical activity can act as a mechanical stressor on the myocardium, promoting the onset of arrhythmias and the development of heart failure, potentially culminating in sudden death (3, 5). In this context, structures of the cardiac conduction system, such as the atrioventricular node and Purkinje fibers, play a central role in the arrhythmogenic mechanisms associated with cardiomyopathies within the ARVC spectrum (4, 15, 18). In the present case, although fibroadipose lesions were observed in the myocardium, the absence of targeted histological evaluation of the cardiac conduction system, including the sinoatrial node and Purkinje fibers, represents a key limitation. Consequently, it is

not possible to determine whether these morphological changes would have caused primary disturbances in cardiac electrical conduction or contributed to arrhythmogenesis, which is a central feature of ARVC in both humans and animals.

Myocardial dysplasia, currently referred to as arrhythmogenic right ventricular cardiomyopathy, usually presents in its classic form, in which the left ventricle and atria remain functionally normal. However, both ventricles may be affected, particularly the outer third of the myocardium and the right side of the interventricular septum (4, 16).

There are two recognized patterns of this disease: the fatty pattern, characterized by the replacement of cardiomyocytes by adipocytes forming scattered islands or strands of adipose tissue within the myocardium, predominantly in the right ventricle, and possibly associated with mild fibrosis; and the fibroadipose pattern, defined by focal to diffuse replacement of the myocardium by dense adipose and fibrous tissue (4). In the present report, the observed pattern was the fibroadipose pattern, evidenced by the concurrent presence of fibrous and adipose tissue, representing the characteristic morphology of this form of the disease.

The main pathological characteristic of ARVC in humans is the progressive loss of right ventricular myocardium replaced by adipose or fibroadipose tissue. In veterinary medicine, ARVC has been observed primarily in the right ventricular free wall. Occasionally, the left ventricle may also be involved, but this has only been reported in Boxer and Shar-Pei dogs (4, 10, 16, 19, 22). The disease's pathogenesis is not fully established, but it is believed to be genetic, with autosomal dominant inheritance in both humans and Boxers. Over 50 gene mutations have been associated with ARVC in humans, including mutations in the RYR2 gene, which encodes the cardiac ryanodine receptor — the main calcium channel in cardiac muscle — and the DSP gene, responsible for desmoplakin (4). However, in animals, no definitive genetic etiology has been established, and comparisons are limited to findings in human medicine (10).

Guiana dolphins (*S. guianensis*) are cetaceans of the genus *Sotalia*, endemic to the Caribbean and the Atlantic coast of South America, ranging from Nicaragua to southern Brazil, including the Amazon River and its many tributaries (6, 7, 8). Strandings of *S. guianensis* are relatively common along the Brazilian coast, as these dolphins inhabit coastal areas, often near regions of intense anthropogenic activity. Among the main threats is fishing, which, although not targeting these animals, results in frequent interactions with boats and gear, leading to injuries, stress, and accidental deaths that compromise the species survival (14).

Cardiac diseases have been observed in various marine mammals, particularly in bottlenose dolphins (*Tursiops truncatus*) and striped dolphins (*Stenella coeruleoalba*). A study conducted in Italy reported macroscopic cardiac changes, including right Valsalva sinus aneurysm, marked autolysis and putrefaction, right ventricular dilation, mitral valve thickening and fibrosis, and left ventricular hypertrophy. Microscopic findings included right Valsalva sinus aneurysm, cirsoid aneurysm, mitral and tricuspid valve endocardiosis, Lambl's excrescences, lymphocytic myocarditis, and significant autolysis and putrefaction (21). Other cardiac alterations reported in dolphins exposed to pollutants in the Gulf of Mexico include atherosclerosis, degeneration or necrosis, heart failure, myocardial karyomegaly, nuclear alignment, and myocarditis (11). However, the authors did not interpret these changes as myocardial dysplasia or as ARVC-like lesion patterns.

Although this condition is still poorly studied in cetaceans, it is important to note that some marine mammal species can exhibit myocardial fat deposition without pathological significance. This feature becomes more evident with advancing age, and the extent of lipid deposition varies across species (1, 4, 13). However, the female described here did not show signs of aging or cardiac lipid measurement parameters of the species. It is worth noting that in cases of physiological lipomatosis, the amount of adipose tissue does not exceed that of myocardial tissue. Even so, there is no consensus in the literature regarding the degree of fatty replacement required to justify a diagnosis of cardiac lipomatosis (2, 9).

In the present case, histopathological analysis revealed replacement of myocardial tissue by fibroadipose tissue, affecting a large portion of the examined tissue — a finding previously unreported in *Sotalia guianensis*. This alteration is suggestive of arrhythmogenic myocardial dysplasia, a condition known to cause ventricular arrhythmias and sudden death in humans and domestic animals such as Boxer dogs (4, 12, 22). However, it is not possible to determine whether these lesions would have resulted in functional impairment or arrhythmias, given the limitations of sampling and the absence of functional assessment. The histological findings observed in the analyzed cardiac segments are consistent with a morphological pattern of myocardial dysplasia, similar to arrhythmogenic right ventricular cardiomyopathy (ARVC-like), and should be interpreted in light of the inherent limitations of cetacean cardiac physiology.

Data Availability

All the original contributions presented in this study are included in the article/supplementary material. Further inquiries can be directed to the corresponding author.

Author Contributions

Fernanda Menezes de Oliveira e Silva: Investigation, Data curation, Formal analysis, Writing – review and editing. **João Ricardo Sales Rocha Filgueiras**: Conceptualization, Methodology, Formal analysis, Writing – original draft preparation. **Vitor Luz Carvalho**: Investigation, Formal analysis, Supervision, Writing – review and editing. All authors have read and approved the final version of the manuscript.

Conflict of Interest

The authors declare no competing interests.

Generative AI Use Statement

The authors did not use generative artificial intelligence tools or technologies in creating or editing any part of this manuscript.

References

1. Ackman RG, Hooper SN, Hingley J. The Harbor Seal Phoca vitulina concolor De Kay: comparative details of fatty acids in lung and heart phospholipids and triglycerides. Can J Biochem. 1977;50(7):833-8. doi: 10.1139/o72-115.
2. Agudelo CF, Svoboda M, Husnik R, Dvir S. Heart lipomatosis in domestic animals: a review. Vet Med, 2013;58(5):252-9. doi: 10.17221/6806-VETMED.
3. Alessi AC, Santos RL. Patologia veterinária. 3rd ed. Rio de Janeiro: Roca; 2023. 65 p.
4. Basso C, Fox PR, Meurs KM, Towbin JA, Spier AW, Calabrese F, Maron BJ, Thiene G. Arrythmogenic right ventricular cardiomyopathy causing sudden cardiac death in boxer dogs: A new animal model of human disease. Circulation. 2004;109(9):1180-5. doi: 10.1161/01.CIR.0000118494.07530.65.
5. Belerenian G, Donati PA, Rodríguez CD, Castillo V, Guevara JM, Olivares RWI. Left-dominant arrhythmogenic cardiomyopathy in a Fila Brasileiro dog. Open Vet J. 2022;12(4):495-501. doi: 10.5455/OVJ.2022.v12.i4.11.
6. Borobia M, Siciliano S, Lodi L, Hoek W. Distribution of the South American dolphin Sotalia fluviatilis. Can J Zool. 1991;69(4):1025-39. doi: 10.1139/z91-148.
7. Carr T, Bonde RK. Tucuxi (Sotalia fluviatilis) occurs in Nicaragua, 800 km north of its previously known range. Mar Mamm Sci. 2000;16(2):447-52. doi: 10.1111/j.1748-7692.2000.tb00936.x.
8. Da Silva VMF, Best RC. Sotalia fluviatilis. Mamm Species. 1996;527(1):1-7. doi: 10.2307/3504117.
9. Gerlis LM, Schmidt-Ott SC, Ho SY, Anderson RH. Dysplastic conditions of the right ventricular myocardium: Uhl's anomaly v arrhythmogenic right ventricular dysplasia. Br Heart J 1993;69(2):142-50. doi: 10.1136/hrt.69.2.142.
10. Hyun C, Filippich LJ. Molecular genetics of sudden cardiac death in small animals - A reviev. Vet J. 2006;171(1):39-50. doi: 10.1016/j.tvjl.2004.10.022.
11. Linnehan BK, Gomez FM, Huston SM, Hsu A, Takeshita R, Colegrove KM, Smith CR. Cardiac assessments of bottlenose dolphins (Tursiops truncatus) in the Northern Gulf of Mexico following exposure to Deepwater Horizon oil. PLoS One. 2021;16(12):e0261112. doi: 10.1371/journal.pone.0261112.
12. Meurs KM, Spier AW, Miller MW. Familial ventricular arrhythmias in boxers. J Vet Intern Med. 1999;13(5):437-9. doi: 10.1111/j.1939-1676.1999.tb01460.x.
13. Monteiro JP, Maciel E, Maia R, Pereira AT, Calado R, Domingues P, Domingues MR. Characterization of the cardiac phospholipidome of small cetaceans provides adaptational insight and a foundation for indirect population health screening. Mar Mamm Sci. 2021;37(4):1406-27. doi: 10.1111/mms.12823.
14. Monteiro-Filho ELDA. Pesca interativa entre golfinho Sotalia fluviatilis guianensis e a comunidade pesqueira da região de Cananéia. Bol Inst Pesca. 1995;22(2):15-23.
15. Nakao S, Hirakawa A, Yamamoto S, Kobayashi M, Machida N. Pathological features of arrhythmogenic right ventricular cardiomyopathy in middle-aged dogs. J Vet Med Sci. 2011;73(8):1031-6. doi: 10.1292/jvms.11-0080.
16. Ocarino NM, Nascimento EF, Paniago JDG, Serkides R. Displasia miocardial ventricular bilateral em um cão Shar-Pei. Arq Bras Med Vet Zootec. 2011;63(3):765-7. doi: 10.1590/S0102-09352011000300034.
17. Palacio MFD, Bernal LJ, Bayon A, Bernabe A, Oca RMD, Seva J. Arrhythmogenic right ventricular dysplasia/cardiomyopathy in a Siberian husky. J Small Anim Pract. 2011;42(3):137-42. doi: 10.1111/j.1748-5827.2001.tb02010.x.
18. Palermo V, Stafford MJJ, Sala E, Brambilla PG, Martin MWS. Cardiomyopathy in Boxer dogs: a retrospective study of the clinical presentation, diagnostic findings and survival. J Vet Cardiol. 2011;13(1):45-55. doi: 10.1016/j.jvc.2010.06.005.
19. Rampazzo A, Nava A, Erne P, Eberhard M, Vian E, Slomp P, Tiso N, Thiene G, Danielli GA. A new locus for arrhythmogenic right ventricular cardiomyopathy (ARVD2) maps to chromosome 1q42–q43. Hum Mol Genet. 1995;4(11):2151-4. doi: 10.1093/hmg/4.11.2151.
20. Santilli RA, Bontempi LV, Perego M, Fornai L, Basso C. Outflow tract segmental arrhythmogenic right ventricular cardiomyopathy in an English Bulldog. J Vet Cardiol. 2009;11(1):47-51. doi: 10.1016/j.jvc.2009.03.006.
21. Scaglione FE, Bollo E, Pregel P, Chiappino L, Sereno A, Mignone W, Guarda F. Heart pathologies in dolphins stranded along the northwestern Italian coast. Dis Aquat Organ. 2013;107(1):31-6. doi: 10.3354/dao02672.
22. Thiene G, Basso C, Danieli G, Rampazzo A, Corrado D, Nava A. Arrhythmogenic right ventricular cardiomyopathy a still underrecognized clinic entity. Trends Cardiovasc Med. 1997;7(3):84-90. doi: 10.1016/S1050-1738(97)00011-X.