Braz J Vet Pathol, 2025, vol. 18, e019009
DOI: https://doi.org/10.24070/bjvp.1983-0246.019009

BJVP
Brazilian Journal of Veterinary Pathology
ISSN 1983-0246

Case Report

Sudden death in a young cat with a cardiomyopathic nonspecific phenotype, primary hypothyroidism and obesity: a case report

Jahnier Andrés Caicedo Martinez[1,2]*, Maria Angelica Avila Rubiano[3], Helbert Yesid Caicedo Martinez[3]; Benjamin Doncel-Diaz[4], Renee Laufer Amorim[1]

[1]Department of Veterinary Clinic, School of Veterinary Medicine and Animal Science, São Paulo State University (UNESP), Botucatu, SP, Brazil
[2]National Veterinary Diagnostic Laboratory, Colombian Agricultural Institute (ICA), Bogotá, DC, Colombia
[3]San José Veterinary Clinic, Bogotá, DC, Colombia
[4]Laboratory of Veterinary Pathology, Faculty of Veterinary Medicine and Animal Science, National University of Colombia, Bogotá, DC, Colombia

***Corresponding author:** jahnier.caicedo@unesp.br
Submitted: December 6th, 2025. Accepted: March 5th, 2026

Abstract
Feline metabolic syndrome is a poorly documented yet clinically relevant condition in veterinary medicine. This syndrome may remain clinically silent for long periods, allowing cardiac and endocrine dysfunction to progress unnoticed. Cardiac fatty infiltration combined with myocardial remodeling represents a rare but important cause of heart failure and sudden death. A three-year-old female mixed-breed cat with no prior clinical history was found dead at home. Necropsy revealed severe obesity (body condition score 9/9) with extensive pericardial, mesenteric, perirenal, and subcutaneous fat deposition; pleural effusion; pulmonary collapse; and cardiomegaly characterized by left ventricular concentric hypertrophy and right ventricular atrophy. Histopathology confirmed left ventricular myocardial hypertrophy with interstitial fibrosis, right ventricular adipose infiltration (adipositas cordis), hepatic and pulmonary congestion, and diffuse thyroid follicular hyperplasia. The absence of fibroadipose replacement excluded arrhythmogenic right ventricular cardiomyopathy (ARVC). Immunohistochemistry demonstrated markedly reduced expression of thyroglobulin and thyroid transcription factor-1, supporting the diagnosis of thyroid dysfunction. Taken together, these findings indicate a rare association of a cardiomyopathic nonspecific phenotype with primary hypothyroidism and obesity, reflecting a complex metabolic–cardiac interplay culminating in sudden death. This case highlights the importance of early metabolic and endocrine assessment in obese cats, even in the absence of clinical signs, and emphasizes the diagnostic value of postmortem immunohistochemistry in identifying sudden deaths of uncertain etiology.

Keywords: cats, obesity, metabolic syndrome, cardiomyopathy, hypothyroidism, immunohistochemistry.

Introduction

Sudden death in apparently healthy young cats represents a major diagnostic challenge in veterinary medicine. Hypertrophic cardiomyopathy (HCM) is recognized as the most frequent cause, but other phenotypes, such as arrhythmogenic right ventricular cardiomyopathy (ARVC) and adipositas cordis (AC), have also been reported (20, 28). In humans, AC is characterized by epicardial and intramyocardial fat accumulation, particularly in the right ventricle, without fibrosis or inflammation and has been associated with fatal arrhythmias (13). Although infrequently documented in cats, recent case reports suggest that AC may be underdiagnosed (9, 20).

Primary hypothyroidism is a rare and likely underrecognized endocrine disorder in felines and is typically reported in experimental contexts or isolated clinical cases (6, 7). Thyroid dysfunction has been linked to systemic metabolic derangements, fat accumulation, and cardiac remodeling (22, 23). Loss of thyroid transcription factor-1 (TTF-1) and thyroglobulin expression on immunohistochemistry provide robust evidence of impaired follicular functional capacity, supporting

Braz J Vet Pathol, 2025, vol. 18, e019009
DOI: https://doi.org/10.24070/bjvp.1983-0246.019009

a diagnosis of primary thyroid dysfunction. Recent necropsy surveys have also revealed a high prevalence of subclinical thyroid lesions, which often coexist with cardiomyopathies (9). However, their contribution to myocardial remodeling in young, clinically silent cats remains poorly characterized.

Obesity further complicates this endocrine-cardiac interplay, with prevalence rates reaching 63% in domestic cats (1, 19, 27). The concept of feline metabolic syndrome encompasses the coexistence of visceral obesity, insulin resistance, hypertension, dyslipidemia, and endocrine alterations, all of which predispose cats to cardiovascular dysfunction and premature death (2, 11, 21).

The ACVIM consensus statement on feline cardiomyopathies recommends classifying cases with diffuse or mixed structural abnormalities as a "nonspecific phenotype" when they do not fit traditional categories such as hypertrophic cardiomyopathy (HCM), restrictive cardiomyopathy (RCM), dilated cardiomyopathy (DCM), or arrhythmogenic right ventricular cardiomyopathy (ARVC) (14).

This report describes a rare case of sudden death in a young cat with a cardiomyopathic nonspecific phenotype, primary hypothyroidism, and marked systemic obesity. These findings underscore the importance of integrated evaluation of the endocrine and cardiovascular systems in obese felines, even in the absence of clinical signs. To our knowledge, the combined presence of a cardiomyopathic nonspecific phenotype, primary hypothyroidism, and prominent visceral obesity in a young adult cat has not been previously documented.

Case description

A three-year-old intact female mixed-breed cat (6.2 kg), with no known medical history, was found dead at home. According to the owner, the cat had shown progressive weight gain over recent months without noticeable changes in behavior or appetite. The body condition score was 9/9, which is consistent with severe obesity.

At necropsy, there was marked accumulation of subcutaneous and visceral fat, particularly in the pericardial, perirenal, and mesenteric regions. Approximately 50 mL of serous pleural effusion was present, and both lungs were partially collapsed and congested. The heart exhibited concentric hypertrophy of the left ventricle (LV), with a wall thickness of 7.8 mm and interventricular septal thickening of 7.0 mm. The right ventricular (RV) free wall was thinned (2.0 mm) and pale (Fig. 1). The mucous membranes were diffusely pale. No significant gross abnormalities were observed in the kidneys, gastrointestinal tract, or lymphoid tissues. The adrenal glands, pancreas, and thyroid glands were grossly unremarkable.

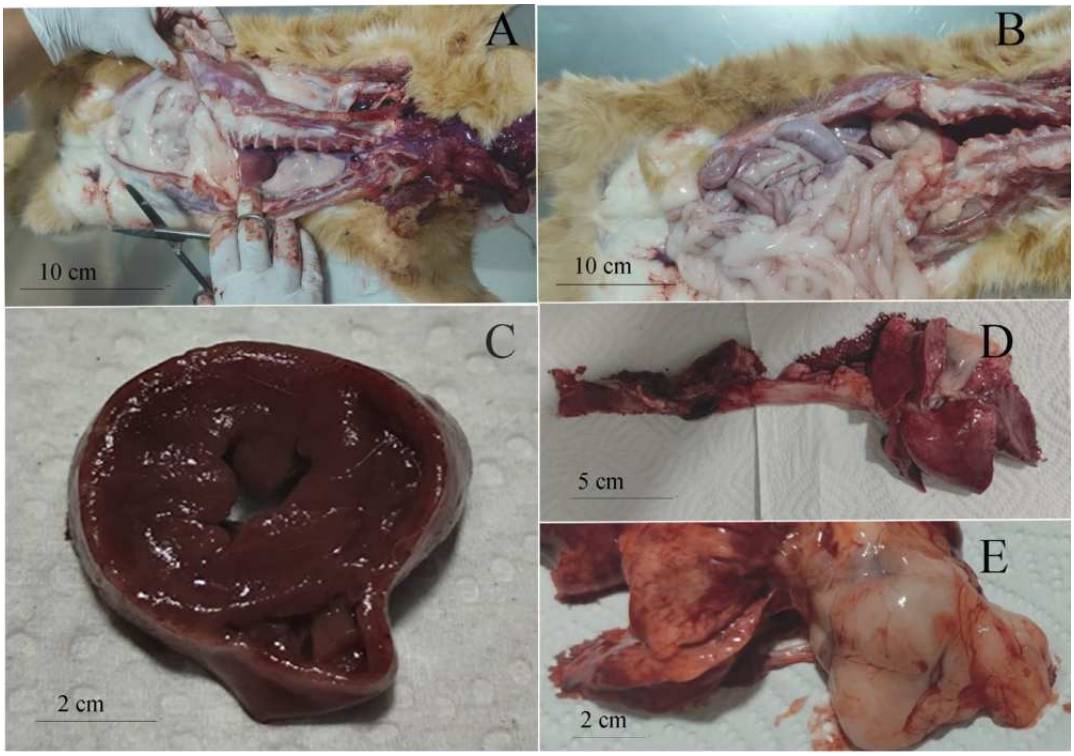

Figure 1. Gross findings in a young cat that died suddenly. A. Thoracic cavity showing severe subcutaneous and visceral fat deposition, pleural effusion, and partial pulmonary collapse (scale bar = 10 cm). B. Abdominal cavity with marked mesenteric and visceral adipose tissue accumulation (scale bar = 10 cm). C. Transverse section of the heart showing concentric left ventricular hypertrophy and thinning of the right ventricular free wall (scale bar = 2 cm). D. Trachea and lungs with evident pulmonary congestion and edema (scale bar = 5 cm). E. Close-up image of the heart surface demonstrating abundant epicardial and visceral fat covering the myocardium (scale bar = 2 cm).

Braz J Vet Pathol, 2025, vol. 18, e019009
DOI: https://doi.org/10.24070/bjvp.1983-0246.019009

Microscopically, the lungs showed severe vascular congestion, alveolar edema, scattered hemorrhage, and hemosiderin-laden macrophages ("heart failure cells") (Fig. 2A-B). The liver exhibited sinusoidal congestion and mild hepatocellular degeneration (Fig. 2C-D). The thyroid glands showed diffuse follicular hyperplasia with irregular architecture, scant colloid, and epithelial proliferation, which is consistent with primary hypothyroidism (Fig. 2E-F).

Cardiac histology revealed left ventricular myocyte hypertrophy with some nuclear enlargement, disorganization of fiber alignment, and interstitial and perivascular fibrosis (Fig. 3A-D). The right ventricle contained extensive infiltration of mature adipose tissue in subepicardial and intramyocardial regions, separating and compressing myofibers without evidence of fibrosis, necrosis, or inflammation (Fig. 4A-C).

Immunohistochemical (IHC) analysis of thyroid tissue revealed a marked reduction in thyroglobulin and thyroid transcription factor-1 (TTF-1) expression, confirming severe thyroid dysfunction (Fig. 5). Fibrosis of the left ventricular

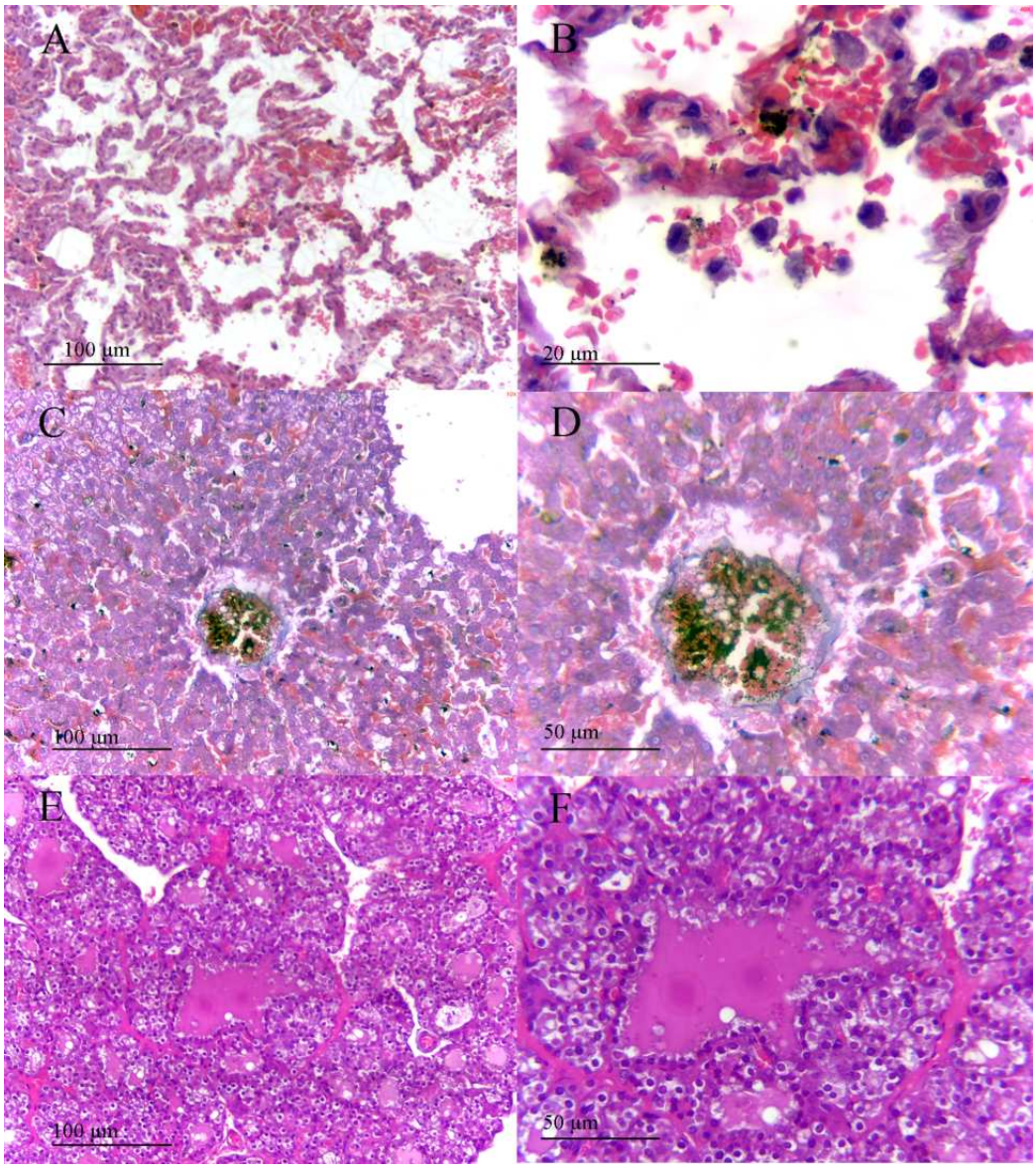

Figure 2. Histopathological findings in the lung, liver, and thyroid of a cat with global cardiomyopathy, metabolic syndrome, and severe thyroid dysfunction. A. Lung with severe vascular congestion, alveolar edema, and hemorrhage (H&E, 10×). B. Higher magnification image showing hemosiderin-laden macrophages ("heart failure cells") within alveoli (H&E, 40×). C. Liver with centrilobular congestion, dilated sinusoids, and pigment accumulation (H&E, 10×). D. Higher magnification of the centrilobular region showing marked sinusoidal congestion and mild hepatocellular degeneration (H&E, 20×). E. Thyroid with altered follicular architecture: irregular follicles, some collapsed or devoid of colloid, and diffuse epithelial proliferation (H&E, 10×). F. Higher magnification image showing hyperplastic cuboidal epithelium with scant colloid in the follicular lumina (H&E, 20×).

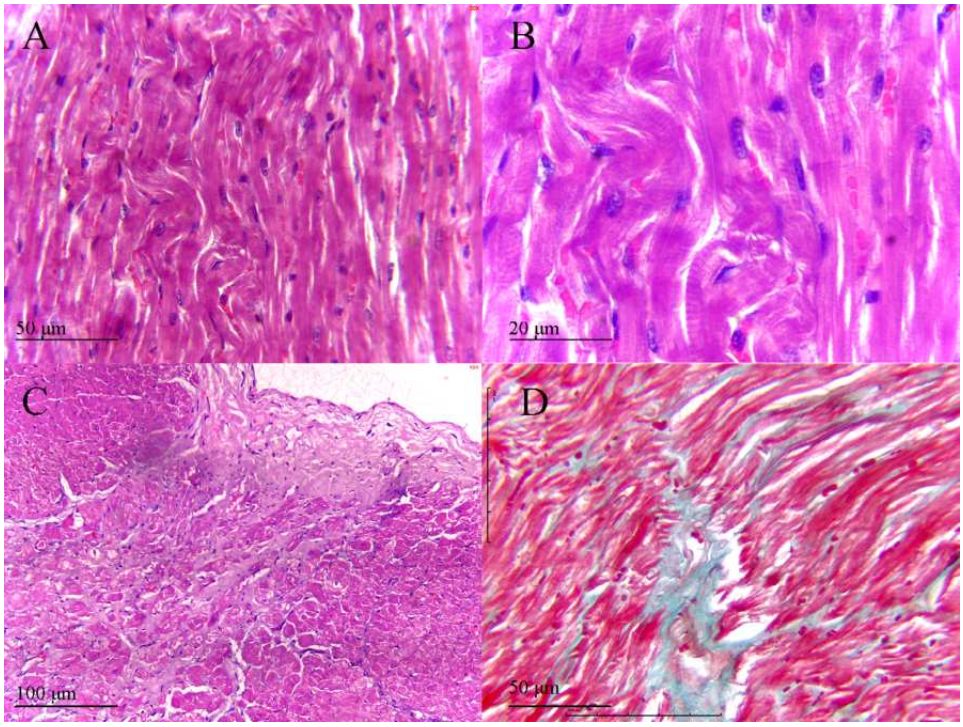

Figure 3. Histopathological changes in the left ventricular myocardium of a cat with sudden death and advanced structural cardiomyopathy. A. Hypertrophied cardiac fibers with prominent central nuclei and irregular, wavy alignment (H&E, 20×). B. Higher magnification image showing anisocytosis, nuclear enlargement, and loss of parallel fiber orientation (H&E, 40×). C. Myocardium with diffuse interstitial fibrosis separating muscle fibers (H&E, 10×). D. Dense collagen deposition confirmed by Masson's trichrome staining, highlighting fibrotic expansion between cardiomyocytes (Masson's trichrome, 20×).

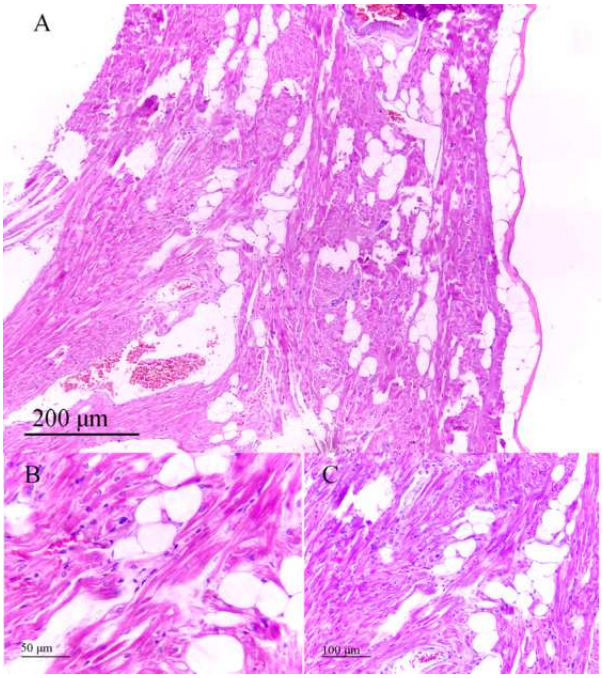

Figure 4. The adipositas cordis in the right ventricle of a cat with sudden death. **A.** Low-power view of the right ventricular myocardium showing extensive infiltration of mature adipose tissue interspersed between cardiac fibers and extending toward the subepicardial region (H&E, 4×). **B.** Higher magnification image of adipocytes penetrating the adjacent myocardium and separating cardiac fibers without inflammation or necrosis, which is consistent with a slow atrophic process due to pressure or disuse (H&E, 20×). **C.** Details of the adipose–myocardial interface showing mild interstitial fibrosis, focal cardiomyocyte thinning, and nuclear displacement (H&E, 40×).

Braz J Vet Pathol, 2025, vol. 18, e019009
DOI: https://doi.org/10.24070/bjvp.1983-0246.019009

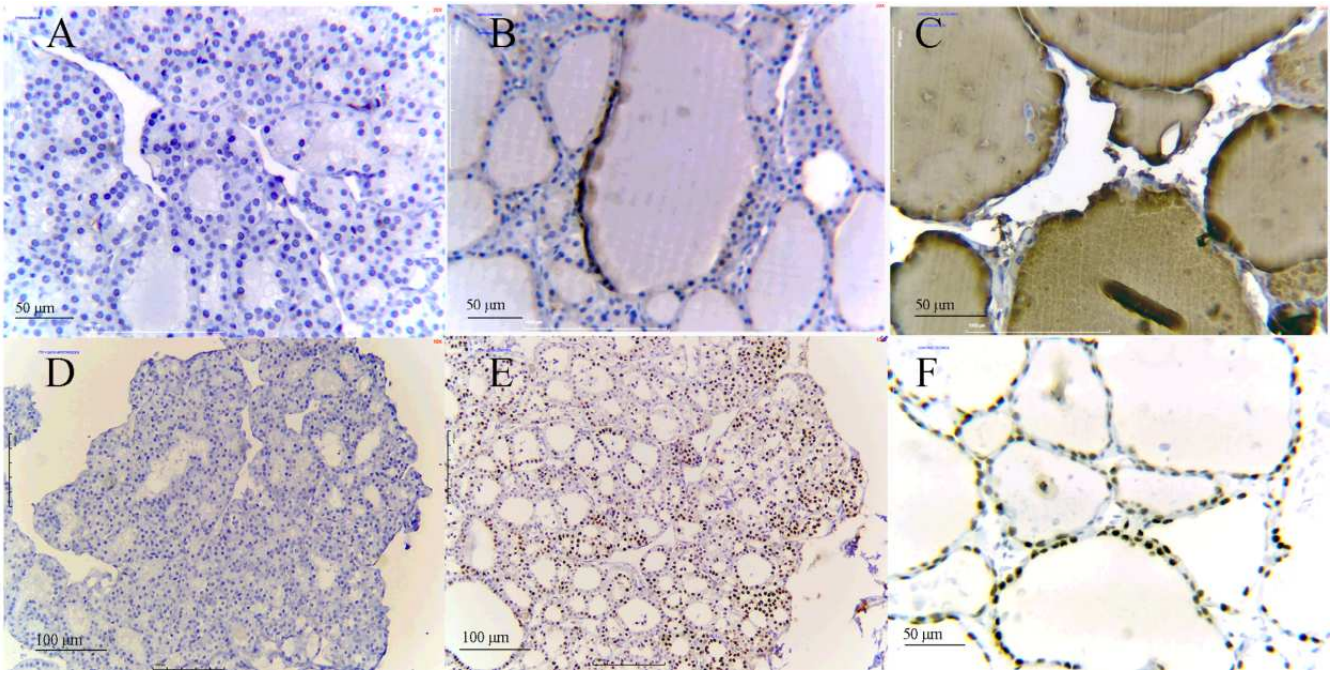

Figure 5. Immunohistochemical expression of thyroglobulin (A–C) and TTF-1 (D–F) in feline thyroid tissue. A. Thyroid tissue from the hypothyroid cat showing complete loss of cytoplasmic thyroglobulin immunoreactivity in follicular cells (score 0, 20×). B. Normal feline thyroid gland with moderate cytoplasmic thyroglobulin expression in the follicular epithelium (score 2, 20×). C. Human thyroid (positive control) showing strong cytoplasmic thyroglobulin staining (score 3, 20×). D. Thyroid tissue from the hypothyroid cat showing the absence of nuclear TTF-1 labeling in follicular cells (score 0, 10×). E. Normal feline thyroid gland with moderate nuclear TTF-1 expression (score 2, 10×). F. Human thyroid (positive control) with strong nuclear TTF-1 immunostaining (score 3, 40×).

myocardium was confirmed by Masson's trichrome staining, whereas the pattern of right ventricular adipose infiltration - without fibrous replacement or inflammation - was consistent with adipositas cordis and excluded arrhythmogenic right ventricular cardiomyopathy (ARVC).

Discussion

This case represents an uncommon pathological association in a young cat characterized by a cardiomyopathic nonspecific phenotype with left ventricular hypertrophy, right ventricular adipose infiltration, diffuse primary hypothyroidism, and systemic obesity. The coexistence of these disorders suggests a chronic, multiorgan remodeling process most likely driven by endocrine dysfunction and visceral adiposity.

Left ventricular hypertrophy and right ventricular mural atrophy (≈2 mm), together with interstitial fibrosis confirmed by Masson's trichrome staining, are consistent with advanced structural cardiomyopathy, a pattern also reported in cats that die suddenly without prior clinical signs (20, 31). Sudden death in such cases is commonly attributed to terminal arrhythmias or acute decompensation associated with diastolic dysfunction. The epicardial and intramyocardial fatty infiltration of the right ventricle—without fibrosis or inflammation—matched the definition of adipositas cordis and effectively excluded arrhythmogenic right ventricular cardiomyopathy (ARVC), in which fibroadipose replacement predominates (20, 28). In human medicine, adipositas cordis is usually considered an incidental finding but may be associated with arrhythmias when conduction pathways are involved (12, 13, 16, 18). Although underreported in cats (5, 20), its recognition is increasing. In the present case, the lack of fibrosis or myocyte degeneration supported a slowly progressive, noninflammatory adipose infiltration rather than a primary arrhythmogenic process.

From an endocrine perspective, the diffuse thyroid follicular hyperplasia observed is compatible with primary hypothyroidism (18, 23). Thyroid dysfunction can reduce the basal metabolic rate, promote adipose accumulation, and exacerbate myocardial remodeling, even in the absence of overt clinical signs (26). Recent necropsy surveys have reported a high frequency of subclinical thyroid lesions in cats, often concomitant with cardiomyopathy (9), reinforcing the importance of systematic endocrine surveillance.

Obesity was another central factor in this case. Its prevalence in domestic cats may reach 63%, and it is frequently accompanied by metabolic comorbidities (17, 27). Obesity is now recognized as a systemic disease characterized by chronic inflammation and endocrine dysfunction, including reduced adiponectin and impaired metabolic signaling (1, 10, 19). Visceral adipose tissue acts as an endocrine organ that

promotes insulin resistance, lipotoxicity, and cardiovascular remodeling (2, 4, 29). These mechanisms are consistent with the marked visceral obesity and associated endocrine–cardiac alterations observed in this patient.

From a methodological perspective, the immunohistochemistry protocols applied adhered to validated standards in comparative pathology (15, 24). The use of specific positive controls strengthened diagnostic reliability, particularly in feline thyroid tissue, where technical validation is essential (25). The marked reduction in thyroglobulin and TTF-1 expression confirmed severe thyroid dysfunction and highlighted the diagnostic value of immunohistochemistry in sudden death investigations.

Taken together, the morphological and immunohistochemical findings in this case emphasize the importance of recognizing the cardiomyopathic nonspecific phenotype described by the ACVIM consensus (14). These findings reinforce the need for integrated endocrine–cardiovascular evaluation in obese cats, even when they are clinically silent, as this approach may improve early detection and prevention of fatal outcomes.

In conclusion, this case demonstrates how the interaction between systemic obesity, primary hypothyroidism, and cardiac remodeling can culminate in the cardiomyopathic nonspecific phenotype and sudden death in a young cat. The combined morphological and immunohistochemical findings, particularly the reduced expression of thyroglobulin and TTF-1 and the right ventricular adipose infiltration consistent with adipositas cordis—provide a coherent explanation for the fatal outcome and effectively exclude arrhythmogenic right ventricular cardiomyopathy. These findings highlight the importance of early recognition of metabolic and endocrine alterations in feline patients and underscore the diagnostic value of incorporating immunohistochemistry into necropsy investigations of unexpected deaths.

Supplementary Material

The online version contains supplementary material available at https://doi.org/10.24070/bjvp.1983-0246.019009.

Conflict of interest

The authors declare that they have no competing interests.

Acknowledgments

The authors would like to thank the Scientific Committee and audience of ENICIP 2025 for their constructive feedback during the presentation of this case report.

Funding

This study received financial support from the Fundación para el Futuro de Colombia (COLFUTURO) through the Programa Crédito-Beca awarded to Jahnier Andrés Caicedo Martínez.

References

1. Appleton DJ, Rand JS, Sunvold GD. Plasma leptin concentrations in cats: reference range, effect of weight gain and relationship with adiposity as measured by dual energy X-ray absorptiometry. J Feline Med Surg. 2000;2(4):191-9. doi: 10.1053/jfms.2000.0103.
2. Araujo SL, Martins PL, de Souza Pereira TH, Sampaio TL, de Menezes RRPPB, da Costa MDR, et al. Evidence of obesity-induced inflammatory changes in client-owned cats. Vet World. 2024;17(7):1685-92. doi: 10.14202/vetworld.2024.1685-1692.
3. Argenta FF, de Mello LS, Slaviero M, Cony FG, Bandinelli MB, Pavarini SP, et al. Pathological and immunohistochemical characterization of thyroid neoplasms in cats. J Comp Pathol. 2021;184:44-55. doi: 10.1016/j.jcpa.2021.01.013.
4. De Souza FB, Golino DV, Bonatelli SP, Alfonso A, Mamprim MJ, de Carvalho Balieiro JC, et al. Effect of obesity on echocardiographic parameters and vertebral heart size (VHS) in cats. Semin Cienc Agrar. 2020;41(2):493-503. doi: 10.5433/1679-0359.2020v41n2p493.
5. Finn E, Freeman LM, Rush JE, Lee Y. The relationship between body weight, body condition, and survival in cats with heart failure. J Vet Intern Med. 2010;24(6):1369-74. doi: 10.1111/j.1939-1676.2010.0584.x.
6. Galgano M, Spalla I, Callegari C, Patruno M, Auriemma E, Zanna G, et al. Primary hypothyroidism and thyroid goiter in an adult cat. J Vet Intern Med. 2014;28(6):1852-6. doi: 10.1111/jvim.12283.
7. Greco DS. Diagnosis of congenital and adult-onset hypothyroidism in cats. Clin Tech Small Anim Pract. 2006;21(2):67-71. doi: 10.1053/j.ctsap.2005.12.007.
8. Harjuhahto TAI, Leinonen MR, Simola OTM, Järvinen AK, Rajamäki MM. Congestive heart failure and atrial fibrillation in a cat with myocardial fibro-fatty infiltration. J Feline Med Surg. 2011;13(2):138-42. doi: 10.1016/j.jfms.2010.08.001.
9. Herbichi AP, Lorenzetti DM, dos Santos MY, Hartmann G, Fighera RA, Flores MM. Thyroid lesions in a population of domestic cats submitted to necropsy without clinical suspicion of thyroid disease. J Comp Pathol. 2024;215:1-9. doi: 10.1016/j.jcpa.2024.08.002.
10. Hoenig M, Thomaseth K, Waldron M, Ferguson DC. Insulin sensitivity, fat distribution, and adipocytokine response to different diets in lean and obese cats

before and after weight loss. Am J Physiol Regul Integr Comp Physiol. 2007;292(1):R227-34. doi: 10.1152/ajpregu.00313.2006.

11. Islam MS, Wei P, Suzauddula M, Nime I, Feroz F, Acharjee M, et al. The interplay of factors in metabolic syndrome: understanding its roots and complexity. Mol Med. 2024;30:279. doi: 10.1186/s10020-024-01019-y.
12. Koparkar G, Biswas DA. Adiposity and cardiac defects: pathophysiology and etiology. Cureus. 2023;15(2):e34026. doi: 10.7759/cureus.34026.
13. Liang YH, Zhu J, Zhong DR, Hou DY, Ma GL, Zhang ZY, Zhang L. Adipositas cordis sudden death: a series of 79 patients. Int J Clin Exp Pathol. 2015;8(9):10861-7.
14. Luis Fuentes V, Abbott J, Chetboul V, Côté E, Fox PR, Häggström J, Kittleson MD, Schober K, Stern JA. ACVIM consensus statement guidelines for the classification, diagnosis, and management of cardiomyopathies in cats. J Vet Intern Med. 2020;34(3):1062-77. doi: 10.1111/jvim.15745.
15. Magaki S, Hojat A, Wei B, So A, Yong W. An introduction to the performance of immunohistochemistry: methods and protocols. Methods Mol Biol. 2019;1897:289-98. doi: 10.1007/978-1-4939-8935-5_25.
16. Martin AI, Sunjic IT, Rojas CA, Donatelli J, Finan J, Caldeira C, Herweg B, Mackie BD. Adipositas cordis: a rare and poorly understood cardiomyopathy. Methodist Debakey Cardiovasc J. 2018;14(2):147-9. doi: 10.14797/mdcj-14-2-147.
17. Masood W. The general and systemic consequences of obesity in cats and dogs. Vet Integr Sci. 2024;22(1):265-90. doi: 10.12982/VIS.2024.020.
18. Meditskou S, Mylonakis P, Giannoglou D, Zegkos T, Pagourelias E, Protonotarios N, Efthimiadis GK, Karvounis H. Adipositas cordis: A case report study and a brief review of the literature. Hellenic J Cardiol. 2017;58(3):239-242. doi: 10.1016/j.hjc.2016.10.005.
19. Okada Y, Ueno H, Mizorogi T, Ohara K, Kawasumi K, Arai T. Diagnostic criteria for obesity disease in cats. Front Vet Sci. 2019;6:284. doi: 10.3389/fvets.2019.00284.
20. Parisi F, Vezzosi T, Saldaña JAM, Poli A. Adipositas cordis in two cats with sudden death. J Comp Pathol. 2020;176:151-5. doi: 10.1016/j.jcpa.2020.03.001.
21. Partington C, Hodgkiss-Geere H, Woods GRT, Dukes-McEwan J, Flanagan J, Biourge V, German AJ. The effect of obesity and subsequent weight reduction on cardiac morphology and function in cats. BMC Vet Res. 2024;20(1):154. doi: 10.1186/s12917-024-04011-0.
22. Peterson ME. Primary goitrous hypothyroidism in a young adult domestic longhair cat: diagnosis and treatment monitoring. J Feline Med Surg Open Rep. 2015;1(1):1-6. doi: 10.1177/2055116915615153.
23. Peterson ME, Carothers MA, Gamble DA, Rishniw M. Spontaneous primary hypothyroidism in 7 adult cats. J Vet Intern Med. 2018;32(6):1864-73. doi: 10.1111/jvim.15239.
24. Ramos-Vara JA. Technical aspects of immunohistochemistry. Vet Pathol. 2005;42(4):405-26. doi: 10.1354/vp.42-4-405.
25. Ramos-Vara JA, Miller MA. When tissue antigens and antibodies get along. Vet Pathol. 2014;51(1):42-87. doi: 10.1177/0300985813505879.
26. Rastoldo G, Tighilet B. Thyroid axis and vestibular physiopathology: from animal model to pathology. Int J Mol Sci. 2023;24(12):9826. doi: 10.3390/ijms24129826.
27. Saavedra C, Pérez C, Oyarzún C, Torres-Arévalo Á. Overweight and obesity in domestic cats: epidemiological risk factors and associated pathologies. J Feline Med Surg. 2024;26(9):e285519. doi: 10.1177/1098612X241285519.
28. Tansey DK, Aly Z, Sheppard MN. Fat in the right ventricle of the normal heart. Histopathology. 2005;46(1):98-104. doi: 10.1111/j.1365-2559.2005.02054.x.
29. Wakshlag J, Loftus J. Canine and feline obesity: a review of pathophysiology, epidemiology, and clinical management. Vet Med Res Rep. 2014;5:49-60. doi: 10.2147/VMRR.S40868.
30. Ward CR, Achenbach SE, Holt D, Peterson ME, Meinkoth JL. Thyrotropin-stimulated DNA synthesis and thyroglobulin expression in normal and hyperthyroid feline thyrocytes in monolayer culture. Thyroid. 2005;15(2):114-20. doi: 10.1089/thy.2005.15.114.
31. Wilkie LJ, Smith K, Luis Fuentes V. Cardiac pathology findings in 252 cats presented for necropsy; a comparison of cats with unexpected death versus other deaths. J Vet Cardiol. 2015;17:S329-40. doi: 10.1016/j.jvc.2015.09.006.