Braz J Vet Pathol, 2026, vol. 19, e019016
DOI: https://doi.org/10.24070/bjvp.1983-0246.019016

BJVP
Brazilian Journal of Veterinary Pathology
ISSN 1983-0246

Case Report

Teschen Disease Outbreak in nursery piglets in Southwestern Brazil

Aline Beatriz da Rosa[1], Jiceli Paola Pospieka[1], José Paulo Hiroji Sato[2], Paula Rodrigues de Almeida[1], Fernando Rosado Spilki[1], Roberto Maurício Carvalho Guedes[3], Karine Ludwig Takeuti[1]

[1] Molecular Microbiology Laboratory, Universidade Feevale, Novo Hamburgo, RS, Brazil
[2] Dr. Bata Brazil, Chapecó, SC, Brazil
[3] Department of Veterinary Clinic and Surgery, Veterinary School, Universidade Federal de Minas Gerais, Belo Horizonte, MG, Brazil

*Corresponding author: karinetakeuti@feevale.br
Submitted: December 9th, 2025. Accepted: May 1st, 2026.

Abstract
This case report details an outbreak on a technified pig farm in the state of São Paulo, Brazil, occurred in June 2022, where nursery piglets presented neurological clinical signs. Three pigs were euthanized, followed by necropsy and sample collections for microbiological, histopathological, and molecular analysis. During the necropsy there were no evident macroscopic lesions, and the microbiological analysis was negative for two of the main causes of neurological signs in nursery piglets: meningoencephalitis caused by *Streptococcus suis* and Edema Disease caused by F18-STx2e enterotoxigenic *Escherichia coli*. However, the histopathological analysis indicated a viral etiology. After a comprehensive tissue sample molecular analysis, *Porcine Teschovirus* (PTV) was detected. The same samples were negative for *Astrovirus*, *Enterovirus* and *Sapelovirus*. These findings highlight the critical importance of collecting central nervous system tissues, particularly brain and spinal cord, in cases presenting compatible neurological clinical signs. In addition, the inclusion of complementary samples, such as cerebrospinal fluid and feces may further improve diagnostic sensitivity. Therefore, PTV should be considered in the differential diagnosis of neurological disease in nursery pigs, especially when clinical and histopathological findings are suggestive of viral infection. In this study, PTV was detected in the absence of co-infection with other picornaviruses commonly reported in similar cases.

Keywords: neurological diseases, polioencephalomyelitis, swine, *Porcine Teschovirus*

Introduction

Porcine Teschovirus (PTV) is a non-enveloped RNAss+, included in *Picornaviridae* family and in the genus *Teschovirus* (8). PTV serotype 1 is a virus responsible for causing Teschen Disease, which affects mainly nursery pigs. Previous studies reporting neurological disease have demonstrated the presence of PTV in multiple regions of Brazil, with high detection rates in pig herds (5, 6, 7). Together, these findings indicate a wide circulation of the virus in the country and suggest a possible endemic pattern, although further epidemiological data are still needed. The clinical signs include diarrhea, fever, and neurological conditions with polioencephalomyelitis, similar to those caused by other viral pathogens, such as *Astrovirus* (PAstV-1), *Enterovirus* (EV-G) and *Sapelovirus* (PSV). Therefore, the only way to distinguish the agent is to perform molecular testing associated with the clinical history of the outbreak and histopathological findings (1).

This case report highlights the importance of including PTV in the differential diagnosis of neurological conditions in nursery piglets. The present study describes an outbreak in a commercial pig farm in São Paulo state, Brazil, in 2022, demonstrating the occurrence of the disease outside the traditionally reported southern regions.

Case description

The outbreak occurred in a commercial pig nursery with capacity for 9,000 animals. In 2021, the average mortality rate was 0.7%, but there was a progressive increase associated with symptoms of neurological disease up to the end of that year. From May to July 2022, there was an increase in mortality rate to 1.8%. At the beginning of the outbreak, central nervous system tissue samples were taken for bacteriology, but no bacteria were isolated. Several antimicrobials were administered intramuscularly, with no response to treatment.

Clinical signs were observed one week after housing in the nursery, characterised by motor incoordination, vocalization, paresis of the forelimbs and/or hind limbs, progressing to paralysis and, in some cases, opisthotonos. Affected animals remained in lateral recumbency (Fig 1) with palpebral reflex, but there was no lack of appetite. Euthanasia of three piglets with neurological clinical signs was carried out due to poor clinical conditions. The brain, spinal cord, cerebrospinal fluid and feces were collected from these animals and refrigerated for further laboratorial analysis. In addition, fragments of brain, spinal cord, lung, lymph nodes, heart, small and large intestine were fixed in 10% buffered formalin, subsequently processed, included in paraffin blocks, sectioned, and stained by hematoxylin and eosin (H&E) for histological analysis (3).

For molecular analysis, genetic material was extracted using the KingFisher Duo – MagMAX CORE Nucleic Acid Kit (Thermo Fisher Scientific, USA), and then cDNA was synthesized using the High-Capacity cDNA Reverse Transcription Kit. Polymerase Chain Reaction (RT-PCR) technique was used to detect PAstV-1 (4), with amplification at 284 base pairs (bp). Nested RT-PCR was used to detect picornaviruses (EV-G, PSV, and PTV) by targeting the highly conserved 5′ untranslated region (5′ UTR) of the viral genome (9) and modified (6) for PTV detection.



Figure 1. Nursery pigs presenting neurological clinical signs, such as lateral recumbency in a commercial pig farm in southern Brazil.

At necropsy, there were no relevant macroscopic findings. However, the histological evaluation revealed that all three animals had similar lesions in the cerebrum, brainstem and spinal cord (Fig 2). Moderate perivascular lymphohistiocitic inflammatory associated with marked multifocal gliosis, hypereosinophilia of some neuronal bodies and multifocal presence of spheroids, Wallerian degeneration with digestion chambers in multifocal bundles and multifocal increase in subependymal cellularity were observed in the cerebrum gray matter.

In brainstem and cerebellum, there were moderate marked lymphocytic perivascular cuffing and multifocal gliosis, particularly around neurons, in addition to chromatolysis, spheroids and neuronophagy. In the spinal cord, only affecting the ventral horn of the gray matter, there were accentuated gliosis, satellitism, and accentuated presence of spheroids in the ventral gray matter were observed, affecting different segments of the cord to varying degrees, digestion chambers with the presence of macrophages and neuronophagy.

The results for viral genomic detection are shown in Table 1, with PTV detection in all animals in different samples.

Discussion

Identifying the causative agent of polyencephalomyelitis is essential due to the variety of pathogens involved in neurological disorders in pigs. A previous study (7) has linked respiratory, enteric, and neurological manifestations to viruses of the *Picornaviridae* family, such as *Teschovirus*, *Sapelovirus* A and *Enterovirus* G, demonstrating at least three agents distinguishable only by molecular methods (1). In 2012, PTV-1 serotype was associated, through molecular detection, with polioencephalomyelitis infections in both natural and experimental infections in piglets (2).

Macroscopic lesions are not common in cases of PTV involvement (11), showing that necropsy findings alone are insufficient to determine the causative agent of the disease. Therefore, it is essential to associate the results of necropsy with clinical history, histopathology, and molecular tests of euthanized animals for a more accurate investigation (7). On the other hand, histopathological lesions located in the CNS, such as non-suppurative polioencephalomyelitis with perivascular lymphocytic, have already been documented previously (7) in infections caused by neurotropic viruses, such as members of the *Picornaviridae* family, like *Teschovirus* serotype 1, *Sapelovirus* A and *Enterovirus* G. The PTV infection in the present case is similar to a previous study (11), with lymphocytic perivascular cuffs, multifocal gliosis and neuronophagy, particularly in regions such as the brainstem and cerebellum. Wallerian degeneration, characterised by digestion chambers, is also an important marker of axonal lesions, commonly associated with neurotropic infections in pigs (2). The presence of neuronal spheroids and chromatolysis, resulting from axonal stress and viral

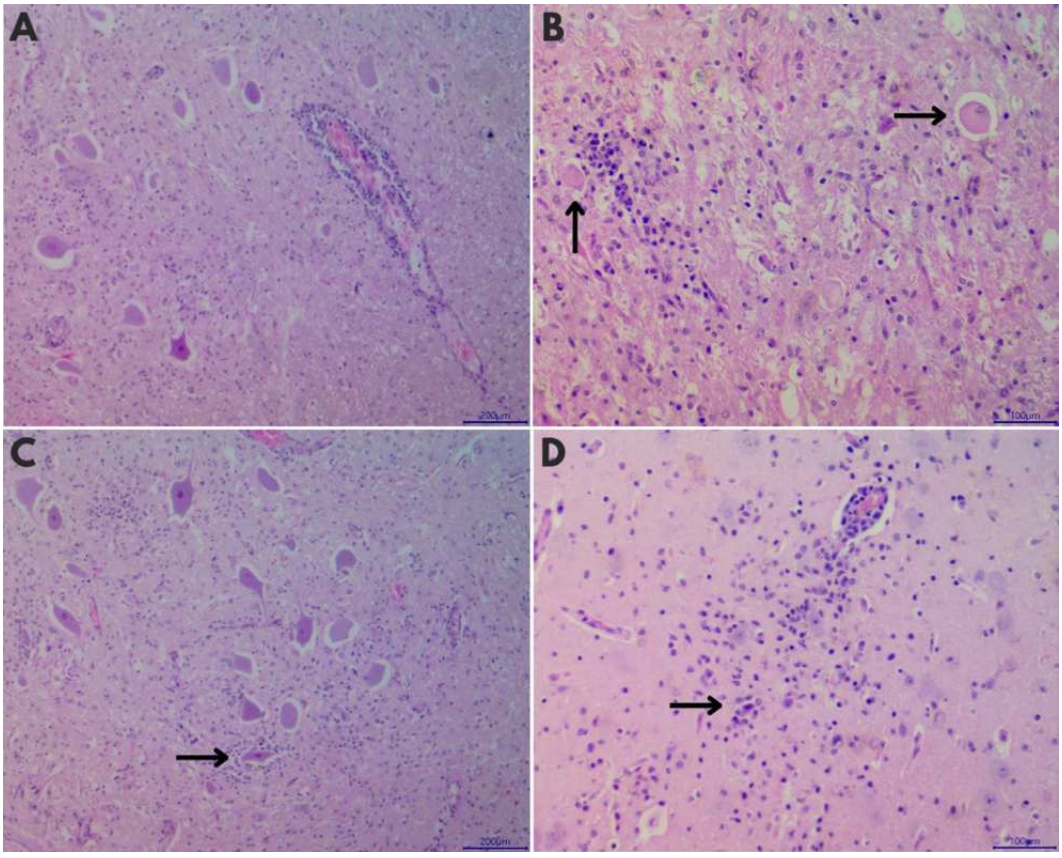

Figure 2. Nonsupurative polioencephalomyelitis associated with Porcine Teschovirus in nursery pigs. A- Encephalic trunk (brainstem). Lymphocytic perivascular cuffing. B- Ventral horn of spinal cord gray matter. Spheroides (arrows) and focal gliosis. C- Encephalic trunk (brainstem). Hypereosinophilic contracted neurons with hyperchromatic nucleus, chromatolysis and perineuronal microglial satellitosis (arrow). D- Ventral horn of spinal cord gray matter. Multifocal gliosis, neuronophagia (arrow) and lymphocytic perivascular cuffing.

Table 1. Detection of *Porcine Teschovirus* (PTV), *Porcine Astrovirus* (PAstV), *Enterovirus* (EV-G), and *Sapelovirus* (PSV) through Reverse Transcription Polymerase Chain Reaction (RT-PCR) in samples collected from nursery piglets with neurological clinical signs.

Animal	Pathogen	Sample			
		Brain	Spinal cord	CSF	Feces
A#1	PTV	+	-	NT	+
	PAstV	-	-	NT	-
	EV-G	-	NT	NT	-
	PSV	-	NT	NT	-
A#2	PTV	+	+	-	+
	PAstV	-	-	-	-
	EV-G	-	NT	NT	-
	PSV	-	NT	NT	-
A#3	PTV	+	+	+	NT
	PAstV	-	-	-	NT
	EV-G	-	NT	NT	-
	PSV	-	NT	NT	-

CSF: cerebrospinal fluid; EV-G: *Enterovirus*; NT: Not tested; PAstV: *Astrovirus*; PSV: *Sapelovirus*; PTV: *Porcine Teschovirus*

inflammation, is described as a frequent finding in cases of viral encephalomyelitis (7).

These alterations denote the damage caused by viral replication in neurons and glial cells, and suggest a progressive neurodegenerative process, leading to the progression of neurological conditions due to the chronic nature of the lesion caused by PTV (13). Other authors (12) have suggested that the involvement of the ventral gray matter of the spinal cord, associated with marked gliosis and the presence of spheroids, is indicative of severe motor dysfunction. In this context, the clinical signs observed, including paralysis and opisthotonos, may be explained by the distribution of lesions affecting the ventral horns of the spinal cord and brainstem, as described in PTV-associated infections (1, 7).

The neurotropic nature of the virus predisposes the CNS as the main site of PTV replication (1, 11). Stool samples, on the other hand, should be taken in acute outbreaks of PTV due to the shedding mechanism and enteric tropism already described in the viruses from *Picornaviridae* family (7). According to the RT-PCR results of this case report, PTV genetic material was detected in at least two of the submitted samples, highlighting the importance of collecting diverse types of samples when neurological disorders occur in pigs. Even though brain and cerebellum are the major organs submitted to laboratory analysis, spinal cord, cerebrospinal fluid and feces should be considered for sampling.

Previous studies in Brazil reported PTV in association with other picornaviruses, such as *Porcine Sapelovirus* and *Enterovirus G* (5, 7). In contrast, PTV was detected without co-infections in the present study, strengthening its association with the observed neurological signs and increased mortality (up to 1.8%). Although the molecular approach used in this study allowed the detection of PTV, it targeted a conserved genomic region and did not enable serotype differentiation or phylogenetic analysis. In this context, future studies including full or partial genome sequencing of the detected strains would be valuable to better characterize the virus and to investigate its genetic relationship with PTV strains previously reported in Southern Brazil and other regions, contributing to a deeper understanding of its epidemiology and potential routes of dissemination. It is already known that recent Brazilian cases have been associated with PTV-6 (7), generally linked to milder clinical presentations, PTV-1 has historically been associated with the more severe form of the disease (2), suggesting a potential relationship between serotype and disease severity. Therefore, the identification of PTV-1 in this study was inferred based on the assay used and clinical-pathological findings, and not confirmed by sequencing. The absence of sequencing or phylogenetic analysis represents a limitation of the study and should be considered when interpreting the results.

Although the outbreak occurred in a technified production system, the introduction of PTV cannot be ruled out, as picornaviruses are widely distributed in swine populations and the environment. Transmission is mainly associated with the fecal–oral route (1), and environmental contamination plays an important role in the horizontal transmission and maintenance of viral circulation within swine herds (10). These factors demonstrate the importance of maintaining strict biosecurity protocols, even in well-managed farms.

Porcine Teschovirus has turned into a relevant cause of neurological disorder in piglets in Southern Brazil over the last years (5, 7) and the present report suggests that the virus might be reaching other portions of the country. Thus, it is important that practitioners, laboratories, and producers must be alerted to perform diagnosis and preventive measures to better control this emerging pathogen. The Teschen disease outbreak described in this study reinforces the importance of including PTV in the differential diagnosis of neurological disorders in piglets. The combination of molecular detection in central nervous system tissues, histopathological findings of non-suppurative polioencephalomyelitis, and compatible clinical signs supports the role of PTV as a significant neurotropic agent and highlights the value of integrating these approaches for accurate diagnosis. The occurrence of successive neurological cases, with no response to antimicrobial treatment, and associated with increased mortality may indicate ongoing viral circulation, underscoring the need for improved biosecurity measures. Effective diagnosis and control strategies are essential to mitigate the impact of this emerging pathogen on swine production.

Data Availability

All the original contributions presented in this study are included in the article/supplementary material. Further inquiries can be directed to the corresponding author.

Author Contributions

Aline Beatriz da Rosa: Investigation, Data curation, Formal analysis, Methodology, Formal analysis, Writing – original draft preparation. **Jiceli Paola Pospieka**: Investigation, Data curation, Methodology. **José Paulo Hiroji Sato**: Investigation, Data curation, Methodology, Writing – review and editing. **Paula Rodrigues de Almeida**: Investigation, Data curation, Methodology, Writing – review and editing. **Fernando Rosado Spilki**: Investigation, Data curation, Methodology, Writing – review and editing. **Roberto Maurício Carvalho Guedes**: Investigation, Data curation, Methodology, Writing – review and editing. **Karine Ludwig Takeuti**: Conceptualization, Investigation, Data curation, Methodology, Formal analysis, Writing – review and editing, Supervision. All authors have read and approved the final version of the manuscript.

Conflict of Interest

The authors declare no competing interests.

Generative AI Use Statement

The authors did not use generative artificial intelligence tools or technologies in creating or editing any part of this manuscript.

Ethics declaration

The samples were collected as part of a research project approved by the Animal Use Ethics Committee of Universidade Feevale (Protocol No. 01.25.141).

Acknowledgement

We are thankful to Dr. Lorena Bezerra for her contributions taking histopathological pictures.

Funding

This research was supported by Universidade Feevale and Universidade Federal de Minas Gerais.

References

1. Alexandersen S, Knowles NJ, Belsham GJ, Dekker A, Nfon C, Zhang Z, Koenen F. Picornaviruses. In: Zimmermann JJ, Karriker LA, Ramirez A, Schwartz KJ, Stevenson GW, Zhang J, editors. Diseases of Swine. 11th ed. Ames: Blackwell Publishing Press; 2019. p. 641-684.
2. Alexandersen S, Knowles NJ, Dekker A, Belsham G, Zhang Z, Koenen F. Picornaviruses. In: Zimmerman J, Karriker LA, Ramirez A, Schwartz KJ, Stevenson GW, editors. Diseases of Swine. 10th ed. Ames: Blackwell Publishing Press; 2012. p. 587–620.
3. Allen TC. Hematoxylin and Eosin. In: Prophet EB, Mills R, Arrington JB, Sobin LH, editors. Laboratory Methods in Histotechnology. Washington, D.C.: American Registry of Pathology; 1992. p.53-58.
4. Chu DKW, Poon LLM, Guan Y, Peiris JSM. Novel astroviruses in insectivorous bats. J Virol. 2008;11:9107–14. doi: 10.1128/jvi.00857-08.
5. Donin DG, Leme RA, Alfieri AF, Alberton GC, Alfieri AA. First report of Porcine teschovirus (PTV), Porcine sapelovirus (PSV) and Enterovirus G (EV-G) in pig herds of Brazil. Trop Anim Health Prod. 2014;46:523–8. doi: 10.1007/s11250-013-0523-z.
6. Donin DG, Leme RA, Alfieri AF, Alberton GC, Alfieri AA. Molecular survey of Porcine teschovirus, Porcine sapelovirus, and Enterovirus G in captive wild boars (*Sus scrofa scrofa*) of Paraná State, Brazil. Pesq Vet Bras. 2015;35:428–32. doi: 10.1590/S0100-736X2015000500003.
7. Hammerschmitt ME, Almeida PR, Cecco BS, Lorenzett MP, Schwertz CI, Cruz RAS, Caprioli RA, Schuh DT, Demoliner M, Eisen AKA, Spilki FR, Pavarini SP, Driemeier D. Swine polioencephalomyelitis in Brazil: identification of Teschovirus A, Sapelovirus A, and Enterovirus G in a farm from Southern Brazil. Braz J Microbiol. 2021;52:1617-22. doi: 10.1007/s42770-021-00509-z.
8. ICTV [Internet]. [place unknown]: International Committee on Taxonomy of Viruses; 2025 [cited 2025 Jan 25]. Available from: https://ictv.global/report/chapter/picornaviridae/picornaviridae/teschovirus.
9. Krumbholz A, Wurm R, Scheck O, Birch-Hirschfeld E, Egerer R, Henke A, Wutzler P, Zell R. Detection of porcine teschoviruses and enteroviruses by LightCycler real-time PCR. J Virol Methods. 2003;113:51-63. doi: 10.1016/S0166-0934(03)00227-1.
10. Leme RA, Silva DR, Lorenzetti E, Moraes DA, Alfieri AF, Alfieri AA. Longitudinal survey of Teschovirus A, Sapelovirus A, and Enterovirus G fecal excretion in suckling and weaned pigs. Braz J Microbiol. 2019;50:321-7. doi: 10.1007/s42770-018-0018-1.
11. Malik YS, Bhat S, Vlasova AN, Wang FI, Touil N, Ghosh S, Dhama K, Yadav AN, Singh RK. Emerging and Transboundary Animal Viruses. In: Malik Y, Singh R, Yadav M, editors. Singapore: Springer; 2020. p. 377.
12. Schock A, Gurrala R, Fuller H, Foyle L, Dauber M, Martelli F, Scholes S, Roberts L, Steinbach F, Dastjerdi A. Investigation into an outbreak of encephalomyelitis caused by a neuroinvasive porcine sapelovirus in the United Kingdom. Vet Microbiol. 2014;172:381–9. doi: 10.1016/j.vetmic.2014.06.001.
13. Yamada M, Kaku Y, Nakamura K, Yoshii M, Yamamoto Y, Miyazaki A, Tsunemitsu H, Narita M. Immunohistochemical detection of porcine teschovirus antigen in the formalin-fixed paraffin-embedded specimens from pigs experimentally infected with Porcine Teschovirus. J Vet Med. 2007;54:571-4. doi: 10.1111/j.1439-0442.2007.00974.x