BJVP
Brazilian Journal of Veterinary Pathology
ISSN 1983-0246

Case Report

Giant cutaneous horn associated with a dilated pore in a cat

Millena Ramos Alves[1], Adriano de Sales Araujo[1], Paula Dias Retamero[1]*, Karla Geovanna Pereira Nascimento[1], Áster Patricia Kerschr Bento[1], Vivian de Assunção Nogueira Carvalho[1], Ticiana do Nascimento França[1]

[1] Pathologic Anatomy Sector, Department of Epidemiology and Public Health, Institute of Veterinary, Federal Rural University of Rio de Janeiro, Highway BR-465 Km 47, Ecologia, Seropédica, RJ, 23890-000, Brazil

[*]**Corresponding author:** paularetamero@ufrrj.br
Submitted: January 3rd, 2026. Accepted: April 21st, 2026.

Abstract
This report aims to describe a rare case of a giant cutaneous horn in a domestic cat and its association with a dilated pore. A 6-year-old female domestic cat was presented to a veterinary clinic with a keratinized, horn-like lesion on the right lateral cheek. The cylindrical mass measured 9.5 cm in length, 1.5 cm in width, and 1.5 cm in thickness, and appeared firm, dark brown to black, and hyperkeratotic. Histopathological examination revealed a dermal cyst lined by well-differentiated squamous epithelium with a prominent granular layer, consistent with an infundibular origin. The cystic lumen contained compact, laminated, partially pigmented keratin, with focal areas of parakeratosis. The lesion was characterized by keratinocyte hyperplasia with extensive laminated parakeratotic hyperkeratosis. These findings led to the diagnosis of a dilated pore, a proliferative variant of the feline infundibular follicular cyst, associated with a giant cutaneous horn. This rare presentation not only provides insight into the pathogenesis and potential relationship between dilated pores and cutaneous horns in cats, but also expands the current understanding of their differential diagnoses, particularly in atypical locations such as the face.

Keywords: feline, face, keratinous growth, projection, skin.

Introduction

A cutaneous horn is a firm, benign lesion characterized by a cylindrical projection of compact, acellular keratin extending vertically from the epidermis (5, 7). These lesions arise from excessive keratin production, typically involving the stratum spinosum (10). Although the horn is composed of keratin, its base may contain a benign, premalignant, or malignant lesion with a distinct etiology (11).

It is a rare lesion in cats, typically occurring around 7 years of age, with no sex predilection (5, 7). Macroscopically, it presents as a single or multiple, well-circumscribed, firm mass with horn-like projections. Histologically, it is characterized by compact, laminated hyperkeratosis with orthokeratotic and/or parakeratotic patterns (7, 12).

Cutaneous horns have a multifactorial etiology. Though their pathogenesis is not fully understood, they may arise from chronic inflammation, keratinization disorders, or underlying lesions such as dilated pores, viral papillomas, actinic keratoses, Bowenoid carcinoma *in situ*, invasive squamous cell carcinoma, and infundibular keratinizing acanthomas (3).

In veterinary species, cutaneous horns have been linked to diverse causes. In dogs, they have been associated with mucocutaneous Bowen's disease (2), in turtles with cutaneous calcinosis (8), and in ruminants with Dermatophilus spp. infections (7). More recently, a horn arising from a dilated pore was reported in an Iberian lynx (6).

This report describes a rare giant cutaneous horn in a domestic cat, highlighting its histopathological association with a dilated pore and its relevance in the differential diagnosis of feline keratinizing lesions.

Case description

A 6-year-old spayed female mixed-breed cat, weighing 5.4 kg and living indoors, presented with a large, keratinous lesion on the right lateral cheek, brown and black in color. The owner reported that the lesion had developed over three years, with a history of facial trauma from an altercation with another feline.

Physical examination showed no systemic alterations attributable to the cutaneous horn. According to the owner, the mass caused no discomfort during handling and did not affect the cat's normal behavior. Screening with a lateral flow immunochromatographic assay was negative for FIV and FeLV.

Surgical excision was selected as the treatment. The patient was sedated, and the area around the lesion was clipped and prepared aseptically. The mass, located on the right side of the face, measured 9.5 × 1.5 × 1.5 cm (Figure 1). It was cylindrical, firm, dark brown to black, and keratinized, with a central cystic cavity containing grayish material. The specimen was fixed in 10% neutral buffered formalin and submitted for histopathological evaluation.



Figure 1. Gross appearance of a cutaneous lesion in a cat, located on the right side of the face, measuring 9.5 × 1.5 × 1.5 cm. The mass was cylindrical, firm, and dark brown to black, with a keratin-like appearance, consistent with a cutaneous horn.

The tissue was routinely processed and stained with hematoxylin and eosin (H&E). In the deep dermis, a cyst lined by stratified, well-differentiated squamous epithelium with a prominent granular layer was observed, consistent with an infundibular origin. The lumen contained compact, laminated, partially pigmented keratin with focal parakeratosis (Figure 2). These findings are consistent with a dilated pore (Winer's type), a proliferative variant of the feline infundibular follicular cyst. Keratinocyte hyperplasia with a prominent granular layer and extensive laminated keratin contributed to the formation of the giant cutaneous horn. Histological margins were free of the lesion.

The prognosis was considered favorable following complete surgical excision of the lesion. The surgical site showed excellent healing, and no recurrence has been observed up to the time of publication.

Discussion

The diagnosis was established based on the characteristic clinical presentation and histopathological findings, without the need for complementary techniques such as immunohistochemistry.

Trauma to the skin can induce epidermal and follicular hyperkeratosis, acanthosis, and obstruction of follicular ostia, leading to keratin retention. This mechanism is well recognized in the pathogenesis of follicular cysts (1). In this case, local trauma likely triggered epidermal and follicular proliferation, resulting in a dilated pore, a proliferative variant of the feline infundibular cyst analogous to

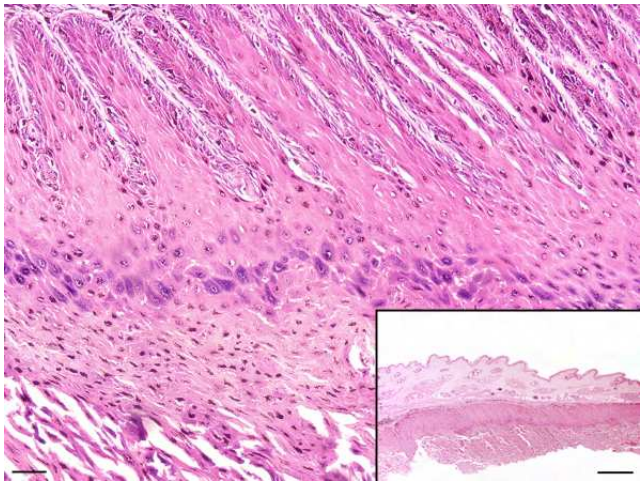

Figure 2. Histological section of a cat skin showing a cyst lined by stratified, well-differentiated squamous epithelium with a prominent granular layer, consistent with an infundibular origin. Compact, laminated, and partially pigmented keratin with focal areas of parakeratosis filled the cystic lumen. H&E stain; bar = 40 µm. Inset - The cyst in the deep dermis. H&E stain; bar = 1000 µm.

Winer's dilated pore in humans. However, a direct causal relationship cannot be definitively established, and its role in the development of the associated cutaneous horn remains uncertain (5).

A retrospective study of 14 feline Winer's dilated pore cases found that 71% were initially misdiagnosed, most often as keratinous cysts, highlighting diagnostic challenges (5). Cutaneous horns are considered uncommon in this species, with relatively few cases described in the veterinary literature, which may also reflect underreporting or misclassification. Identifying the underlying lesion is crucial, as cutaneous horns can arise from a wide range of benign and malignant conditions, even though the horn itself reflects only morphology, not the biological behavior of the base lesion. Reported underlying lesions include actinic keratosis, papillomas, viral papillomas, Bowen's disease (squamous cell carcinoma *in situ*), invasive squamous cell carcinoma, and infundibular keratinizing acanthoma or dilated pores (3).

In humans, actinic keratosis, which can progress to invasive squamous cell carcinoma, is the most common underlying lesion associated with cutaneous horn formation, particularly in sun-exposed areas. In the present case, the cat developed a facial horn, and no histopathological changes consistent with actinic keratosis were observed. This was an anticipated finding, as dark pigmentation against UV radiation. In human medicine, horns larger than their base are more likely associated with squamous cell carcinoma. Interestingly, in this feline case, despite the horn exceeding its base, histopathology revealed a benign Winer's dilated pore, a rare finding in animals (9, 4).

In cats, multiple cutaneous horns on the footpads have been linked to Feline Leukemia Virus (FeLV) infection, with viral particles detected in lesions (12). Some studies suggest a broader association between FeLV and horn development (7). In this case, however, FIV and FeLV tests were negative.

The diagnosis was established based on the characteristic clinical presentation and histopathological findings, without the need for complementary techniques such as immunohistochemistry. Histopathology is essential for definitive diagnosis, allowing differentiation between benign and potentially malignant lesions. Early recognition is clinically important, as it guides appropriate treatment, which usually consists of complete surgical excision.

This unusual presentation of a giant facial cutaneous horn associated with a dilated pore expands the spectrum of reported cases in cats and highlights the importance of considering follicular lesions in its pathogenesis. Furthermore, it underscores the clinical relevance of histopathological examination, as the underlying lesion may vary despite a characteristic gross appearance, while complete surgical excision remains an effective approach with a favorable prognosis.

Data Availability

All the original contributions presented in this study are included in the article/supplementary material. Further inquiries can be directed to the corresponding author.

Author Contributions

Millena Ramos Alves: Conceptualization, Validation, Writing – review & editing. **Adriano de Sales Araujo:** Conceptualization, Validation, Writing – review & editing. **Paula Dias Retamero:** Conceptualization, Validation, Writing – original draft, Writing – review & editing. **Karla Geovanna Pereira Nascimento:** Validation. **Áster Patricia Kerschr Bento:** Validation. **Vivian de Assunção Nogueira Carvalho:** Conceptualization, Validation, Writing – review & editing. **Ticiana do Nascimento França:** Conceptualization, Validation, Writing – review & editing.

Conflict of Interest

The authors declare no competing interests.

Generative AI Use Statement

The authors did not use generative artificial intelligence tools or technologies in creating or editing any part of this manuscript.

References

1. Duclos DD, Hargis AM, Hanley PW. Pathogenesis of canine interdigital palmar and plantar comedones and follicular cysts, and their response to laser surgery. Vet Dermatol. 2008;19(3):134–141. doi: 10.1111/j.1365-3164.2008.00662.x.
2. Golchin D, et al. Mucocutaneous Bowen's disease with a cutaneous horn overgrowth in a German Shepherd dog. Comp Clin Pathol. 2022;31(4):579–584. doi: 10.1007/s00580-022-03368-8.
3. Gross TL, Ihrke PJ, Walder EJ, Affolter VK. Poro dilatado. In: Gross TL, Ihrke PJ, Walder EJ, Affolter VK, eds. Doenças de Pele do Cão e do Gato: Diagnóstico Clínico e Histopatológico. 2nd ed. São Paulo: Roca; 2009:596–697.
4. Kimura R, Sugita K, Goto H, et al. Squamous cell carcinoma manifested as a cutaneous horn: a key to early detection. Yonago Acta Med. 2018;61(2):140–141. doi: 10.33160/yam.2018.06.007.

5. Luther PB, Scott DW, Buerger RG. The dilated pore of Winer: an overlooked cutaneous lesion of cats. J Comp Pathol. 1989;101(4):375–379. doi: 10.1016/0021-9975(89)90020-0.
6. Martínez-Silvestre A, Frye FL. A case of calcinosis cutis and pseudocutaneous horn in a captive red-eared slider (Trachemys scripta elegans). Bol Asoc Herpetol Esp. 2002;13:45–48.
7. Mauldin EA, Peters-Kennedy J. Integumentary system. In: Jubb KVF, Kennedy PC, Palmer N, eds. Pathology of Domestic Animals. 6th ed. Vol 1. Elsevier; 2016:509–736.
8. Pérez E, Molín J, Pérez M, et al. A dilated pore of Winer in a young Iberian Lynx (Lynx pardinus). Acta Vet Beograd. 2023;73(2):271–278. doi: 10.2478/acve-2023-0021.
9. Pyne J, Sapkota D, Wong JC. Cutaneous horns: clues to invasive squamous cell carcinoma being present in the horn base. Dermatol Pract Concept. 2013;3:3–7. doi: 10.5826/dpc.0302a02.
10. Requena L, Requena C, Cockerell CJ. Benign epidermal tumors and proliferations. In: Bolognia J, Jorizzo JL, Schaffer JV, eds. Dermatology. 3rd ed. Elsevier Saunders; 2012:1805–1806.
11. Schosser RH, Hodge SJ, Gaba CR, et al. Cutaneous horns: a histopathologic study. South Med J. 1979;72:1129–1131. doi: 10.1097/00007611-197909000-00014.
12. Souza HJMD, Costa FVA, Dorigon O, Damico CB, Brito MD. Múltiplos cornos cutâneos em coxins palmares e plantares de um gato Persa. Cienc Rural. 2010;40:678–681. doi: 10.1590/S0103-84782010005000036.