Braz J Vet Pathol, 2025, vol. 18, Suppl. 1, e018S119
https://doi.org/10.24070/bjvp.1983-0246.018S119

BJVP
Brazilian Journal of Veterinary Pathology
ISSN 1983-0246

Diagnostic Exercise
From the Latin Comparative Pathology Group and the Davis-Thompson Foundation

Congenital goiter in sibling goat kids

M Kevin Keel[1], Elizabeth C. Rose[2,3], Celeste M Morris[2,4].

[1]Department of Pathology, Microbiology and Immunology (Keel); School of Veterinary Medicine; University of California, Davis; Davis, CA 95616
[2]William R. Pritchard Veterinary Medical Teaching Hospital; School of Veterinary Medicine; University of California, Davis; Davis, CA. 95616
[3]Current address: Department of Population Health and Pathobiology, College of Veterinary Medicine, North Carolina State University, Raleigh, NC 27607
[4]Current address: Department of Veterinary Medicine and Surgery; College of Veterinary Medicine; University of Missouri; Columbia, MO 65211

Corresponding author: mkkeel@ucdavis.edu
Submitted: August 1, 2025. Accepted: August 10, 2025

History: Nine, adult, female Boer goats were presented to the University of California, Davis, Veterinary Medical Teaching Hospital for timed artificial insemination. To synchronize their estrous cycles, the owner gave each doe 7.5 mg dinoprost tromethamine (Lutalyse®) intramuscularly 12 hours prior to presentation and 24 hours prior to removal of the doe's progesterone controlled intravaginal drug release device (EAZI-BREED™ CIDR®). Approximately 52 hours after prostaglandin administration, one of the does delivered two live kids, one female and one male, without complication. The neonates were unexpectedly premature by approximately two weeks. Both kids exhibited bilateral, smooth swelling at the laryngotracheal junction and generalized alopecia. Both kids were euthanized, and they were sent to the UC Davis Anatomic Pathology Service for necropsy.

Autopsy Findings: Both animals had marked gular swelling that corresponded to palpably enlarged thyroid glands (Fig 1). Each also had a soft, short, hair coat, and these changes were most prominent along the dorsum, ventrum, flanks and external aspects of the pinnae (Fig 2). The thyroid glands were approximately 3 x 1.5 x 1 cm in the male and 4 x 2.5 x 2 cm in the female. On cut section, the glands were smooth, firm and dark red. The tongues of both kids were expanded by edema to a maximal thickness of 1 cm. In the female, the loose connective tissue surrounding the trachea and esophagus was also expanded by clear fluid (edema). The mandible of the male extended approximately 1 cm beyond the rostral aspect of the maxilla (mild prognathism). Both kids had scant internal and subcutaneous adipose tissue. Samples of the thyroid glands were submitted for histopathology (Figs 3 and 4).

Follow-up questions:

- *Morphologic diagnosis*:
- *Name the disease*:

The Diagnostic Exercises are an initiative of the Latin Comparative Pathology Group (LCPG), the Latin American subdivision of The Davis-Thompson Foundation (DTF). These exercises are contributed by members and non-members from any country of residence. Consider submitting an exercise! A final document containing this material with answers and a brief discussion will be posted on the DTF website: https://davisthompsonfoundation.org/diagnostic-exercise/

Editor-in-chief for this Diagnostic Exercise: *Claudio Barros*
Associate Editor for this Diagnostic Exercise: *Franklin Riet-Correa*

Histopathology:

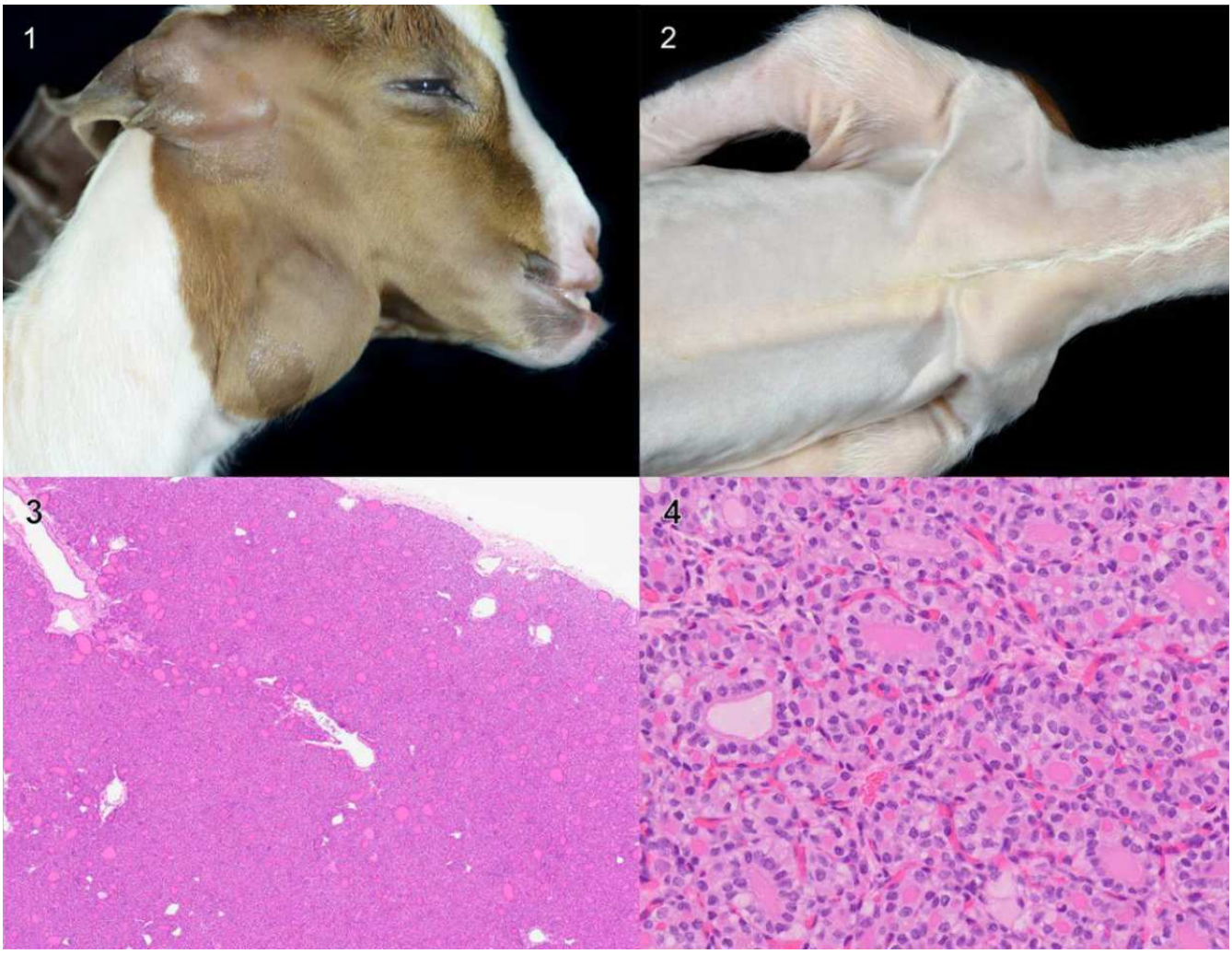

ANSWERS

Microscopic description:

Histologic sections of the thyroid glands from both animals appeared similar; the glands were very cellular with scattered colloid-filled follicles interspersed among hypercellular tissue with poorly discernible follicles (Figure 3). Thyroid epithelial cells in the hypercellular regions surrounded variably collapsed follicular lumens and were occasionally up to 3 cell layers thick (Figure 4). The epithelial cells of the collapsed follicles were crowded, and cuboidal to tall-columnar with basal or central nuclei and moderate amounts of lightly eosinophilic, vacuolated cytoplasm. Follicular lumens contained scant amounts of eosinophilic to pale pink colloid.

Morphologic diagnosis: bilaterally symmetric, follicular cell hyperplasia and hypertrophy of thyroid glands with follicular collapse (consistent with congenital hyperplastic goiter)

Etiology: Inadequate production of thyroid hormone

Comments:

Goiter is a condition in which the thyroid gland is enlarged due to hyperplasia or hypertrophy of thyroid follicular epithelial cells, or the excessive accumulation of colloid, and it has been documented in a wide variety of mammals, birds, reptiles, and other vertebrates (9). Any disease which interferes with normal production of thyroid hormone can result in goiter. Iodine is essential for the synthesis of thyroid hormones, and goiter will occur if there is insufficient iodine in the diet. Physiological deficiency can be caused by ingestion of plant compounds (collectively known as goitrogens),

which interfere with the incorporation of iodine into the thyroid gland (6). Goiter can also result from genetic defects in the enzymes responsible for biosynthesis of thyroidal hormones, and paradoxically by an excess of dietary iodine (6).

Newborn goats are much more significantly affected than adults in the same herd (10). In addition to goiter, decreased thyroid hormone during development often results in alopecia, or partial alopecia, as well as myxedema of the tongue, oropharynx and larynx (1, 6, 9). Myxedema is associated with the accumulation of glycosaminoglycans and may be so severe as to interfere with respiration (6, 9).[1,2] In some cases of severe congenital goiter, the thyroid glands become so enlarged that they contribute to dystocia (6, 9). Prolonged gestation and retention of placentas are also reported (9). Goat kids with goiter are frequently still born or die shortly after birth.

The role of iodine in the development of thyroid hormones is common among vertebrate taxa. Iodine is actively taken up by thyroid follicular cells through a sodium-iodide symporter located in the basal membrane and moves to the apical surface of the cell along an electrochemical gradient (2). Iodide is then transported into the lumen of the follicles by pendrin, an apical iodide/chloride transporter. Thyrocytes also produce the protein thyroglobulin and secrete it into the lumen of follicles, where it forms a major constituent of the colloid. The vesicles responsible for thyroglobulin secretion also carry thyroid peroxidase (TPO), which oxidizes the luminal iodine.

Thyroid peroxidase also incorporates one or two oxidized iodine atoms into select tyrosyl residues of thyroglobulin, to create multiple molecules of monoiodotyrosine (MIT) and diiodotyrosine (DIT). These remain integrated within each thyroglobulin molecule. Under the influence of thyroid stimulating hormone (TSH) some of the iodinated tyrosine residues are conjugated by TPO. Conjugation of one MIT and one DIT yield triiodothyronine (T3), and conjugation of two DIT molecules yield tetraiodothyronine (thyroxine, T4). Both T3 and T4 remain integrated in the peptide chain of thyroglobulin.

Before T3 and T4 can be secreted into the bloodstream, they must be released by hydrolysis of thyroglobulin. This begins with the endocytosis of colloid by thyrocytes, followed by degradation of thyroglobulin in endolysosomes. Subsequently, T4, T3, MIT and DIT are all released (2). Although T3 and T4 are released into the bloodstream, MIT and DIT are largely recycled within the thyrocytes.

All aspects of thyroid hormone production are stimulated by TSH except for iodide transport and oxidation. In addition, TSH can stimulate the proliferation of follicular epithelial cells. If circulating T3 and T4 are insufficient, TSH concentrations are increased leading to hyperplastic goiter.

The only sources of iodine are dietary, and goiter was once common among animals and people in iodine deficient regions such as some mountain ranges, montane rain shadows and some central continental regions (4). Iodine is adsorbed to organic materials and is concentrated in organic-rich sediments and sedimentary rocks. Weathering results in leeching of iodine to the oceans (4). It is abundant in seawater and is returned to the continents through evaporation and rain. However, rainfall farther from the ocean has a lower concentration of iodine (4). The addition of iodine salts to animal feeds has greatly curtailed primary deficiency, but it can still occur in iodine-deficient regions if livestock aren't supplemented.

Goitrogens include cyanogenic glycosides, glucosinolates (syn thioglycosides or thioglucosides) and some flavonoids (5, 6). Flavonoids are organic compounds that naturally occur in plants, usually as pigments (5). Not all flavonoids are goitrogenic, but those that inhibit the iodination of tyrosine by TPO. The cyanogenic glycosides and glucosinolates are common in cruciferous plants (family Brassicaceae; e.g. cabbage, kale, collards, mustard, rapeseed, and broccoli) (1, 6). Toxic metabolites are generated from cyanogenic glycosides (thiocyanate) and glucosinolates (isothiocyanate and thiocyanate) after ingestion (5). These metabolites inhibit the uptake of iodine by thyrocytes; at higher concentrations they may also inhibit TPO (5).

Excessive iodine can also lead to goiter (3,9). Although rare in clinical practice, it could be associated with inappropriate supplementation or consumption of high levels from natural sources (e.g. seaweed) (3). Normally, the thyroid gland is able to reject excessive iodine, possibly through the formation of iodopeptides that prevent organification of thyroglobulin. Goiter results when iodine levels return to normal, but the thyroid gland cannot escape the inhibitory effects. This may be exacerbated by other types of thyroid disease (e.g. inflammation) (3).

A genetic basis for goiter has been described in cattle, sheep, and goats (6, 7). Defects in thyroglobulin synthesis leading to congenital goiter have been suggested in Merino sheep, and various breeds of goat, including South African Boer goats (8). These cases were associated with inadequate production of thyroglobulin, or defective thyroglobulin that was not appropriately iodinated or otherwise led to a reduced production of T3 and T4.

Decreased production of thyroglobulin corresponds to collapsed follicles or lightly staining colloid, as described in these goats. However, in this case, the etiology was not confirmed. The lesions are similar regardless of the ultimate cause of inadequate thyroid hormone in the goat kids. A complete history was not available for the herd.

References

1. Bhardwaj RK. Iodine Deficiency in Goats. In: Goat Science. IntechOpen, 2018.
2. Dunn JT, Dunn AD. Update on intrathyroidal iodine metabolism. Thyroid® 2001;11:407–414.
3. Farebrother J, Zimmermann MB, Andersson M. Excess iodine intake: sources, assessment, and effects on thyroid function. Annals of the New York Academy of Sciences 2019;1446:44–65.

4. Fuge R. Soils and Iodine Deficiency. In: Selinus O, ed. Essentials of Medical Geology: Revised Edition. Dordrecht: Springer Netherlands, 2013;417–432.
5. Gaitan E. Goitrogens, Environmental. In: Martini L, ed. Encyclopedia of Endocrine Diseases. New York: Elsevier, 2004;286–294.
6. Nowek Z, Mickiewicz M, Biernacka K, et al. Causes of goiter in goats | [Przyczyny powstawania wola u kóz]. Medycyna Weterynaryjna 2023;79:6776–2023.
7. Pammenter M, Albrecht C, Liebenberg W, et al. Afrikander cattle congenital goiter: characteristics of its morphology and iodoprotein pattern. Endocrinology 1978;102:954–965.
8. Rac R, Hill GN, Pain RW, et al. Congenital goitre in Merino sheep due to an inherited defect in the biosynthesis of thyroid hormone. Research in Veterinary Science 1968;9:209–225.
9. Rosol TJ, Gröne A. Endocrine glands. In: Jubb, Kennedy & Palmer's pathology of domestic animals. Vol 3. Elsevier Health Sciences, 2015;269–357.
10. van Jaarsveld P, Theron C, van der Walt B, et al. Congenital goitre in South African boer goats. J S Afr Vet Med Assoc 1971; 42:295–303.