Braz J Vet Pathol, 2025, vol. 18, Suppl. 1, e018S122
https://doi.org/10.24070/bjvp.1983-0246.018S122

BJVP
Brazilian Journal of Veterinary Pathology
ISSN 1983-0246

Diagnostic Exercise
From the Latin Comparative Pathology Group and the Davis-Thompson Foundation

Xanthogranulomatosis in an eclectus parrot

Carmina Migoni[1], Michelle Rubio Sánchez[2], Francisco A. Uzal[3], Javier Asin[3], Eileen Henderson[3]*

[1]Instituto de Investigaciones en Ciencias Veterinarias, Universidad Autónoma de Baja California, México.
[2]Facultad de Medicina Veterinaria y Zootecnia, Universidad Nacional Autónoma de México, México.
[3]California Animal Health and Food Safety Laboratory system, San Bernardino branch, University of California-Davis.

***Corresponding author:** eehenderson@ucdavis.edu
Submitted: August 15, 2025. Accepted: August 22, 2025.

History: A 14-year-old female eclectus parrot was submitted for necropsy with a history of abdominal distension and weight gain

Autopsy Findings: The carcass was in good nutritional condition, with prominent pectoral musculature and abundant coelomic fat deposits. Dark red clotted blood was present within the anterior portion of the coelomic cavity and adhered to both the capsular surface of the liver and the pleural surface of the lungs. The liver was mottled red to tan, friable, and had rounded edges. Within the caudal half of the abdomen, there was a 5.5 cm x 5 cm x 2.5 cm black/grey to yellow, soft mass (Fig. 1) with multiple fluid filled cysts.



Figure 1. Gross appearance of black/grey to yellow intracoelomic mass.

**The Diagnostic Exercises are an initiative of the Latin Comparative Pathology Group (LCPG), the Latin American subdivision of The Davis-Thompson Foundation and published in cooperation with the Brazilian Journal of Veterinary Pathology. These exercises are contributed by members and non-members from any country of residence. Consider submitting an exercise! A final document containing this material with answers and a brief discussion will be posted on the CL Davis website: https://davisthompsonfoundation.org/diagnostic-exercise/*

Editor-in-chief for this Diagnostic Exercise: *Claudio Barros*
Associate Editor for this Diagnostic Exercise: *Francisco A Uzal*

Follow-up questions:

- *Morphologic diagnosis*
- *Microscopic description*
- *Name the disease*

ANSWERS

Morphological diagnosis:

Xanthogranulomatous coelomitis

Microscopic description:

The coelomic mass was characterized by a central region of necrosis surrounded by macrophages, multinucleated giant cells, extracellular deposits of pale-yellow material, and dissecting bands of fibrous connective tissue. The macrophages often contained variable numbers of clear intracytoplasmic vacuoles with sharply demarcated borders (Fig. 2).

Additionally, there were globules of deeply eosinophilic proteinaceous material and deposits of pale-yellow extracellular material similar to what was noted within the coelomic mass.

Name the disease

Intracoeoelomic xanthogranulomatosis

Comments:

Xanthomas are non-neoplastic accumulations of yellowish, cholesterol-rich material, foamy macrophages and necrosis with infiltration of heterophils, lymphocytes and multinucleated giant cells. In psittacine birds, these lesions are typically observed in adult individuals, ranging from 3 to 30 years of age, with an average of around 10 years. Xanthomas commonly appear on the skin over the ventral abdomen, thighs, wings, eyelids, and facial regions. Internal organ or bone marrow involvement is rare. Clinically, the lesions may present as pruritic nodules and are frequently associated with other abnormalities such as lipomas, hernias, or areas of chronic irritation. Although the exact etiology remains unclear, contributing factors may include high-fat or cholesterol-rich diets, genetic predispositions, or repeated trauma (6).

Xanthogranulomatous disease, also known as xanthogranuloma(s), xanthomatosis, or xanthoma(s), has been inconsistently defined. While xanthogranulomas are generally considered benign, their clinical significance can vary depending on their location and the extent of organ involvement (Table 1). Although cutaneous lesions are the most frequently reported, extracutaneous and systemic manifestations have also been documented (1). Xanthogranulomatosis is recognized as a common dermatologic condition in avian species. This inflammatory process, which may be linked to lipid metabolism disorders, is primarily localized to the skin, a finding still rarely described in avian medicine. Xanthogranulomatosis is most often reported in Cockatiels (*Nymphicus hollandicus*) and Budgerigars (*Melopsittacus undulatus*), where it manifests as non-neoplastic yet focally infiltrative yellow to orange nodules or plaques composed

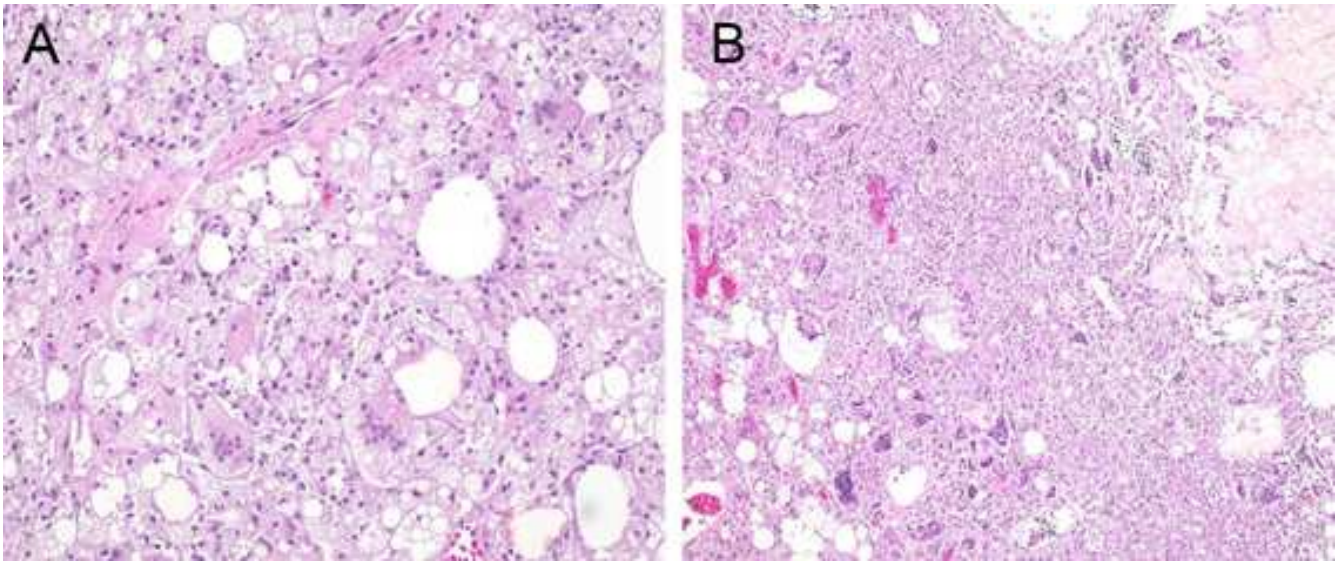

Figure 2. Intracoelomic mass. Numerous macrophages, many of them lipid-laden, and multinucleated giant cells are present throughout the mass. H&E.

Table 1. List of differential diagnosis for xanthomatosis and common neoplasms of birds.

System	Name	Description
Integumentary and soft tissue	Squamous Cell Carcinoma	Malignant tumor of the epithelial cells lining certain tissues or organs. These can occur anywhere on the body and are commonly seen on the feathered skin, beak, uropygial gland, and phalanges and in the upper gastrointestinal tract (in particular affecting the crop) (6).
Integumentary and soft tissue	Lipoma	Benign neoplasms of adipose tissue, most commonly found in the subcutaneous tissues and can arise anywhere on the body, including inside the thoracic or coelomic cavity (6).
Soft tissue	Fibrosarcoma	A malignant tumor of fibrous tissue. They are locally invasive, and metastasis is uncommonly reported. They are most commonly seen in the facial/oral regions and bones and can be seen in the coelomic cavity or cloaca as well (6).
Hematopoietic	Lymphoma	Can manifest in birds as a visceral, cutaneous, retrobulbar or periorbital, oral, or leukemic disease (6).
Urogenital	Granulosa cell tumor and oviductal adenocarcinoma	Clinical signs include persistent breeding behavior, egg retention, and coelomic distention secondary to ascites or organomegaly, diffuse coelomic metastasis is common (6).
Urogenital	Seminoma	Tumors of immature germ cells, grossly appear yellow-red and cause enlargement of the testis (4).
Urogenital	Sertoli Cell Tumor	Primary testicular tumors of gonadal-stroma that arise from the Sertoli (sustentacular) cells. Are generally firm, gray-white neoplasms that appear nodular on section (4).

of lipid deposits (4,5). These lesions typically develop in regions subjected to trauma, pressure, hemorrhage, or chronic inflammation, though visceral and bone marrow involvement remains exceedingly uncommon (8).

Recently, a disseminated form of xanthogranulomatosis has been described in Eclectus Parrots (*Eclectus roratus*) and Budgerigars (3). This variant is histologically characterized by the presence of intracoelomic mass(es) composed of lipid-laden macrophages, extracellular lipids, characteristic cholesterol clefts and hemorrhage; the inflammatory response varies, with infiltration by heterophils and lymphocytes, as well as the formation of multinucleated giant cells, fibrosis and occasional necrosis (7). In some cases, these lesions may become locally invasive (2).

Disseminated coelomic xanthogranulomatosis remains a rare and poorly understood condition in birds. However, emerging evidence suggests that Eclectus parrots may exhibit a predisposition to this form of the disease, warranting further investigation into potential species-specific risk factors and pathogenic mechanisms (1).

References:

1. Ambar N, Mans C, Gasper DJ. Antemortem Diagnosis and Successful Long-term Management of Disseminated Intracoelomic Xanthogranulomatous Disease in an Eclectus Parrot (*Eclectus roratus*). *Journal of Avian Medicine and Surgery*. 2024; 37(4):330-8.
2. Donovan TA, Garber MM, Phalen D, Reavill D, Monette S, Le Roux AB, Hanson M, Chen S, Brown C, Echeverri C. aand QuesenberryK. Disseminated Coelomic Xanthogranulomatosis in Eclectus Parrots (*Eclectus roratus*) and budgerigars (*Melopsittacus undulatus*). *Veterinary Pathology*. 2022; 59: 143-151.
3. Konicek C, Heenemann K., Craner K., Vahlenkamp T.W., Schmidt V. Case Series of Disseminated Xanthogranulomatosis in Red-crowned Parakeets (*Cyanoramphus novaezelandiae*) with Detection of Psittacine Adenovirus 2 (PsAdV-2). Animals 2022; 12: 2316.
4. Raynor, P.L. Periosseous xanthogranulomatosis in a fledgling great horned owl (*Bubo virginianus*). J. Avian Med. Surg. 1999, 13, 269–274.
5. Reavill DR, Dorrestein G.M. Pathology of aging psittacines. Vet Clin North Am Exot Anim Pract. 2010;13 (1):135-50.
6. Reavill, D.R. and Dorrestein G.M in Terio K.A., McAloose D., St.Leger J. Pathology of Wildlife and *Zoo Amals*; Academic Press: San Diego, CA, USA, 2018; p. 776.
7. Robat C.S., Ammersbach M., Mans C. Avian Oncology: Diseases, Diagnostics, and Therapeutics. Vet Clin North Am Exot Anim Pract. 2017;20 (1):57-86.
8. Schmidt, RE, Reavill, DR, Phalen, DN. Pathology of Pet and Aviary Birds, 2nd ed.; Wiley Blackwell: Ames, IA, USA, 2015; p. 194.