Braz J Vet Pathol, 2025, vol. 18, Suppl. 1, e018S126
https://doi.org/10.24070/bjvp.1983-0246.018S126

BJVP
Brazilian Journal of Veterinary Pathology
ISSN 1983-0246

Diagnostic Exercise
From the Latin Comparative Pathology Group and the Davis-Thompson Foundation

Nasal neuroendocrine carcinoma in a dog

Yiqing Gong[1], Lina Crespo Bilhava[1], Emily Swan[2], Elizabeth Parsley[3], Elise LaDoucer[2], Leslie Sharkey[3], Emily Brinker[1*]

[1]Department of Comparative Pathobiology, Cummings School of Veterinary Medicine, Tufts University, North Grafton, MA 01536
[2]Joint Pathology Center, Silver Spring, MD 20910
[3]Department of Clinical Sciences, Cummings School of Veterinary Medicine, Tufts University, North Grafton, MA 01536

***Corresponding author:** Emily.Brinker@tufts.edu

History:

A 10-year-old male neutered Golden Retriever dog presented for seizures and a tendency for clockwise circling. A large extra-axial homogenously contrast-enhancing mass was seen with magnetic resonance imaging in the right frontal lobe/olfactory bulb area extending into the nasal cavity. A transfrontal craniotomy with debulking was performed with cytological touch impressions and biopsy. Acute-onset focal seizures and episodes of compulsive circling started around 1 month following surgery, with regrowth of the extra-axial mass with secondary perilesional edema on imaging. Euthanasia was elected.

Cytologic findings:

Impression smears are characterized by numerous lysed cells and abundant nuclear streaming material. The predominant population consists of round to polygonal cells, observed individually or in poorly cohesive aggregates (Figure 1). These cells contain small to moderate amounts of pale basophilic, poorly defined cytoplasm, which occasionally contains discrete, small, colorless vacuoles. The nuclei are round to oval, with finely stippled chromatin and no visible nucleoli. Anisocytosis and anisokaryosis are mild to moderate within this population, and pyknosis and mitotic figures are frequently observed. Numerous macrophages are present, often containing intracytoplasmic apoptotic cell fragments (tingible-body macrophages). Scant nondegenerate neutrophils and plasma cells are also observed.

Autopsy findings:

On necropsy, the cribriform plate and caudal portion of the ethmoid turbinates are absent, replaced by soft, malacic, hemorrhagic, friable tissue (Figure 5)**.** Histologically**,** similar neoplastic cells as seen on biopsy are present in this tissue.

*The Diagnostic Exercises are an initiative of the Latin Comparative Pathology Group (LCPG), the Latin American subdivision of The Davis-Thompson Foundation (DTF). These exercises are contributed by members and non-members from any country of residence. Consider submitting an exercise! A final document containing this material with answers and a brief discussion will be posted on the DTF website: https://davisthompsonfoundation.org/diagnostic-exercise/

Editor-in-chief for this Diagnostic Exercise: *Claudio Barros*
Associate Editor for this Diagnostic Exercise: *Francisco Carvallo*

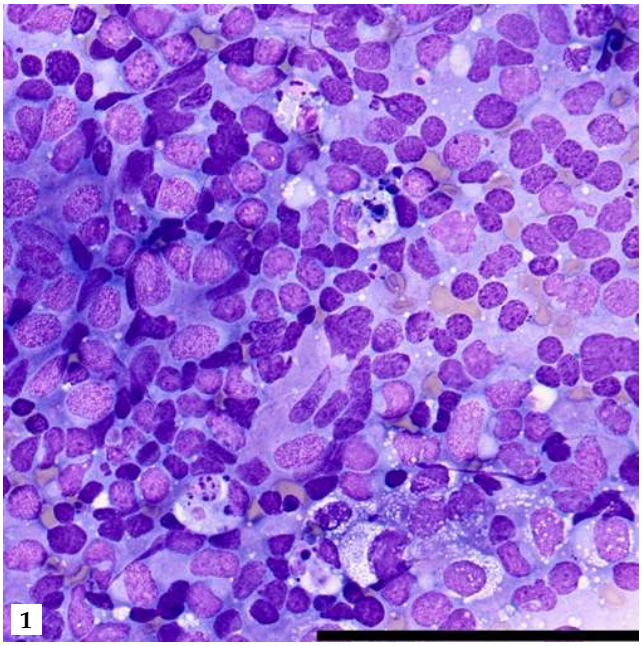

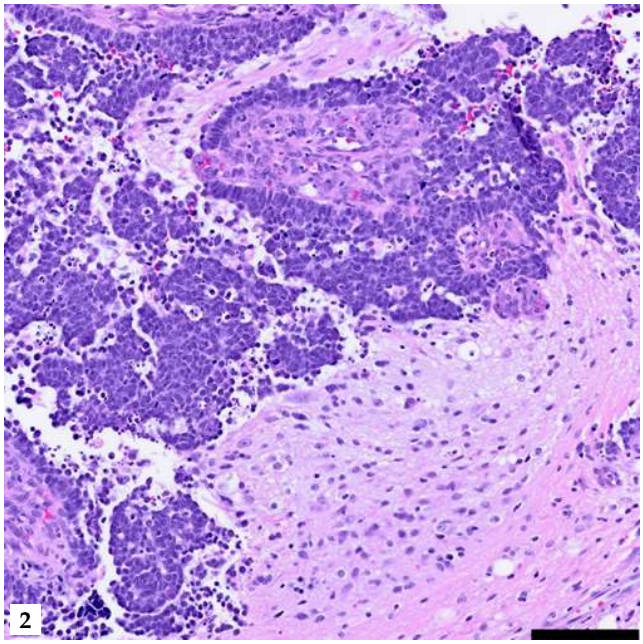

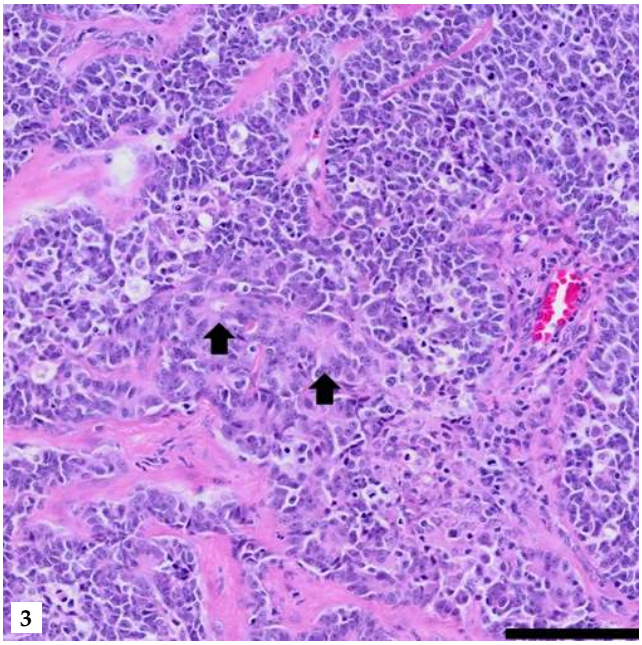

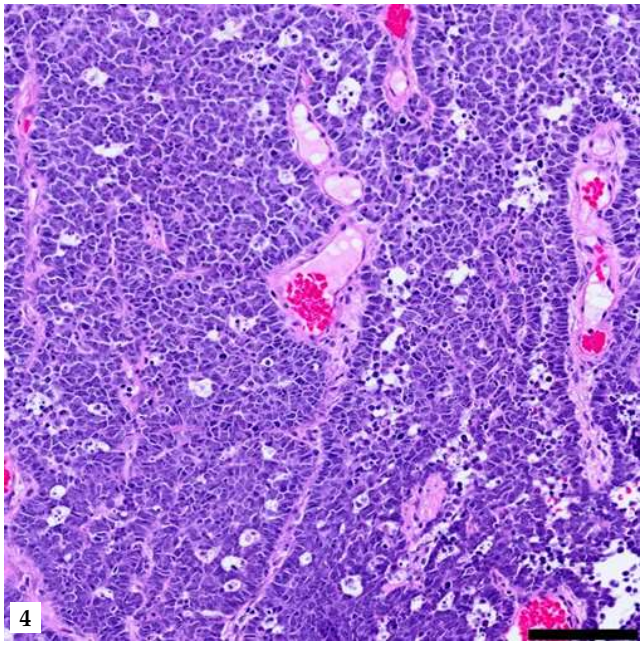

Figure 1. Impression smear showing loosely associated neoplastic cells and tingible body macrophages. Wright–Giemsa. **Figure 2.** The neoplasm invades the brain. H&E. **Figure 3.** Neoplastic cells form Flexner-Wintersteiner rosettes (arrows). H&E. **Figure 4.** Polygonal neoplastic cells on the periphery of the trabeculae and sheets palisade along the basement membrane. H&E. Scale bar = 100 µm.

Histopathologic findings of frontal lobe/olfactory bulb mass:

A densely cellular neoplasm invades and distorts a small portion of the attached cerebrum (Figure 2). The neoplasm is composed of polygonal cells arranged in sheets, trabeculae, Homer-Wright and Flexner-Wintersteiner rosettes, and pseudorosettes within a fibrovascular stroma (Figure 3). Neoplastic cells have a scant amount of amphophilic cytoplasm with discrete cell borders. Nuclei are round to ovoid with finely stippled chromatin and indistinct nucleoli. Anisocytosis and anisokaryosis are moderate. There are 69 mitotic figures in ten consecutive 400x fields (2.37 mm^2). Neoplastic cells palisade along the basement membrane at the periphery of the neoplastic sheets and trabeculae (Figure 4). Numerous tingible body macrophages are scattered throughout the neoplasm, creating a "starry sky"

appearance. The cerebral tissue directly surrounding the neoplasm is hemorrhagic.

Follow-up questions:

- *Differential diagnoses:*
- *What immunohistochemistry (IHC) would you perform?*
- *What electron microscopy findings (EM) should be assessed for definitive diagnosis?*

ANSWERS

1. Differential diagnoses:

Olfactory neuroblastoma (esthesioneuroblastoma), neuroendocrine carcinoma

2. What immunohistochemistry (IHC) would you perform?

Immunomarkers such as chromogranin A (Figure 6) and synaptophysin would confirm neuroendocrine differentiation, both of which were both expressed by this neoplasm (Table 1).

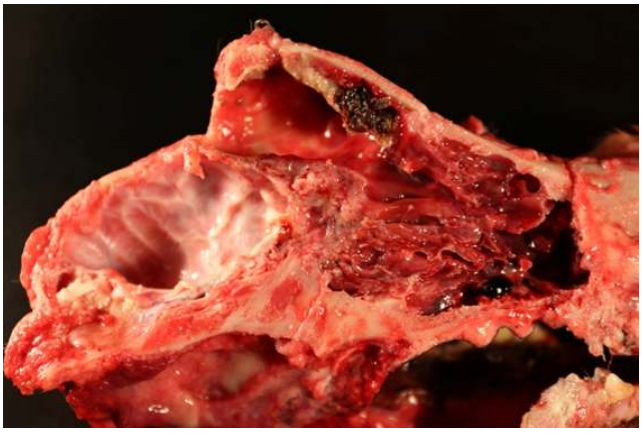

Figure 5. The neoplasm in the caudal ethmoid turbinate effaces the cribriform plate.

Immunohistochemical markers that target microtubules, βIII-tubulin (TuJ) and microtubule-associated protein 2 (MAP2), have been used to differentiate between olfactory neuroblastomas and neuroendocrine carcinomas.

3. What electron microscopy (EM) findings should be assessed for definitive diagnosis?

Of the differential diagnoses, both olfactory neuroblastomas and neuroendocrine carcinomas have neurosecretory granules, but only olfactory neuroblastomas have microtubules (Table 2). On electron microscopy, the neoplasm in this case had cytoplasmic neurosecretory granules and lacked microtubules (Figure 7), consistent with a neuroendocrine carcinoma rather than an olfactory neuroblastoma.

Comments:

The diverse group of "small round blue cell tumors" presents diagnostic challenges to the pathologist due to overlapping and non-distinctive histomorphology, which needs to be aided by techniques like immunohistochemistry,

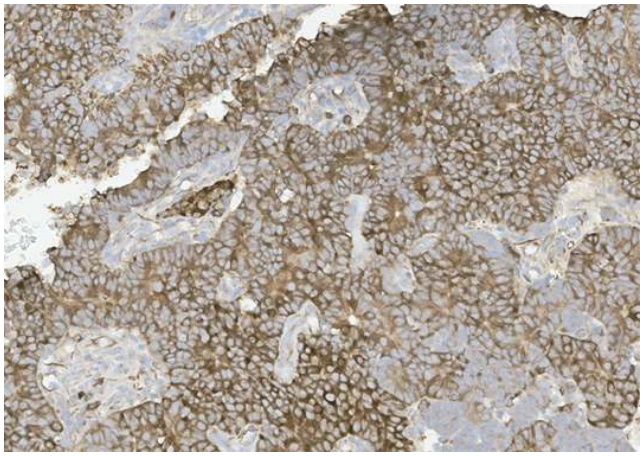

Figure 6. Chromogranin-A immunohistochemistry. Diffusely, neoplastic cells have strong cytoplasmic immunoreactivity to chromogranin A.

Table 1. Immunohistochemical profile of the neoplasm.

IHC Marker	Control cell type	Immunoreactivity for this neoplasm
Pancytokeratin (AE1/AE3)	Epithelial cells	Strong multifocal cytoplasmic immunoreactivity
Chromogranin A	Neuroendocrine cells	Strong multifocal immunoreactivity
Synaptophysin	Neuroendocrine cells	Weak to moderate multifocal cytoplasmic immunoreactivity
Neuron Specific Enolase (NSE)	Neurons and neuroendocrine cells	Strong multifocal cytoplasmic immunoreactivity
S100	Neural crest cells	Weak to moderate diffuse cytoplasmic immunoreactivity
Glial Fibrillary Acidic Protein (GFAP)	Astrocytes	Immunonegative

Table 2. Major findings used to differentiate between caudal olfactory neoplasms with sheet-like epithelial to neuroendocrine morphology[7].

Tumoral type	Histology	EM Findings	IHC Findings
Olfactory neuroblastoma	Polygonal cells in lobules and clusters in neurofibrillary matrix of sustentacular cells, rosettes	Frequent dendritic processes Neurosecretory granules Microtubules Rare synapses	TuJ-1 +/- MAP2, pancytokeratin, synaptophysin, chromogranin A, NSE, S100, neurofilament
Neuroendocrine carcinoma	Sheets, nests and cords with peripheral palisading, rosettes	Neurosecretory granules Absent dendritic processes Close apposition of cell membranes with rare primitive cell junctions	+/- pancytokeratin, synaptophysin, chromogranin A, NSE
Undifferentiated carcinoma	Sheets of round to polygonal cells, cellular atypia and pleomorphism	Close apposition of cell membranes with primitive to well-developed desmosomal cell junctions No neurosecretory granules	Pancytokeratin +/- synaptophysin, S100, chromogranin A

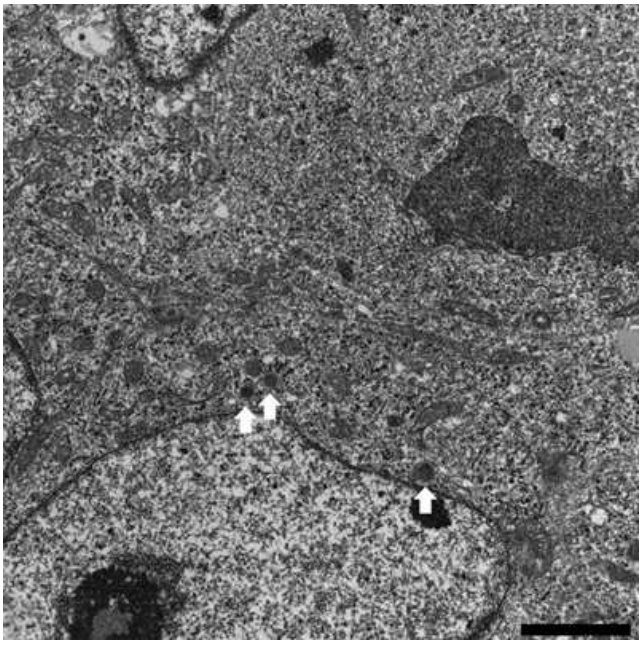

Figure 7. Neoplastic cells are densely packed with cell membranes joined by small desmosomes. Nuclei are irregularly round to oval with mixed euchromatin and heterochromatin. Within the cytoplasm, there are a few membrane-bound dense core secretory granules (arrows) and empty, clear membrane-bound vacuoles, as well as clusters of mitochondria, endoplasmic reticulum, and free ribosomes. Neurofilaments, microtubules, and dendritic processes are not observed. Transmission electron microscopy. Bar = 2.0 µm.

ultrastructure, and potentially molecular approaches[1]. Differentials for this area include olfactory neuroblastoma (ONB), neuroendocrine carcinoma (NEC), sinonasal undifferentiated carcinoma, poorly-differentiated non-keratinizing squamous cell carcinoma, rhabdomyosarcoma, amelanotic malignant melanoma, primitive neuroectodermal tumor, extramedullary plasmacytoma, and lymphoma[1].

Sinonasal NECs are rarely observed and most commonly reported in dogs, with fewer reports in horses and an isolated report in a raccoon dog[12,11,5,8,10]. These masses tend to be locally aggressive and prone to invade the brain, cranial cavity and cribriform plate[13], as seen in this case[13]. There are a few reports of metastasis to the lungs, various lymph nodes, thyroid glands, adrenal glands, and pituitary gland[11,5,8,10,12]. Olfactory neuroblastomas are rare sinonasal tumors of the olfactory neuroepithelium, and have been reported in veterinary medicine in horses, dogs, cats, and non-mammals like fish and axolotls[6].

The peripheral palisading of neoplastic polygonal cells along the basement membrane of trabeculae and sheets, as well as the formation of rosettes in a nasal tumor, led to an initial general morphological diagnosis of a malignant epithelioid neoplasm with neuroendocrine features. The major differentials based on H&E were ONB, also commonly referred to as esthesioneuroblastoma, or NEC[13]. Given the formation of sheet architecture and the possibility of overinterpretation of poorly differentiated acini lacking a defined basement membrane as rosettes, a lesser differential diagnosis of undifferentiated carcinoma was considered. Due to the overlapping histological features of ONBs and NECs, definitive diagnosis between the two often relies on electron microscopy[13,7]. Therefore, initially, immunohistochemistry for neuroendocrine differentiation and electron microscopy were suggested for a more definitive diagnosis in this case.

Immunohistochemistry to differentiate between ONBs, NECs, and sinonasal carcinomas should be interpreted with caution. The stereotypic neuroendocrine immunomarkers, such as chromogranin A (Figure 6), synaptophysin, neuron-specific enolase, and S100, are variably expressed in olfactory neuroblastomas and neuroendocrine carcinomas (Table 2)[11,3,2]. Additionally, nasal carcinomas have been reported to undergo neuroendocrine differentiation and express the neuroendocrine markers S100, chromogranin A, and synaptophysin and develop agyrophilic, Grimelius staining cytoplasmic granules[9]. Due to potential expression by all three tumors, pancytokeratin, as well, cannot

be used alone to differentiate these neuroendocrine tumors from an undifferentiated carcinoma[3,11,9]. Immunohistochemical markers aimed at differentiating between NECs and ONBs capitalize on the presence of microtubules in ONBs but not NECs[4,11,6]. TuJ-1, a Class III beta-tubulin neuronal cytoskeletal protein, demonstrates strong cytoplasmic immunoreactivity to olfactory neuroblastomas in one study[3], and some propose it as the "marker of choice" to confirm canine ONB diagnosis[3,11]. Microtubule-associated protein 2 (MAP2) has additionally been suggested as a differentiating immunohistochemical marker to react with ONBs, and not NECs, although immunoreactivity is inconsistent[2,3]. Although we did not perform TuJ-1 or MAP2 IHC, ultrastructural findings in our case are definitive for olfactory NEC due to the presence of neuroendocrine granules and the lack of microtubules (Table 2)[13,7].

References:

1. Bridge JA, Bowen JM, Smith RB. The Small Round Blue Cell Tumors of the Sinonasal Area. Head and Neck Pathology. 2010;4**:** 84–93.
2. Brosinski K, Janik D, Polkinghorne A, Von Bomhard W, Schmahl W. Olfactory Neuroblastoma in Dogs and Cats – a Histological and Immunohistochemical Analysis. Journal of Comparative Pathology. 2012;146**:** 152–159.
3. Church ME, Veluvolu SM, Durham AC, Woolard KD. Clinical outcomes, ultrastructure and immunohistochemical features of canine high-grade olfactory neuroblastoma. Veterinary and Comparative Oncology. 2019;17**:** 578–584.
4. Hirose T, Scheithauer BW, Lopes MBS, et al. Olfactory neuroblastoma. An immunohistochemical, ultrastructural, and flow cytometric study. Cancer. 1995;76**:** 4–19.
5. Kubo M, Matsuo Y, Okano T, et al. Nasal neuroendocrine carcinoma in a free-living Japanese raccoon dog (Nyctereutes procyonoides viverrinus). J Comp Pathol. 2009;140**:** 67–71.
6. Lubojemska A, Borejko M, Czapiewski P, Dziadziuszko R, Biernat W. Of mice and men: olfactory neuroblastoma among animals and humans. Veterinary and Comparative Oncology. 2016;14**:** e70–e82.
7. Min K-W. Usefulness of Electron Microscopy in the Diagnosis of "Small" Round Cell Tumors of the Sinonasal Region. Ultrastructural Pathology. 1995;19**:** 347–363.
8. Molazem M, Amini E, Salimi A, Muhammadnejad A, Hasannejad H. Magnetic Resonance Imaging Features of Olfactory Neuroendocrine Carcinoma in a Dog. Iranian Journal of Veterinary Medicine. 2024;18**:** 447–452.
9. Ninomiya F, Suzuki S, Tanaka H, Hayashi S, Ozaki K, Narama I. Nasal and Paranasal Adenocarcinomas with Neuroendocrine Differentiation in Dogs. Veterinary Pathology. 2008;45**:** 181–187.
10. Patnaik AK, Ludwig LL, Erlandson RA. Neuroendocrine carcinoma of the nasopharynx in a dog. Vet Pathol. 2002;39**:** 496–500.
11. Sako T, Shimoyama Y, Akihara Y, et al. Neuroendocrine Carcinoma in the Nasal Cavity of Ten Dogs. Journal of Comparative Pathology. 2005;133**:** 155–163.
12. van Maanen C, Klein WR, Dik KJ, van den Ingh TSGAM. Three Cases of Carcinoid in the Equine Nasal Cavity and Maxillary Sinuses: Histologic and Immunohistochemical Features. Veterinary Pathology. 1996;33**:** 92–95.
13. Wilson DW. Tumors of the Respiratory Tract. In: Tumors in Domestic Animals. 2016:467–498.