Braz J Vet Pathol, 2026, vol. 19, e019017
DOI: https://doi.org/10.24070/bjvp.1983-0246.019017

BJVP
Brazilian Journal of Veterinary Pathology
ISSN 1983-0246

Case Report

Transmural gastrointestinal stromal tumor of the mixed subtype in a canine: case report

Lucas Costa Nogueira[1], Virgilio Zoppi Lemos[1]*, Luise Klawa Jubrael[2], Tábata Maués[3], Angélica Consalter[3], Marcela Freire Vallim de Mello[4]

[1] Multiprofessional Residency in Veterinary Anatomical Pathology, Federal Fluminense University – UFF. Niterói, RJ, Brazil
[2] Multiprofessional Residency in Veterinary Medicine - Surgery and Veterinary Oncology, Federal Fluminense University – UFF. Niterói, RJ, Brazil
[3] Professor Firmino Másrico Filho University Hospital of Veterinary Medicine, Fluminense Federal University – UFF. Niterói, RJ, Brazil
[4] Department of Pathology and Veterinary Clinic, Federal Fluminense University – UFF. Niterói, RJ, Brazil

***Corresponding author:** vzlemos@id.uff.br
Submitted: January 5th, 2026. Accepted: May 6th, 2026.

Abstract
Gastrointestinal stromal tumors (GISTs) are mesenchymal neoplasms originating from interstitial cells of Cajal, characterized, in most cases, by the immunohistochemical expression of c-Kit (CD117). In dogs, they are rare and the associated clinical signs are nonspecific, including vomiting, diarrhea, weight loss, and abdominal pain, which often makes clinical diagnosis difficult. This paper describes a case of GIST in a dog, located in the cecum, detected through imaging exams and diagnosed via anatomopathological evaluation, and immunohistochemical. Macroscopically, the mass was transmural and measured approximately 7.0 cm in diameter, white to dark brown in color, had a soft consistency, and, upon cutting, a smooth, solid surface. Microscopically, the neoplasm was predominantly composed of spindle cells, with multifocal areas of epithelioid cells, both with positive plasma membrane staining for c-Kit and absence of Desmin expression, confirming the diagnosis. This report reinforces the importance of immunohistochemical evaluation in differentiating GISTs from other mesenchymal neoplasms of the gastrointestinal tract and contributes to the understanding of the morphological and clinicopathological aspects of this entity in dogs.

Keywords: c-Kit, dog, GIST, immunohistochemistry, mesenchymal neoplasm.

Introduction

Gastrointestinal neoplasms in dogs are considered rare, representing less than 3% of tumors affecting the species (12). Despite their infrequency, a wide variety of diagnoses can be observed within this group, with distinct histogenesis (3, 8, 9, 13, 16). Among gastrointestinal neoplasms, the most common diagnoses are adenocarcinomas, lymphomas, leiomyosarcomas, and gastrointestinal stromal tumors (GISTs) (22).

GISTs are mesenchymal neoplasms found primarily in the intestine and stomach (4). They are believed to originate from the interstitial cells of Cajal, known as the pacemaker of the gastrointestinal system and responsible for regulating intestinal motility (16, 19).

Recent studies highlight a higher occurrence in mixed-breed dogs, Dachshunds, Poodles, Labradors, and Golden Retrievers (1, 4). There is no clear gender predilection, although there are reports indicating a higher number of cases in males (1, 4, 8). Middle-aged and older animals are the most affected, with a higher prevalence in dogs over 8 years old (1, 4, 8, 9).

Because of their histopathological characteristics similar to smooth muscle neoplasms, it is estimated that, in the past, a significant portion of leiomyosarcoma diagnoses in dogs actually corresponded to GISTs (16, 19). Differentiation

from other neoplasms is mainly made by the distinct immunohistochemical profile of GISTs. In this context, Cajal cells express positive staining for c-Kit proteins, which are transmembrane tyrosine kinase receptor proteins involved in cell differentiation and proliferation, and DOG1, a calcium-dependent chloride channel. Leiomyosarcomas have positive expression for desmin, a widely used smooth muscle marker, while Cajal cells from GISTs generally do not express this protein (4, 5, 17).

Therefore, specific diagnostic determination is fundamental for the appropriate therapeutic choice, since GISTs are responsive to therapy with tyrosine kinase inhibitors, which does not occur with other non-hematopoietic sarcomas (4). Thus, the objective of this work is to report a case of gastrointestinal stromal tumor in a dog, highlighting the histopathological and immunohistochemical aspects.

Case description

A 12-year-old female mixed-breed dog was treated at the University Veterinary Medicine Hospital of the Federal Fluminense University with a chief complaint of a nodule in the ventral cervical region, with a suspected diagnosis of recurrence of cutaneous mast cell tumor. The animal presented with obesity, pale mucous membranes, abdominal tenderness, enlarged prescapular and popliteal lymph nodes, and a grade I/IV mitral valve murmur.

An abdominal ultrasound examination was performed, which revealed a mass of approximately 7.0 centimeters in the mesogastric region, near the transverse colon. Cytopathological examination of the mass, collected by ultrasound-guided puncture, suggested a malignant neoplasm of mesenchymal origin.

Subsequently, due to the inability of the responsible party to perform an abdominal CT scan, exploratory laparotomy and excision of the abdominal mass were chosen. Pre-operative complementary examinations were performed, including blood count, serum biochemistry, chest X-ray, abdominal ultrasound, electrocardiogram, and echocardiogram. The blood count revealed mild anemia, lymphocytosis, and the presence of microfilariae. The echocardiogram revealed myxomatous degeneration of the mitral valve, without hemodynamic repercussions. The electrocardiogram showed an increased P wave, suggestive of left atrial overload. Radiographic examination revealed enlargement of the right atrioventricular region, associated with a vascular pattern, suggesting heart disease and pulmonary congestion. Preoperative abdominal ultrasound revealed, in addition to the previously mentioned mass, bilateral nephropathy, mild gastropathy, dense biliary sludge, and moderate splenomegaly. The ELISA test for Dirofilaria immitis was positive.

During an exploratory laparotomy, it was observed that the abdominal massage originated from the cecum, and a typhlectomy was performed. The excised mass was transmural, with a multinodular and irregular appearance, and measured approximately 7.0 cm in diameter. It presented a white and dark brown color, a soft consistency, and, upon cutting, a smooth, solid, white and brown surface (Fig. 1). The sample was fixed in 10% buffered formalin and subjected to routine histological processing to obtain 3 to 5 µm sections, which were then stained with hematoxylin and eosin (2, 18).

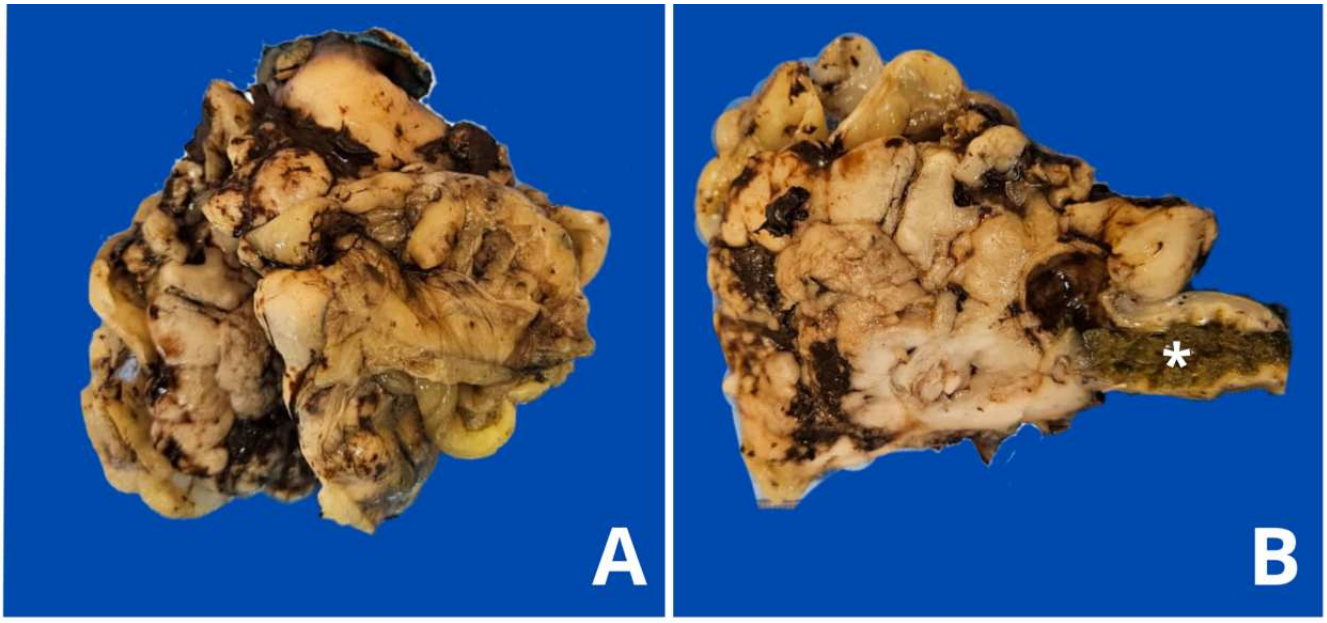

Figure 1. Neoplastic mass in the cecum of a dog. A) Macroscopic aspect of the excised transmural mass, irregular, multinodular, 7.0 cm in diameter and soft consistency. B) Partial section showing the intestinal lumen (*).

Microscopic analysis revealed densely cellular, multinodular neoplastic proliferation in the intestinal muscular layer, continuous with the mucosal layer, involving the intestinal crypts (Fig. 2A and D). The cells were organized in a storiform arrangement, with solid areas, supported by a well-vascularized, abundant fibrocollagenous stroma with areas of loose matrix. They appeared fusiform to epithelioid (Fig. 2B), with eosinophilic cytoplasm, elongated or

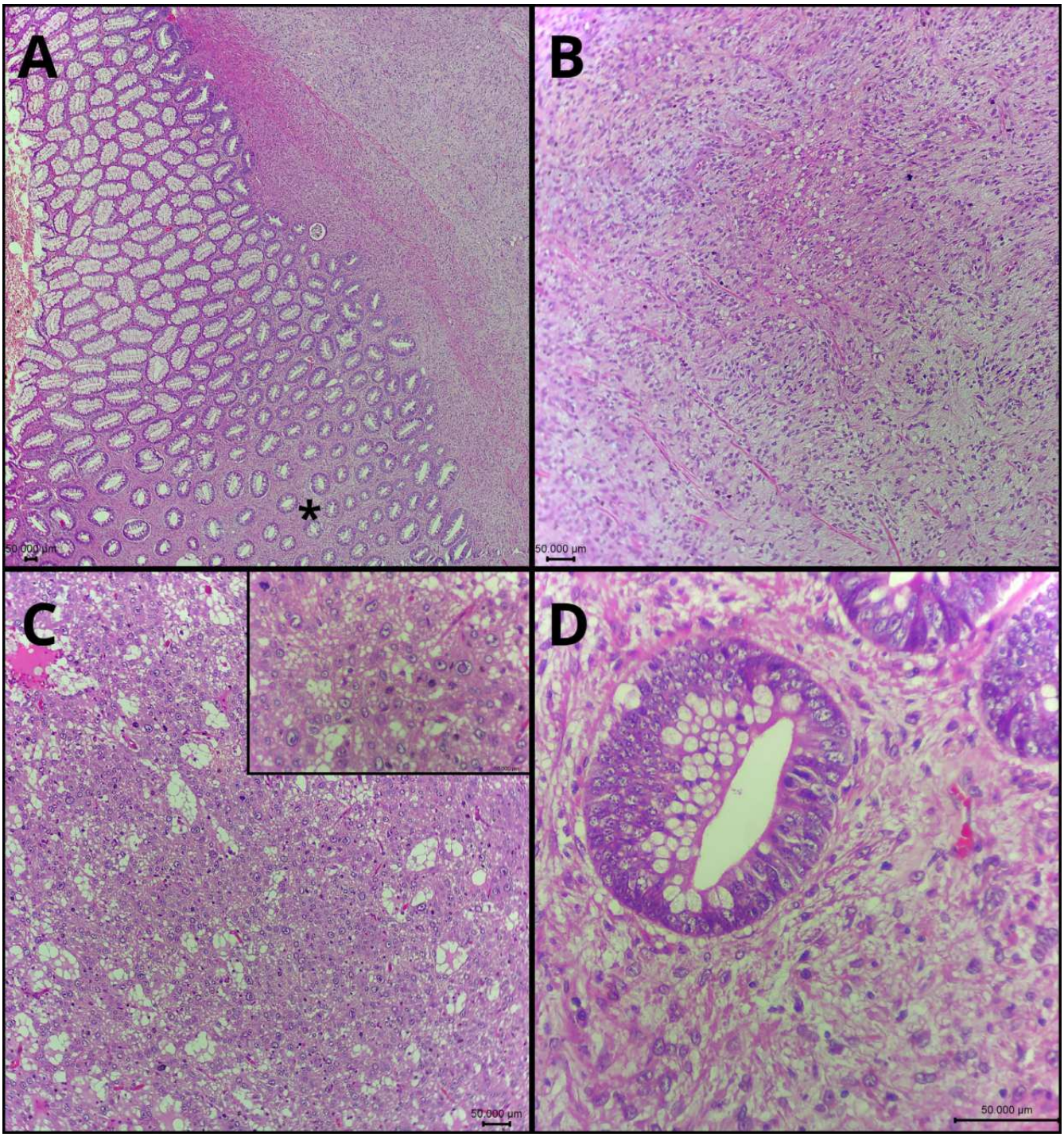

Figure 2. Gastrointestinal stromal tumor, intestine, dog. A) Neoplastic proliferation in the muscular layer, dissecting the mucosa (arrow). Note the attenuation of the intestinal crypts interspersed with neoplastic bundles (*). B) Area composed of spindle cells. C) Area composed of epithelioid cells. Insert: Pleomorphic neoplastic cells, with mitotic figures and intranuclear pseudoinclusions (H&E, 400X). D) Intestinal crypt surrounded by spindle-shaped neoplastic cells. Hematoxylin and eosin staining, A=40X, B and C=100X and D=400X.

cigar-shaped nuclei, coarse chromatin, and prominent nucleoli. There was marked anisocytosis and anisokaryosis, karyomegaly, and frequent bizarre cells, in addition to eosinophilic intranuclear pseudoinclusions resulting from cytoplasmic invagination (Fig. 2C). Extensive areas of hemorrhage were also observed, in addition to lymphoplasmacytic inflammatory infiltrate in the mucosal region. Ten mitotic figures, both typical and atypical, were counted in 15 fields (40x objective/FN18/2.37 mm²). The morphological diagnosis was compatible with spindle cell sarcoma, suggestive of GIST or leiomyosarcoma.

For diagnostic confirmation, the material was submitted to immunohistochemical examination with the markers CD117 (c-Kit) and Desmin. A primary mouse monoclonal antibody anti-c-Kit (ThermoFisher, code 180066) was used at a 1:200 dilution and a mouse monoclonal antibody anti-Desmin (Cell Marque, clone D33) at a 1:1000 dilution (12). In both cases, antigen retrieval was performed in citrate solution pH 6, in a commercial pressure cooker (Muscae Plus, Erviegas). The detection system used was Envision (HRP polymer, Dako), with diaminobenzidine (DAB) as chromogen and counterstaining with hematoxylin (12). Protein blocking was performed with a commercial universal solution (Dako), while endogenous peroxidase was inactivated with 8% hydrogen peroxide in methanol (Dinâmica) (12). Canine pancreas was used as a positive control for c-Kit and skeletal muscle for desmin, and mouse immunoglobulin (ThermoFisher) was replaced as a negative control (12). Neoplastic cells exhibited diffuse and intense cytoplasmic immunostaining for c-Kit, confirming the diagnosis of GIST (Fig. 3A-C), while the absence of desmin staining (Fig. 3D) ruled out the hypothesis of leiomyosarcoma.

Discussion

Clinically, the signs observed in dogs with GISTs are usually nonspecific, such as vomiting, diarrhea, anorexia, weight loss, and abdominal pain (1, 4, 15). This nonspecificity results from the expansive growth of the mass, which promotes mechanical compression of adjacent intestinal loops, altered motility, and partial obstruction of intestinal transit. Furthermore, ulceration of the overlying mucosa can result in intraluminal hemorrhage, leading to melena or anemia (9, 15). In some cases, clinical signs only manifest in advanced stages, when the tumor volume or ulceration becomes clinically significant (15). In the present report, the presence of mild anemia may be associated with both diagnosed dirofilariasis and micro-hemorrhages of the cecal mucosa and paraneoplastic syndrome.

The diagnosis of gastrointestinal stromal tumor was established based on ultrasound, histopathological, and immunohistochemical findings. The ultrasound revealed a mass in the mesogastric region, without a clear definition of origin, a finding consistent with descriptions of GISTs, which generally present as large, expansive masses that make it difficult to determine the primary site until surgical exploration (16). In the present case, the cecal origin was only confirmed during laparotomy, reinforcing the importance of intraoperative assessment for anatomical definition. This finding corroborates reports that the cecum is one of the main sites of GIST involvement in dogs, reinforcing the need for detailed inspection of this region in suspected cases (9, 13).

Microscopically, the neoplasm was predominantly composed of spindle-shaped cells in storiform arrangement, with solid areas, characteristics more frequent in canine GISTs (1, 4). However, polygonal cells with an epithelioid appearance were also observed, which, although less common, are part of the morphological spectrum described in GISTs, and may occur in isolation or mixed with the spindle pattern (9, 16). The coexistence of these patterns reinforces the morphological heterogeneity of the neoplasm and the limitations of diagnosis based solely on conventional histopathology. Intranuclear pseudoinclusions are cited in different neoplasms; however, in cases of GISTs, they are correlated with greater cellular pleomorphism and malignancy (20, 21).

The simultaneous presence of fusiform and epithelioid patterns can lead to diagnostic difficulties when considering only morphology, since smooth muscle neoplasms or even poorly differentiated carcinomas can be considered differential diagnoses (19). In this context, diffuse positive staining for c-Kit was crucial for confirming GIST, while the absence of Desmin expression allowed for ruling out leiomyosarcoma. It is worth highlighting that, in cases of c-kit negativity, the use of markers such as DOG1 can be fundamental for diagnostic confirmation, especially in cases with a predominantly epithelioid pattern (5, 17).

The choice of canine pancreas as a positive control was appropriate, since this tissue exhibits basal expression of c-Kit in some cell populations, ensuring the reactivity of the technique (7, 16). This methodological care strengthens the reliability of the results, since the standardization of immunohistochemistry is still a challenge in laboratories, and may influence diagnostic sensitivity.

GISTs frequently exhibit activating mutations in the c-KIT gene, generating direct implications for therapeutic management, with the possibility of using tyrosine kinase inhibitors, such as toceranib phosphate, in adjuvant therapy, which has demonstrated considerable prognostic efficacy (1, 6, 11). In contrast, leiomyosarcomas generally do not present such mutations, making the use of conventional cytotoxic chemotherapy, such as doxorubicin, preferable. Therefore, from a clinicopathological point of view, confirmation of GIST is relevant because, in addition to characterizing the histogenetic origin of the neoplasm, it guides potential therapeutic strategies. In the present case, both cell populations, spindle-shaped and solid, showed positive immunostaining for c-Kit, confirming the homogeneity of the immunophenotypic profile of the neoplasm,

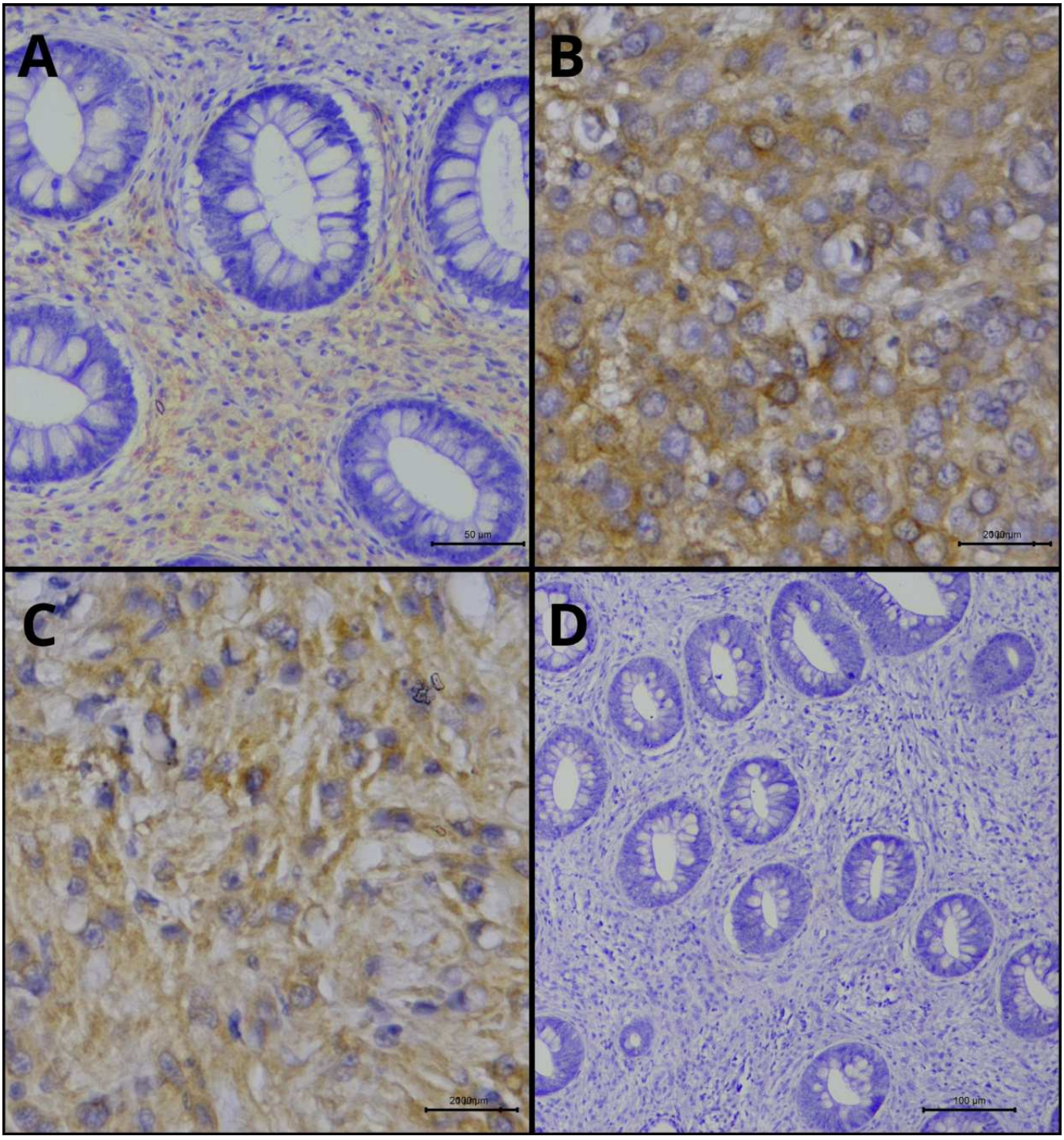

Figure 3. Gastrointestinal stromal tumor, intestine, dog. Immunohistochemical examination. A) Positive staining for c-kit in the plasma membrane of spindle cells surrounding the intestinal mucosal crypts. B) Positive staining for c-kit in the plasma membrane of neoplastic polygonal cells. C) Positive staining for c-kit in the plasma membrane of neoplastic spindle cells. D) Absence of staining for desmin. DAB chromogen, haematoxylin counterstain.

even in the face of morphological heterogeneity. This result reinforces that despite histological variation, GIST maintains a consistent immunophenotypic pattern, which facilitates its differentiation from other sarcomas.

Furthermore, recent studies have suggested that tumor size (>5 cm) and elevated mitotic index are associated with a worse prognosis in dogs with GISTs, parameters that can be used in complementary analyses and in

future work for prognostic stratification. In the present case, the findings were consistent with these negative prognostic indicators, as the specimen exceeded the 5 cm threshold and exhibited a high mitotic rate per high-power field. This correlation reinforces the aggressive biological behavior observed and underscores the importance of such parameters in predicting clinical outcomes for the patient. (5, 11).

Therefore, this case reinforces that the combination of morphological findings, even in the presence of cellular heterogeneity (fusiform and epithelioid), with immunohistochemistry is essential for the accurate diagnosis of GISTs in dogs, avoiding diagnostic errors and enabling more assertive therapeutic decisions. The integration of imaging exams, detailed anatomopathological analysis, and immunophenotyping should be considered the gold standard for the diagnosis of mesenchymal gastrointestinal neoplasms in veterinary medicine.

Data Availability

All the original contributions presented in this study are included in the article/supplementary material. Further inquiries can be directed to the corresponding author.

Author Contributions

Lucas Costa Nogueira: methodology, formal analysis, investigation, data curation, and writing – original draft. **Virgilio Zoppi Lemos:** methodology, formal analysis, investigation, data curation, and writing – review and editing. **Luise Klawa Jubrael:** methodology, formal analysis, investigation, data curation, and writing – review and editing. **Tábata Maués:** methodology, formal analysis, investigation, data curation, and writing – review and editing. **Angélica Consalter:** methodology, formal analysis, investigation, data curation, and writing – review and editing. **Marcela Freire Vallim de Mello:** methodology, formal analysis, investigation, data curation, and writing – review and editing.

Conflict of Interest

The authors declare no competing interests.

Generative AI Use Statement

The authors did not use generative artificial intelligence tools or technologies in creating or editing any part of this manuscript.

References

1. Berger EP, Johannes CM, Jergens AE, Allenspach K, Powers BE, Du Y, Mochel JP, Fox LE, Musser ML. Retrospective evaluation of toceranib phosphate (Palladia®) use in the treatment of gastrointestinal stromal tumors of dogs. J Vet Intern Med. 2018;32(6):2045-53. doi: 10.1111/jvim.15335.
2. Bancroft JD, Layton C, Suvarna SK. Bancroft's Theory and Practice of Histological Techniques. 8th ed. Elsevier, 2018. 557p.
3. Bettini G, Morini M, Marcato PS. Gastrointestinal spindle cell tumours of the dog: histological and immunohistochemical study. J Comp Pathol. 2003;129(4):283-93. doi: 10.1016/S0021-9975(03)00046-X.
4. Costa ML, Sueiro FAR, Jark PC, Carvalho LL, Rodrigues MA, Almeida VTS, Dias FGG. Diagnósticos histomorfológico e imunofenotípico de tumores estromais gastrointestinais e outros sarcomas que acometem o intestino de cães. Ciênc Anim Bras. 2023;24:e80937. doi: 10.1590/1809-6891v24e-75610P.
5. Dailey DD, Ehrhart EJ, Duval DL, Bass T, Powers BE. DOG1 is a sensitive and specific immunohistochemical marker for diagnosis of canine gastrointestinal stromal tumors. J Vet Diagn Invest. 2015;27(3):268-77. doi: 10.1177/1040638715578878.
6. De Nardi AB, Daleck CR. Oncologia em cães e gatos. 2nd ed. São Paulo: Roca; 2016. 766p.
7. Feng ZC, Riopel M, Popell A, Wang R. A survival kit for pancreatic beta cells: stem cell factor and c-Kit receptor tyrosine kinase. Diabetologia. 2015;58(4):654-65. doi: 10.1007/s00125-015-3504-0.
8. Frgelecová L, Škorič M, Fictum P, Husník R. Canine gastrointestinal tract tumours: a retrospective study of 74 cases. Acta Vet Brno. 2013;82(4):387-92. doi: 10.2754/avb201382040387.
9. Frost D, Lasota J, Miettinen M. Gastrointestinal stromal tumors and leiomyomas in the dog: a histopathologic, immunohistochemical, and molecular genetic study of 50 cases. Vet Pathol. 2003;40(1):42-54. doi: 10.1354/vp.40-1-42.
10. Girard-Luc A, Reyes-Gomez E, Fontaine JJ, Lagadic M, Bernex F. Les tumeurs stromales gastro-intestinales du chien: état des connaissances et rôle diagnostique du pathologiste. Prat Méd Chir Anim Comp. 2010;45:19–25. doi: 10.1016/j.anicom.2010.01.003.
11. Hirota S. Gastrointestinal stromal tumors: their origin and cause. Int J Clin Oncol. 2001;6(1):1-5. doi: 10.1007/PL00012072.
12. Kiupel M, Webster JD, Kaneene JB, Miller R, Yuzbasiyan-Gurkan V. The use of KIT and tryptase expression patterns as prognostic tools for canine cutaneous mast cell tumors. Vet Pathol. 2004 Jul;41(4):371-7. doi: 10.1354/vp.41-4-371. Erratum in: Vet Pathol. 2004 Sep;41(5):543.

13. Leandro RM, Freitas FP, Sá LRM. The importance of clinical, histopathological and immunohistochemical marking for differential diagnosis of non-hematopoietic gastrointestinal mesenchymal neoplasms in dogs: literature review. Braz J Vet Res Anim Sci. 2017;54(4):287. doi: 10.11606/issn.1678-4456.bjvras.2017.128846.
14. Leandro RM, Sá LRM. Tumor estromal gastrointestinal em cães: estudo clínico-anatomopatológico. Arq Bras Med Vet Zootec. 2016;68(4):938-44. doi: 10.1590/1678-4162-8767.
15. Leibman NF, Larson VS, Ogilvie GK. Oncology diseases of the digestive system. In: Tams TR, editor. Handbook of small animal gastroenterology. 2nd ed. St. Louis: Saunders; 2003. p. 370-415.
16. Munday JS, Löhr CV, Kiupel M. Tumors of the alimentary tract. In: Meuten DJ, editor. Tumors in domestic animals. 5th ed. Ames: John Wiley & Sons Inc.; 2017. p. 499-601.
17. Parab TM, Derogatis MJ, Boaz AM, Grasso SA, Issack PS, Duarte DA, Urayeneza O, Vahdat S, Qiao J, Hinika GS. Gastrointestinal stromal tumors: a comprehensive review. J Gastrointest Oncol. 2018;10(1):144-54. doi: 10.21037/jgo.2018.08.20.
18. Prophet EB, Mills B, Arrington JB, Sobin LH. Afip Laboratory Methods in Histotechnology. Washington: American Registry of Pathology; 1992. 279p.
19. Russell KN, Mehler SJ, Skorupski KA, Baez JL, Shofer FS, Goldschmidt MH. Clinical and immunohistochemical differentiation of gastrointestinal stromal tumors from leiomyosarcomas in dogs: 42 cases (1990–2003). J Am Vet Med Assoc. 2007;230(9):1329-33. doi: 10.2460/javma.230.9.1329.
20. Vij M, Agrawak V, Kumar A, Pandey R. Cytomorphology of gastrointestinal stromal tumors and extra-gastrointestinal stromal tumors: a comprehensive morphologic study. J Cytol. 2013;30(1):8. doi: 10.4103/0970-9371.107505.
21. Voltaggio L, Montgomery EA. Gastrointestinal tract spindle cell lesions - just like real estate, it's all about location. Mod Pathol. 2015;28(Suppl 1):S47-66. doi: 10.1038/modpathol.2014.126.
22. Willard MD. Alimentary neoplasia in geriatric dogs and cats. Vet Clin North Am Small Anim Pract. 2012;42(4):693-706. doi: 10.1016/j.cvsm.2012.04.006.