BJVP
Brazilian Journal of Veterinary Pathology
ISSN 1983-0246

Case Report

Granulomatous posthitis caused by *Halicephalobus gingivalis* in association with penile squamous cell carcinoma in an equine: clinical and anatomopathological aspects

Jamile Macedo Garcia[1], Ticiana Brasil Ervedosa[1], Luciana Neves Torres[1], Luiz Augusto Santana Silva[1], Julio David Spagnolo[2], Carla Bargi Belli[3], José Luiz Catão-Dias[1], Lilian Rose Marques de Sá[1]*

[1]Serviço de Patologia Animal, School of Veterinary Medicine and Animal Science, University of São Paulo, SP, Brazil
[2]Serviço de Cirurgia de Grandes Animais, School of Veterinary Medicine and Animal Science, University of São Paulo, SP, Brazil
[3]Departamento de Clínica Médica, School of Veterinary Medicine and Animal Science, University of São Paulo, SP, Brazil

*Corresponding author: liliansa@usp.br
Submitted: January 21st, 2026. Accepted: May 28sh, 2026.

Abstract
Penile and preputial squamous cell carcinomas are among the most common tumors in horses, and inflammation of the external genitalia caused by *Halicephalobus gingivalis* is an important differential diagnosis. *H. gingivalis* is a free-living nematode that causes fatal parasitic encephalitis in horses and humans and can eventually be diagnosed in the kidneys, lymph nodes, lungs, genital and ocular mucosa. The objective was to characterize clinical and pathological lesions caused by *H. gingivalis* infection in the prepuce with concomitant involvement of penile squamous cell carcinoma in an equine. A 15-year-old male Pampa horse with prepuce and penis ulcerated lesions had these surgically excised. Histopathological analysis revealed granulomatous posthitis with *H. gingivalis* intralesional and ulcerated penile squamous cell carcinoma. The animal had a satisfactory clinical and surgical evolution, and there was no recurrence of the lesions after a six-month follow-up period. Considerations regarding the route of infection, treatment, and zoonotic potential were highlighted, showing the importance of including this pathogen in the differential diagnosis of nodular lesions affecting the preputial and penile areas in horses.

Keywords: Nematode, diagnosis, pathology, zoonoses.

Introduction

Halicephalobus gingivalis, previously named *Micronema deletrix* or *Halicephalobus deletrix*, is a free-living nematode found primarily in soil and decaying organic matter (17, 28). This parasite has a worldwide distribution, with zoonotic potential (11), having been implicated in over 100 cases reported in horses, in addition to occasional cases in humans (18, 20, 30). There are also reports in donkeys (*Equus asinus*) (27), ponies (*Equus caballus*) (1, 3), zebra (*Equus grevyi*) (12), and cattle (*Bos taurus*) (7). Most cases are fatal due to meningoencephalitis (13, 18, 32). Halicephalobiasis predominantly affects the nervous system, although manifestations have also been observed in kidneys, nasal and oral cavities, lymph nodes, lungs, eyes, heart, blood vessels, testicles, liver, stomach, bones, spleen, and prepuce (1, 5-6, 18, 23, 25, 29-30).

Preputial and penile tumors are among the most common neoplasms in horses, with squamous cell carcinoma (SCC) being the most frequently diagnosed type (4). As these tumors enlarge, affected animals may exhibit copulatory difficulties and frequent penile protrusion (31). Cytology can be used as a preoperative diagnostic tool, but it is not entirely reliable due to the cytological characteristics of keratinocytes, which are similar across multiple lesion types, including non-neoplastic ones (31). The most recommended diagnostic

technique is biopsy, as it allows for assessment of tumor architecture and the extent of tissue invasion (31). These tumors are histologically classified as well-differentiated (grade 1), moderately differentiated (grade 2), or poorly differentiated (grade 3) (31).

This report describes the clinical and pathological features of *Halicephalobus gingivalis* in the prepuce of an equine with concomitant involvement of penile SCC, and points out the first documented case in Brazil involving this anatomical site.

Case description

A 15-year-old male Pampa horse was admitted to the Veterinary Teaching Hospital, School of Veterinary Medicine and Animal Science, University of São Paulo, presenting a nodular formation in the prepuce covered by pigmented mucosa, measuring 6.5 x 3.5 x 3.0 cm, and an ulcerated formation in the penis, measuring 6.5 x 6.0 x 2.5 cm (Fig. 1). According to the responsible, the animal was treated for 20 days with an oral antimicrobial based on sulfadiazine in association with trimethoprim, twice a day, and the lesions were washed with soap and water, with subsequent application of wound healing ointment twice a day. The formations exhibited contact with each other when the penis was retracted. No other clinical signs were observed.



Figure 1. Equine, prepuce and penis. Nodular ulcerated formations in the prepuce (white arrow) and penis (asterisk) during clinical examination.

Fine-needle aspiration cytology was performed from one of the lesions (preputial or penile). However, the anatomical origin of the sampled lesion was not specified in the submission records. The slides were stained using a rapid panoptic method and revealed a high cellularity, composed predominantly of polymorphonuclear cells, with fewer macrophages and keratinocytes exhibiting occasional atypia. The background contained abundant cellular debris. The cytological findings were suggestive of a predominantly neutrophilic inflammatory process. However, the marked inflammatory component may have contributed to the observed keratinocyte atypia, precluding a clear distinction between reactive changes and neoplastic transformation. Given the uncertainty regarding the origin of the sample and the overlap between inflammatory and potential neoplastic features, the cytological evaluation was considered inconclusive for definitive diagnosis. On the same day, the horse underwent sedation and local anesthesia for surgical excision of the lesions.

Samples were fixed in 10% buffered formalin and submitted to the Animal Pathology Service at the same institution for histopathological examination. Macroscopically, the preputial formation was black, firm, and irregular. The cut surface was white, and the remaining features were similar to the external ones. The penile formation was firm, tanned, irregular, and ulcerated.

Representative fragments were routinely processed and stained with hematoxylin and eosin for examination under optical microscopy using an Eclipse, NiU light microscope (Nikon, Japan) by two pathologists (JMG, LRMS). The preputial samples exhibited a marked and diffuse infiltration of epithelioid macrophages, multinucleated giant cells, along with occasional lymphocytes, plasma cells, and rare neutrophils and eosinophils. There were a significant number of eggs (Fig. 2A), larvae (Fig. 2B), and adult female nematode parasites. The adult nematode measured between 250 to 460 µm in length, and displayed a rhabditoid esophagus divided into body, isthmus, and bulb (Fig. 2C), with a dorsiflexed ovary and ventroflexed uterus (Fig. 2D), sometimes presenting a developed egg measuring 40 to 55 µm. The morphological diagnosis was granulomatous posthitis, focally extensive, associated with larvae, eggs, and adult females of a nematode parasite consistent with *Halicephalobus gingivalis*.

Regarding the penile formation, a diagnosis of malignant neoplastic proliferation of keratinocytes arranged in islands and anastomosed trabeculae, with invasive growth, formation of keratin pearls, and ulceration with neutrophilic exudation, whose diagnosis was ulcerated well differentiated penile SCC (Fig. 3).

After the excision, the surgical site was washed with saline solution twice a day, followed by the application of topical antimicrobial agents. The animal had a satisfactory clinical and surgical recovery, with no recurrence of the parasite or the tumor after six-month of follow-up

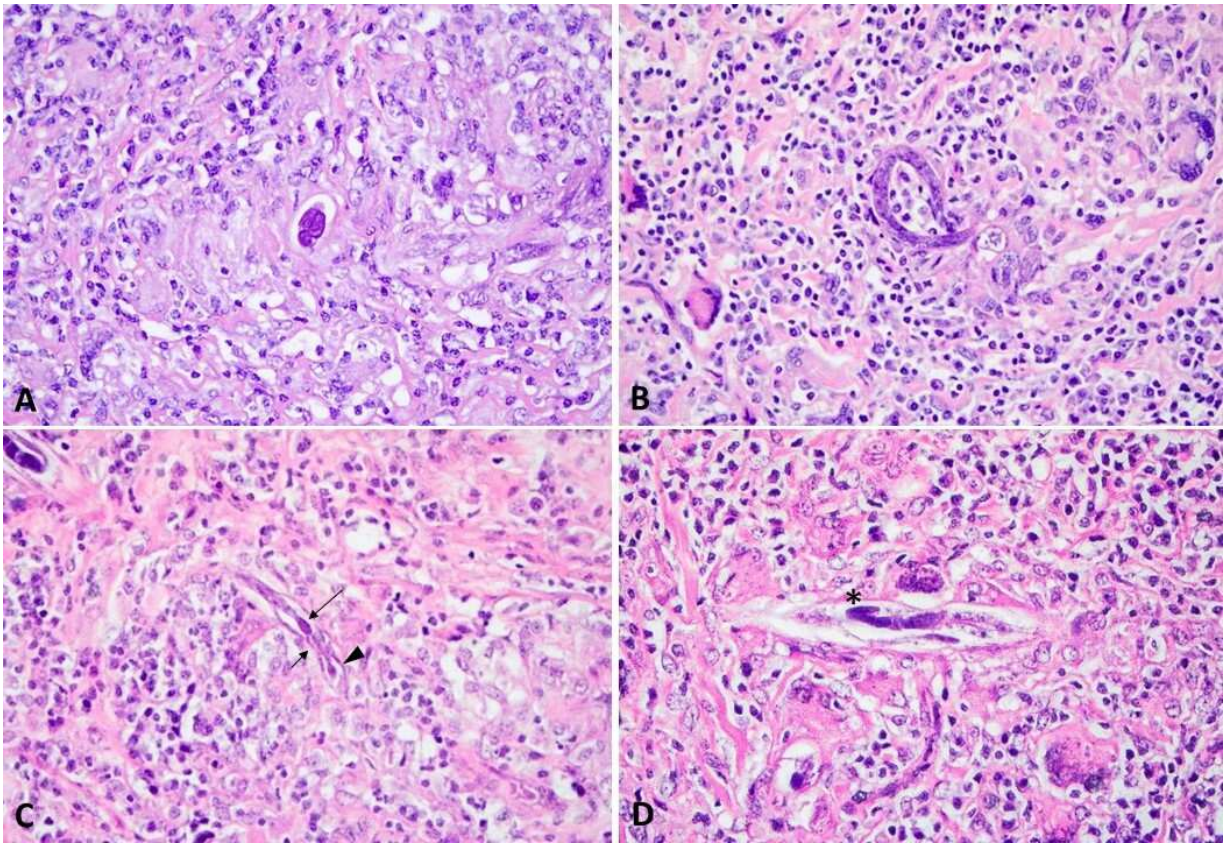

Figure 2. Equine, prepuce. Granulomatous posthitis with nematoide parasites intralesional. Note the marked inflamation, mainly characterized by epithelioid macrophages and multinucleated giant cells, and cuts of egg (A), larvae (B), and adult females (C) with esophagus divided into body (arrowhead), isthmus (short arrow), and bulb (long arrow), (D) dorsiflexed ovary (asterisk) and ventroflexed uterus. Hematoxylin and eosin, 400x.

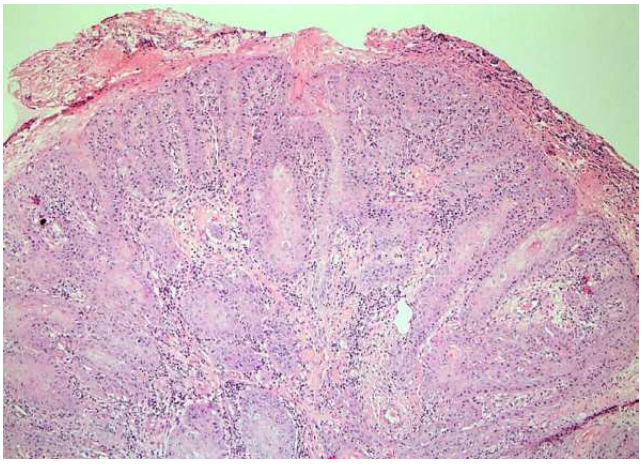

Figure 3. Equine, penis. Ulcerated squamous cell carcinoma well differentiated (grade 1). Hematoxylin and eosin, 100x.

Discussion

Here, the concomitant involvement of preputial halicephalobiasis and penile SCC in an equine was completely described. To our knowledge, this would be the first reported case in the literature. There are three other reports of this parasite in the prepuce of horses (6, 16, 21), this being the fourth described in the world and the first in Brazil.

Lesions associated with *H. gingivalis* can vary widely depending on the affected organs and the extent of involvement (5, 23, 29). Horses with parasitic posthitis previously described showed solely preputial formations, without systemic or neurological symptoms. In contrast, the animal in this report exhibited a concomitant neoplastic process in the penis. Previous reports described lesions caused by *H. gingivalis* as multiple nodules ranging from 0.5 to 8.0 cm in size, whereas this case demonstrated a single ulcerated lesion (6, 16, 21).

The clinical and pathological diagnosis of halicephalobiasis in horses is a challenge. In cases with cutaneous and/or mucosal nodular lesions, the granulomatous process should be considered among the potential differentials, such as habronemosis, pythiosis, atypical mycobacteriosis, foreign body reactions, and neoplasms, such as SCC (28). Diagnostic methods for nodular lesions include cytology, histopathological examination of incisional or excisional biopsies, and molecular tests (28). In the present case, a presumptive diagnosis of neoplasia was initially considered,

and cytological evaluation was performed prior to surgical excision. However, an important limitation was that the anatomical origin of the cytological sample was not recorded, preventing the determination of whether the material originated from the penile neoplastic lesion or from the adjacent preputial lesion associated with parasitic infection. Cytologically, the sample was characterized by a marked polymorphonuclear inflammatory infiltrate with cellular debris and keratinocytes displaying occasional atypia. Although these findings were suggestive of an inflammatory process, it is well recognized that intense inflammation may induce reactive epithelial atypia, complicating the differentiation from neoplastic changes. Consequently, the overlapping cytological features, combined with the uncertainty regarding the lesion sampled, limited the diagnostic value of cytology in this case and precluded definitive interpretation. Cytodiagnosis was not used in any reported case to demonstrate the inflammatory process or the intralesional parasite in similar cases (6, 16, 21). The definitive diagnosis was the histopathological examination of the nodular tissue fragment, confirming parasitic granulomatous posthitis and penile SCC. Histopathology remains the primary diagnostic tool applicable in clinical settings capable of identifying *H. gingivalis*, despite its predominantly post-mortem diagnosis by other authors (15, 18, 24, 32).

The morphological aspects of the parasites were used to determine the agent, considering rhabditiform esophagus, dorsiflexed ovary, and slender tail for identifying *H. gingivalis* in histological sections (2, 6). Only eggs, larvae, and adult females were observed in the inflammatory process, which suggests that the parasite reproduces asexually by parthenogenesis, as stated before (2).

The main differential diagnoses of *H. gingivalis* in equine skin are two rhabditids, *Cephalobus* sp. and *Strongyloides westerii* (6). Both can be differentiated from *H. gingivalis* by morphology (28). *Cephalobus* sp. has differences in the posterior end and esophagus, which has a greater proportion of body to isthmus (28). *Strongyloides westerii*, on the other hand, does not present eggs in the middle of the inflammatory process, since only larvae penetrate the skin (28).

We postulate that the proximity between the preputial and penile lesions facilitated the development of the parasitic infection, as tumor-associated penile exposure may have increased contact between the preputial mucosa and the ground. Although the routes of infection remain unclear, previous reports suggest that the parasite penetrates through damaged mucosa (2, 6, 22). It should also be considered that mucosal lesions may not be clinically apparent, which could explain cases in which lacerations are not observed (18, 24).

Despite the presence of ulceration in the neoplastic tissue, intralesional parasites were not identified in this area. This finding may be explained by the particular characteristics of the tumor microenvironment (TME) (14). Neoplastic tissue, especially in advanced and ulcerated lesions, is frequently associated with hypoxia, necrosis, and abnormal vascularization with reduced blood flow (14, 34), which may influence the establishment and persistence of infectious agents. Additionally, the TME represents a specialized and dynamically regulated niche characterized by altered immune responses and cytokine signaling (14, 33). These conditions may variably influence parasite survival and may not support typical host-parasite interactions within tumor tissue. Alternatively, parasite distribution may be focal and therefore not represented in the examined sections. Therefore, the absence of parasites in the neoplastic tissue does not preclude the proposed route of infection but underscores the complexity of host-parasite-tissue interactions in such cases.

The treatment based only on the surgical procedure was sufficient to control the disease in the animal, which has not presented recurrence or systemic clinical manifestations. In the literature, in the few cases of success in the treatment of halicephalobiasis, protocols based on ivermectin were used, which may or may not be associated with other medications or surgical procedures (6, 16). In cases of parasite infection of the brain, mortality rates reach 100%, even in animals treated with anthelmintics (3, 8, 10, 13, 25), since the drug does not cross the blood-brain barrier in satisfactory concentrations, and due to the low sensitivity of *H. gingivalis* to available medications (9, 26).

In humans, rare cases of *H. gingivalis* infection have been reported, all resulting in fatal parasitic meningoencephalitis (1, 15, 19). None of these cases had a documented history of direct contact with infected horses. However, one case reported disease development following contact with horse feces (1). Although rare, halicephalobiasis is recognized as an occupational disease with zoonotic potential, highlighting the critical role of veterinarians in controlling and preventing human infections (1).

Data Availability

All the original contributions presented in this study are included in the article/supplementary material. Further inquiries can be directed to the corresponding author.

Author Contributions

Jamile M. Garcia: Investigation, Data Curation, Visualization, Writing – Original Draft. **Ticiana B. Ervedosa**: Investigation, Writing – Review & Editing. **Luciana N. Torres**: Investigation, Visualization, Writing – Review & Editing. **Luiz A. S. Silva**: Investigation, Writing – Review & Editing. **Julio D. Spagnolo**: Resources, Writing – Review & Editing. **Carla B. Belli**: Resources, Writing – Review & Editing. **José L. Catão-Dias**: Visualization, Supervision, Writing – Review & Editing. **Lilian R. M. de Sá**: Conceptualization, Visualization, Supervision, Writing – Review & Editing.

Conflict of Interest

The authors declare no competing interests.

Generative AI Use Statement

The authors did not use generative artificial intelligence tools or technologies in creating or editing any part of this manuscript.

Funding

This research received no specific grant from any funding agency in the public, commercial, or not-for-profit sectors.

References

1. Akagami M, Shibahara T, Yoshiga T, Tanaka N, Yaguchi Y, Onuki T, Kondo T, Yamanaka T, Kubo M. Granulomatous nephritis and meningoencephalomyelitis caused by Halicephalobus gingivalis in a pony gelding. J Vet Med Sci. 2007;11:1187-90. doi: 10.1292/jvms.69.1187.
2. Anderson RC, Linder KE, Peregrine AS. Halicephalobus gingivalis (Stefanski, 1954) from a fatal infection in a horse in Ontario, Canada with comments on the validity of H. deletrix and a review of the genus. Parasite. 1998;5:255-61. doi: 10.1051/parasite/1998053255.
3. Baker E, Geick A, Hines M, Gerhold R, Cordero-Aponte C. Case report: Halicephalobus gingivalis in a Tennessee pony. Vet Parasitol Reg Stud Reports. 2023;39:100843. doi: 10.1016/j.vprsr.2023.100843.
4. Bianchi MV, Boos GS, Mello LS, Vargas TP, Sonne L, Driemeier D, Pavarini SP. A retrospective evaluation of equine cutaneous lesions diagnosed in southern Brazil. Acta Sci Vet. 2016;44:1-7. doi: 10.22456/1679-9216.81154.
5. Cavasani JPS, Silva WDM, Pavelegini LAD, Colodel EM, Furlan FH. Granulomatous disease associated with Halicephalobus sp. in a horse. Braz J Vet Pathol. 2025;18(Suppl 1):e018S105. doi: 10.24070/bjvp.1983-0246.018S105.
6. Dunn DG, Gardiner CH, Dralle KR, Thilsted JP. Nodular granulomatous posthitis caused by Halicephalobus (syn. Micronema) sp. in a horse. Vet Pathol. 1993;30:207-8. doi: 10.1177/030098589303000215.
7. Enemark HL, Hansen MS, Jensen TK, Larsen G, Al-Sabi MNS. An outbreak of bovine meningoencephalomyelitis with identification of Halicephalobus gingivalis. Vet Parasitol. 2016;218:82-6. doi: 10.1016/j.vetpar.2016.01.014.
8. Ferguson R, van Dreumel T, Keystone JS, Manning A, Malatestinic A, Caswell JL, Peregrine AS. Unsuccessful treatment of a horse with mandibular granulomatous osteomyelitis due to Halicephalobus gingivalis. Can Vet J. 2008;49:1099-103.
9. Fonderie P, Bert W, Hendrickx F, Huthoofd W, Moens T. Anthelmintic tolerance in free-living and facultative parasitic isolates of Halicephalobus (Panagrolaimidae). Parasitology. 2012;139:1301-8. doi: 10.1017/S0031182012000558.
10. Henneke C, Jespersen A, Jacobsen S, Nielsen MK, McEvoy F, Jensen HE. The distribution pattern of Halicephalobus gingivalis in a horse is suggestive of a haematogenous spread of the nematode. Acta Vet Scand. 2014;56:56. doi: 10.1186/s13028-014-0056-0.
11. Hoostraten J, Young WG. Meningoencephalomyelitis due to the saprophagous nematode Micronema deletrix. Can J Neurol Sci. 1974;2(2):121-6. doi: 10.1017/s0317167100020102
12. Isaza R, Schiller CA, Stover J, Smith PJ, Greiner EC. Halicephalobus gingivalis (Nematoda) infection in a Grevy's zebra (Equus grevyi). J Zoo Wildl Med. 2000;31(1):77-81. doi: 10.1638/1042-7260(2000)031[0077:HGNIIA]2.0.CO;2.
13. Kinde H, Mathews M, Ash L, Leger JS. Halicephalobus gingivalis (H. deletrix) infection in two horses in southern California. J Vet Diagn Invest. 2000;12:162-5. doi: 10.1177/104063870001200213.
14. Li Z, Li J, Bai X, Huang X, Wang Q. Tumor microenvironment as a complex milieu driving cancer progression: a mini review. Clin Transl Oncol. 2025;27:1943–1952. doi: 10.1007/s12094-024-03697-w.
15. Lim CK, Crawford A, Moore CV, Gasser RB, Nelson R, Koehler A, Bradbury RS, Speare R, Dhatrak D, Weldhagen GF. First human case of fatal Halicephalobus gingivalis meningoencephalitis in Australia. J Clin Microbiol. 2015;53(5):1768-74. doi: 10.1128/JCM.00032-15.
16. Muller S, Grzybowski M, Sager H, Bornand V, Brehm W. A nodular granulomatous posthitis caused by Halicephalobus sp. in a horse. Vet Dermatol. 2008;19(1):44-8. doi: 10.1111/j.1365-3164.2007.00643.x.
17. Nadler SA, Carreno RA, Adams BJ, Kinde H, Baldwin JG, Mundo-Ocampo M. Molecular phylogenetics and diagnosis of soil and clinical isolates of Halicephalobus gingivalis (Nematoda: Cephalobina: Panagrolaimoidea), an opportunistic pathogen of horses. Int J Parasitol. 2003;33:1115-25. doi: 10.1016/s0020-7519(03)00134-6.
18. Noiva R, Ruivo P, Carvalho LM, Fonseca C, Fevereiro M, Carvalho P, Orge L, Monteiro M, Peleteiro MC. First description of a fatal equine infection with Halicephalobus gingivalis in Portugal: relevance for public health. Vet Med Sci. 2019;5(2):222-9. doi: 10.1002/vms3.142.
19. Ondrejka SL, Procop GW, Lai KK, Prayson RA. Fatal parasitic meningoencephalomyelitis caused by Halicephalobus deletrix. Arch Pathol Lab Med. 2010;134(4):625-9. doi: 10.5858/134.4.625.

20. Onyiche TE, Okute TO, Oseni OS, Okoro DO, Biu AA, Mbaya AW. Parasitic and zoonotic meningoencephalitis in humans and equids: current knowledge and the role of Halicephalobus gingivalis. Parasite Epidemiol Control. 2018;3:36-42. doi: 10.1016/j.parepi.2017.12.002.
21. Payán J, Soto R, Romero J, Flórez G. Granulomas en el prepucio de un equino causados por Micronema. Rev ICA. 1979;14(4):283-9.
22. Pearce SG, Bouré LP, Taylor JA, Peregrine AS. Treatment of a granuloma caused by Halicephalobus gingivalis in a horse. J Am Vet Med Assoc. 2001;219(12):1735-8. doi: 10.2460/javma.2001.219.1735.
23. Pillai VV, Mudd LJ, Sola MF. Disseminated Halicephalobus gingivalis infection in a horse. J Vet Diagn Invest. 2023;35(2):173-7. doi: 10.1177/10406387221141698.
24. Pintore MD, Cerutti F, D'Angelo A, Corona C, Gazzuola P, Masoero L, Colombo C, Bona R, Cantile C, Peletto S, Casalone C, Iulini B. Isolation and molecular characterisation of Halicephalobus gingivalis in the brain of a horse in Piedmont, Italy. Parasit Vectors. 2017;10:135. doi: 10.1186/s13071-017-2070-3.
25. Rames DS, Miller DK, Barthel R, Craig TM, Dziezyc J, Helman RG, Mealey R. Ocular Halicephalobus (syn. Micronema) deletrix in a horse. Vet Pathol. 1995;32(5):540-2. doi: 10.1177/030098589503200514.
26. Schinkel AH. P-glycoprotein, a gatekeeper in the blood-brain barrier. Adv Drug Deliv Rev. 1999;36:179-94. doi: 10.1016/s0169-409x(98)00085-4.
27. Schmitz DG, Chaffin MK. What is your diagnosis? Halicephalobus gingivalis. J Am Vet Med Assoc. 2004;225:1667-8. doi: 10.2460/javma.2004.225.1667.
28. Scott DW, Miller WH Jr. Equine dermatology. 2nd ed. Philadelphia: Elsevier; 2011. p. 90-1, 248-9.
29. Sousa TM, Toma HS, Lima AP, Lacreta Junior ACC, Nunes MM, Silva APC, Wouters D, Albuquerque AS, Varaschin MS, Raymundo DJ, Toma CDM, Batista FA. Pathological fracture induced by Halicephalobus gingivalis (Nematoda: Rhabditida) in a horse limb. Parasites Hosts Dis. 2024;62(1):131–138. doi: 10.3347/PHD.23066.
30. Taulescu MA, Ionică AM, Diugan E, Pavaloiu A, Cora R, Amorim I, Catoi C, Roccabianca P. First report of fatal systemic Halicephalobus gingivalis infection in two Lipizzaner horses from Romania: clinical, pathological, and molecular characterization. Parasitol Res. 2016;115:1097-103. doi: 10.1007/s00436-015-4839-7.
31. Van den Top JGB, Ensink JM, Barneveld A, van Weeren PR. Penile and preputial squamous cell carcinoma in the horse and proposal of a classification system. Equine Vet Educ. 2011;23(12):636-48. doi: 10.1111/j.2042-3292.2010.00216.x.
32. Vasconcelos RO, Lemos KR, Moraes JRE, Borges VP. Halicephalobus gingivalis (H. deletrix) in the brain of a horse. Cienc Rural. 2007;37(4):1185-7. doi: 10.1590/S0103-84782007000400047.
33. Wei XY, Feng HJ, Zhu YY, Guo SJ, Wang H, Li M, Mei Q. The immune microenvironment of pathogen-associated cancers and current clinical therapeutics. Mol Cancer. 2025;24:232. doi: 10.1186/s12943-025-02448-x.
34. Xie Y, Wang J, Wang Y, Wen Y, Pu Y, Wang B. Parasite-enhanced immunotherapy: transforming the "cold" tumors to "hot" battlefields. Cell Commun Signal. 2024;22:448. doi: 10.1186/s12964-024-01822-4.