Braz J Vet Pathol, 2025, vol. 18, e019010
DOI: https://doi.org/10.24070/bjvp.1983-0246.019010

BJVP
Brazilian Journal of Veterinary Pathology
ISSN 1983-0246

Case Report

Malignant catarrhal fever and Clostridium perfringens co-infection in White-Spotted Deer: a fatal encounter

Fathin Faahimaah Abdul Hamid[1]*, Amirul Faiz Mohd Azmi[2], Brenda Sabrina Gilbert[1], Mohammad Auzaie Afandi[1], Abubakar Danmaigoro[1], Nani Izreen Mohd Sani[3], Che Wan Salma Che Wan Zalati[3], Norsyamimi Farhana Mat Kamir[3], Jasni Sabri[4], Alun Williams[5]

[1]Department of Veterinary Paraclinical Studies, Universiti Malaysia Kelantan, Kota Bharu, Kelantan, Malaysia
[2]Department of Veterinary Preclinical Sciences, Universiti Malaysia Kelantan, Kota Bharu, Kelantan, Malaysia
[3]University Veterinary Diagnostic Centre, Faculty of Veterinary Medicine, Universiti Malaysia Kelantan, Kota Bharu, Kelantan, Malaysia
[4]Faculty of Veterinary Medicine, Universitas Brawijaya, Malang, Indonesia
[5]Department of Veterinary Medicine, University of Cambridge, United Kingdom

***Corresponding author:** faahimaah.ah@umk.edu.my
Submitted: September 16th, 2025. Accepted: March 6th, 2026.

Abstract

Malignant Catarrhal Fever (MCF) is one of the diseases reported as a transboundary disease, which is commonly caused by Alcelaphine herpesvirus 1 (AlHV-1) and Ovine herpesvirus 2 (OvHV-2). Cervidae (Deer) are susceptible to this virus infection, with the outbreak occurring sporadically. A total of 5 out of 42 deer were presented with sudden death and weakness, with bloody diarrhea ranging from a few days to 24 hours before death. Gross and histopathological evaluations revealed severe haemorrhagic enteritis, pulmonary edema, and widespread necrotizing vasculitis observed in the lung, liver, and kidney. Diagnostic laboratory testing revealed a positive result of MCF (OvHV-2) virus from the lung samples through Polymerase chain reaction (PCR). Anaerobic culture, PCR and sequencing of the intestinal sample were positive for *C. perfringens*. Following the deaths of 2 deer, examination of the feed revealed an unplanned dietary transition from deer pellet to goat pellet with the differences in the protein content (min 14%) with mostly grains and higher moisture content (max 13%) in the goat pellet, leading to possible changes in the gastrointestinal flora of the deer gut which causes proliferation of *C. perfringens*. Presence of OvHV-2 targets the CD8+ lymphocytes that induce systemic inflammation, causing widespread vascular injury, which further promotes proliferation of *C. perfringens* that contributes to the severity of the enteritis observed. The resulting necrohaemorrhagic enteritis leads to hypovolemic shock, ultimately death due to circulatory failure. This report highlights the review, presents findings, transmission and pathology of Malignant Catarrhal Fever and *C. perfringens* in white spotted deer.

Keywords: Malignant Catarrhal Fever, Ovine herpesvirus 2, Clostridium perfringens, transboundary disease

Introduction

Necrohaemorrhagic enteritis, characterized by severe necrotic, intraluminal blood content in the intestine, is one of the characteristic presentations of multiple diseases in deer, including epizootic haemorrhagic disease, bovine viral diarrhea, malignant catarrhal fever, and enterotoxemia caused by *Escherichia coli* and *Clostridium* spp. Malignant Catarrhal Fever (MCF) is one of the diseases reported as a transboundary disease, which is commonly caused by Alcelaphine herpesvirus 1 (AlHV-1) and Ovine herpesvirus 2 (OvHV-2), and has been observed in ruminants and is considered to be endemic in sheep without apparent signs and remains as a reservoir host (37). Cervidae (Deer) are considered one of the most susceptible hosts to this virus infection. Outbreaks of the disease have been described to occur sporadically, with a few animals affected at a time (24). This disease can cause severe manifestations in the susceptible species that affect the lymphoid tissues, the mucosal lining of the respiratory and gastrointestinal tracts, and the central nervous system of susceptible ungulate species (17). Previous literature

on MCF in deer caused by OvHV-2, as described in Table 1, has shown that the most common predisposing factor was the presence of a sheep farm located near the susceptible species, resulting in the disease outbreak. The common pathological lesions observed include lymphoproliferative necrotizing vasculitis and pulmonary lesions, which include congestion and edema. Meanwhile, *Clostridium perfringens* is a spore-forming gram-positive anaerobic bacteria which are also ubiquitous in the environment and can be part of the normal gastrointestinal tract (18, 19). Under favourable conditions, these bacteria may proliferate and produce toxins, which include a few major toxins, which are alpha (CPA), beta (CPB), epsilon (ETX), and iota (ITX) (10, 31), and these toxins can lead to severe necrotic enteritis in the animals. This disease is also a major leading cause of high mortality and significant economic losses. Table 2 describes the clostridial diseases causing enterotoxemia in deer, which are mainly haemorrhagic enteritis, with diarrhea and sudden death being one of the common signs that could be evidence in most cases due to sudden changes in feed. This report highlights the review, presents findings, transmission, and pathology of Malignant Catarrhal Fever and *C. perfringens* infection in white-spotted deer in Bachok, Kelantan, Malaysia.

Case description

Animal and feed management

A farm housing a population of 42 deer implemented a feeding regimen consisting of twice-daily feedings. The diet comprised a combination of *Brachiaria decumbens* (freshly cut fodder), commercial deer pellets, and access to limited grazing within a confined pen area. Fresh water was provided *ad libitum via* storage drums. Routine health management practices, including vaccination, deworming, and vitamin supplementation, were not implemented for the deer. Mineral block supplementation was provided inconsistently and was dependent on stock availability. Within a 5-kilometer radius, a temporary research sheep pen was located at the University teaching farm.

Table 1. Malignant Catarrhal Fever caused by Ovine herpesvirus-2 (OvHV-2) in deer

Agents	Clinical Findings	Lesions	Cause/Predisposing factors	Reference(s)
Ovine herpesvirus- 2 (OvHV-2)	• Incoordination, ataxia, falls and difficulties getting up. • Opisthotonos and dry nostrils	Gross: • Edema • Pulmonary congestion Histopathology: • Perivascular and meningeal inflammatory lymphocytic infiltrate. • Fibrinoid vasculitis • Multifocal periglomerular interstitial nephritis • Lymphoid hyperplasia • Interstitial pneumonia • White pulp depletion • Diffuse lymphocytic enteritis • Lymphocytic choroiditis, keratitis	• Deer and sheep shared the same location and drinking fountains.	Mariana *et al.,* 2018
Ovine herpesvirus-2 (OvHV-2)	• Thin, weak, and have diarrhea, • Sudden death • Moribund	Histopathology: • Lymphocytic vasculitis was observed in the lung, kidney, bladder mucosa, and heart. • Pulmonary congestion and low-protein edema fluid were observed.	• Deer were occasionally close to sheep in the adjacent agricultural valley. • Overlap between land used for sheep grazing	Patricia *et al*., 2007
Ovine herpesvirus-2 (OvHV-2) & Caprine herpesvirus (CpHV-2)	• Bloody diarrhoea • High Fever, dry, flushing nose • Depression and food refusal. • Lameness and hyperesthesia	Gross: • Pulmonary haemorrhage • Prominent white nodules on the kidney. • Petechial haemorrhage in the liver, bladder • Mesentric lymphadenomegaly • Splenomegaly • Hepatomegaly Histopathology: • Vasculitis & Arteritis • Perivascular lymphoid cell infiltration • Interstitial fibrosis of the lung • Lymphocytic nephritis, hepatitis • Valvular degeneration, necrosis and haemorrhage	• Direct or indirect contact with domestic sheep or goats.	Zhu *et al.,* 2019)

Table 2. Clostridiosis caused by *Clostridium perfringens* in deer

Agents	Clinical Findings	Lesions	Causes/Predisposing factors	Reference(s)
Clostridium perfringens type A	No stated	Gross and Histopathology: • Severe haemorrhagic enteritis with infiltration of *Clostridium perfringens*	• Alteration of the concentration of fooder during cold winter	(Niu *et al.,* 2014)
Clostridium perfringens type A	• Sudden death with no clinical signs	Gross changes: • Small intestinal haemorrhage • Splenomegaly • Splenic congestion • Hepatic necrosis	• Increased grain in the diet or dietary changes. Feed rich in carbohydrates and proteins.	(Hyatt *et al.,* 2005)
Clostridium perfringens	• Loose feces are located in the farm area.	Gross: • Bloody fluid in the abdominal cavity (abomasum) and upper small intestine • Diffuse mucosal haemorrhage in the intestine	• Altering a rich diet	(Brickmann *et al.,* 2004)
Clostridium perfringens Type A	• Fever • Recumbent • Diarrhea • Incoordination • Death	Gross: • Congested and red hepatization of lungs • Paler liver • Myocardial haemorrhage • Pulpy kidney	• Organized in a dairy farm with a lack of strong biosecurity of the farm • Feeding of supplemented with a higher ratio of protein.	Sultana *et al.,* 2021)
Clostridium perfringens Type D	• No clinical sign in peracute form Acute cases: • Restlessness • Abdominal pain • Salivation • High temperature (40.5°C) • Respiratory distress • Greenish watery diarrhea	Gross: • Pinpoint haemorrhages on all serosal surfaces and in the muscles. • Greenish fibrino-necrotic material. • Straw coloured fluid, indicating hydroperitoneum, hydrothorax, and hydropericardium. • Haemorrhagic on the abomasum, intestine and myocardium. • Pulpy kidney (soft and black)	• Spores of the causative organism are found in soil and in the faeces of healthy animals raised in areas where the disease is prevalent.	Khan *et al.,* 2008)
Clostridium perfringens	• Sudden death	Gross: • Catarrhal enteritis with haemorrhages in the small intestine	• Contamination of the paddock at the feeding areas with *Clostridium perfringens*	Sato & Matsuura, 1998)

Clinical presentations and signs

The deer was presented with sudden death and weaknesses were observed ranging from a few days to 24 hours before death, with no prior history of feed changes or any clinical signs observed. Consistent features of blood from the anus were observed for all 4 deer. 1 out of 5 deer showed signs of ataxia and diarrhea before death. A total of 5 deer were found dead.

Gross pathological findings

The main gross pathological changes observed in the deer were haemorrhagic enteritis with marked reddening of the serosal and mucosal surface of the small and large intestinal loops, with a mixture of feed and intraluminal blood content in the intestines. Prominent lesions were also observed in the lung, liver, and kidney, which included the pulmonary consolidations, prominent interlobular septa, hepatomegaly, and renomegaly (Figs. 1 and 2).

Cytology

From the blood content of the intestine, cytological smears were conducted, which revealed the presence of rod-shaped bacteria with numerous small spores also observed (Fig. 3).

Bacterial isolation and polymerase chain reaction (PCR)

The bacterial isolation and identification revealed the growth of *Clostridium* spp. from the anaerobic culture,

and 2 intestinal tissues were sent for PCR and sequencing, which showed a positive result for *C. perfringens*. The lung sample collected from all 3 deer revealed a positive result for Malignant Catarrhal Fever (OvHV-2) virus and was confirmed by sequencing of the virus (Fig. 4).

Feeding management

During the observation period after the death of two deer, the feed was checked, and an unplanned dietary transition occurred in which the regular deer pellet was temporarily

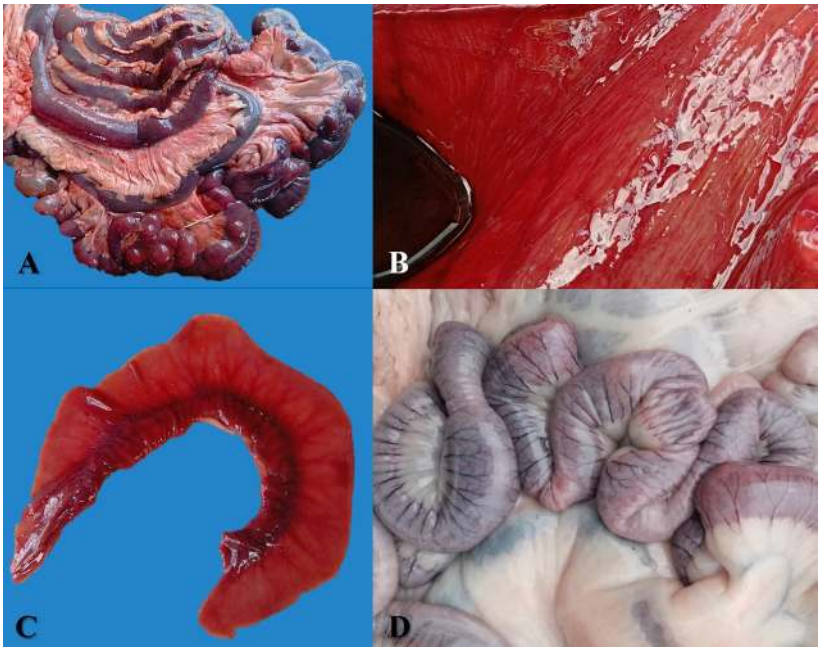

Figure 1. Necrohaemorrhagic enteritis, deer. A. Marked reddening of the serosal surface with distension of the intestine, B. The exposed affected intestine revealed the presence of blood content C. Severe diffuse reddening of the intestinal mucosa is evident, D. Serosal surface of the colon showed prominent engorged blood vessels

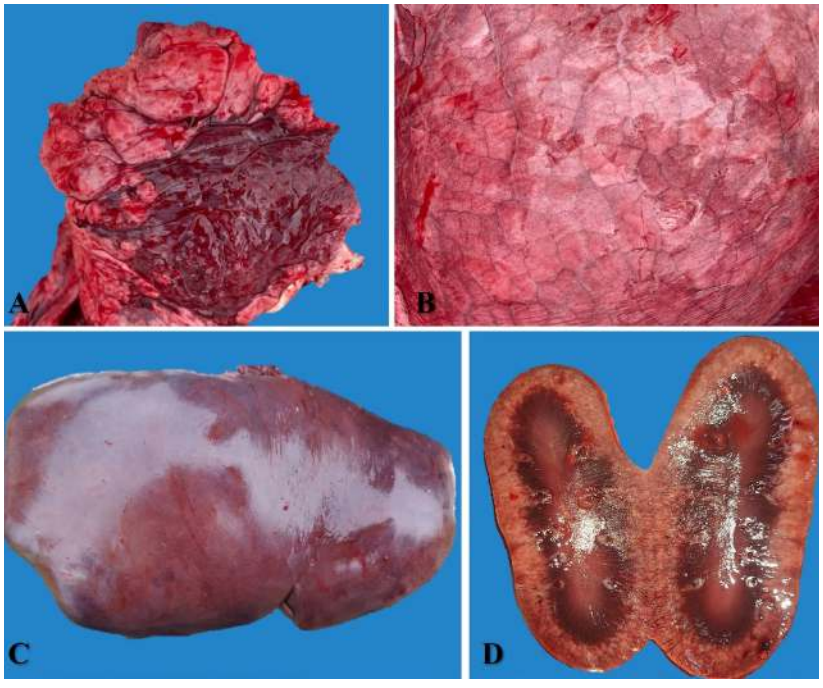

Figure 2. Malignant Catarrhal Fever, deer. A. A dark red, depressed area was present, interspersed between raised areas of the right cranial lung lobes. Within this depressed area, consolidation was evident. B. The caudal lung lobes are moderately congested and show prominent interlobular septa. C. Hepatomegaly is characterized by a rounded border and multifocal to locally extensive pale areas, D. Diffuse multifocal to coalescing cortical pale areas.

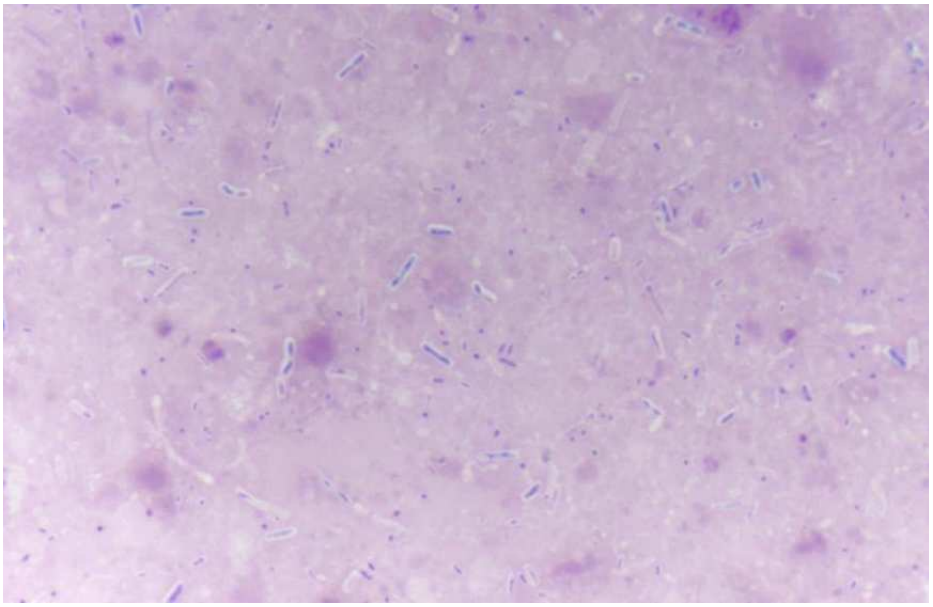

Figure 3. Rod-shaped bacteria observed from the intestinal content smear

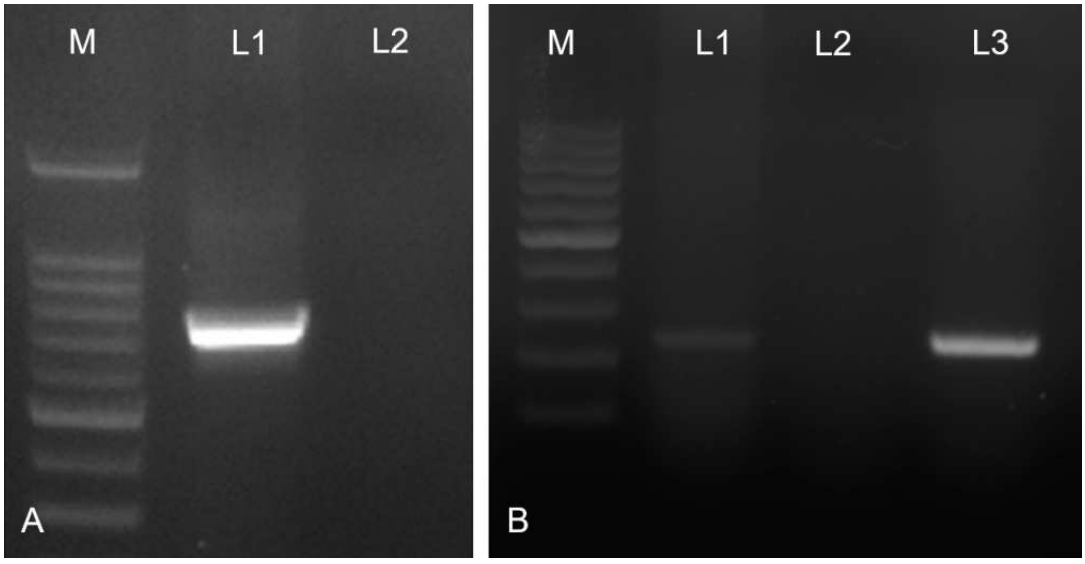

Figure 4. Polymerase Chain Reaction (PCR) detection of the *Clostridium perfringens* and Ovine herpes virus-2 (OvHv-2). M: molecular weight marker; A. Lane 1 (L1): Positive sample of *Clostridium perfringens*, B. Lane 1 (L1): Positive sample of Ovine herpes virus-2 (OvHv-2), Lane 3 (L3): Positive control of Ovine herpes virus-2 (OvHv-2).

replaced with a goat pellet for a duration of one month before reverting to the original deer pellet. The goat pellet differed notably in nutritional composition, exhibiting higher moisture content (13.0% vs. 5.7%), increased crude fibre (20.0% vs. 15.5%), and slightly higher crude protein (minimum 14.0% vs. 13–16%). However, crude fat content was not specified in the goat pellet formulation. The dry matter content was lower in the goat pellet (minimum 87.0% vs. 94.3%), while the ash content was elevated (10.0% vs. 7.6%). Additionally, the ingredient profile of the goat pellet was more complex, incorporating a wider array of components such as protein meals, vitamins, minerals, amino acids, and feed additives that were absent in the standard deer pellet (Table 3)

Histopathological findings

The histopathological evaluations revealed severe necrohaemorrhagic enteritis characterized by the complete loss of the villous with a mixture of inflammatory cells (neutrophils, macrophages, lymphocytes) and necrotic cellular debris. Necrosis of the smooth muscle of the intestine was also observed by the complete loss of nuclei (karyolysis) and eosinophilic cytoplasm of the smooth muscle. Other presentations of lesions observed in the intestine of the other deer include congestion, the presence of an inflammatory infiltrate within the lamina propria, and haemorrhage characterized by the presence of red blood cells within the villi of the intestine.

Braz J Vet Pathol, 2025, vol. 18, e019010
DOI: https://doi.org/10.24070/bjvp.1983-0246.019010

In the lung and liver, lymphocytic perivascular cuffing and lymphocytic necrotizing vasculitis are characterized by the infiltration of lymphocytes and macrophages into the blood vessel with loss of the vascular structures and with a prominent eosinophilic appearance of the blood vessel indicating necrosis. Pulmonary edema is observed as homogenous eosinophilic fluid within the alveolar spaces (Figs. 5 and 6).

Discussion

The occurrence of the disease started with a few predisposing factors, which eventually led to the development of the disease. Based on the history, a sheep farm was located within a 5-kilometer radius of the deer enclosure. One of the main carriers for Malignant Catarrhal Fever (MCF)

Table 3: Comparison of the nutritional value of commercial deer and goat pellets in the farm

Nutritional profiles	Deer pellet	Goat pellet
Moisture %	Max 5.7	Max 13
Crude Protein %DM	Max 13-16	Min 14
Crude Fibre %DM	Max 15.5	Max 20
Crude Fat %DM	Max 4.3	-
Dry Matter %DM	Max 94.3	Min 87
Ash %DM	Max 7.6	Max 10
Ingredient	PKE, cocoa shell, rice bran, rice husk, wheat pollard, soya husk, corn, salt, molasses	PKC/PKE, soybean by product, corn & corn by--products, grains & grains byproduct, protein meals, cocoa by products, molasses, salt, calcium carbonate, dicalcium phosphate, vitamins, minerals, amino acids, mold-inhibitors, and pellet binder

Notes: Ingredient and the composition retrieved from the feed label

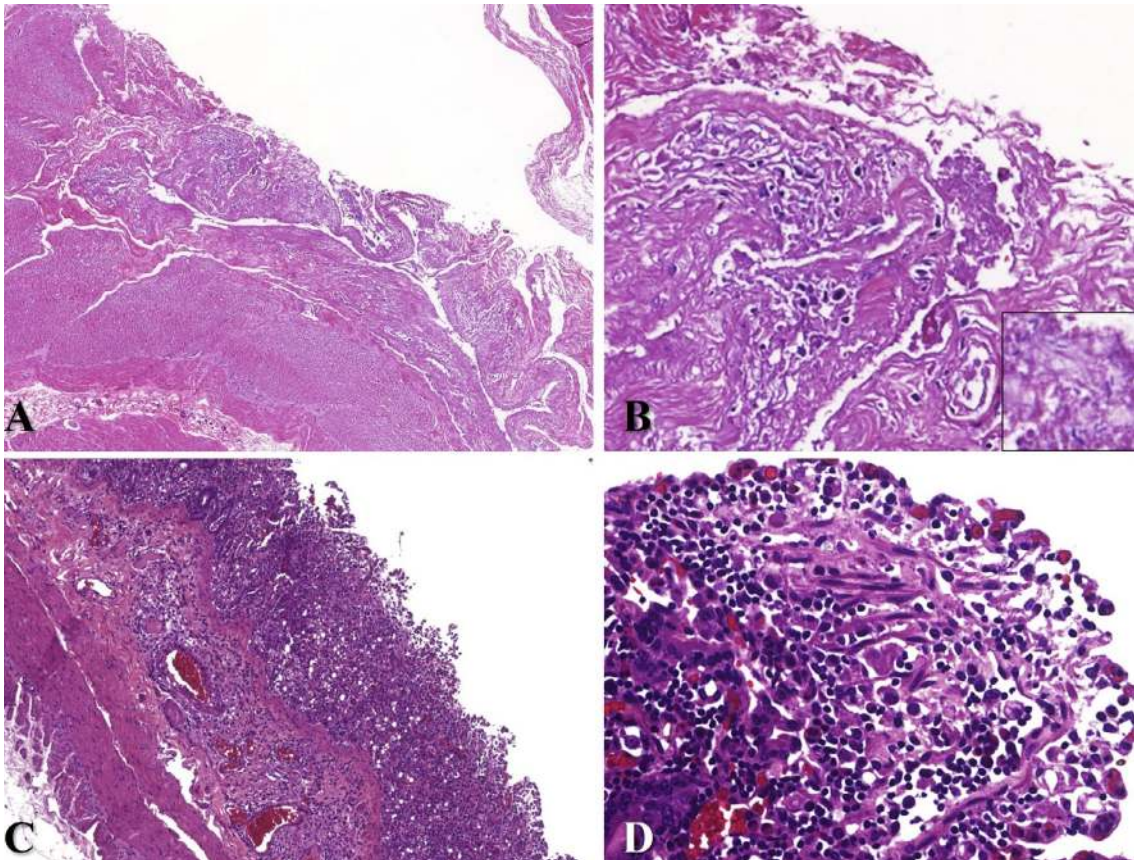

Figure 5. Necrohaemorrhagic enteritis, Deer. A. Severe enteritis with total loss of the villous and smooth muscle necrosis was observed, B. Necrotic villi with the presence of necrotic debris and inflammatory cells (neutrophil and macrophages) and a bacterial colony was found on the necrotic villi area (see inset), C. Haemorrhagic enteritis observed with moderate loss of villi, D. Presence of red blood cells within the villi indicating haemorrhage and mixture of inflammatory cells (neutrophils, macrophages and lymphocytes).

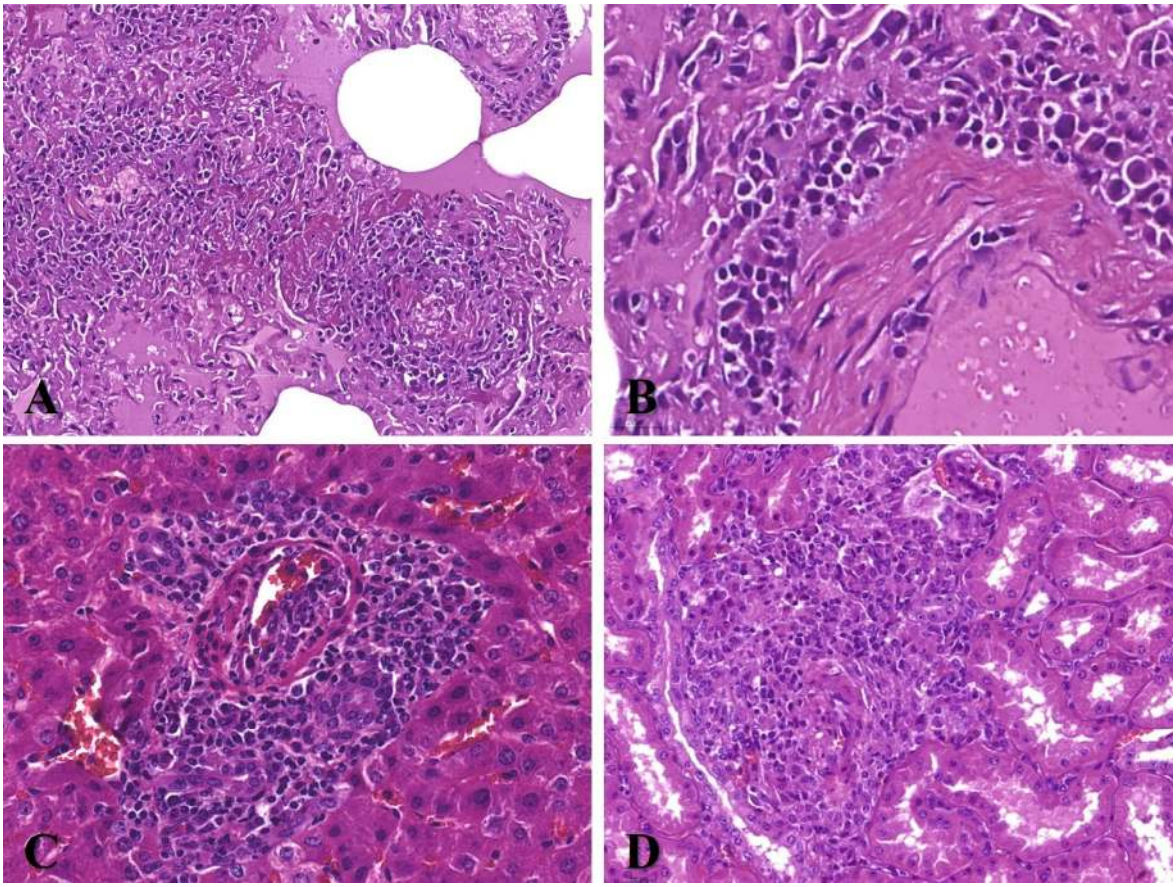

Figure 6. Lymphoproliferative necrotizing vasculitis, Deer. A. Presence of inflammatory cells (lymphocytes, macrophages) surrounding and within the blood vessel, obliterating the vessel and homogenous eosinophilic fluid within the alveolar spaces, B. Perivascular cuffing surrounding the blood vessels, C. Presence of mainly lymphocytes and macrophages infiltration observed surrounding and within the portal triad of the liver, D. Loss of the vessel architecture and massive lymphocyte infiltration within the vascular area and renal interstitium.

is the sheep that carries the Ovine herpesvirus-2 (OvHv-2). The reservoir animal normally remains asymptomatic and they often shed the virus through nasal secretion, through which the virus can travel through inhalation, indirect and direct contact, including fomites. In this case, the detection of the virus from the sheep lung was found to be negative for OvHv-2. The virus shedding can occur intermittently in the sheep (24) and the low viral load in the carrier may result in a negative result for the virus. Deer are among the animals that are highly susceptible to the disease, particularly to OvHv-2 strain (22) and can be presented as peracute illness, in which the clinical signs can be absent and most of the signs can only be seen before the death of the animals.

The transmission of the disease in this case can be both from the aerosol route and fomites as a result of contact or handling of the farm animal by the same animal handler. Previously, a long-distance spread of OvHV-2 within more than a 5-kilometer radius has been reported from feedlot lambs to ranch bison (15). The arrival of the sheep was in June 2024, and the first death of the deer was observed in October 2024, which was within 4 months of the first case reported death in the deer. The horizontal transmission of the virus can lead to disease development within an incubation period of 3 weeks to 5 months (16, 33, 36). The nature of the herpesvirus infection is that it can be a persistent latent infection (12, 35), and the viral reactivation then could infect the susceptible species. The virus infects the deer by mainly targeting the T-lymphocytes (CD8+), which induces the lymphocytes proliferation that activates the cytotoxic T-cells, leading to the dysregulation of the immune system, causing mainly vascular damage, inflammation, and necrosis by the activation of endothelial cells without known evidence up to date (26). This then continuously promotes an inflammatory reaction, causing vascular injury and widespread vasculitis. Lymphocytic necrotizing vasculitis has been described as one of the common features of the disease. Recent studies with OvHV-2 have found the association of not only lymphocytes but also macrophages in the activation of pro-inflammatory cytokines (IFN-ɣ) (20), which contributes to the disease severity, as they infect the T-cells, monocytes and locally proliferating macrophages, resulting in the necrotizing vasculitis. This could be as a result of the disruption of the vessel layer (tunica media), which then causes infiltration of macrophages that also release the reactive oxygen species

(ROS) and matrix metalloproteinases (MMPs) destroy and digest the internal elastic lamina (28, 30) leading to the loss of the vascular structure as observed histopathologically. The evidence of this systemic vasculitis then led to all the lesions observed in multiple organs. An increase in intestinal permeability could have resulted from MCF disease itself. On the other hand, an unplanned feed change has also taken place. Previously, a study has described on the infection of *Clostridium difficile* in colon of a white tailed deer that was positive for Caprine herpesvirus-2 (CpHV-2) which suggestive that the diarrhea and colitis are resulted from the bacteria, although the speculation over either it is a primary or secondary agent were unknown, in which the agent may proliferated or exacerbated by the presence of the virus itself (11). In this case, the proliferation of *C. perfringens* itself could be due to the alteration in the diet from deer to goat pellet, which contains a higher moisture content, crude protein level, and the composition of the feed was also different, causing abruption of the normal microflora in the deer. The bacteria then produce a toxin, which kills the intestinal cells and villi, leading to severe necrohaemorrhagic enteritis observed in this case. Severe loss of intravascular blood volume causes hypovolemic shock, which results in low cardiac output and tissue perfusion, together with pulmonary edema as a result of increased vascular permeability, which impairs the gaseous exchange activities leading to hypoxemia and death of the deer.

The importance of early disease investigation and intervention remains critical in ensuring that proper management can take place. In this disease outbreak, one of the effective control measures that should be taken is the practice of proper biosecurity of the farm. Increasing the distance between the sheep farm and relocation of the farm away from the susceptible animals can be the best measures and this reduces the aerosol spread of the virus. This step may not be suitable in many conditions that favour a more effective approach in the prevention of the disease. Secondly, the handler or farmer shall be advised in terms of proper handling, and the possibility of the virus spreading is higher if the same handler handles all of the animals, which could increase the risk of spreading through fomites or even contact with the nasal discharges, which could lead to the spread of the disease. Having a separate handler for each species of the farm animal would further reduce the risk of the disease spreading to the susceptible host (37). Current consensus also stated that the infected animals do not need to be culled or separated, due to the transmission from them is unlikely or rare because they are the end host for the disease (34). One of the best methods to prevent disease occurrence is reduced exposure to stressors, such as capturing activity, which might help prevent serious illnesses in subclinically infected or mildly affected animals. The guidelines by the Centre for Food Security and Public Health and the World Organization of Animal Health (WOAH) suggested that 3% sodium hypochlorite can be used for disinfection and to reduce the risk of disease transmission.

To date, there is no successful treatment regimen or vaccination that has been described in treating and preventing MCF. The previously reported case in the MCF outbreak in Spain had used flunixin meglumine and doxycycline as treatment however, they are proven not to be effective enough and were considered only as supportive therapy (13). One study conducted by Patho et al. shows that ivermectin was able to inhibit the ALHV-1 cell replication in vitro, and no further studies have been conducted to explore the potential of ivermectin to be used in the treatment of MCF. Recent vaccination studies targeting the OvHV-2 glycoprotein B have found a promising result in the experimental trial in rabbits, resulting in a greater protection rate of 66.6 to 771.4% observed in the vaccinated trials on rabbits (8). Up to date, there is one clinical vaccination trial using the ALHV-1 C500 vaccine that has been conducted in Kenya livestock, particularly cattle and buffalo, which shows it has about 80% vaccine efficacy and can prevent mortality up to 79% (6). These recent studies show that there is a promising future for the prevention of the disease with vaccination.

For the prevention of clostridial diseases, what we learn from this case is that it is not only important to check the feed label, but also the content of the feed itself, to ensure the correct feed is given to the animals. Good management of feed storage, such as placing feed in an airtight container and a well-ventilated area, could prevent the contamination of the feed. The addition of probiotics to the feed has proven to reduce the incidence of the disease (7) The use of a multivalent conventional clostridial vaccine made from the bacterial toxoids was highly recommended to the young herd of animals (5, 27) and a study was conducted on naive deer to see their response towards epsilon toxin, and it shows that they had a high serologic antibody response towards the toxin that lasted up to more than 9 to 12 months (29).

Conclusions

This case involved a fatal co-infection of Malignant Catarrhal Fever (OvHV-2) and *C. perfringens* in white-spotted deer. It likely resulted from contact with sheep, causing the spread of the virus, followed by changes in feed content leading to proliferation of *C. perfringens.* The combination of these diseases causes severe vascular damage and enteritis in the deer. This situation emphasizes the need for strong biosecurity measures, the importance of separating workers in mixed farming, and careful feed management to reduce the risk of clostridial infections. While there is currently no effective treatment for MCF, recent research in vaccines and antiviral treatments shows promising future prevention. Additionally, using multivalent clostridial vaccines, probiotics, and correct feeding practices should be key parts of herd health programs. Ultimately, this case serves as a reminder that complex disease processes in wildlife and ruminants require a comprehensive strategy that includes careful monitoring, good farm management, and effective biosecurity measures to protect the animals from avoidable deaths.

Conflict of Interest

The authors declare no competing interests.

References

1. Allaart JG, van Asten AJ, Gröne A. Predisposing factors and prevention of Clostridium perfringens-associated enteritis. Comp Immunol Microbiol Infect Dis. 2013;36(5):449-64. doi: 10.1016/j.cimid.2013.05.001.
2. Brinkman TJ, Jenks JA, DePerno CS, Haroldson BS. Clostridium perfringens type A in a free-ranging fawn. Praire Nat. 2004;36(3):181-4.
3. Brooks JW, Whary MT, Hattel AL, Shaw DP, Ge Z, Fox JG, Poppenga RH. Clostridium piliforme infection in two farm-raised white-tailed deer fawns (Odocoileus virginianus) and association with copper toxicosis. Vet Pathol. 2006;43(5):765-8. doi: 10.1354/vp.43-5-765.
4. Clarke LL. Postmortem diagnoses and factors influencing diagnoses in captive white-tailed deer in Wisconsin, 2009-2021. J Vet Diagn Invest. 2023;35(6):782-788. doi: 10.1177/10406387231190420.
5. Compiani R. Prevention of the main Clostridial diseases in cattle. Large Anim Rev. 2021;27(1):51-6.
6. Cook E, Russell G, Grant D, Mutisya C, Omoto L, Dobson E, Lankester F, Nene V. A randomised vaccine field trial in Kenya demonstrates protection against wildebeest-associated malignant catarrhal fever in cattle. Vaccine. 2019;37(40):5946-5953. doi: 10.1016/j.vaccine.2019.08.040.
7. Cull C, Singu VK, Cull BJ, Lechtenberg KF, Amachawadi RG, Schutz JS, Bryan KA. Efficacy of Two Probiotic Products Fed Daily to Reduce Clostridium perfringens-Based Adverse Health and Performance Effects in Dairy Calves. Antibiotics (Basel). 2022;11(11):1513. doi: 10.3390/antibiotics11111513.
8. Cunha CW, Baker KN, O'Toole D, Cole E, Shringi S, Dewals BG, Vanderplasschen A, Li H. A vaccine targeting ovine herpesvirus 2 glycoprotein B protects against sheep-associated malignant catarrhal fever. Vaccines (Basel). 2022;10(12):2156. doi: 10.3390/vaccines10122156.
9. Embury-Hyatt CK, Wobeser G, Simko E, Woodbury MR. Investigation of a syndrome of sudden death, splenomegaly, and small intestinal hemorrhage in farmed deer. Can Vet J. 2005;46(8):702-8.
10. Gharaibeh S, Al Rifai R, Al-Majali A. Molecular typing and antimicrobial susceptibility of Clostridium perfringens from broiler chickens. Anaerobe. 2010;16(6):586-9. doi: 10.1016/j.anaerobe.2010.10.004.
11. Giannitti F, Li H, Patnayak D, Olsen K, Crossley B, Moore H, Uzal F. Clostridium difficile colonic infection in a white-tailed deer (Odocoileus virginianus) with caprine herpesvirus-2-associated malignant catarrhal fever. American College of Veterinary Pathology (ACVP) Annual Meeting, Minneapolis, October; 2015.
12. Hüssy D, Stäuber N, Leutenegger CM, Rieder S, Ackermann M. Quantitative fluorogenic PCR assay for measuring ovine herpesvirus 2 replication in sheep. Clin Diagn Lab Immunol. 2001;8(1):123-8. doi: 10.1128/CDLI.8.1.123-128.2001.
13. Iván M, María P, Gorka A, Pere O, Javier DF. Malignant catarrhal fever in cattle in Spain. Vet Rec Case Rep. 2022;10(4):e483. doi: 10.1002/vrc2.483.
14. Khan A, Ali I, Hussain I, Ahmad N. Clostridium perfringens type D enterotoxaemia in the chinkara deer (Gazella bennettii). Turk J Vet Anim Sci. 2008;32(3):225-228.
15. Li H, Karney G, O'Toole D, Crawford TB. Long distance spread of malignant catarrhal fever virus from feedlot lambs to ranch bison. Can Vet J. 2008 Feb;49(2):183-5.
16. Liggitt HD, DeMartini JC. The pathomorphology of malignant catarrhal fever. I. Generalized lymphoid vasculitis. Vet Pathol. 1980;17(1):58-72. doi: 10.1177/030098588001700107.
17. MacLachlan NJ, Dubovi EJ. Coronaviridae. In: Fenner's Veterinary Virology. 5th ed. London: Academic Press; 2017. p. 435-61.
18. McClane BA, Robertson SL, Li J. Clostridium perfringens. In: Doyle MP, Buchanan RL, editors. Food Microbiology: Fundamentals and Frontiers, 4th ed. Washington: ASM Press; 2012. p.465-89.
19. Mehdizadeh Gohari I, A Navarro M, Li J, Shrestha A, Uzal F, A McClane B. Pathogenicity and virulence of Clostridium perfringens. Virulence. 2021;12(1):723-753. doi: 10.1080/21505594.2021.
20. Nelson DD, Davis WC, Brown WC, Li H, O'Toole D, Oaks JL. CD8(+)/perforin(+)/WC1(-) gammadelta T cells, not CD8(+) alphabeta T cells, infiltrate vasculitis lesions of American bison (Bison bison) with experimental sheep-associated malignant catarrhal fever. Vet Immunol Immunopathol. 2010;136(3-4):284-91. doi: 10.1016/j.vetimm.2010.03.023.
21. Niu Y, Wang G, Ma H, Yu K, Qu Y, Zhang Z, Yue RC, Lv CW, SD Liu SD. A comprehensive diagnosis of deer enterotoxaemia caused by Clostridium perfringens A in Shandong province, China. Inter J Vet Sci. 2015;4(1):44-9.
22. O'Toole D, Li H. The pathology of malignant catarrhal fever, with an emphasis on ovine herpesvirus 2. Vet Pathol. 2014;51(2):437-52. doi: 10.1177/0300985813520435.
23. Patho B, Grant DM, Percival A, Russell GC. Ivermectin inhibits replication of the malignant catarrhal fever virus alcelaphine herpesvirus 1. Virology. 2024;590:109958. doi: 10.1016/j.virol.2023.109958.
24. Russell GC, Stewart JP, Haig DM. Malignant catarrhal fever: a review. Vet J. 2009;179(3):324-35. doi: 10.1016/j.tvjl.2007.11.007.
25. Sato Y, Matsuura S. Gastric mucormycosis in a sika deer (Cervus nippon) associated with proliferation of

Clostridium perfringens. J Vet Med Sci. 1998;60(8):981-3. doi: 10.1292/jvms.60.981.

26. Saura-Martinez H, Al-Saadi M, Stewart JP, Kipar A. Sheep-associated malignant catarrhal fever: role of latent virus and macrophages in vasculitis. Vet Pathol. 2021;58(2):332-345. doi: 10.1177/0300985820978310.
27. Salvarani FM, Vieira EV. Clostridial infections in cattle: a comprehensive review with emphasis on current data gaps in Brazil. Animals (Basel). 2024;14(20):2919. doi: 10.3390/ani14202919.
28. Samson M, Corbera-Bellalta M, Audia S, Planas-Rigol E, Martin L, Cid MC, Bonnotte B. Recent advances in our understanding of giant cell arteritis pathogenesis. Autoimmun Rev. 2017;16(8):833-44. doi: 10.1016/j.autrev.2017.05.014.
29. Scala C, Duffard N, Beauchamp G, Boullier S, Locatelli Y. Antibody response to epsilon toxin of Clostridium perfringens in captive red deer (Cervus elaphus) over a 13-month period. J Zoo Wildl Med. 2016;47(1):38-44. doi: 10.1638/2014-0169.1.
30. Shirai T, Hilhorst M, Harrison DG, Goronzy JJ, Weyand CM. Macrophages in vascular inflammation--From atherosclerosis to vasculitis. Autoimmunity. 2015;48(3):139-51. doi: 10.3109/08916934.2015.1027815.
31. Sipos W, Fischer L, Schindler M, Schmoll F. Genotyping of Clostridium perfringens isolated from domestic and exotic ruminants and swine. J Vet Med B Infect Dis Vet Public Health. 2003;50(7):360-2. doi: 10.1046/j.1439-0450.2003.00690.x.
32. Sultana S, Sultana N, Islam M, Pervin M, Khan MAI, Khan MAHN. Zoonotic diseases were a major hurdle to successful deer farming in Bangladesh. Vet World. 2021;14(9):2462-72. doi: 10.14202/vetworld.2021.2462-2472.
33. Taus NS, Oaks JL, Gailbreath K, Traul DL, O'Toole D, Li H. Experimental aerosol infection of cattle (Bos taurus) with ovine herpesvirus 2 using nasal secretions from infected sheep. Vet Microbiol. 2006;116(1-3):29-36. doi: 10.1016/j.vetmic.2006.03.005.
34. The Center for Food Security and Public Health: Malignant catarrhal fever, malignant catarrh, malignant head catarrh, gangrenous coryza, catarrhal fever, snotsiekte. Institute for International Cooperation in Animal Biologics, Iowa State University; 2016. 9p.
35. Thonur L, Russell GC, Stewart JP, Haig DM. Differential transcription of ovine herpesvirus 2 genes in lymphocytes from reservoir and susceptible species. Virus Genes. 2006;32(1):27-35. doi: 10.1007/s11262-005-5842-3.
36. Uzal FA, Plattner BL, Hostetter JM. Alimentary system. In: Maxie G, editor. Jubb, Kennedy & Palmer's Pathology of Domestic Animals. 6th ed. St. Louis: Elsevier; 2016. p.1-257.
37. World Organization for Animal Health. Manual of diagnostic tests and vaccines for terrestrial animals. OIE; 2020.