Braz J Vet Pathol, 2026, vol. 19, e019018
DOI: https://doi.org/10.24070/bjvp.1983-0246.019018

BJVP
Brazilian Journal of Veterinary Pathology
ISSN 1983-0246

Case Report

PRAME immunoexpression in canine melanocytic tumors: a case series study

Isabeli Joaquim Contel[1]*, Fwu Shing Teng[2], Rafael Torres Neto[3], Heitor Flavio Ferrari[4], Renee Laufer-Amorim[2], José Cândido Caldeira Xavier-Júnior[1,5]

[1] Department of Pathology, Botucatu Medical School, São Paulo State University (UNESP), Botucatu, SP, Brazil
[2] Department of Veterinary Clinic, School of Veterinary Medicine and Animal Science, São Paulo State University (UNESP), Botucatu, SP, Brazil
[3] VetMol Laboratory, Botucatu, SP, Brazil
[4] University Center of Adamantina, Adamantina, SP, Brazil
[5] Salesian Catholic University Center Auxilium, Medical School, Araçatuba, SP, Brazil

*Corresponding author: isabeli.contel@unesp.br
Submitted: March 15th, 2026. Accepted: May 7th, 2026.

Abstract
Diffuse immunoexpression of Preferentially Expressed Antigen in Melanoma (PRAME) is an ancillary diagnostic tool for distinguishing human melanoma from melanocytic nevi. Canine melanocytic neoplasms are common in veterinary diagnostic practice; however, no established immunohistochemical biomarkers of malignancy are currently available. This case series study aimed to investigate the immunoexpression of the anti-PRAME (EPR20330) antibody in canine melanocytic tumors. Two cutaneous melanocytomas and six melanomas from distinct anatomical sites (haired skin, oral cavity and feet) were submitted to immunohistochemistry protocol with anti-PRAME antibody (clone EPR20330, dilution 1:100, Abcam) overnight at 4°C. Nuclear immunolabeling was scored on a 5-point scale based on the percentage of positive tumor cells (0: none; 1: 1–25%; 2: 26–50%; 3: 51–75%; 4/diffuse: ≥76%). The two evaluated melanocytomas were PRAME-negative. All melanomas were PRAME-positive and diffuse nuclear immunolabeling was observed in 4/6 cases. To the best of our knowledge, this is the first study to demonstrate the immunohistochemical expression of the anti-PRAME antibody (clone EPR20330) in canine melanomas. Our preliminary findings, based on a limited sample size, suggest that PRAME may represent a promising ancillary diagnostic marker for these tumors, similar to its use in human samples. However, further studies with larger cohorts are needed to better characterize its labeling patterns in canine melanocytic neoplasms and to confirm its diagnostic value in veterinary pathology.

Keywords: Dogs, melanoma, diagnosis, immunohistochemistry.

Introduction

Melanocytic neoplasms in dogs can occur at various anatomical sites, including the oral cavity, mucocutaneous junctions, skin, feet, and eyes (2,20). These tumors are relatively common, accounting for approximately 5% to 9% of all canine skin tumors, with malignant cutaneous melanomas being more common than benign melanocytomas (13,16). Oral malignant melanoma is the most common neoplasm of the canine oral cavity, whereas apparently benign melanocytic oral neoplasms—also referred to as histologically well-differentiated melanocytic neoplasms—occur less frequently (3,6).

In veterinary medicine, immunohistochemical analysis is widely employed as a diagnostic tool, especially for poorly differentiated or undifferentiated cases, and to provide valuable prognostic information. Despite several immunohistochemical melanocytic markers' availability, none reliably differentiate between benign and malignant lesions (19).

The Preferentially Expressed Antigen in Melanoma (PRAME) was first identified in 1997 as a tumor antigen recognized by autologous T cytolytic lymphocyte clones derived from a human patient with metastatic cutaneous melanoma (8). In the past eight years, several human studies have investigated the potential of PRAME immunoexpression as a useful ancillary tool for diagnosing primary and metastatic human melanoma (1,10,11,14,15).

Although not specific for melanocytic tumors (9), PRAME typically exhibits diffuse nuclear expression in most conventional human melanomas and focal or absent expression in melanocytic nevi (1). Therefore, our study aimed to investigate the immunohistochemical expression of this antigen in canine melanocytic tumors, serving as an initial exploratory analysis.

Case description

This study was approved by the Ethics Committee on Animal Use (*Comissão de Ética no Uso de Animais* - CEUA) of the School of Veterinary Medicine and Animal Science of São Paulo State University (UNESP) (CEUA protocol 000.268/2024).

Formalin-fixed paraffin-embedded (FFPE) canine specimens, retrospectively selected from the archives of VetMol Laboratory (Botucatu, Brazil) and the Veterinary Pathology Service at the School of Veterinary Medicine and Animal Science, São Paulo State University (UNESP, Botucatu, Brazil) were analyzed. Cases with a prior diagnosis of melanoma were included, which were based on morphological criteria as described in the recent literature (17) and immunopositivity to Melan-A (clone A103, prediluted, Dako) and SOX10 (clone EP268, Cell Marque®), previously evaluated by one author (R.T.N.). For comparative purposes, melanocytomas were also included. Due to the preliminary and exploratory nature of the study, a convenience sampling approach was adopted, including samples that were available and accessible at the time of analysis.

PRAME immunohistochemical staining was carried out on 4-µm sections obtained from the FFPE samples. The antigen retrieval was performed by humid heating (water bath at 95°C) for 20 minutes with a high pH Target Retrieval Solution (EnVision™ FLEX Target Retrieval Solution, Dako). Endogenous peroxidase activity was blocked with EnVision™ FLEX Peroxidase-Blocking Reagent (Agilent) for 5 minutes at room temperature. All the sections were incubated with the anti-PRAME antibody (clone EPR20330, dilution 1:100, Abcam) overnight at 4°C. After this, the slides were incubated with the linker (EnVision FLEX+ Mouse LINKER, Agilent®) for 20 minutes for amplification of the reaction and then incubated with the secondary HRP-conjugated antibody (EnVision FLEX/HRP, Agilent®) for 30 minutes. The reaction was revealed with a magenta chromogen (EnVision™ FLEX HRP Magenta Substrate Chromogen System, Agilent). The slides were counterstained with Harris hematoxylin and mounted with a polymer-based synthetic medium agent. A human sebaceous gland was used as a positive control, as cytoplasmic labeling of human sebaceous glands is a consistent nonspecific feature of this clone (EPR20330) (10). Keratinocytes and normal melanocytes of the same human non-neoplastic skin were used as negative control.

PRAME immunolabelling analysis was evaluated jointly by three authors (I.J.C., F.S.T., R.L.A.). The extension of the nuclear immunolabeling was evaluated on a 5-point scale according to Lezcano et al. (2018) (10). Grading was based on the percentage of stained tumor cells throughout the entire tumor (0 = absence of immunolabeling; 1 = 1% - 25% positive neoplastic cells; 2 = 26% - 50% positive neoplastic cells; 3 = 51% - 75% positive neoplastic cells; and 4/"diffuse" = 76% or more positive neoplastic cells). A descriptive analysis was performed by calculating the frequencies and percentages for the immunolabeling.

A total of eight non-metastatic tumors were included, comprising two melanocytomas from haired skin, and six melanomas, including one from the oral cavity, four from haired skin, and one from the feet. PRAME immunolabeling was absent in the two analyzed melanocytomas, as well as in non-neoplastic epidermal melanocytes. All melanomas were positive for PRAME and most of them (4/6, 66.67%) exhibited diffuse nuclear immunolabeling (Fig. 1). The results of the immunohistochemical expression are summarized in Table 1.

Discussion

PRAME is a cancer-testis antigen (CTA) expressed in different cancer cells, particularly in melanoma cells, with limited expression in normal tissues, mainly restricted to the testis, endometrium, ovary, and adrenal gland (9,10,22). Furthermore, PRAME acts as a dominant repressor of retinoic acid receptor signaling, a pathway involved in proliferation arrest, differentiation, and apoptosis (5). Therefore, PRAME plays a role not only in immunotherapy responses in human cancers, but also in antagonizing cellular processes that might result in growth or survival advantages to cancer cells (5,23).

Human pathology encompasses a broad classification of cutaneous melanocytic tumors, including not only benign *melanocytic nevi* and malignant *melanoma*s, but also tumors of intermediate or uncertain biological behavior. Although debated, the term *melanocytoma* in human pathology refers to tumors with increased cellularity and/or atypia and a low potential for neoplastic progression (4). In contrast, in dogs, the morphological diagnosis of cutaneous melanocytic tumors is restricted to *melanocytoma* for benign lesions and *melanoma* for malignant lesions (19). However, a subset of canine cutaneous melanocytic tumors exhibits morphologically ambiguous features, which frequently hampers classification as benign or malignant (17).

Several immunohistochemical markers are available and may be used individually or in combination, mainly employed to confirm melanocytic origin in poorly differentiated canine tumors, including Melan-A, PNL2, and MiTF, among others. Although Ki-67 may also aid in distinguishing between benign and malignant melanocytic neoplasms, it is important to note that the proliferative index provided by Ki-67 has prognostic value (18), and it is not a strict biomarker of malignancy.

The potential of PRAME as an immunohistochemical diagnostic biomarker was first explored by Lezcano et al. (10), and multiple studies have demonstrated the utility of PRAME as an ancillary tool for distinguishing unequivocal human cutaneous melanocytic nevi from unequivocal human melanomas (12,14,15).

Diffuse nuclear PRAME immunolabeling is observed in most conventional (non-desmoplastic) human melanomas, whereas most benign melanocytic nevi are negative or exhibit focal immunolabeling (10). Although there is a strong association between diffuse PRAME expression and human melanoma diagnosis, positive staining might also be observed in a few benign melanocytic neoplasms and borderline melanocytic lesions (10,21). Therefore, PRAME cannot be considered an absolute marker of malignancy for all cases. Instead, it has been proposed as a diagnostic aid for

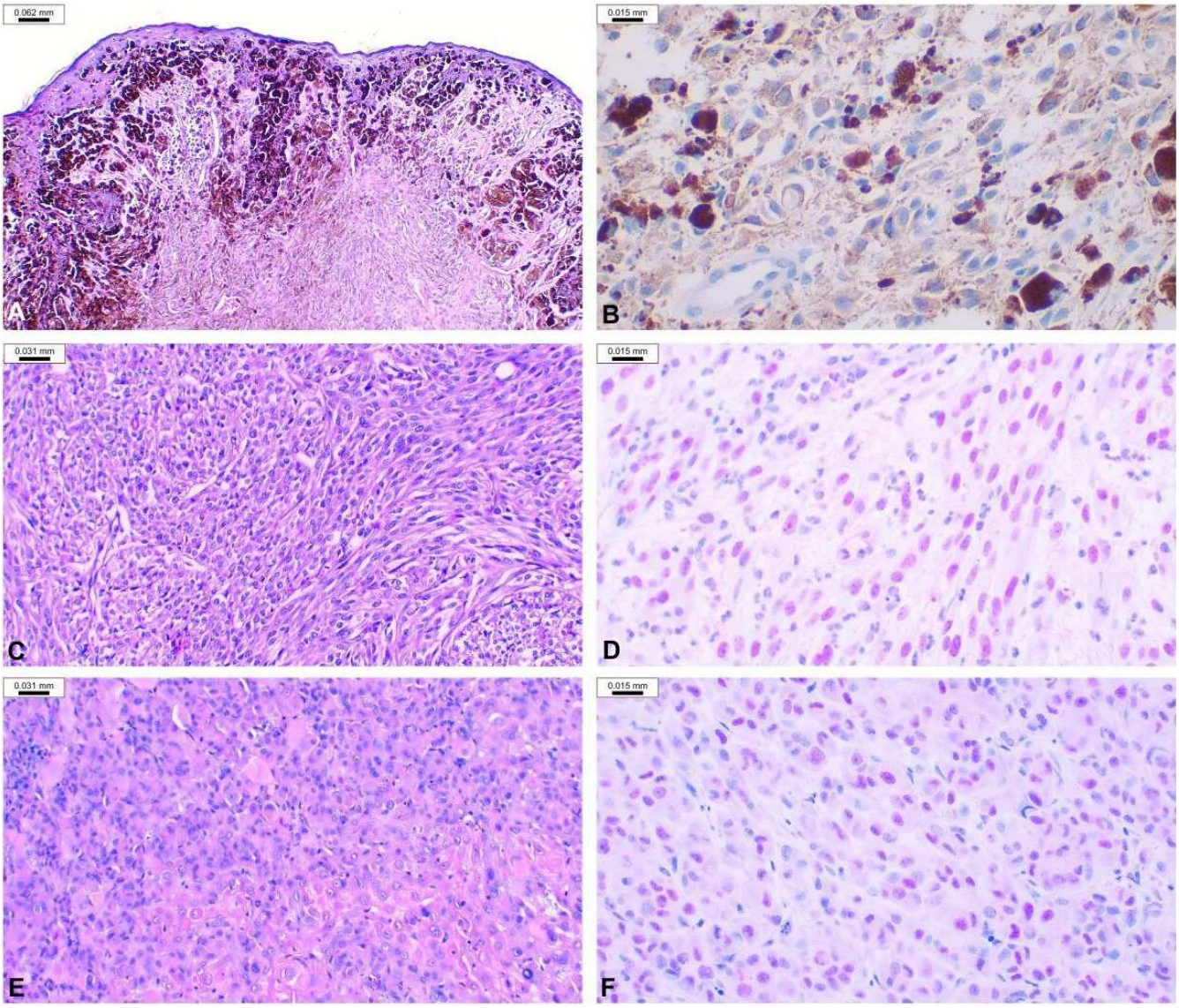

Figure 1. Histopathology and PRAME immunolabeling in canine melanocytic tumors. A) Skin, melanocytoma. Case 7. Hematoxylin and eosin, x100. B) Same case as in A. PRAME immunolabeling was not observed. Immunoperoxidase-Magenta, Hematoxylin counterstain, x400. C) Oral cavity, melanoma. Case 4. Hematoxylin and eosin, x200. D) Same case as in C. Diffuse strong nuclear PRAME immunoexpression. Immunoperoxidase-Magenta, Hematoxylin counterstain, x400. E) Skin, amelanotic melanoma. Case 6. Hematoxylin and eosin, x200. F) Same case as in E. Diffuse strong nuclear PRAME immunoexpression. Immunoperoxidase-Magenta, Hematoxylin counterstain, x400.

Table 1. Summary of the clinical data and PRAME immunohistochemical evaluation

Case	Previous diagnosis	Anatomical location	PRAME (score)[a]
1	Amelanotic melanoma	Haired skin	4
2	Melanoma	Haired skin	3
3	Melanoma	Haired skin	2
4	Melanoma	Oral cavity	4
5	Amelanotic melanoma	Feet	4
6	Amelanotic melanoma	Haired skin	4
7	Melanocytoma	Haired skin	0
8	Melanocytoma	Haired skin	0

[a] Score of extension of the PRAME immunolabeling (0 = absence of immunolabeling; 1 = 1% - 25% positive neoplastic cells; 2 = 26% - 50% positive neoplastic cells; 3 = 51% - 75% positive neoplastic cells; and 4 = 76% or more positive neoplastic cells).

human melanocytic lesion analysis, where diffuse PRAME immunolabeling supports the diagnosis of melanoma when other criteria, such as clinical and histological features, favor malignancy (10,12).

In our study, all melanoma cases were PRAME-positive, with most exhibiting diffuse nuclear immunolabeling, similar to what has been described for human melanocytic lesions. These findings suggest a difference in PRAME expression between the evaluated malignant and benign lesions and, consequently, its potential role as an ancillary diagnostic marker.

In veterinary medicine, Hindriks et al. (7) recently presented an insightful investigation into the mRNA expression of eight CTAs, including PRAME, in both canine melanoma and healthy tissues. Their study not only demonstrated the potential of CTAs as immunotherapeutic targets in canine melanomas but also revealed the possibility of exploring some of them as promising diagnostic markers. While their results placed particular emphasis on the melanoma antigen gene (MAGE), which was also assessed via immunohistochemistry, PRAME expression was also evaluated using real-time PCR. In addition to their results, we would like to support the utility of PRAME in canine melanoma diagnosis, in parallel to human pathology experience.

This study has limitations that should be acknowledged, particularly those inherent to its retrospective design. In addition, the small sample size, which mainly reflects the preliminary and exploratory nature of the study, limits the ability to establish definitive conclusions.

In conclusion, this case series study has demonstrated immunopositivity for the anti-PRAME antibody (EPR20330) in canine melanomas from distinct anatomical sites. Although the limited sample size precludes definitive conclusions, our findings suggest that PRAME may represent a promising ancillary diagnostic marker for these tumors, analogous to its application in human samples. However, further studies are needed to confirm its diagnostic utility; these studies should include larger cohorts, encompassing benign, malignant, metastatic, and diagnostically challenging melanocytic lesions, as well as the evaluation of PRAME expression in non-melanocytic tumors and validation of this protein in canine samples.

Data Availability

All the original contributions presented in this study are included in the article. Further inquiries can be directed to the corresponding author.

Author Contributions

Isabeli Joaquim Contel: Investigation, Data curation, Formal analysis, Visualization, Writing – original draft, Writing – review & editing. **Fwu Shing Teng:** Investigation, Data curation, Visualization, Writing – review & editing. **Rafael Torres Neto:** Investigation, Resources, Writing – review & editing. **Heitor Flavio Ferrari:** Investigation, Writing – review & editing. **Renee Laufer-Amorim:** Investigation, Resources, Writing – review & editing. **José Cândido Caldeira Xavier-Júnior:** Conceptualization, Supervision, Formal analysis, Resources, Writing – review & editing. All authors have read and approved the final version of the manuscript.

Conflict of Interest

The authors declare no competing interests.

Generative AI Use Statement

The authors did not use generative artificial intelligence tools or technologies in creating any part of this manuscript.

Funding

This research did not receive any specific grant from funding agencies in the public, commercial, or not-for-profit sectors.

References

1. Bahmad HF, Oh KS, Alexis J. Potential diagnostic utility of PRAME and p16 immunohistochemistry in melanocytic nevi and malignant melanoma. J Cutan Pathol. 2023;50:763-72. doi: 10.1111/cup.14438.

2. Bergman PJ, Selmic LE, Kent MS. Melanoma. In: Vail DM, Tham DH, Liptak JM, editors. Withrow and MacEwen's Small Animal Clinical Oncology. 6th ed., Elsevier; 2019, p.367-81.
3. Blume GR, Eloi RSA, Oliveira LB, Sonne L, Rezende LPO, Sant'Ana FJF. Lesions of the oral cavity of dogs: 720 cases. Pesq Vet Bras. 2023;43:e07073. doi: 10.1590/1678-5150-PVB-7073.
4. Elder DE, Massi D, Scolyer RA, Willemze R. WHO Classification of Skin Tumors. 4th ed. Lyon: International Agency for Research on Cancer; 2018. p.65-152.
5. Epping MT, Wang L, Edel MJ, Carlée L, Hernandez M, Bernards R. The human tumor antigen PRAME is a dominant repressor of retinoic acid receptor signaling. Cell. 2005;122:835-47. doi: 10.1016/j.cell.2005.07.003.
6. Esplin DG. Survival of dogs following surgical excision of histologically well-differentiated melanocytic neoplasms of the mucous membranes of the lips and oral cavity. Vet Pathol. 2008;45:889-96. doi: 10.1354/vp.45-6-889.
7. Hindriks E, Bergmann W, Ruiz AM, De Maria R, Zandvliet MMJM, Sijts AJAM, et al. Cancer-testis antigen expression in canine melanoma and healthy tissues. Vet Immunol Immunopathol. 2025;284:110946. doi:10.1016/j.vetimm.2025.110946.
8. Ikeda H, Lethé B, Lehmann F, van Baren N, Baurain JF, de Smet C, et al. Characterization of an antigen that is recognized on a melanoma showing partial HLA loss by CTL expressing an NK inhibitory receptor. Immunity. 1997;6:199-208. doi: 10.1016/s1074-7613(00)80426-4.
9. Kaczorowski M, Chłopek M, Kruczak A, Ryś J, Lasota J, Miettinen M. PRAME expression in cancer. A systematic immunohistochemical study of >5800 epithelial and nonepithelial tumors. Am J Surg Pathol. 2022;46:1467-76. doi: 10.1097/PAS.0000000000001944.
10. Lezcano C, Jungbluth AA, Nehal KS, Hollmann TJ, Busam KJ. PRAME expression in melanocytic tumors. Am J Surg Pathol. 2018;42:1456-65. doi: 10.1097/pas.0000000000001134.
11. Lezcano C, Pulitzer M, Moy AP, Hollmann TJ, Jungbluth AA, Busam KJ. Immunohistochemistry for PRAME in the distinction of nodal nevi from metastatic melanoma. Am J SurgPathol. 2020;44:503-8. doi:10.1097/PAS.0000000000001393.
12. Lohman ME, Steen AJ, Grekin RC, North JP. The utility of PRAME staining in identifying malignant transformation of melanocytic nevi. J Cutan Pathol. 2021;48:856-62. doi: 10.1111/cup.13958.
13. Machado GAC, Fontes TN, Larangeira DF, Estrela-Lima A, Moreira ELT, Ribeiro LS, et al. Incidence of skin tumors in dogs in Salvador, Bahia state, Brazil (2007-2016). Pesq Vet Bras. 2018;38:2146-9. doi: 10.1590/1678-5150-PVB-5686.
14. Rasic D, Korsgaard N, Marcussen N, Precht Jensen EM. Diagnostic utility of combining PRAME and HMB-45 stains in primary melanocytic tumors. Ann Diagn Pathol. 2023;67:152211. doi: 10.1016/j.anndiagpath.2023.152211.
15. Rawson R V., Shteinman ER, Ansar S, Vergara IA, Thompson JF, Long G V., et al. Diagnostic utility of PRAME, p53 and 5-hmC immunostaining for distinguishing melanomas from naevi, neurofibromas, scars and other histological mimics. Pathology. 2022;54:863-73. doi: 10.1016/j.pathol.2022.05.012.
16. Santos IR, Lima ACMP, Ferreira HH, Rezende BR, Silva AR, Santos AS. Canine cutaneous neoplasms in the metropolitan region of Goiânia, Goiás state, Brazil. Pesq Vet Bras. 2020;40:614-20. doi: 10.1590/1678-5150-PVB-6531.
17. Smedley R, Bacmeister C, Bongiovanni L, Clifford CA, Donovan TA, Esplin DG, et al. Cutaneous Melanoma Guideline, version 1.0. Https://VcgpOrg/Documents/2022/03/Cutaneous-Melanocytic-Neoplasms-CaninePdf/ 2021:1–6.
18. Smedley RC, Bongiovanni L, Bacmeister C, Clifford CA, Christensen N, Dreyfus JM, et al. Diagnosis and histopathologic prognostication of canine melanocytic neoplasms: A consensus of the Oncology-Pathology Working Group. Vet Comp Oncol. 2022;20:739-51. doi:10.1111/vco.12827.
19. Smedley RC, Sebastian K, Kiupel M. Diagnosis and prognosis of canine melanocytic neoplasms. Vet Sci. 2022;9:175. doi: 10.3390/vetsci9040175.
20. Spangler WL, Kass PH. The histologic and epidemiologic bases for prognostic considerations in canine melanocytic neoplasia. Vet Pathol. 2006;43:136-49. doi: 10.1354/vp.43-2-136.
21. Turner N, Ko CJ, Mcniff JM, Galan A. Pitfalls of PRAME immunohistochemistry in a large series of melanocytic and nonmelanocytic lesions with literature review. Am J Dermatopathol. 2023;46:21-30. doi: 10.1097/dad.0000000000002584.
22. Wadelin F, Fulton J, Mcewan PA, Spriggs KA, Emsley J, Heery DM. Leucine-rich repeat protein PRAME: expression, potential functions and clinical implications for leukaemia. Mol Cancer. 2010;27:226. doi: 10.1186/1476-4598-9-226.
23. Xu Y, Zou R, Wang J, Wang Z wei, Zhu X. The role of the cancer testis antigen PRAME in tumorigenesis and immunotherapy in human cancer. Cell Prolif. 2020;53:e12770. doi: 10.1111/cpr.12770.