Braz J Vet Pathol, 2026, vol. 19, e19S101
DOI: https://doi.org/10.24070/bjvp.1983-0246.019S101

BJVP
Brazilian Journal of Veterinary Pathology
ISSN 1983-0246

**Diagnostic Exercise**
From the Latin Comparative Pathology Group and the Davis-Thompson Foundation

# Feline Malignant Melanoma

Cassandra M. Powers[1, 2, *]
[1]California Animal Health and Food Safety Laboratory, Davis, CA
[2]Purdue University, West Lafayette, IN

[*]**Corresponding author:** cmpowers@ucdavis.edu

**History:**

A 5-year-old female spayed domestic shorthair initially presented to oncology services for a 4-month history of a subcutaneous mass on the right side of the mandible that extended into the mouth. The right eyeball had been previously enucleated one year prior due to an undisclosed reason. At presentation, the animal was having difficulty eating and breathing. Due to concerns for quality of life, humane euthanasia was elected.

**Autopsy Findings (Fig. 1):**

Within the lingual gingival margin of tooth 108 and extending into, infiltrating, and partially effacing the right temporalis muscle, the right pterygoid muscle, the right masseter muscle, the right digastricus muscle, and teeth 108 and 109 was an 8.5 cm x 7 cm x 4 cm dark brown to black, well demarcated firm mass. The mass completely filled the empty right orbit and partially invaded and contorted the right nasal conchae and frontal bone towards midline. On cut section, the mass was diffusely dark brown to black with a friable center.

Additional necropsy findings include pale mucous membranes, a mild to moderate left ventricular hypertrophy, and chronic passive hepatic congestion.

**Autopsy Findings (Fig. 1):**

Within the lingual gingival margin of tooth 108 and extending into, infiltrating, and partially effacing the right temporalis muscle, the right pterygoid muscle, the right masseter muscle, the right digastricus muscle, and teeth 108 and 109 was an 8.5 cm x 7 cm x 4 cm dark brown to black, well demarcated firm mass. The mass completely filled the empty right orbit and partially invaded and contorted the right nasal conchae and frontal bone towards midline. On cut section, the mass was diffusely dark brown to black with a friable center.

**The Diagnostic Exercises are an initiative of the Latin Comparative Pathology Group (LCPG), the Latin American subdivision of The Davis-Thompson Foundation (DTF). These exercises are contributed by members and non-members from any country of residence. Consider submitting an exercise! A final document containing this material with answers and a brief discussion will be posted on the DTF website: https://davisthompsonfoundation.org/diagnostic-exercise/*

***Editor-in-chief for this Diagnostic Exercise:*** *Claudio Barros*
***Associate Editor for this Diagnostic Exercise:*** *Daniel Rissi*

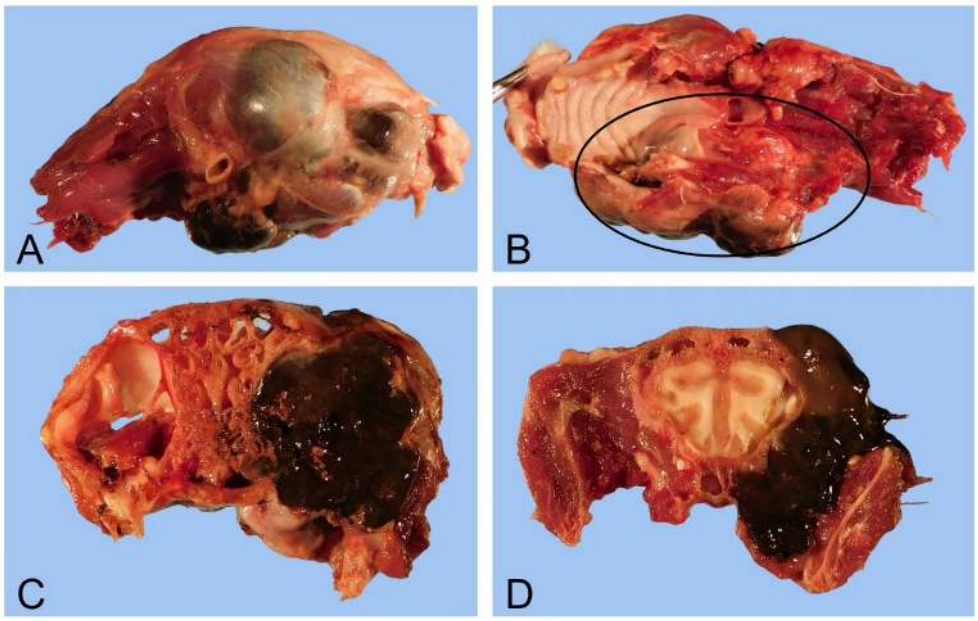


**Figure 1**. **(A)** The mass infiltrates into and partially effaces most of the musculature on the right side of the face and fills the empty right orbit. **(B)** On the ventral aspect of palate, the mass infiltrates into and raises the gingiva, replacing teeth 108 and 109. **(C, D)** On cut section, the mass infiltrates and partially contorts the right conchae and frontal bone.

Additional necropsy findings include pale mucous membranes, a mild to moderate left ventricular hypertrophy, and chronic passive hepatic congestion.

**Follow-up questions:**

- *Histologic Description:*
- *Diagnosis:*

**ANSWERS**

**Histologic Description (Figs. 2 and 3):**

Embedded within the subcutis, compressing and infiltrating the surrounding connective tissue, and surrounding and effacing adjacent muscular bundles was a densely cellular neoplasm composed of round to polygonal cells arranged in sheets and packets on a scant stroma with basophilic fibrillar cellular material and hemorrhage. Neoplastic cells had variably distinct cell borders with moderate amounts of eosinophilic cytoplasm and variable amounts of intracytoplasmic black to brown granules (melanin). Nuclei were round to oval and slightly hyperchromatic. Binucleation and multinucleation were common. Anisocytosis and anisokaryosis were moderate to marked. There were 8 mitotic figures in 2.37 $mm^2$. Neoplastic cells infiltrated into the adjacent bones of the calvarium and nasal conchae, raising the respiratory epithelium and expanding the subepithelial stroma.

**Diagnosis:**

Malignant melanoma

**Comments:**

The diagnosis in this case was malignant melanoma. There was debate on the origin of this tumor. On clinical presentation, an oral melanoma was diagnosed based on the gross changes. However, this cat also had a history of enucleation of the right eye due to an unconfirmed ocular disease. Since ocular melanomas are more common than oral tumors in cats, a primary ocular melanoma was suspected in this case. However, this diagnosis could not be confirmed.

In cats, melanomas are found most often on the head, neck, and lower limbs. Malignant melanomas are relatively rare in cats. Melanomas, in general, comprise less than 3% of skin tumors with approximately 42% to 68% of those being malignant (3). Malignant melanomas account for less than 1% of oral tumors in cats (7). Most cat melanomas are amelanotic. There are no established grading schemes for melanomas in cats. However, a recently proposed grading scheme for feline non-ocular melanomas evaluates tumor site, mitotic count, and intratumoral necrosis (6, 7).

On gross evaluation, melanocytomas are usually solitary, circumscribed, alopecic nodules that range from 1 to 4 cm in diameter. In comparison, malignant melanomas are variably circumscribed, unencapsulated, polypoid, dome-shape, or plaque-like. Most melanocytic tumors are brown to

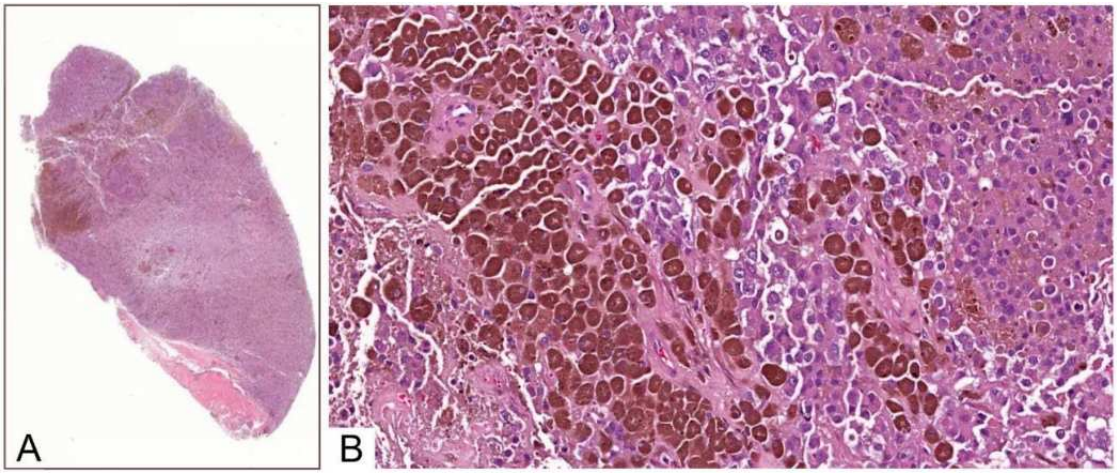


**Figure 2**. **(A)** Low magnification of the mass. **(B)** The neoplasm is composed of round to polygonal cells arranged in sheets and packets on scant amounts of stroma. Neoplastic cells have variably distinct borders with moderate amounts of eosinophilic cytoplasm and variable amounts of intracytoplasmic brown granules (melanin).

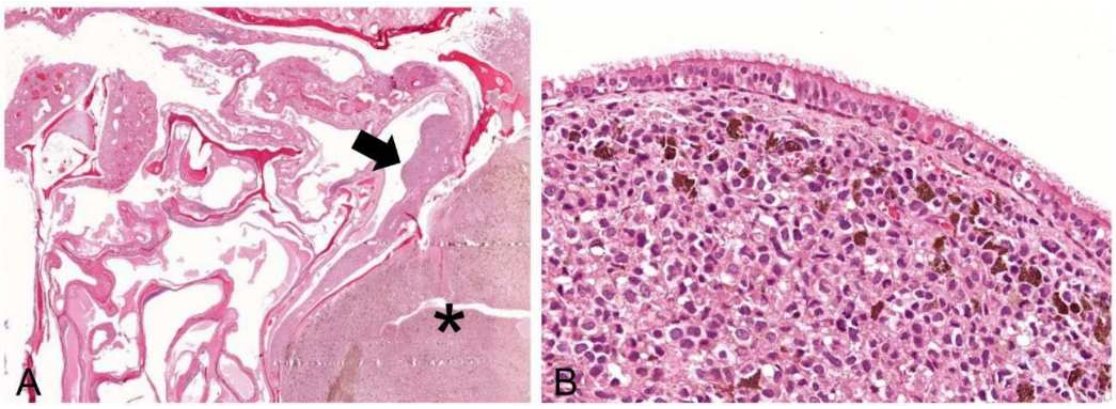


**Figure 3: (A)** The mass **(asterisk)** infiltrates into and partially contorts the nasal conchae. The neoplastic cells infiltrate into the adjacent bones and nasal conchae **(arrow)**. **(B)** The neoplasm raises the ciliated respiratory epithelium and expands the subepithelial stroma.

black but may also appear gray to tan. Ulceration is common (7, 8, 9).

Histologically, melanocytic tumors are often composed of pleomorphic cells arranged in a variety of distributions including sheets, interwoven bundles, clusters, etc. Uncommon histological variants include balloon cell, clear cell, signet ring, rhabdoid, and desmoplastic. The amount of pigmentation is variable and may not be found at all in cases. Junctional activity is an important diagnostic feature in many cases (7, 8, 9).

Oral malignant melanomas are rare in cats and comprise less than 1% of oral malignancies in this species (7). Tumor sites include the gums, lip, palate, and tongue. In general, prognosis is poor for feline oral melanocytic neoplasms. In one study, most cats were euthanized due to metastases in 1–135 days (mean 61 days) (5). Cats with oral melanomas treated using radiation therapy had a median survival time of 146 days (2).

Melanocytic neoplasia is the most common form of ocular tumors in cats, accounting for 67% of cases (4). Feline diffuse iris melanoma (FDIM) is by far the most common form of ocular melanocytic neoplasia and uveal melanoma, with limbal melanomas and atypical melanoma (melanoma affecting the choroid or ciliary body) infrequently recognized. Early lesions begin as flat areas of pigmentation of the iris, known as iris melanosis. Iris melanosis in cats is generally a benign change but has been reported in rare cases to transform into malignant melanoma (4).

Non-ocular melanocytic neoplasms are often considered rare in cats. These tumors often account for less than 1% of all feline oral neoplasms and approximately 0.5% of feline cutaneous tumors (1, 5, 6). According to the current literature, feline non-ocular melanomas seem to respond much like canine melanomas and have similar biological tendencies to their canine counterparts (1, 5).

Melan-A and PNL-2 antibodies are routinely used for the diagnosis of amelanotic melanomas in dogs and cats. Some feline oral melanomas have been reported to label with S100, although the specificity of this antibody is unknown (7, 9). Wide surgical excision has been suggested for treatment of non-ocular melanoma in both dogs and cats. Monitoring for metastasis is crucial, as surgery will only control localized disease (7).

**References:**

1. Chamel G, Abadie J, Albaric O, Labrut S, Ponce F, Ibisch C. Non-ocular melanomas in cats: a retrospective study of 30 cases. J Feline Med Surg. 2017;19(4):351-357. doi: 10.1177/1098612X15625355. Epub 2016 Jan 1. PMID: 26767979; PMCID: PMC11119639.
2. Farrelly J, Denman DL, Hohenhaus AE, Patnaik AK, Bergman PJ. Hypofractionated radiation therapy of oral melanoma in five cats. Vet Radiol Ultr.. 2004;45(1):91-3.
3. Gross TL, Ihrke PJ, Walder EJ, Affolter VK. Skin diseases of the dog and cat: clinical and histopathologic diagnosis. John Wiley & Sons; 2008 Apr 15.
4. Kayes D, Blacklock B. Feline Uveal Melanoma Review: Our Current Understanding and Recent Research Advances. Vet Sci. 2022 26;9(2):46. doi: 10.3390/vetsci9020046. PMID: 35202299; PMCID: PMC8877522.
5. Luna LD, Higginbotham ML, Henry CJ, Turnquist SE, Moore AS, Graham JC. Feline non-ocular melanoma: a retrospective study of 23 cases (1991–1999). J Fel Med Surg. 2000;2(4):173-81.
6. Pittaway R, Dobromylskyj MJ, Erles K, Pittaway CE, Suárez-Bonnet A, Chang YM, Priestnall SL. Nonocular Melanocytic Neoplasia in Cats: Characterization and Proposal of a Histologic Classification Scheme to More Accurately Predict Clinical Outcome. Vet Pathol. 2019;56(6):868-877. doi: 10.1177/0300985819854435. Epub 2019 Jun 20. PMID: 31221042.
7. Polton G, Borrego JF, Clemente-Vicario F, Clifford CA, Jagielski D, Kessler M, Kobayashi T, Lanore D, Queiroga FL, Rowe AT, Vajdovich P. Melanoma of the dog and cat: consensus and guidelines. Front Vet Sci. 2024 5;11:1359426.
8. Puckett Y, Wilson AM, Farci F, Thevenin C. Melanoma pathology. In: StatPearls [Internet] 2024 Jul 2. StatPearls Publishing.
9. Smith SH, Goldschmidt MH, McManus PM. A comparative review of melanocytic neoplasms. Vet Pathol. 2002;39(6):651–678.15.