Braz J Vet Pathol, 2026, vol. 19, e19S102
DOI: https://doi.org/10.24070/bjvp.1983-0246.019S102

BJVP
Brazilian Journal of Veterinary Pathology
ISSN 1983-0246

Diagnostic Exercise
From the Latin Comparative Pathology Group and the Davis-Thompson Foundation

Fibrous osseous dystrophy and early-onset chronic kidney disease from renal dysplasia in a juvenile dog

Deepa Cavalli-Sforza[1], Pablo Díaz-Santana[2], Bernat Martí-García[1], Alejandro Suarez-Bonnet[1]*.
The Royal Veterinary College, Hawkshead Lane, North Mymms, Hatfield, Hertfordshire & Veterinary Pathology Centre, University of Surrey, Guildford, United Kingdom.

Corresponding author: asuarezbonnet@rvc.ac.uk

History:

A postmortem examination was performed on an 8-month-old, intact female crossbred dog that was humanely euthanized following an acute onset of vomiting, diarrhea, and lethargy. The animal had renal azotemia, chronic kidney disease and small stature.

Autopsy findings:

On gross examination, the kidneys were bilaterally reduced in size, with irregular contours and a coarse capsular surface. The corticomedullary junction was inconspicuous, and approximately 85% of the parenchyma was replaced by firm white tissue (Figure 1). The parathyroid glands were bilaterally and symmetrically enlarged. The bones of the skull and all teeth were markedly pliable. The calvarial midline was easily incised with a scalpel, and on sectioning, the maxillary and frontal bones bilaterally exhibited reduced bone mass and distortion and widening by proliferative, disorganized, firm white tissue (Figure 3). The lungs were bilaterally and diffusely markedly heavy, with a gritty consistency, reddened and failed to collapse. Multifocal, random, ill-defined intraparenchymal cream-colored gritty areas were present. On cut surface, the lungs exuded a large volume of serosanguinous foamy serous fluid. The intima of the aorta, adjacent to the aortic valve, was multifocally irregular and gritty. Tissue samples from the kidneys (Figure 2), parathyroid glands, lungs, stomach, aorta, heart and bone (Figures 4-5) were collected for histopathological examination. .

*The Diagnostic Exercises are an initiative of the Latin Comparative Pathology Group (LCPG), the Latin American subdivision of The Davis-Thompson Foundation (DTF). These exercises are contributed by members and non-members from any country of residence. Consider submitting an exercise! A final document containing this material with answers and a brief discussion will be posted on the DTF website: https://davisthompsonfoundation.org/diagnostic-exercise/

Editor-in-chief for this Diagnostic Exercise: *Claudio Barros*
Associate Editor for this Diagnostic Exercise: *Daniel Rissi*

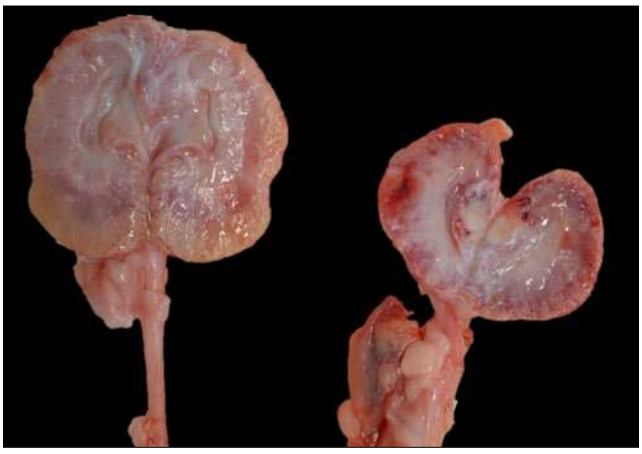

Figure 1. Kidneys of a juvenile dog with renal dysplasia. The kidneys are small, irregular and with a coarse capsular surface. Approximately 85% of the parenchyma is replaced by firm white tissue.

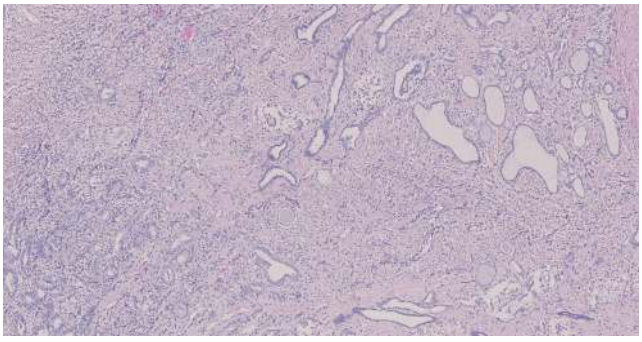

Figure 2. Kidney of a juvenile dog with renal dysplasia Medulla. There are multifocal, variably sized, persistent metanephric ducts lined by pseudostratified cuboidal to columnar epithelium. The medullary interstitium is expanded by highly cellular, undifferentiated and poorly organised extracellular matrix consistent with immature mesenchyme.



Figure 3. Craniofacial changes associated with fibrous osteodystrophy. The maxillary and frontal bones show reduced bone mass with distortion and expansion by proliferative, disorganized, firm white tissue

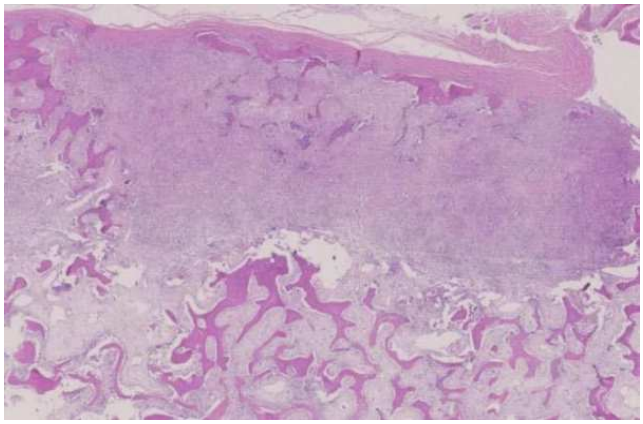

Figure 4. Frontal bone. There is diffuse fibroplasia, with bone trabeculae and marrow spaces replaced by proliferation of highly cellular fibrous connective tissue.

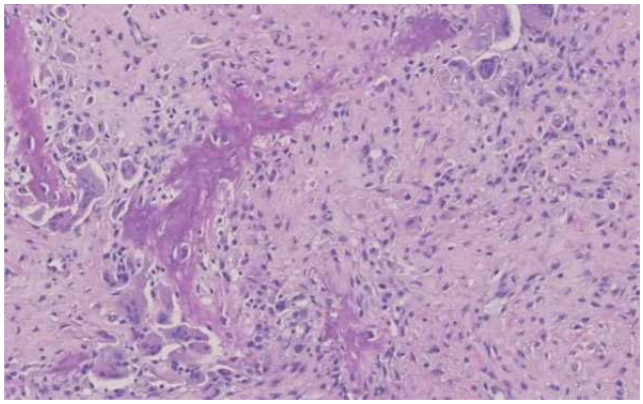

Figure 5. Frontal bone. There are high numbers of multinucleated osteoclasts within Howship's lacunae along the surface of mineralised trabeculae (active bone resorption) or scattered within the fibrous connective tissue. Embedded within the fibrous connective tissue there are variably sized, irregular and delicate trabeculae of poorly mineralized woven bone, lined by plump osteoblasts (new bone formation).

Microscopic description:

Kidneys: There is extensive capsular and cortical interstitial fibrosis which replaces glomeruli and tubules. The remaining glomeruli are atrophied, have mineralized Bowman's capsule or consist of immature tructures with dilated Bowman's space and poor to absent capillary tufts. Remaining cortical tubules are ectatic and lined by attenuated, often mineralized epithelium. Glomeruli and cortical tubules are extensively distorted by woven bone (dysontogenic metaplasia). In the medulla, there are numerous variably sized, persistent metanephric ducts lined by pseudostratified cuboidal to columnar epithelium, and the interstitium is expanded by highly cellular, undifferentiated and poorly organized extracellular matrix consistent with immature mesenchyme.

Bone, frontal bone: There is a diffuse fibroplasia, with bone trabeculae and marrow spaces replaced by proliferation of highly cellular fibrous connective tissue. There are high numbers of multinucleated osteoclasts in Howship's lacunae along the surface of mineralized trabeculae (active bone resorption) or scattered within the fibrous connective tissue. Embedded within the fibrous connective tissue there are variably sized, irregular and delicate trabecula of poorly mineralized woven bone lined by plump osteoblasts.

Follow up questions:

- Name the skeletal condition
- How does chronic kidney disease lead to the craniofacial bone remodeling observed in this case?

ANSWERS

- **Name the skeletal condition:**

Fibrous osteodystrophy (osteodystrophy fibrosa, osteitis fibrosa cystica)

- **How does chronic kidney disease lead to the craniofacial bone remodeling observed in this case?"**

In **chronic kidney disease**, the kidney's ability to excrete phosphate can be impaired, resulting in **hyperphosphatemia**. As phosphorus binds to calcium, elevated phosphate levels can result in **hypocalcaemia**. Concurrently, renal dysfunction reduces the kidney's capability to convert 25-hydroxyvitamin D to **calcitriol** (1,25-dihydroxyvitamin D_3), its active form. As calcitriol is needed for intestinal calcium absorption, a deficiency in this vitamin in turn, can exacerbate hypocalcaemia.

Both the hypocalcaemia and the decreased calcitriol levels are sensed by the parathyroid glands, leading typically to bilateral, symmetrical hyperplasia, to increase PTH secretion (**secondary (renal) hyperparathyroidism**). Elevated PTH enhances osteoclastic bone resorption via RANKL expression on osteoblast precursors.

Over time, there is an excessive and disorganised bone resorption, with replacement of normal trabecular bone by fibrous connective tissue (**fibrous osteodystrophy**). The affected bones become pliable and deformed, particularly in regions of high remodelling activity such as the mandible and the maxilla. In advanced cases, this may manifest clinically as "rubber jaw", a colloquial term to described advanced bone demineralisation and fibrous replacement in the jaw bones.

As a compensatory mechanism to hyperphosphatemia, **fibroblast growth factor 23 (FGF23)** is upregulated, a hormone produced mainly by osteocytes and to a lesser extent by osteoblasts in the bone. FGF23 decreases phosphate levels by reducing phosphate reabsorption in the proximal tubules and supresses calcitriol synthesis via downregulation of 1-alpha hydroxylase and PTH secretion. However, in CKD, likely due to reduced Klotho expression (a cofactor required by FGF23 for binding to its FGF-23 receptors), FGF23 signalling is impaired, limiting its effectiveness. This contributes to persistent hyperphosphatasemia and worsening hypocalcemia, perpetuating PTH release and bone resorption (2).

Discussion:

This case exemplifies the systemic consequences of renal dysplasia in a juvenile dog, characterised by classical gross and microscopic features of renal dysplasia, fibrous osteodystrophy, and metastatic calcification, among other findings.

Renal dysplasia is typically a congenital condition characterised by disorganised development of the renal parenchyma due to anomalous differentiation (1, 3, 6). This process often results in impaired nephron formation and progressive renal failure (1). While the condition is known to be hereditary in several dog breeds, including Shih Tzus, Lhasa Apsos, Golden Retrievers, and Alaskan Malamutes (1), and inherited in an autosomal dominant manner in Suffolk sheep (cystic renal dysplasia) (6), it may also arise from neonatal disease occurring before nephrogenesis is complete (3). Reported infectious causes include Canine herpesvirus-1, Feline panleukopenia virus, and Bovine viral diarrhoea virus (1). In pigs, renal dysplasia has been associated with hypovitaminosis A and dysregulation of proto-oncogene Ret signalling pathways (3). In this case, no infectious aetiology was identified, and the dog's genetic background was deemed non-contributory.

Based on the gross appearance of the kidneys and the animal's age, differential diagnoses included renal hypoplasia, early-onset renal fibrosis, and progressive juvenile nephropathy (6). There are five recognized histological hallmarks of renal dysplasia: immature glomeruli with poorly developed tufts; persistent primitive metanephric ducts lined with cuboidal or columnar epithelium; primitive mesenchyme; atypical tubular epithelium; and dysontogenic osseous or cartilaginous metaplasia (1, 3, 6). It is important to note that presence of immature glomeruli alone is not diagnostic for renal dysplasia, as they may occur in small numbers in normal dogs (1). In this case, the presence of persistent primitive metanephric ducts, primitive mesenchyme, and dysontogenic osseous metaplasia supported a definitive diagnosis of renal dysplasia. Secondary features may include interstitial fibrosis, renal cysts, and compensatory glomerular hypertrophy. No concurrent congenital anomalies—such as imperforate anus or segmental ureteral agenesis, that are sometimes associated with renal dysplasia (3)—were identified in this case.

Secondary to altered calcium–phosphorus metabolism, the dog developed bilateral **parathyroid gland**

hyperplasia, histologically confirmed as chief cell hyperplasia. This endocrine response was associated with marked skeletal abnormalities, particularly bilateral distortion and demineralization of the maxilla and frontal bones, consistent with the classical "rubber jaw" presentation—pliable mandibles, dental malocclusion, and craniofacial distortion (4). Histologically, the skeleton showed extensive osteolysis with marked fibroplasia, increased osteoclastic bone resorption, and osteoblastic activity with formation of immature woven bone, confirming fibrous osteodystrophy.

Fibrous osteodystrophy is a metabolic bone disease resulting from persistently elevated plasma parathyroid hormone (PTH) levels, due to either primary hyperparathyroidism (e.g. functional chief cell adenoma), pseudohyperparathyroidism (humoral hypercalcemia of malignancy, e.g. adenocarcinoma of the apocrine glands of the anal sac secreting parathyroid hormone-related peptide, lymphoma), or more commonly, secondary renal or nutritional causes (2, 4, 5). Nutritional secondary hyperparathyroidism arises from diets low in calcium, high in phosphorus, or containing calcium-binding oxalates, as seen in tropical grasses (4). A classic example of this is "bran disease" in horses fed grain, corn, and grain by-products (4). Species commonly affected by fibrous osteodystrophy include horses, pigs, dogs, cats, ferrets, goats, reptiles, and New World nonhuman primates, with sheep and cattle less frequently involved (4). Clinical signs tend to be more severe in young, growing animals due to high rates of bone turnover and include craniofacial deformities ("big head"), lameness, and impaired mastication (4).

Additional findings in this case included interstitial pneumonia with septal mineralisation and alveolar oedema (uraemic pneumonitis), chronic lymphoplasmacytic erosive gastritis with mucosal and vascular mineralisation (uraemic gastritis), and mineralisation of the aortic intima. These lesions are consistent with widespread soft tissue metastatic calcification secondary to uraemia (6) and likely contributed to the clinical signs of vomiting and diarrhoea observed prior to death.

In conclusion, this case represents severe early-onset chronic kidney disease due to bilateral renal dysplasia in a juvenile dog. The condition was complicated by secondary renal hyperparathyroidism, fibrous osteodystrophy, and extensive metastatic calcification, including uraemic gastritis and pneumonitis, illustrating the systemic impact of congenital renal maldevelopment.

References:

1. Bruder MC, Shoieb AM, Shirai N, Boucher GG, Brodie TA. Real dysplasia in Beagle dogs: four cases. *Toxicol Pathol*. 2010;38(7):1051-1057.
2. Chacar FC, Kogika MM, Zafalon RVA, Brunetto MA. Vitamin D Metabolism and Its Role in Mineral and Bone Disorders in Chronic Kidney Disease in Humans, Dogs and Cats. *Metabolites*. 2020;10(12):499.
3. Cianciolo RE, Mohr FC. Urinary system. In: Maxie MG, editor. *Jubb, Kennedy & Palmer's Pathology of Domestic Animals*. 6th ed. Vol. 2. St. Louis: Elsevier; 2016. p. 391–397.
4. Craig LE, Dittmer KE, Thompson KG. Bones and joints. In: Maxie MG, editor. *Jubb, Kennedy & Palmer's Pathology of Domestic Animals*. 6th ed. Vol. 1. St. Louis: Elsevier; 2016. p. 75–80.
5. Dittmer KE, Thompson KG. Vitamin D metabolism and rickets in domestic animals: A review. *Vet Pathol*. 2011;48(2):389–407.
6. Sula MJ, Lane LV. Urinary system. In: Zachary JF, editor. *Pathologic Basis of Veterinary Disease*. 7th ed. St. Louis: Elsevier; 2022. p. 722–724.