Braz J Vet Pathol, 2026, vol. 19, e19S103
DOI: https://doi.org/10.24070/bjvp.1983-0246.019S103

BJVP
Brazilian Journal of Veterinary Pathology
ISSN 1983-0246

Diagnostic Exercise
From the Latin Comparative Pathology Group and the Davis-Thompson Foundation

Caprine thymoma

Kaylin Lizette Moctezuma[1], Emily Reinhardt[1], Julia Burkett[1].
[1]Department of Pathobiology, Connecticut Veterinary Medical Diagnostic Laboratory. University of Connecticut.

Corresponding author: kaylin.moctezuma@uconn.edu

History:

6-year-old, neutered male, goat was submitted for necropsy. Clinical history included 3 weeks of lameness following possible trauma which was gradually improving. The day prior to euthanasia this goat was acutely lethargic and anorexic. On physical exam, the goat was thin and weak. The animal was euthanized due to quality-of-life concerns.

Autopsy findings:

Within the cranial mediastinum there was a multilobulated, highly vascularized mass measuring approximately 25 cm x 24 cm x 8 cm in diameter which resulted in caudal and lateral displacement of lung lobes (Fig 1). There were multiple adhesions between the pleural surfaces of multiple lung lobes and the pericardium to the mass, most severely of the right cranial lung lobe. On the cut surface the periphery of the mass was composed of light tan to pink homogenous tissue which bulged on the cut surface. The center of the mass consisted of a caseous yellow material (necrosis, presumed) and multiple regions of yellow gelatinous material and/or hemorrhage. The lungs were non-collapsed and mottled light pink to dark red (Fig 2). Samples of the lung (Fig 3) and mass (Fig 4) were collected for histopathology.

Follow-up questions:

- *Morphologic diagnosis:*
- *Paraneoplastic conditions that could be associated:*
- *What IHC markers would be requested:*

**The Diagnostic Exercises are an initiative of the Latin Comparative Pathology Group (LCPG), the Latin American subdivision of The Davis-Thompson Foundation (DTF). These exercises are contributed by members and non-members from any country of residence. Consider submitting an exercise! A final document containing this material with answers and a brief discussion will be posted on the DTF website: https://davisthompsonfoundation.org/diagnostic-exercise/*

Editor-in-chief for this Diagnostic Exercise: *Claudio Barros*
Associate Editor for this Diagnostic Exercise: *Daniel Rissi*

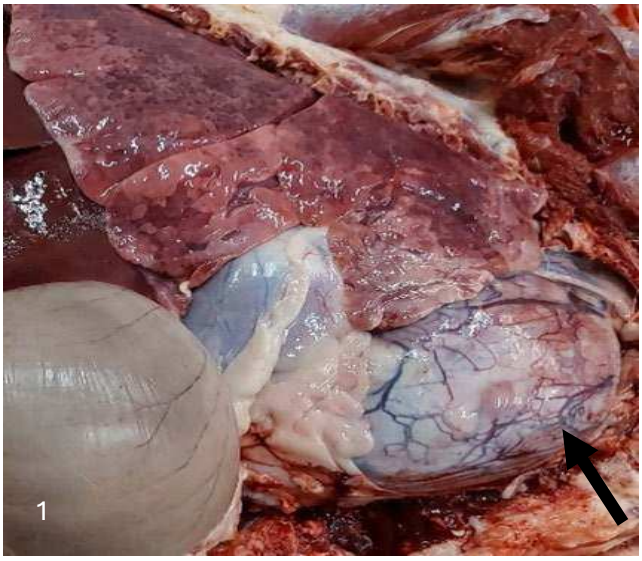

Figure 1. Thoracic cavity & mediastinum. The black arrow indicates a mediastinal mass compressing the heart and cranially displacing the lung.



Figure 2. The mediastinal mass on cut surface had an extensive area of caseous necrosis admixed with hemorrhage and gelatinous material.

ANSWERS

Histologic description:

Lung (Fig. 3): The lung exhibits moderate atelectasis due to compression by the mediastinal mass, which is well demarcated by a thick fibrous capsule.

Mediastinal Mass (Figs. 3 & 4): The expansile and compressive mass comprises an encapsulated, well-demarcated and highly cellular neoplasm composed of polygonal cells, arranged in small islands and occasional loose cords supported by a fibrovascular stroma. Neoplastic cells have a distinct cell border and abundant eosinophilic cytoplasm, and round to oval nucleus with finely stippled chromatin and indistinct nucleoli. Interspersed throughout are high numbers of small lymphocytes. There is moderate anisocytosis and anisokaryosis. Mitoses are rare. Mixed with neoplastic cells are occasional mineral deposits.

Immunohistochemical slides were evaluated for CD3 (Figs. 5 and 6; low and high magnification, respectively), CD20 and Pancytokeratin AE1/AE3 (Figs. 7 and 8; low and high magnification, respectively). A non-pathologic caprine lymph node was used as a positive control for CD3 and CD20; and a section of caprine small intestine was used as a positive control for Pancytokeratin AE1/AE3.

Immunohistochemistry:

Multiple immunohistochemical markers were evaluated including:

Immunohistochemistry	Results	Interpretation
CD3	+	Non-neoplastic small lymphocytes have strong cytoplasmic immunoreactivity (Fig 5 and 6).
CD20	-	There is no immunoreactivity.
PANCKYTOKERATIN AE1/AE3	+/-	50% of neoplastic cells have strong cytoplasmic immunoreactivity.

Morphologic diagnosis:

Thymoma

Comment:

Primary neoplasms of the thymus are uncommon. Of these, the most commonly observed neoplasms include thymic epithelial tumors (thymomas and thymic carcinomas) and thymic lymphomas. Rare neoplasms include thymic germ cell tumors. The histologic classification of thymomas and thymic carcinomas in veterinary medicine has been inconsistent, and the correlation of different classification schemes with clinical outcome is not well established. Most thymic epithelial neoplasms have a favorable long-term prognosis following surgical removal, but a small subset will recur or metastasize. Furthermore, like other thymic diseases, thymic epithelial neoplasms increase the risk of having one or more autoimmune disorders, most notably myasthenia gravis.[1]

In human medicine, multiple histologic classifications have been proposed for thymic epithelial tumors to better correlate histologic features with clinical behavior, but the World Health Organization (WHO) classification scheme for thymic epithelial tumors is most widely used. The basis for this classification is the morphology of the neoplastic epithelial cells and the relative proportion of non-neoplastic lymphocytes. It is rare for thymic epithelial tumors to be purely epithelial, and the association of lymphocytes with epithelium, even in metastatic sites, suggests that the latter

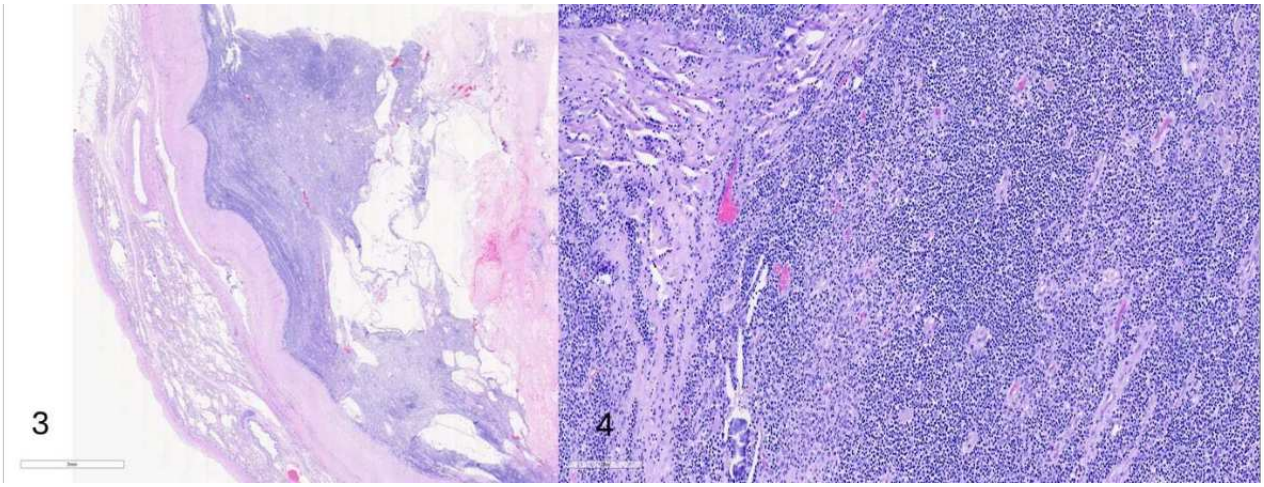

Figs. **3 and 4.** Mediastinal mass . Fig. 3. Lung, The lung exhibits moderate atelectasis due to compression by the mediastinal mass, which is well demarcated by a thick fibrous capsule. (Fig. 3) The expansile and compressive mass comprises an encapsulated, well-demarcated and highly cellular neoplasm composed of polygonal cells, arranged in small islands and occasional loose cords supported by a fibrovascular stroma.

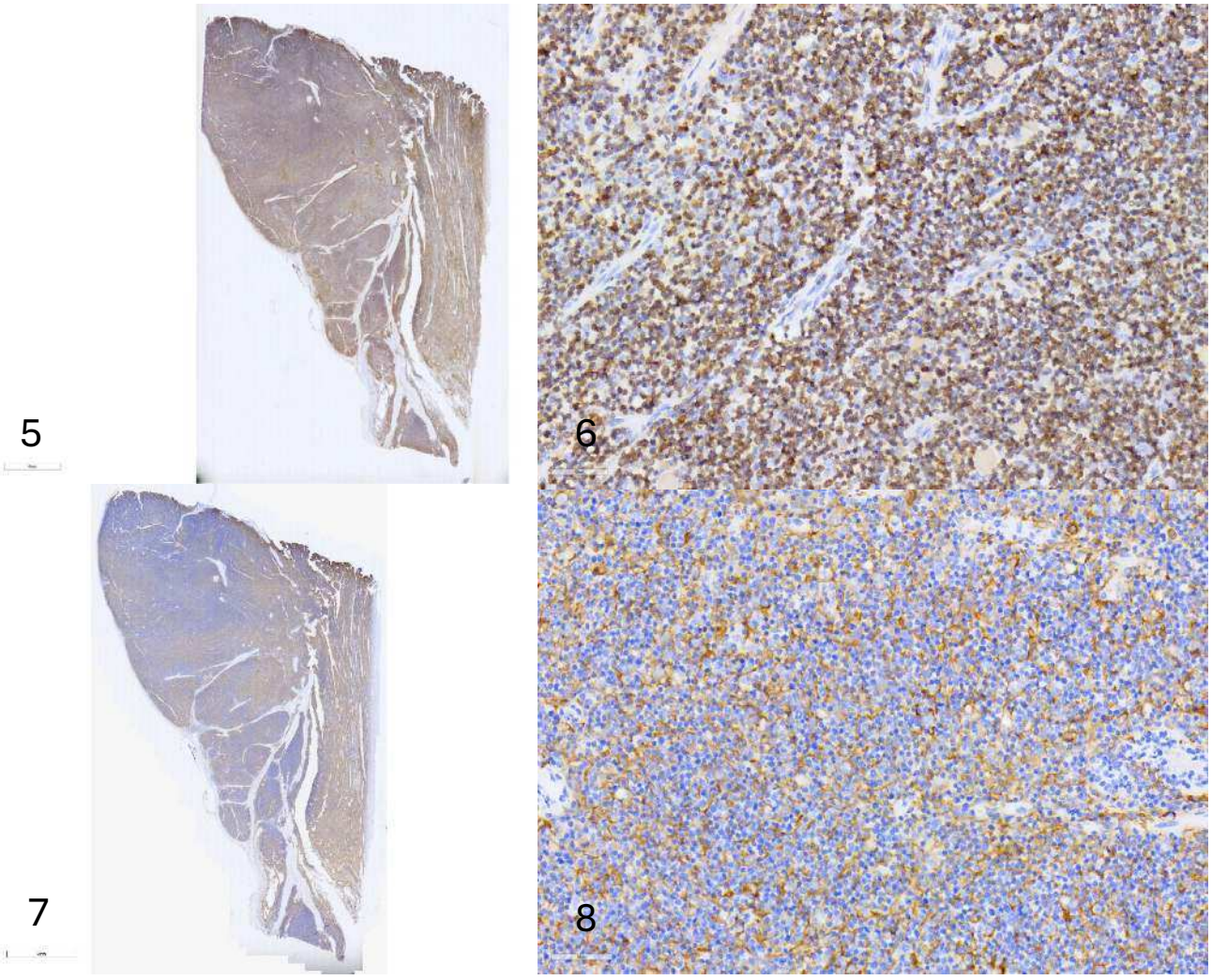

Fig, 5-8. Immunohistochemical sections of CD3 (Figs. 5 and 6; low and high magnification, respectively), and Pancytokeratin AE1/AE3 (Figs. 7 and 8; low and high magnification, respectively).

retains some lymphoid inductive capacity. The WHO classification system for thymic epithelial tumors identifies non-encapsulated or invasive thymomas and thymic carcinomas. Because invasive thymomas can only be distinguished from encapsulated thymomas when the entire neoplasm is available for histologic examination, this distinction is rarely applicable in veterinary medicine.[1,5]

Given their rarity and their generally favorable post-surgical outcome, thymic epithelial neoplasms have not been extensively studied in most animal species and are commonly only classified as thymoma or thymic carcinoma, with the latter being exceedingly rare. In dogs, cats, horses, and occasionally cattle, thymic epithelial neoplasms most commonly occur with clinical signs of respiratory and/or cardiovascular impairment, whereas they are usually seen as incidental findings in sheep and goats.[1]

Most caprine thymomas are located in the cranial mediastinum and are 3-8 cm in diameter[1], although there are previous reports of a huge tumor measuring 30cm in diameter and some involve the cervical region.[4,7] They are encapsulated, often cystic, and may have large areas of ischemic infarction.[1]

The WHO classification of thymomas is based on the 2 major histologic thymoma phenotypes that have low-grade cellular atypia. Type A thymomas are composed of spindle cells; type B thymomas are composed of epithelioid cells and are lymphocyte-rich. Admixtures of these two patterns in one mass are designated as type AB thymomas. Type B thymomas are further subdivided into type B1, B2, or B3 thymomas. The ratio of the epithelioid to lymphoid cells is the major distinguishing feature between the different type B thymomas with lymphocytes most abundant in B1 thymoma, and epithelial cells most abundant in B3 thymoma. Type AB thymomas is seen most frequently in the goat and sheep as a space-occupying lesion, as seen in this case. They tend to appear as well-formed lobules composed of a lymphocyte-poor type A component and a lymphocyte-rich type B component. In ruminants, the mediastinum is a common site for multicentric T-cell lymphoma in goats.[1]

A wide variety of autoimmune diseases have been reported in animals in association with thymomas including polymyositis, thrombocytopenia, anemia, and granulocytopenia.[9] Myasthenia gravis is an autoimmune disorder of humans, dogs, and cats, with progressive muscle weakness and reduced exercise tolerance. Specific areas of involvement include the facial and extraocular muscles with the development of megaesophagus associated with difficult swallowing, regurgitation, and aspiration pneumonia. Myasthenia gravis can be congenital or acquired. Only acquired myasthenia gravis commonly occurs in animals with thymoma; a broader range of autoimmune conditions is noted in humans with thymoma. Acquired myasthenia gravis in animals is due to autoantibodies to the acetylcholine receptor of neuromuscular junctions.[1] Paraneoplastic myasthenia gravis is thought to follow improper T-cell maturation and central tolerance in the neoplastic thymus, resulting in the release of self-reactive CD4+ and CD8+ T cells. Thymoma-associated exfoliative dermatitis, a rare paraneoplastic condition reported in goats, is also caused by self-reactive lymphocytes.[2]

Many goats with thymoma do not show any clinical symptoms, and the tumor is detected incidentally during diagnostic imaging performed for other reasons o,r more likely, during necropsy or slaughter.[3,6]

Some studies also support the opinion that thymomas in animals should be regarded as malignant tumors due to their metastatic potential.[10]

References:

1. Bienzle D, Wood RD, Keller SM. Hematopoietic system. In: *Jubb, Kennedy, and Palmer's Pathology of Domestic Animals*. Vol. 3. 7th ed. St. Louis, MO: Elsevier; 2025:170-176.
2. Byas AD, Applegate TJ, Stuart A, Byers S, Frank CB. Thymoma-associated exfoliative dermatitis in a goat: case report and brief literature review. J Vet Diagn Invest. 2019 Nov;31(6):905-908
3. Hadlow WJ. High prevalence of thymoma in the dairy goat. Report of seventeen cases. Vet Pathol 1978;15:153–169.
4. Hill JA, Fubini SL, Hackett RP. Clinical features, treatment, and outcome in goats with thymomas: 13 cases (1990-2014). *JAVMA*; 2017;251(7):829-834.
5. International Agency for Research on Cancer. Thoracic Tumours. WHO Classification of Tumours. 5th ed. IARC, 2021.
6. Löhr C V. One hundred two tumors in 100 goats. *Vet Pathol*. 2012;50(4):668-675.
7. Olchowy T, Toal R, Brenneman K, Slauson D, McEntee M. Metastatic thymoma in a goat. *Can Vet J*. 1996;37(3):165-167.
8. Parish SM, Middleton JR, Baldwin TJ. Clinical megaoesophagus in a goat with thymoma. *Vet Rec*. 1996;139:94.
9. Rostkowski CM, Stirtzinger T, Baird JD. Congestive heart failure associated with thymoma in two nubian goats. *Can Vet J*. 1985;26:267-269.
10. Szaluś-Jordanow, O., Czopowicz, M., Witkowski, L., Mickiewicz, M., Moroz, A., Kaba, J., ... & Frymus, T. (2019). Malignant thymoma–the most common neoplasm in goats. *Polish Journal of Veterinary Sciences*, 475-480.