Braz J Vet Pathol, 2026, vol. 19, e019025
DOI: https://doi.org/10.24070/bjvp.1983-0246.019025

BJVP
Brazilian Journal of Veterinary Pathology
ISSN 1983-0246

Case Report

Cervical stenotic myelopathy in a Brazilian Sport Horse foal

Talita de Oliveira[1]* , Ludimila dos Reis Lopes[1] , Amanda Mikaelly Marinho Lima Carvalho[1] , Edson Moleta Colodel[2] , Pedro Eduardo Brandini Néspoli[3] , Regina de Cassia Veronezi[1]

[1] Veterinary Hospital of the Federal University of Mato Grosso, Large Animal Clinic and Surgery, Federal University of Mato Grosso, Cuiabá, MT, Brazil
[2] Veterinary Hospital of the Federal University of Mato Grosso, Veterinary Pathology Laboratory, Federal University of Mato Grosso, Cuiabá, MT, Brazil
[3] Veterinary Hospital of the Federal University of Mato Grosso, Department of Diagnostic Imaging, Federal University of Mato Grosso, Cuiabá, MT, Brazil

*Corresponding author: Talita.oliveira1@ufmt.br
Submitted: March 24th, 2026. Accepted: June 10th, 2026.

Abstract
Cervical stenotic myelopathy (CSM) is a neurological disorder characterized by spinal cord compression in the cervical region, frequently associated with ataxia in horses. The objective of this study was to report a case of cervical stenotic myelopathy in a Brazilian Sport Horse filly evaluated at the Veterinary Hospital of the Federal University of Mato Grosso, Cuiabá campus, describing the clinical history, epidemiological factors, radiographic and tomographic findings of the cervical region, and post mortem findings. The animal presented with a history of frequent falls, incoordination and Increased volume in the femoral region of the right pelvic limb. Laboratory tests showed no significant abnormalities, and swelling in the pelvic limb was compatible with a hematoma. Cervical radiographs revealed spinal canal stenosis between C3 and C4. After death, computed tomography associated with myelography demonstrated greater compression at this level during cervical flexion, with sagittal ratio values consistent with stenosis. Morphological evaluation of the cervical vertebrae indicated articular incongruence suggestive of cervical instability, and histopathology of the spinal cord revealed degenerative changes consistent with cervical stenotic myelopathy. These results highlight the importance of combining clinical evaluation, imaging studies, and anatomopathological analysis for definitive diagnosis and emphasize the diagnostic complexity of this condition, especially in young animals with nonspecific neurological signs.

Keywords: equine, Wobbler syndrome, computed tomography.

Introduction

The "Wobbler" syndrome refers to horses that present incoordination due to developmental abnormalities or degenerative conditions affecting the cervical vertebrae and, consequently, compressing the spinal cord (20). Associated with the disease include dorsal vertebral subluxation or instability, osteoarthritis of the articular processes, and different types of vertebral fractures (14). The condition is also referred to as cervical stenotic myelopathy (CSM), cervical vertebral malformation, and cervical spondylotic myelopathy (18).

The main factors involved in the development of CSM likely include abnormalities in vertebral development, osteochondrosis of the articular processes, and nutritional alterations such as copper deficiency, excess zinc and carbohydrates in the diet (10, 12). Additional structural changes, including vertebral canal stenosis, hypertrophy of the articular processes and ligamentum flavum, physeal widening, and

synovial cyst formation, may also contribute to spinal cord compression (12, 20).

The syndrome is mainly observed in young animals with rapid growth and has been reported in horses between 6 months and 7 years of age. Although it can affect all breeds, studies indicate that approximately 1.3% to 2% of Thoroughbred horses are affected (18), and breeds such as Quarter Horse, Warmblood, and Tennessee Walking Horse are also considered predisposed. In addition to breed, a higher probability has been observed in males than in females (3).

Compressive cervical myelopathy is classified into two types. Type I, also called dynamic vertebral compression, intensifies during flexion and occurs predominantly between C1 and C6, being more common in horses younger than two years of age. Type II, or static vertebral compression, results from osseous and soft tissue compression within the vertebral canal, generally between C5 and T1 (20).

The condition manifests as symmetric ataxia, spasticity, upper motor neuron paresis, and dysmetria, usually more evident in the pelvic limbs than in the thoracic limbs (18). Clinical signs typically develop progressively and subtly, although they may appear suddenly.

Due to the nonspecific nature of neurological clinical signs in horses, a broad differential diagnosis should be considered. In the absence of a definitive diagnosis, these cases may be initially classified as Equine Neuromotor Syndrome (ENMS), encompassing infectious (viral, bacterial, fungal, and protozoal), degenerative, immune-mediated, toxic, traumatic, and neoplastic disorders affecting the central nervous system. Therefore, a comprehensive diagnostic approach is required, including a detailed neurological examination, hematological and cerebrospinal fluid analyses, serological and microbiological testing, and advanced imaging techniques when available (14, 23).

Diagnosis of cervical vertebral stenotic myelopathy is based on clinical history, identification of spinal ataxia, and imaging studies capable of demonstrating vertebral canal stenosis, including laterolateral and 50° lateroventrodorsal oblique radiography, myelography, computed tomography, magnetic resonance imaging, and cervical spinal canal endoscopy (16, 17, 23).

Treatment may be conservative or surgical. Conservative management includes anti-inflammatory drugs and dimethyl sulfoxide (DMSO) associated with management strategies such as exercise restriction and nutritional control of carbohydrates, copper, and zinc (3, 23). In more severe cases, surgical stabilization by intervertebral fusion using a perforated stainless-steel basket or threaded cylinder may be indicated (18).

The objective of this study was to report a case of cervical stenotic myelopathy in a Brazilian Sport Horse filly evaluated at the Veterinary Hospital of the Federal University of Mato Grosso, Cuiabá campus, describing the clinical history, epidemiological factors, radiographic and tomographic findings of the cervical region, and postmortem findings.

Case description

On April 3, 2025, a five-month-old Brazilian Sport Horse filly weighing 215 kg was admitted to the Veterinary Hospital of the Federal University of Mato Grosso with a history of right pelvic limb injury and locomotor difficulty with spontaneous falls.

According to the veterinarian responsible for the property, the filly began to present swelling in the femoral region of the right pelvic limb three weeks earlier, accompanied by locomotor difficulty and frequent falls, especially when running in the paddock or climbing steps. After aspiration of the swelling using an 18 G hypodermic needle (40 × 12 mm) and identification of sanguineous content, a lance procedure was performed to drain the hematoma, followed by internal lavage of the cavity with saline solution and topical povidone-iodine (PVPI). Daily cleaning resulted in significant reduction of the hematoma; however, recurrence occurred, and a second procedure similar to the previous one was performed. During this period, due to suspected associated neurological injury, systemic intravenous therapy with dexamethasone and dimethyl sulfoxide (DMSO) was administered for four days, and systemic intramuscular antibiotic therapy was instituted for seven days with Pencivet® Plus PPU (procaine benzylpenicillin 10,000,000 IU/100 mL, benzathine benzylpenicillin 10,000,000 IU/100 mL, dihydrostreptomycin sulfate 10,500 mg/100 mL, and piroxicam 1,000 mg/100 mL). Due to new recurrence, worsening of the hematoma, and persistence of locomotor difficulty, the animal was referred to Veterinary Hospital of the Federal University of Mato Grosso. The filly had been routinely dewormed and was maintained primarily on maternal milk, although she had already shown interest in hay, alfalfa, and concentrate feed. No history of training activities was reported by the owner. This was an isolated case, and no similar neurological disorders had been observed in other horses on the property. Detailed information regarding dietary calcium-to-phosphorus ratio and nutrient composition was not available.

At admission, the animal presented grade IV lameness according to the American Association of Equine Practitioners (AAEP) scale (1), with extensive swelling in the femoral region of the right pelvic limb and marked incoordination of the pelvic limbs, classified as grade IV (2). Abrasions were also observed in the fetlock, carpus, and shoulder regions of the left thoracic limb and in the calcaneal region of the right pelvic limb. Heart rate was 36 bpm, respiratory rate 24 breaths per minute, rectal temperature 38.7 °C, capillary refill time 2 seconds, mucous membranes pink and hydrated, normal intestinal motility, and body condition score 4 according to (8). Laboratory tests were immediately performed, including complete blood count, leukogram, total protein, fibrinogen, and serum concentrations of urea, creatinine, total, direct and indirect bilirubin, aspartate aminotransferase (AST), gamma-glutamyl transferase (GGT), and creatine kinase (CK), which showed no relevant abnormalities.

The swelling in the right pelvic limb extended along the lateral, medioventral, and caudal aspects of the femoral region (Fig. 1A), presenting a fluctuating consistency, mild increase in local temperature, and increased sensitivity to palpation. After restraint and asepsis, aspiration was performed with a 16 G needle (40 × 16 mm) at the most fluctuating point, resulting in drainage of serosanguineous fluid. Considering the animal's discomfort and severe lameness of the right pelvic limb, which hindered neurological evaluation, it was decided to initially perform a lance procedure and drain the entire content. The animal was sedated with a reduced dose of detomidine hydrochloride (0.005 µg/kg, IV) in an attempt to maintain quadrupedal position; however, it assumed left lateral recumbency. After new asepsis, a 3 cm skin incision was made with a scalpel at the same puncture site, resulting in intense drainage of serosanguineous content with the presence of fibrin, clots, and necrotic tissue (Fig. 1B).

Samples were collected for cavitary fluid analysis, cytology, culture, and antimicrobial susceptibility testing. Results indicated predominance of erythrocytes associated with slightly eosinophilic amorphous material, in addition to clusters of neutrophils, with a lower proportion of monocytes and lymphocytes. Cytocentrifugation demonstrated that approximately 50% of cellularity consisted of neutrophils, while the remainder corresponded predominantly to erythrocytes. No bacteria or mononuclear cells were identified, and the findings were compatible with a hematoma. Bacterial culture revealed growth of *Staphylococcus* sp., showing partial sensitivity to sulfadoxine.

After complete drainage, the entire internal cavity, subcutaneous tissue, and musculature were cleaned using a sequence of hydrogen peroxide (until the entire space was filled), 1 L of lactated Ringer's solution, 2 L of 1% povidone-iodine (PVPI) in saline solution, and finally 1 L of lactated Ringer's solution containing 2.5% gentamicin. After instillation of each product, an average of three minutes was allowed before removing the content through manual massage. The gentamicin-containing solution was left in place, with spontaneous drainage through the incision until the next dressing, performed at 24-hour intervals.

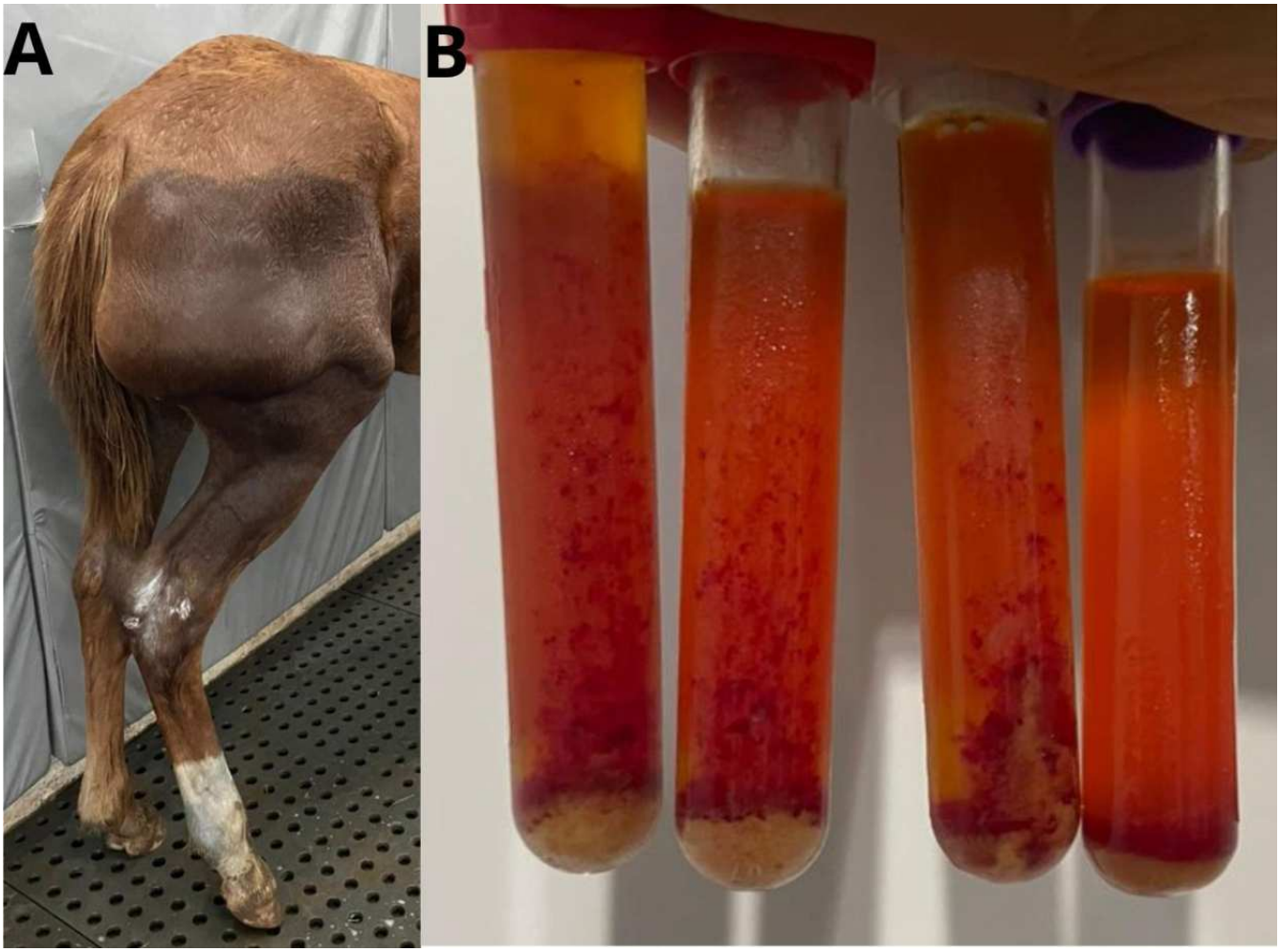

Figure 1. A- Swelling in the femoral region and antalgic posture of the right pelvic limb. B- Appearance of the drained content from the femoral region.

Sodium rifamycin spray (10 mg/mL) was applied over the incision, followed by a healing and repellent ointment (Unguento®). Systemically, flunixin meglumine (1.1 mg/kg, IV) and Fortgal Plus® (sulfadoxine 20 g, trimethoprim 4 g, and piroxicam 1.2 g) were administered at a dose of 30 mg/kg, IV. These medications, together with omeprazole (20 mg/kg, PO), were prescribed to be administered every 24 hours for five days. After recovery from sedation, the filly was kept in a small paddock.

On April 5, considering the locomotion pattern and motor incoordination, associated with the filly's age, size, and history, radiographic examination of the cervical region was requested due to suspicion of compressive spinal cord injury. At this time, asymmetry of the neck in the cranial cervical region was observed in the dorsal view. It is noteworthy that a complete neurological examination was not performed due to the severity of motor incoordination (grade IV) and lameness of the right pelvic limb. Cervical radiographs were obtained with the patient standing and without sedation, due to the risk of falling, and were subjectively evaluated, revealing narrowing of the spinal canal between vertebrae C3 and C4 (. 2A and 2B). In fig. 2A, the arrow indicates projection of vertebra C4 over the spinal canal. In fig. 2B, the spinal canal is highlighted in yellow, and the narrowing region is indicated by sagittal lines in yellow, red, and green, while black sagittal lines indicate normal diameter. Based on this finding, the animal was transferred to a stall to restrict movement and access to the feed offered to the dam.

During the early morning of April 8, the animal was found in the stall in right lateral recumbency, with cyanotic mucous membranes and cardiorespiratory arrest. Cardiopulmonary resuscitation maneuvers were performed, but were unsuccessful. After death, computed tomography of the cervical region was performed to assess and confirm spinal cord compression, followed by necropsy examination.

Computed tomography myelography was performed using a SOMATOM Spirit multidetector computed tomography scanner (Siemens Healthineers, Erlangen, Germany), with images acquired only in neutral laterolateral and flexed cervical positions due to rigor mortis. In this evaluation, cervical stenosis was observed, indicated by failure of filling of the dorsal and ventral contrast columns over the C3–C4 articulation (Fig. 3, black arrow), consistent with compressive cervical myelopathy. Similar computed tomographic myelographic features have been reported in horses with cervical vertebral compressive myelopathy, in which narrowing of the vertebral canal and distortion or reduction of the subarachnoid contrast columns are considered indicative of spinal cord compression (5,11).

Using the tomographic image shown in fig. 4, the minimum sagittal diameter of the vertebral canal was measured as 2D6 and 2D8, and the maximum cranial diameter of the vertebral body was identified as 2D5 and 2D7. These measurements were used to assist in quantitative diagnosis through the ratio between the two values, as described (20). The values obtained were 0.39 for the C4 vertebral body, at which point narrowing of the spinal canal was observed, and 0.52 for the C5 vertebral body, in which no canal narrowing was observed.

At necropsy (15), an organized hematoma was observed in the femoral region of the right pelvic limb, associated with moderate focal suppurative fasciitis, neovascularization, and fibroplasia. The cervical vertebrae were subjected to maceration for morphological evaluation, and structural changes compatible with articular incongruence between the vertebrae were observed, suggesting cervical instability (Fig. 5A).

Spinal cord samples were collected, fixed in 10% formaline, and processed by conventional histological processing methods, and stained using the following colors:

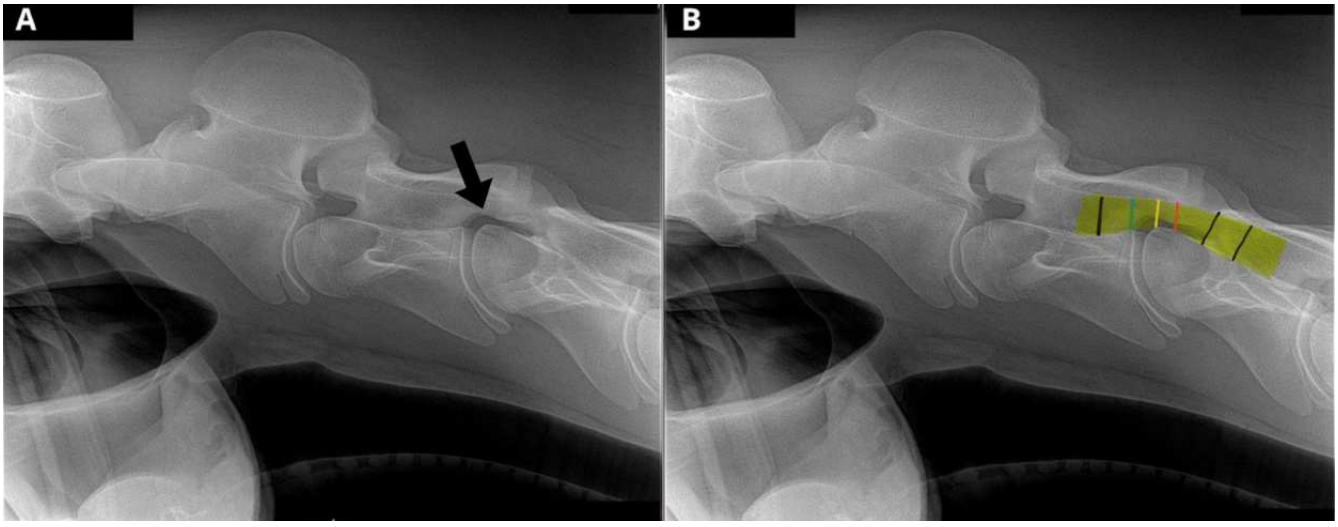

Figure 2. A- Laterolateral cervical radiograph, with an arrow indicating the projection of vertebra C4 over the spinal canal. B- Spinal canal highlighted in yellow, with sagittal lines in yellow, red, and green indicating the stenosis site.

Hematoxylin & Eosin (H&E) (15). In the spinal cord, moderate spongiosis was observed in the lateral and ventral funiculi, more evident in the border areas adjacent to the spinal cord "H" and near the ventromedian fissure (Fig. 5B). In these regions, the histopathological study showed approximately 25% of axons exhibited myelin sheaths dilated two to ten times above normal, and hyaline, eosinophilic, and swollen axons (spheroids) were identified, along with enlarged astrocytes with eosinophilic cytoplasm. In the gray matter horns, swollen and eosinophilic neurons were noted (Fig. 5C). These findings histopathological were consistent with spongiotic and degenerative myelopathy.

Discussion

The clinical history, epidemiological factors, radiographic and tomographic findings of the cervical region, as well as the macroscopic and microscopic pathological findings observed in this case, were complementary and allowed the diagnosis of cervical stenotic myelopathy. Imaging studies demonstrated vertebral canal stenosis with consequent spinal cord compression between vertebrae C3 and C4. Similar vertebral lesions have been described in horses with cervical vertebral stenotic myelopathy, affecting both articular cartilage and subchondral/trabecular bone and including developmental and degenerative changes that contribute to vertebral instability and spinal cord compression (9).

Vertebral canal stenosis was evident on plain radiography, although this method has relatively low sensitivity, estimated at 42%, whereas radiographic myelography may reach 68% when compared with necropsy findings (5).

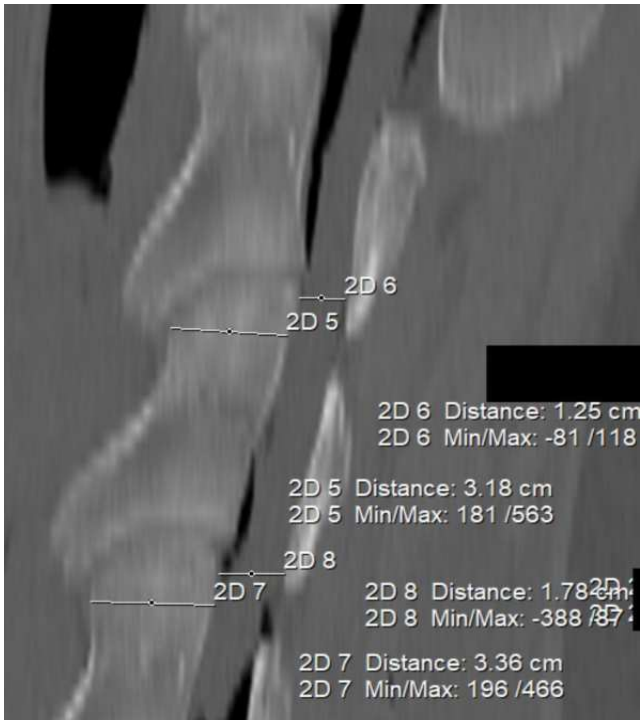

Figure 4. Measurement of the sagittal diameter of the vertebral bodies of C4 and C5 and the spinal canal by computed tomography.

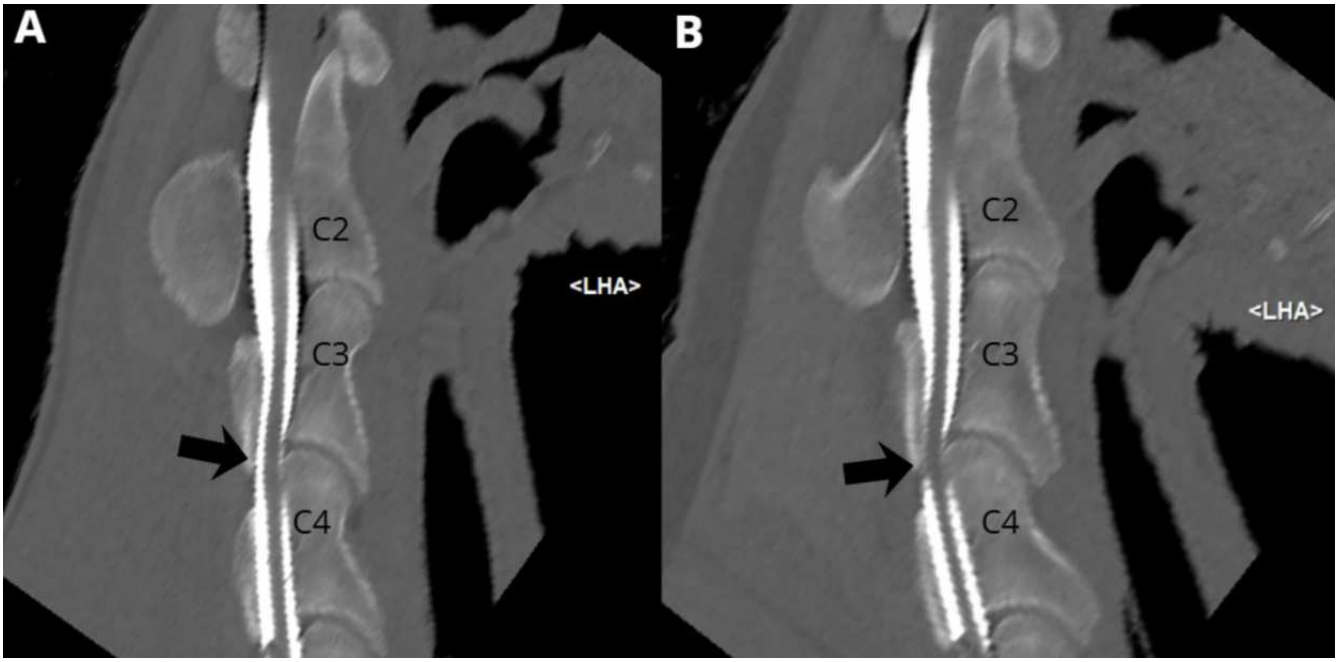

Figure 3. A- Cervical lateral computed tomography myelography in neutral position indicating the site of spinal canal stenosis between vertebrae C3 and C4 (arrow). B- Cervical lateral computed tomography myelography in flexion indicating the site of spinal canal stenosis between vertebrae C3 and C4 (arrow).

For greater diagnostic accuracy, the ratio between the minimum sagittal diameter of the vertebral canal and the cranial height of the vertebral body can be calculated (23). This calculation was performed using computed tomography images. The values obtained were 0.39 for the C4 vertebral body, where narrowing of the spinal canal was observed on subjective evaluation, and 0.52 for the C5 vertebral body, in which no evident narrowing was identified subjectively.

Considering reference values described in the literature, ratios lower than 0.52 between C4 and C6 and lower than 0.56 at C7 are considered predictive of spinal cord compression, with sensitivity and specificity of approximately 89% for diagnosis (4, 23). In this context, the value observed at C4 is compatible with spinal cord compression, whereas the value obtained at C5 lies at the threshold described for these vertebral segments. Regarding the cutoff at C7, also reported values lower than 0.52 and value lower than 0.54 (20, 23).

On the tomographic image with the head in flexion, greater narrowing of the spinal canal was observed, evidenced by discontinuity of the contrast column between vertebrae C3 and C4. This finding is consistent with type I compressive cervical myelopathy, a condition more common in young animals and that may be exacerbated during cervical flexion (23), factors that were also observed in the clinical history and dynamic examination of the animal.

In a study (6), a higher number of animals with dynamic cervical stenotic myelopathy presented spinal cord compression between C3 and C4. Similar results were reported (4), who observed a higher frequency of compression at this same site. However, these authors (4, 6) also highlighted the difficulty of confirming diagnosis based exclusively on imaging studies, since in some cases definitive diagnosis was established only through necropsy. These findings reinforce the importance of evaluating the cervical spine in different positions, considering that certain spinal cord compressions may be evident only with the head in flexion or, in more challenging situations, exclusively at postmortem examination, highlighting the diagnostic complexity of this condition.

A study performed in non-affected animals demonstrated that cervical flexion may reduce the subarachnoid space and alter the relationship between the spinal cord and the dural tube in specific segments (6). This finding reinforces

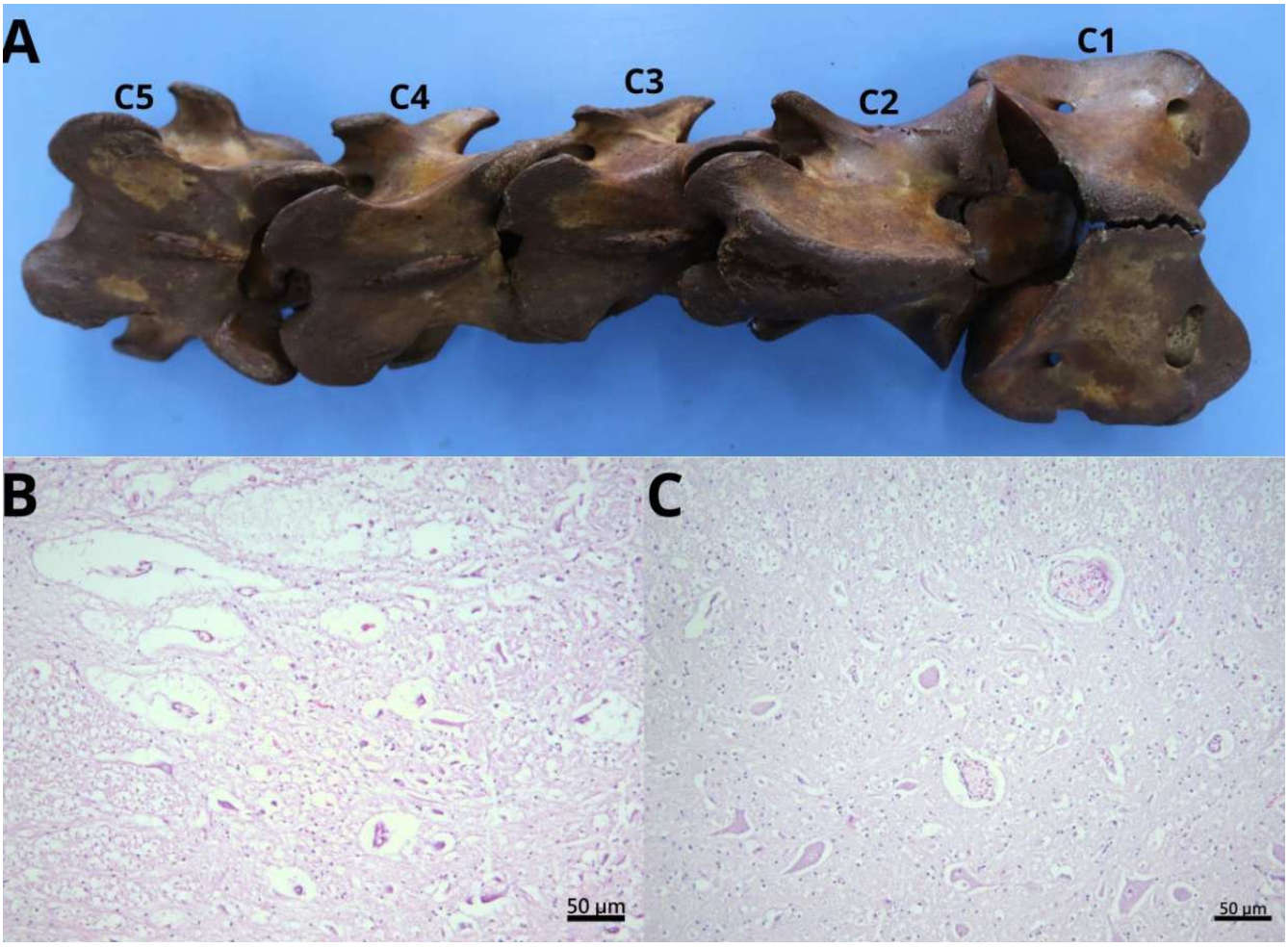

Figure 5. A- Cervical vertebrae after maceration, from C1 to C5. B- Spinal cord histopathology showing spongiosis (10X, H&E). C- Spinal cord histopathology showing hyaline, swollen, and eosinophilic axons (10X, H&E).

the need for careful interpretation of these changes and correlation with clinical signs.

The absence of significant alterations in hematological and serum biochemical tests is consistent with descriptions for compressive cervical myelopathy, a condition in which routine laboratory tests generally do not show specific abnormalities (3, 7). This finding reinforces the limitation of these tests as diagnostic tools for compressive spinal cord disorders, highlighting the importance of neurological evaluation and imaging methods.

Results of the analysis of the drained femoral content were consistent with necropsy findings, which revealed organized hematoma, edema, and muscle necrosis, alterations described in more severe traumatic injuries (13). In the present case, these findings were likely secondary to frequent falls associated with the neurological condition. Traumatic lesions, distal abrasions, and history of falls are described as indirect manifestations of neurological disorders and may precede recognition of ataxia, complicating diagnosis in acute cases (2, 23). Thus, the presence of multiple abrasions and hematoma reinforces that neurological dysfunction preceded the traumatic episodes and was the primary cause of the observed lesions.

Isolation of *Staphylococcus* sp. from the drained material should be interpreted with caution, since this microorganism is commonly present in the cutaneous microbiota and mucosa of the respiratory tract (19). Considering that the swelling had previously been drained, environmental or secondary contamination is more plausible than primary infection, especially given the absence of systemic alterations compatible with an active infectious process.

Due to the nonspecific nature of the clinical signs observed, consideration of a wide range of differential diagnoses is essential. Initially, equine herpesvirus type 1 infection (EHV-1), equine protozoal myeloencephalitis (EPM), babesiosis, Wobbler syndrome (cervical stenotic myelopathy), and traumatic lesions were considered (23). Other relevant differential diagnoses include equine degenerative myeloencephalopathy, equine motor neuron disease, hepatic encephalopathy, brain abscesses, neoplasia, rabies, and other viral encephalitides. Additionally, structural abnormalities of the cervical vertebral column, including osteoarthritis of the caudal articular process joints, hypertrophy of the ligamentum flavum, intervertebral disc protrusion, and extradural masses, should be considered during clinical examination and diagnostic investigation (7).

The etiology of cervical stenotic myelopathy is considered multifactorial, involving genetic predisposition, rapid growth, biomechanical factors, and nutritional influences. Although mineral analyses of the soil, pasture, and animal tissues were not performed in the present case, nutritional factors cannot be completely excluded (10, 13). The municipality of Nova Mutum is located within the Brazilian Cerrado region, where highly weathered soils frequently exhibit low availability of micronutrients, particularly zinc and, under certain conditions, copper. Previous studies conducted in Mato Grosso and other Cerrado areas have demonstrated reduced concentrations of these trace elements in soils and pastures, potentially affecting mineral intake by grazing animals. Because copper and zinc play important roles in skeletal growth and cartilage metabolism, imbalances in trace mineral nutrition may contribute to developmental orthopedic alterations that have been associated with cervical vertebral stenotic myelopathy (21, 22). However, this hypothesis could not be confirmed in the present case due to the lack of mineral analyses.

Maceration of the cervical vertebrae for morphological evaluation allowed identification of structural changes compatible with articular incongruence suggestive of vertebral instability. Such alterations have been described in horses with cervical stenotic myelopathy and may be associated with biomechanical changes of the cervical spine, contributing to the development of spinal cord compression (7, 23). Additionally, (9) described a higher frequency of lesions throughout the cervical spine in horses with CSM, not only at the compression site. In the present case, these findings reinforce the relationship between structural changes of the cervical spine, and the compression point previously identified on imaging.

Microscopic evaluation of the spinal cord also revealed degenerative changes compatible with compressive cervical myelopathy, including dilation of myelin sheaths, swollen axons, neuronal degeneration, and glial alterations, similar to those described (9). In conclusion, we describe a case of Cervical Stenotic Myelopathy in a Brazilian Sport Horse Foal in Matto Grosso, Brazil, through a multidisciplinary study: clinical history, epidemiological factors, radiographic and tomographic findings of the cervical region, and postmortem findings. The distribution of these lesions at sites corresponding to stenosis identified on imaging reinforces the importance of correlating clinical, radiological, and anatomopathological findings for accurate diagnosis of cervical stenotic myelopathy, further highlighting the diagnostic complexity of this condition, especially in young animals with nonspecific neurological signs.

Data Availability

All the original contributions presented in this study are included in the article/supplementary material. Further inquiries can be directed to the corresponding author.

Author Contributions

Fernanda Menezes de Oliveira e Silva: Investigation, Data curation, Formal analysis, Writing – review and editing. **João Ricardo Sales Rocha Filgueiras**: Conceptualization, Methodology, Formal analysis, Writing – original draft

preparation. **Vitor Luz Carvalho**: Investigation, Formal analysis, Supervision, Writing – review and editing. All authors have read and approved the final version of the manuscript.

Conflict of Interest

The authors declare no competing interests.

Generative AI Use Statement

The authors used generative artificial intelligence (ChatGPT, OpenAI) solely for language editing and manuscript revision assistance. All scientific content, interpretations, and conclusions were developed and verified by the authors, who assume full responsibility for the final manuscript.

References

1. American Association of Equine Practitioners (AAEP). Lameness exams: evaluating the lame horse. Lexington (KY): AAEP; 2024. Available from: https://aaep.org/horsehealth/lameness-exams-evaluating-lame-horse. Accessed Jun 8, 2026.
2. Borges AS, Mendes LCN, Kuchembuck MRG. Exame neurológico em grandes animais. Parte II – Medula espinhal: equino com incoordenação motora. Rev Educ Contin Med Vet Zootecnia CRMV-SP. 2000;3(2):3-15. doi: 10.36440/recmvz.v3i2.3334.
3. Furr M, Reed S, editors. Equine neurology. 2nd ed. Hoboken: Wiley-Blackwell; 2015.
4. González-Medina S, et al. Cone beam computed tomographic myelography in horses with cervical vertebral compressive myelopathy. Equine Vet J. 2025:1-10. doi: 10.1111/evj.70094.
5. Gough SL, Anderson JDC, Dixon JJ. Computed tomographic cervical myelography in horses: technique and findings in 51 clinical cases. J Vet Intern Med. 2020;34(5):2142-2151. doi: 10.1111/jvim.15848.
6. Hellige M, et al. Computed tomographic myelography of the cranial cervical vertebral column in unaffected Warmblood horses: comparison of transverse vertebral ratios in the flexed and neutral cranial cervical vertebral column. J Equine Vet Sci. 2026;156:105735. doi: 10.1016/j.jevs.2025.105735.
7. Hellige M, Warnken T, Puff C, Feige K. CT myelographic diagnosis of ligamentum flavum hypertrophy in a Warmblood gelding with progressive ataxia. Vet Radiol Ultrasound. 2021;62(4):e44-e47. doi: 10.1111/vru.12971.
8. Henneke DR, et al. Relationship between condition score, physical measurements and body fat percentage in mares. Equine Vet J. 1983;15(4):371-372. doi: 10.1111/j.2042-3306.1983.tb01826.x.
9. Janes JG, et al. Cervical vertebral lesions in equine stenotic myelopathy. Vet Pathol. 2015;52(5):919-927. doi: 10.1177/0300985815593127.
10. Levine JM, et al. Associations of sex, breed, and age with cervical vertebral compressive myelopathy in horses: 811 cases (1974–2007). J Am Vet Med Assoc. 2008;233(9):1453-1458. doi: 10.2460/javma.233.9.1453.
11. Lindgren CM, Wright L, Kristoffersen M, Puchalski SM. Computed tomography and myelography of the equine cervical spine: 180 cases (2013–2018). Equine Vet Educ. 2021;33(9):475-483. doi: 10.1111/eve.13350.
12. Maxie MG, editor. Jubb, Kennedy and Palmer's pathology of domestic animals. 5th ed. London: W.B. Saunders; 2007.
13. McGowan C. Traumatic muscle injuries. Vet Clin North Am Equine Pract. 2025;41(1):181-192. doi: 10.1016/j.cveq.2024.11.009.
14. Morales BA, Méndez SA, Pérez AJ. La región del cuello del caballo. Connotaciones anatomo-aplicativas: una revisión. Int J Morphol. 2014;32(4):1212-1221. doi: 10.4067/S0717-95022014000400015.
15. Morales-Briceño A. The equine necropsy: an update. EC Vet Sci. 2020;5(11):49-60.
16. Pezzanite L, Easley J. Update on surgical treatment of wobblers. Vet Clin North Am Equine Pract. 2019;35(2):299-309. doi: 10.1016/j.cveq.2019.04.002.
17. Prange T, Derksen FJ, Stick JA, Garcia-Pereira FL, Carr EA. Cervical vertebral canal endoscopy in the horse: intra- and post operative observations. Equine Vet J. 2011;43(4):404-411. doi: 10.1111/j.2042-3306.2010.00310.x.
18. Reed SM, Bayly WM, Sellon DC. Equine internal medicine. 4th ed. St. Louis: Saunders; 2017.
19. Rycroft AN. Fundamentals of veterinary microbiology. Hoboken: Wiley-Blackwell; 2023.
20. Smith BP, Van Metre DC, Pusterla N, editors. Large animal internal medicine. 6th ed. St. Louis: Mosby; 2019.
21. Sousa JC, Conrad JH, Mott GO, McDowell LR, Ammerman CB, Blue WG. Interrelationships among mineral levels in soil, forage and animal tissues on ranches in northern Mato Grosso. IV. Zinc, magnesium, sodium and potassium. Pesq Agropec Bras. 1982;17(1):11-20. doi: 10.1590/S1678-3921.pab1982.v17.15507.
22. Vendrame PRS, Brito OR, Quantin C, Becquer T. Availability of copper, iron, manganese and zinc in soils under pastures in the Brazilian Cerrado. Pesq Agropec Bras. 2007;42(6):859-864. doi: 10.1590/S1678-3921.pab2007.v42.7639.
23. Woodie B, Johnson AL, Grant B. Cervical vertebral stenotic myelopathy. Vet Clin North Am Equine Pract. 2022;38(2):225-248. doi: 10.1016/j.cveq.2022.05.002.
24. Yamada K, Sato F, Hada T, Horiuchi N, Ikeda H, Nishihara K, Sasaki N, Kobayashi Y, Nambo Y. Quantitative evaluation of cervical cord compression by computed tomographic myelography in Thoroughbred foals. J Equine Sci. 2016;27(4):143-148. doi: 10.1294/jes.27.143.