Braz J Vet Pathol, 2026, vol. 19, e019013
DOI: https://doi.org/10.24070/bjvp.1983-0246.019013

BJVP
Brazilian Journal of Veterinary Pathology
ISSN 1983-0246

Case Report

Follicular thyroid carcinoma in a domestic pigeon (*Columba livia*)

Ana Cecilia Guevara-Mata[1], Nestor Ledesma-Martínez[2], Félix Domingo Sánchez-Godoy[2], Elizabeth Morales-Salinas[1*]

[1]Departamento de Patología, Facultad de Medicina Veterinaria y Zootecnia, Universidad Nacional Autónoma de México, Mexico
[2]Departamento de Medicina y Zootecnia de Aves, Facultad de Medicina Veterinaria y Zootecnia, Universidad Nacional Autónoma de México, Mexico

[*]**Corresponding author:** moraless@unam.mx
Submitted: March 24th, 2024. Accepted: April 14th, 2026.

Abstract

A 10-year-old female domestic pigeon (*Columba livia*), presented with marked depression, hyporexia, and scant green droppings for approximately two weeks, according to the owners. On general physical examination, a nodule was detected in the subcutaneous tissue at the level of the crop. Due to the bird´s poor prognosis, euthanasia was performed. At necropsy, an oval mass was found in the subcutaneous tissue of the ventral region of the distal third of the neck, located above the crop and adjacent to the trachea. The mass measured 3.5 x 2.2 x 1.5 cm, was light brown, had a slightly irregular and firm consistency, and on cut section showed small cavitations. The tissue was submitted to the Departamento de Patología, Facultad de Medicina Veterinaria y Zootecnia, UNAM, for histological evaluation, where it was diagnosed as follicular thyroid carcinoma. In birds, thyroid neoplasms have been reported as incidental findings, and their prognosis is usually poor. Antemortem diagnosis is difficult because birds often exhibit nonspecific clinical signs; therefore, in most cases, the definitive diagnosis is made *postmortem*. Although papillary thyroid adenomas have previously been reported in pigeons, the aim of the present study is to report the first case of follicular thyroid carcinoma in a domestic pigeon.

Keywords: neoplasia, carcinoma, thyroid, pigeon

Introduction

Primary neoplasms of the thyroid gland have been reported as incidental findings in different avian species. Thyroid adenomas and carcinomas derived from follicular cells (thyrocytes) have been reported in pigeons (*Columba livia*) (28), budgerigars (*Melopsittacus undulatus*) (4, 14, 21), African grey parrots (*Psittacus erithacus*), yellow-crowned amazons (*Amazona ochrocephala*), blue-fronted amazons (*Amazona aestiva*) (5, 10), common and green pheasants (*Phasianus versicolor, Phasianus colchicus*) (13, 17), a scarlet macaw (*Ara macao*) (27), an Andean goose (*Chloephaga melanoptera*) (12), a carrion crow (*Corvus corone*) (30), a bald eagle (*Haliaeetus leucocephalus*) (3), a saker falcon (*Falco cherrug*) (23), a wild barred owl (*Strix varia*) (6), and psittacine birds of the family Cacatuidae (20, 29).

These neoplasms cause enlargement of the thyroid gland, which may result in respiratory disturbances, regurgitation, or changes in vocalization in some birds due to compression of the trachea and esophagus, although clinical signs may be nonspecific or absent before death. (10, 18). In birds, adenomas have been described as soft, smooth, red to violaceous nodules, whereas carcinomas are commonly multinodular, firm, white or gray, and poorly demarcated (20, 29). Although a higher incidence of thyroid neoplasia has been observed, psittacine birds such as budgerigars and cockatoos (20, 29), there is limited information in birds regarding predisposing factors according to taxonomy, age, sex, or environmental factors involved, possibly due to the

diversity of avian species and the low number of reported cases (10).

Because the available literature on malignant thyroid tumors in birds is limited, the aim of the present study is to report the first case of follicular thyroid carcinoma in a domestic pigeon.

Case description

A 10-year-old female domestic pigeon (*Columba livia*), that lived with its owners and was fed a mixed diet based on cereals, legumes, and oilseeds, with water provided *ad libitum*, was presented for veterinary consultation due to weakness, lethargy, hyporexia, and scant green droppings for approximately two weeks. On physical examination, poor body condition (1/5) and a movable subcutaneous nodule on the ventral aspect of the neck were noted. Due to the patient´s poor condition, the owners elected euthanasia, followed by necropsy.

Macroscopic evaluation

During necropsy, an oval mass was found within the subcutaneous tissue of the ventral region of the distal third of the neck, above the crop and adjacent to the trachea. It measured 3.5 x 2.2 x 1.5 cm, was yellowish-white had a slightly irregular surface and firm consistency, extended to the thoracic inlet, completely replaced the thyroid gland bilaterally, and compressed the trachea and esophagus (Fig. 1). On cut section, it showed small cavitations delineated by solid yellowish-white tissue and areas of hemorrhage (Fig. 2). This was the only finding reported at necropsy. The mass was fixed in 10% buffered formalin for 14 days and submitted to the Department of Pathology, Faculty of Veterinary Medicine and Animal Science, National Autonomous University of Mexico, for routine histologic processing. Sections 4µm thick were prepared, stained with hematoxylin and eosin (H&E), and examined microscopically.

Histopathological evaluation

Histologic examination revealed a neoplasm partially encapsulated by fibrous connective tissue that completely replaced the normal thyroid tissue. The neoplasm was composed predominantly of cells forming follicles of variable size, with occasional papillae, embedded in a delicate fibrous stroma (Fig. 3). The cells lining the follicular structures were cuboidal to columnar, with a moderate amount of pale eosinophilic cytoplasm and pleomorphic, round to oval, basophilic nuclei containing finely granular chromatin; some nuclei were hyperchromatic and had prominent nucleoli. Mitoses were infrequent (0-1 per high-power field) (Fig. 4). Some follicles contained scant amorphous eosinophilic material (colloid) within the lumen (Fig. 5). In addition, there were small foci of necrosis and hemorrhage, with aggregates of heterophils and the presence of neoplastic cells in some areas of the capsule. The histologic diagnosis was follicular thyroid carcinoma.

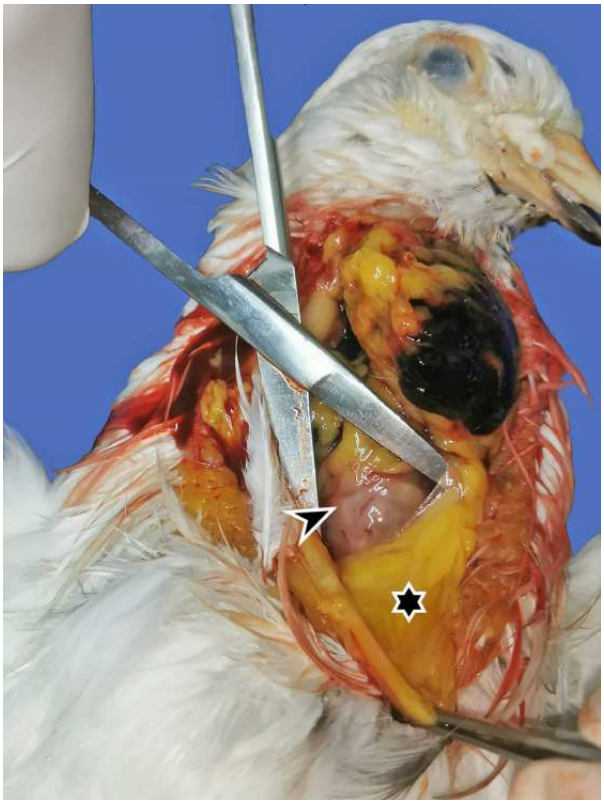

Figure 1. Thyroid carcinoma in the pigeon located at the base of the neck in the ventral position, above the crop and adjacent to the trachea (arrow) and surrounding adipose tissue (asterisk).



Figure 2. Transverse sections of the thyroid carcinoma showing small cavitations delineated by solid yellowish-white tissue and areas of hemorrhage.

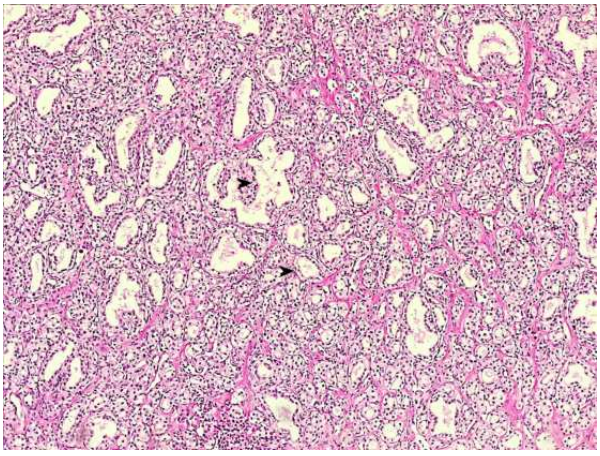

Figure 3. Neoplastic tissue composed of follicles of different shapes and sizes (arrows), embedded in a delicate fibrous stroma (follicular pattern). H&E, 100x

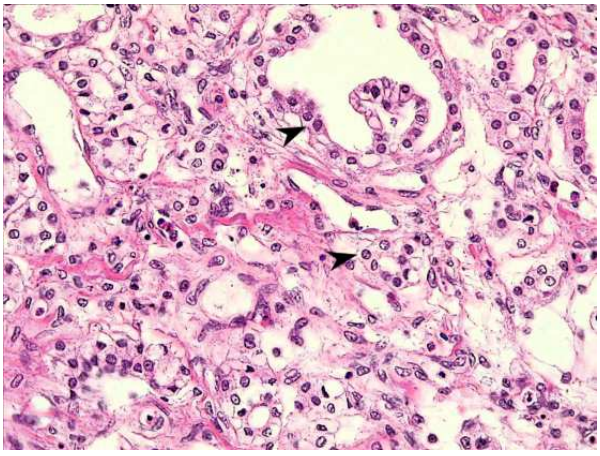

Figure 4. The cells lining the follicles are cuboidal, with pale eosinophilic cytoplasm and pleomorphic round to oval basophilic nuclei with finely granular chromatin, some hyperchromatic and with prominent nucleoli (arrows). H&E, 400x

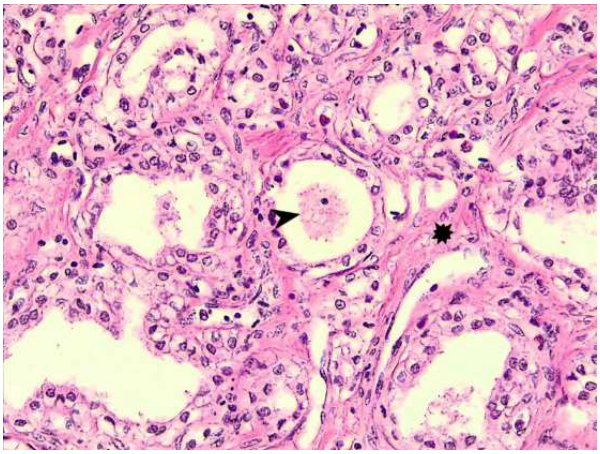

Figure 5. Some follicles contain scant amorphous eosinophilic material (colloid) (arrow) and are embedded in a delicate fibrous stroma (asterisk). H&E, 400x.

Immunohistochemistry

Histologic sections of the neoplastic tissue were analyzed by immunohistochemistry (IHC). For heat- induced epitope retrieval (HIER), Diva Decloaker 20X was used in a pressure cooker (Decloaking Chamber) for 10 minutes (Biocare Medical, CA, USA). The available antibodies used were pancytokeratin (AE1/AE3) (mouse monoclonal, Biocare Medical, CA, USA.; dilution 1:100) and thyroglobulin (mouse monoclonal, clone 2H11/6E1, Bio SE, CA, USA; ready to use [RTU]). As negative controls, the primary antibodies were excluded for the reaction; for positive controls, sections of chicken intestine (pancytokeratin) and equine thyroid (thyroglobulin) were used. For detection and visualization, peroxidase-conjugated secondary antibodies and diamino-benzidine were used (Reveal Detection System Polyvalent HRP DAB, Spring Bioscience, CA, USA). The analyzed sections of the neoplastic tissue showed no immunoreactivity for either marker.

Discussion

Thyroid tumors have been reported more frequently in companion birds, particularly in budgerigars and cockatoos, with adenomas being the most common type (14, 20, 29). However, in domestic, companion, and ornamental birds, there are fewer reports than in dogs, cats, and horses (2, 7, 11, 22, 25, 31). Most thyroid tumors are malignant in dogs (8, 22, 31) and benign in cats and horses (1, 7, 15, 22). The low frequency of thyroid tumors reported in birds may be due to lower species predisposition or underdiagnosis, either because clinical signs may be nonspecific of go unnoticed, or because birds die suddenly and a *postmortem* examination is not requested; therefore, such cases are not recorded (10, 13).

In both mammals and birds, the main differential diagnoses for follicular cell thyroid carcinomas that should be considered are adenoma and hyperplasia or goiter (16). In this regard, in a retrospective study, bilateral papillary adenomas were diagnosed in the thyroid lobes of 5 out of 83 (6%) pigeons (28). In dogs, thyroid adenomas are usually bilateral, whereas in birds, they are usually unilateral, with well-defined fibrous capsules, and are smaller than adenocarcinomas, which, when large, distort the affected glands and may be more easily palpated on clinical examination than adenomas. The cells composing thyroid adenomas are well differentiated and resemble normal cells (16, 22). Based on the histologic growth patterns, thyroid adenomas in birds have been classified as follicular, papillary, and cystic (20, 29).

Thyroid carcinomas in dogs are usually unilateral, although they may also be bilateral, and in birds, they may affect one or both thyroid lobes (16, 22). As in the present case, they may be partially encapsulated or encapsulated, and the neoplastic cells often invade the capsule. They may also invade blood vessels, adjacent tissues, or give rise to

metastases, none of which were detected in the present case. Histologically, they are more cellular and show a greater degree of pleomorphism and atypia than adenomas, as well as areas of necrosis and hemorrhage near the central regions (22). According to the predominant histologic growth pattern used in mammals, carcinomas derived from thyroid follicles are classified into follicular, papillary, compact cell (solid), cystic, or mixed subtypes, a classification that has also been used in birds (22). The follicular pattern has been reported as the most common histologic pattern of thyroid carcinomas in birds, whereas only a few cases have corresponded to the papillary pattern (5, 10, 13, 29). In the present case, most tumor cells were also arranged in a follicular pattern, although with rare papillary formations.

In birds, follicular cell-derived thyroid carcinomas may be non-secretory for serum T3, T4, and thyroglobulin (18); however, there is one report of a thyroglobulin-producing thyroid carcinoma in a wild barred owl (*Strix varia*) (6). On microscopic examination, another neoplasm that should be differentiated because of its location and histologic similarity is medullary thyroid carcinoma (parafollicular, C-cell, carcinoma), which produces calcitonin (2, 8). Likewise, differential diagnosis should include parathyroid carcinoma producing PTH; however, unlike dogs, such carcinomas have not been described in birds (29).

In the present case, we conclude that the histological characteristics of the neoplasm, such as the presence of thyroid follicles of different sizes and irregular shapes, pleomorphic nuclei with prominent nucleoli, areas of necrosis, and mainly the invasion of the capsule by neoplastic cells, were the findings considered for the diagnosis of follicular thyroid carcinoma.

The use of IHC has been helpful in determining the cellular origin of thyroid neoplasms in dogs and other species (2, 8, 9). In some birds, thyroid carcinoma has been diagnosed by correlating the neoplasm's anatomic location with histopathologic findings, without IHC (5, 10, 13).

However, in a wild barred owl (*Strix varia*) with follicular thyroid carcinoma, the neoplastic cells were immunoreactive for thyroglobulin and pancytokeratin, demonstrating the usefulness of IHC for diagnosis in this species (6). In the present case, although the same markers (for thyroglobulin and pancytokeratin) were used, the neoplastic cells showed no immunoreactivity, possibly because the neoplastic tissue had been preserved in formalin for 14 days, a condition that could hinder antigen retrieval in the tissues, because the antibodies used were unable to bind to pigeon tissue antigens, or because the neoplasm was not secreting thyroglobulin.

Thyroid hyperplasia (goiter) is a common disorder in birds and is most frequently observed in budgerigars (*Melopsittacus undulatus*) and pigeons (Columba livia) (14, 25). There are also reports in macaws (*Ara* sp.), cockatiels (*Nymphicus hollandicus*), Moluccan cockatoos *(Cacatua moluccensis*), tanagers *(Tangara spp*.), turacos *(Tauraco spp.),* lovebirds *(Agapornis spp.),* and cormorants (*Phalacrocorax spp*.), and in most cases it has been associated with dietary iodine deficiency or consumption of vegetables containing goitrogenic substances (14, 16, 18, 26). Hyperplastic nodules usually affect both thyroid lobes and tend to be small, non-encapsulated, and do not always enlarge the affected thyroid lobe. Histologically, as described in dogs and in 30 different types of birds with thyroid hyperplasia, hyperplastic nodules form irregular follicles with obliterated lumina containing little or no colloid, lined by large cuboidal to low columnar epithelial cells (22, 26).

The causes of thyroid neoplasms in domestic animals have not been extensively studied. However, in dogs, cats, and birds, advanced age has been correlated as a predisposing factor for the development of neoplasms, including thyroid neoplasms. In this regard, it has been proposed that mammals and birds that live longer are at greater risk of genetic damage leading to cellular mutations (19, 22, 24, 31), which may have been the case in this pigeon, since it was 10 years old. However, no studies have examined other predisposing factors specifically associated with the development of thyroid neoplasms in avian species. The importance of thyroid neoplasms in birds lies in establishing the diagnosis before death, which may be difficult due to their low frequency, the location of the thyroid glands, and the nonspecific nature of the clinical signs, which may be confused with respiratory and digestive disorders; therefore, unfortunately, in most cases the diagnosis is made *postmortem* (10, 13).

We consider this to be the first report of follicular thyroid carcinoma in a domestic pigeon, and although pigeons are not common pets, this condition should be considered as a differential diagnosis in geriatric birds presenting with masses at the level of the coelom entry extending toward the ingluvies, causing dyspnea, regurgitation, crop stasis, or changes in vocalization.

Data Availability

All the original contributions presented in this study are included in the article/supplementary material. Further inquiries can be directed to the corresponding author.

Author Contributions

Ana Cecilia Guevara: Investigation, Writing – review & editing. **Nestor Ledesma**: Writing – review & editing. **Félix Domingo Sánchez**: Writing – review & editing. **Elizabeth Morales**: Writing – original draft, Writing – review & editing. All authors have read and approved the final version of the manuscript.

Conflict of Interest

The authors declare that they have no competing interests.

Generative AI Use Statement

The authors did not use generative artificial intelligence tools or technologies in creating or editing any part of this manuscript.

Acknowledgments

The authors thank MVZ Axel Brum González who examined the pigeon and submitted the neoplasm for histopathologic evaluation as well as technicians Jaime Eugenio Córdova López and Miguel Ángel Martínez Ramírez for their assistance with the photographic material and immunohistochemical preparations, respectively.

References

1. Argenta FF, de Mello LS, Slaviero M, Cony FG, Bandinelli MB, Pavarini SP, Driemeier D, Sonne L. Pathological and immunohistochemical characterization of thyroid neoplasms in cats. J Comp Pathol. 2021;184:44-55. doi: 10.1016/j.jcpa.2021.01.013.
2. Athey JM, Vieson MD, Bailey K, Rudmann D, Baumgartner WA, Selting KA. Canine thyroid carcinomas: A review with emphasis on comparing the compact subtype of follicular thyroid carcinomas and medullary thyroid carcinomas. Vet Pathol. 2024;61(1):7-19. doi: 10.1177/03009858231177225.
3. Bates G, Tucker RL, Ford S, Mattix ME. Thyroid adenocarcinoma in a bald eagle (*Haliaeetus leukoocephalus*). J Zoo Wildl Med. 1999;30(3):439-442.
4. Bauck L. Neoplasms. In: Rosskopf W, Woerpel R, editors. Diseases of cage and aviary birds. 3ª ed. Hong Kong: Williams and Wilkins; 1996. p. 481-489.
5. Bert E, Piñeiro CJS, Crosta L, Raineri R, Rossi G. (2016). Carcinoma tiroideo papilar unilateral relacionado con el metabolismo graso en un loro amazona de frente azul (*Amazona aestiva*). Rev Electron Vet. 2016;17(11):1-6.
6. Brandão J, Manickam B, Blas-Machado U, Cohen E, Mejia-Fava J, Divers S, Mayer J. Productive thyroid follicular carcinoma in a wild barred owl (*Strix varia*). J Vet Diagn Invest. 2012;24(6):1145-50. doi: 10.1177/1040638712463562.
7. Breuhaus BA. Disorders of the equine thyroid gland. Vet Clin North Am Pract. 2011;27:115-128. doi: 10.1016/j.cveq.2010.12.002.
8. Campos M, Ducatelle R, Rutteman G, Kooistra HS, Duchateau L, de Rooster H, Peremans K, Daminet S. Clinical, pathologic, and immunohistochemical prognostic factors in dogs with thyroid carcinoma. J Vet Intern Med. 2014;28(6):1805-13. doi: 10.1111/jvim.12436.
9. Carver JR, Kapatkin A, Patnaik AK. A Comparison of medullary thyroid carcinoma and thyroid adenocarcinoma in dogs: a retrospective study of 38 cases. Vet Surg. 1994;24(4):244.
10. Doukaki C, Kik MJL, Ducatelle R, Cornelissen H, van Zeeland YRA. Thyroid adenocarcinoma in two parrots. Vet Rec Case Rep. 2014;2:e000101. doi:10.1136/vetreccr-2014-000101.
11. Edinboro CH, Scott-Moncrieff JC, Glickman LT. Feline hyperthyroidism: potential relationship with iodine supplement requirements of commercial cat foods. J Feline Med Surg. 2010;12(9):672-9. doi: 10.1016/j.jfms.2010.07.011.
12. Effron M, Griner L, Benirschke K (1977). Nature and rate of neoplasia found in captive wild mammals, birds and reptiles at necropsy. J Natl Cancer Inst. 1977;59(1):185-198. doi: 10.1093/jnci/59.1.185.
13. Escorcia MGQ, Calderón ANL, García EG. Thyroid adenocarcinoma in a versicolor pheasant. Vet Mex. 2008;39(4):435-41.
14. Helmer PJ, Carpenter JW, Hoskinson JJ. What is your diagnosis? J Avian Med Surg. 2000;14(3):200-3. doi.org/10.1647/1082-6742(2000)014[0200:WIYD]2.0.CO;2
15. Herbichi AP, Lorenzetti DM, Dos Santos MY, Hartmann G, Fighera RA, Flores MM. Thyroid lesions in a population of domestic cats submitted to necropsy without clinical suspicion of thyroid disease. J Comp Pathol. 2024;215:1-9. doi: 10.1016/j.jcpa.2024.08.002
16. Lumeij JT. Oncology. Endocrine System. In: Ritchie BW, Harrison GJ, Harrison LR, editors. Avian Medicine: Principles and Application. Lake Worth, FL: Wingers; 1994. p. 659-660.
17. Pang VF, Chang P, Wang F, Chin S, Jeng C, Liu C, Chu P, Zhuo Y. Spontaneous neoplasms in zoo mammals, birds, and reptiles in Taiwan -a 10-year survey. Anim. Biol. 2012;62: 95-110. doi:10.1163/157075611X616941.
18. Rae M. Endocrine disease in pet birds. Semin Avian Exot Pet Med. 1995;4(1):32-8. doi.org/10.1016/S1055-937X(05)80007-6.
19. Reavill DR, Dorrestein GM. Pathology of aging psittacines. Vet Clin North Am Exot Anim Pract. 2010;13(1):135-50. doi: 10.1016/j.cvex.2009.12.001.
20. Reavill DR. Tumors of pet birds. Vet Clin North Am Exot Anim Pract. 2004;7(3):537-60 v. doi: 10.1016/j.cvex.2004.04.008.
21. Reece RL. Observations on naturally occurring neoplasms in birds in the state of Victoria, Australia, Avian Pathol. 1992;21(1):3-32. doi: 10.1080/03079459208418815.
22. Rosol TJ, Meuten DJ. Tumors, hyperplasia, and cysts oy thyroid follicular cells. In: Meuten DJ, editor. Tumors in domestic animals. 5th ed. Ames, Iowa: John Wiley & Sons Inc.; 2017. p. 791-803. doi: 10.1002/9781119181200.
23. Samour JH, Naldo JL, Wernery U, Kinne J. Thyroid cystadenocarcinoma in a saker falcon (*Falco cherrug*). Vet Rec. 2001;149(9):277-8. doi: 10.1136/vr.149.9.277.

24. Sánchez-Godoy F, Ledesma-Ramírez I, Morales-Salinas E. A retrospective study of neoplasms in ornamental and pet birds diagnosed at the hospital de aves of the Universidad Nacional Autónoma de México (2007-2014). Braz J Vet Pathol. 2020;13(1):1-11. doi: 10.24070/bjvp.1983-0246.v13i1p1-11.
25. Scarlett JM. Epidemiology of thyroid diseases of dogs and cats. Vet Clin North Am Small Anim Pract. 1994 May;24(3):477-86. doi: 10.1016/s0195-5616(94)50053-6.
26. Schmidt RE, Reavill DR. Thyroid hyperplasia in birds. J Avian Med Surg. 2002;16(2):111-14. doi:10.1647/1082-6742(2002)016[0111:THIB]2.0.CO;2
27. Schlumberger HG. Spontaneous goiter and cancer of the thyroid in animals. Ohio J Sci. 1955;55:23-43.
28. Shimonohara N, Holland CH, Lin TL, Wigle WL. Naturally occurring neoplasms in pigeons in a research colony: a retrospective study. Avian Dis. 2013;57(1):133-9. doi: 10.1637/10244-051012-Case.1
29. Smit D. Endocrine System. In: Schmidt RE, Struthers JD, Phalen DN, editors. Pathology of pet and aviary birds. 3rd ed. New Jersey: Wiley Blackwell; 2024. p. 291-305. doi:10.1002/9781119650522.
30. Wadsworth PF, Jones DM. Some abnormalities of the thyroid gland in non-domesticated birds. Avian Pathol. 1979 Jul;8(3):279-84. doi: 10.1080/03079457908418352
31. Wucherer KL, Wilke V. Thyroid cancer in dogs: an update based on 638 cases (1995-2005). J Am Anim Hosp Assoc. 2010;46(4):249-54. doi: 10.5326/0460249.