Braz J Vet Pathol, 2026, vol. 19, e019024
DOI: https://doi.org/10.24070/bjvp.1983-0246.019024

BJVP
Brazilian Journal of Veterinary Pathology
ISSN 1983-0246

Case Report

Intramedullary dermoid cyst associated with Wallerian degeneration in a dog

Mayara Caroline Rosolem[1]* , Pamela Rodrigues Reina Moreira[2] , Maria Gisela Laranjeira[3] , Gisele Fabrino Machado[3] , Rosemeri de Oliveira Vasconcelos[1]

[1] Department of Pathology, Reproduction and One Health, Faculty of Agricultural and Veterinary Sciences, UNESP, Jaboticabal, SP, Brazil
[2] Department of Pathology, Faculty of Veterinary Medicine and Animal Science, UFU, Uberlândia, MG, Brazil
[3] Department of Clinical, Surgery and Animal Reproduction, Faculty of Veterinary Medicine of Araçatuba, UNESP, Araçatuba, SP, Brazil

*Corresponding author: mayara.c.rosolem@unesp.br
Submitted: March 30th, 2026. Accepted: June 3rd, 2026.

Abstract
Dermoid cysts are benign congenital lesions of ectodermal origin lined by stratified squamous epithelium and containing cutaneous adnexal structures, keratin debris, and sebaceous material. These lesions are commonly identified in the skin of dogs and cats, particularly along embryonic fusion lines. Occurrence within the central nervous system is uncommon and intramedullary localization is exceptionally rare. This report describes an intramedullary dermoid cyst associated with Wallerian degeneration in an eight-month-old female Boxer dog presenting with a one-month history of paraplegia, self-mutilation of the right pelvic limb paw, and loss of deep pain perception. Due to severe neurological dysfunction, euthanasia was performed and the animal was submitted for pathological examination. Gross examination revealed a 2 cm thin-walled, pearly white cystic lesion located within the L4–S3 spinal cord segments, containing friable brownish material with keratin filaments. Histopathological examination demonstrated a cyst lined by well-differentiated stratified squamous keratinizing epithelium with a prominent stratum granulosum and abundant orthokeratotic laminated keratin within the lumen. Cutaneous adnexal structures, including sebaceous and apocrine glands, were observed within the cyst wall. Adjacent spinal cord tissue exhibited severe compression, focal malacia, and Wallerian degeneration characterized by digestion chambers and gitter cells. Immunohistochemically, the epithelial lining showed strong cytokeratin immunostaining and absence of vimentin expression, whereas stromal and adnexal components were vimentin-positive. The morphological diagnosis was an intramedullary dermoid cyst associated with Wallerian degeneration. This report highlights the rare intramedullary presentation of dermoid cysts in dogs and reinforces the importance of histopathological and immunohistochemical evaluation for definitive diagnosis.

Keywords: intramedullary dermoid cyst, spinal cord, canine, Wallerian degeneration, neuropathology.

Introduction

Dermoid cysts are congenital developmental anomalies of ectodermal origin lined by stratified squamous epithelium and containing keratin, sebaceous material, hair follicles, and other cutaneous adnexal structures (5, 13, 15, 21). These lesions are commonly identified in the skin of dogs and cats, particularly along embryonic fusion lines, and may vary from 1 to 5 cm in diameter (4, 13). The most frequently affected anatomical sites include the dorsal cervical region, periorbital area, suprasternal region, and head (4, 13). Dermoid cysts have been reported more commonly in large dog breeds such as Saint Bernard and Boxer dogs, as well as

in smaller breeds, including Dachshunds and Basset Hounds (21). Cats may also be affected (15).

Dermoid cysts involving the central nervous system are uncommon and may occur intracranially or, less frequently, within the spinal canal and spinal cord parenchyma (3, 5, 13, 20). These lesions are considered congenital malformations associated with neural tube dysraphism, resulting from ectodermal inclusion during neural tube closure in embryogenesis (10-13, 20). During this process, ectodermal elements become entrapped within the developing neural tissue before complete meningeal formation, giving rise to ectopic cutaneous structures within the neuraxis (10-13, 20). As these lesions progressively accumulate keratinaceous debris and sebaceous material, they may act as space-occupying masses, causing spinal cord compression and compressive myelopathy associated with neurological signs such as paraplegia and sensory dysfunction (3).

Histologically, these lesions are classified according to the structures present within the cyst wall. Epidermoid cysts are lined by stratified squamous epithelium without cutaneous adnexal structures, whereas dermoid cysts contain skin appendages such as sebaceous glands, apocrine glands, and hair follicles. Teratoid cysts additionally contain tissues derived from all three embryonic germ layers (1, 5). Malignant transformation is considered rare but has occasionally been described, particularly as squamous cell carcinoma (1, 5).

The differential diagnoses for dermoid cysts affecting the central nervous system include encephalocele, meningocele, lipoma, hemangioma, hematoma, sebaceous cyst, pilonidal cyst, and pericranial cysts (6, 8). Most spinal dermoid cysts reported in the literature are located in the intradural-extramedullary compartment, whereas intramedullary localization is considered exceptionally rare (16). Therefore, the objective of the present report is to describe the clinical, pathological, and immunohistochemical findings of an intramedullary dermoid cyst associated with Wallerian degeneration in a young Boxer dog.

Case description

An eight-month-old female Boxer dog was evaluated at the "Luiz Quintiliano de Oliveira" Veterinary Hospital, School of Veterinary Medicine of Araçatuba (FMVA), UNESP, Araçatuba, São Paulo State, Brazil. The animal had a one-month history of neurological signs, including self-mutilation of the right pelvic limb paw, paraplegia, and loss of deep pain perception. Due to the severe neurological dysfunction and poor prognosis, euthanasia was elected, and the animal was submitted for pathological examination.

Tissue samples were collected during necropsy, fixed in 10% buffered formalin, routinely processed for histopathology, embedded in paraffin, sectioned at 5 µm, and stained with hematoxylin and eosin (H&E). Immunohistochemical analysis was subsequently performed to confirm the epithelial origin of the lesion.

Gross examination revealed a thin-walled, pearly white cystic lesion located within the L4–S3 spinal cord segments, in the region of the lumbosacral plexus, measuring approximately 2 cm in diameter. On cross-section, the cyst contained friable brownish material suggestive of keratin filaments (Fig. 1A), and the adjacent spinal cord tissue was edematous and whitish.

Histologically, a cystic formation occupying more than 50% of the spinal cord parenchyma was observed. The cyst was lined by well-differentiated stratified squamous keratinizing epithelium with a prominent stratum granulosum. The lumen contained abundant orthokeratotic laminated keratin. Cutaneous adnexal structures, including sebaceous and apocrine glands, were present within the cyst wall and were associated with a moderate multifocal lymphoplasmacytic inflammatory infiltrate (Fig. 1B). Adjacent adipose tissue was also observed. The lesion caused marked compression of the spinal cord parenchyma, resulting in focal areas of necrosis of neurons, astrocytes, and oligodendrocytes with the presence of Gitter cells and adjacent white matter Wallerian degeneration characterized by digestion chambers and gitter cells. The morphological diagnosis was intramedullary dermoid cyst associated with Wallerian degeneration.

Immunohistochemical analysis was performed using antibodies against cytokeratin (clone AE1/AE3, monoclonal, mouse anti-human, Dako, dilution 1:250) and vimentin (clone V9, monoclonal, mouse anti-vimentin, Dako, dilution 1:100). Antigen retrieval was performed in a pressure chamber (Pascal, Dako). Endogenous peroxidase activity was blocked using methanol and 10% hydrogen peroxide, followed by blocking of nonspecific reactions with Protein Block (Dako, code X0909). Primary antibodies were incubated for 18h at 4°C. Immunoreactions were detected using the LSAB Kit (Dako, code K0690-1) and visualized with 3,3-diaminobenzidine (DAB; Dako, code K3468-1). Sections were counterstained with Harris hematoxylin.

Immunohistochemically, the epithelial lining of the cyst showed strong cytokeratin immunolabeling, confirming its epithelial origin (Fig. 1C). The epithelial cells were negative for vimentin, whereas the stromal tissue and cutaneous adnexal structures exhibited positive immunostaining for this marker (Fig. 1D).

Discussion

Epidermoid and dermoid cysts involving the neuraxis are rare lesions reported in humans and several animal species, including dogs, horses, rodents, and mice (1, 4, 6, 10-15, 18). In canine breeds, Boxer dogs have been described as a predisposed breed for the development of dermoid cysts, including lesions affecting the central nervous system (15).

Braz J Vet Pathol, 2026, vol. 19, e019024
DOI: https://doi.org/10.24070/bjvp.1983-0246.019024

Dermoid cysts are congenital lesions associated with neural tube dysraphism and originate from abnormal ectodermal inclusion during neural tube closure in embryogenesis (2, 10-13, 20, 16). During this developmental process, ectodermal elements become entrapped within the developing spinal canal or spinal cord parenchyma before complete meningeal formation, resulting in ectopic cutaneous structures within the neuraxis (10-13, 20). Although congenital, clinical signs may only become evident later in life due to the gradual accumulation of keratinaceous debris and progressive compression of adjacent neural tissue (2, 16).

Most spinal dermoid cysts described in the literature are located in the intradural-extramedullary compartment, whereas intramedullary localization is considered exceptionally rare (16). The unusual intramedullary location observed in the present case highlights the importance of including this lesion among the differential diagnoses for progressive spinal cord compression in young dogs presenting neurological dysfunction.

The dog described in the present report exhibited paraplegia, loss of deep pain perception, and self-mutilation of the right pelvic limb associated with severe neurological dysfunction (21-23). The self-mutilation behavior was likely associated with neuropathic sensory alterations, such as paresthesia or dysesthesia, resulting from compression of the dorsal horns and/or lumbosacral nerve roots by the cystic lesion. Similar manifestations have been reported in dogs with neuropathic pain secondary to spinal cord and peripheral nerve injury (7, 23).

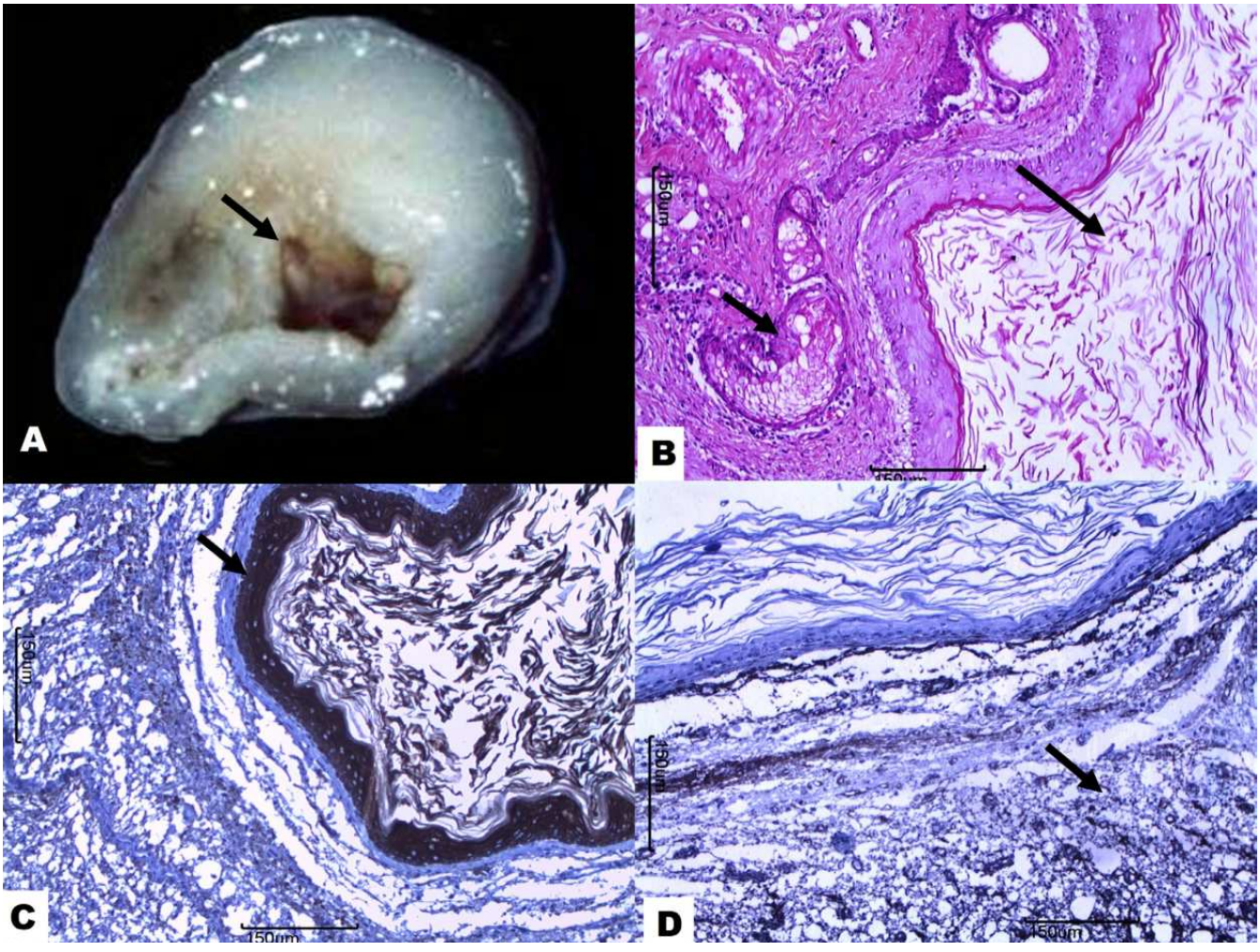

Figure 1. Intramedullary dermoid cyst, dog. (A) Gross appearance of a tan swelling (arrow). On cross-section, a pearly white cyst measuring approximately 2 cm in diameter and containing friable brownish material suggestive of keratin filaments was observed. (B) Histopathological appearance showing cutaneous adnexal structures (short arrow) and well-differentiated stratified squamous keratinizing epithelium with a prominent stratum granulosum surrounding the nervous tissue (long arrow) (H&E, 400×). (C) Immunohistochemistry showing positive cytokeratin immunostaining in the epithelial lining of the cyst. (D) Immunohistochemistry for vimentin showing negative staining in the epithelial cells and positive immunolabeling in the stromal tissue (arrow) and cutaneous adnexal structures (peroxidase polymer method, bar = 100 µm).

Gross findings in the present case were consistent with previous descriptions of spinal dermoid cysts, characterized by a pearly white cystic lesion containing friable keratinaceous material (5, 12, 15, 20, 21). Histologically, dermoid cysts resemble cutaneous dermoid lesions and are characterized by cyst walls lined by well-differentiated stratified squamous keratinizing epithelium supported by fibrous stroma and associated with cutaneous adnexal structures, including sebaceous glands, apocrine glands, and hair follicles (1, 5, 10, 12, 20). In the present case, the identification of cutaneous adnexal structures within the cyst wall was essential for distinguishing the lesion from an epidermoid cyst.

The main histopathological differential diagnosis for dermoid cyst is epidermoid cyst, since both lesions are lined by stratified squamous keratinizing epithelium and contain laminated keratin within the lumen (9, 19). However, epidermoid cysts lack cutaneous adnexal structures, whereas dermoid cysts contain skin appendages such as sebaceous glands, apocrine glands, and hair follicles within the cyst wall (9, 19). The presence of these adnexal structures supported the diagnosis of intramedullary dermoid cyst in the present case.

In addition to the cystic lesion, adjacent spinal cord tissue exhibited focal necrosis and Wallerian degeneration characterized by digestion chambers and Gitter cells. These findings were likely secondary to chronic compression of the spinal cord parenchyma by the expanding cystic lesion, resulting in ischemia, hypoxia, and compressive myelopathy. The loss of deep pain perception observed clinically further supported the severity of the spinal cord injury (22).

Immunohistochemically, the epithelial lining of the cyst showed strong cytokeratin immunoreactivity and absence of vimentin expression, confirming its epithelial origin. In contrast, stromal tissue and cutaneous adnexal structures exhibited positive vimentin immunostaining, consistent with their mesenchymal origin. Similar immunohistochemical findings have been previously described in dermoid cysts affecting the nervous system (10, 12, 20).

Although dermoid cysts are more frequently reported intracranially, particularly involving the fourth ventricle and cerebellopontine angle (13, 20), spinal cord involvement is considerably less common (10, 12, 21, 22). Therefore, the present report contributes to the limited veterinary literature describing intramedullary dermoid cysts associated with severe neurological dysfunction and secondary Wallerian degeneration in dogs.

Intramedullary dermoid cysts are exceptionally rare congenital lesions in dogs and should be considered among the differential diagnoses for progressive spinal cord compression associated with severe neurological dysfunction in young animals. In the present case, the presence of cutaneous adnexal structures within the cyst wall was essential for differentiating the lesion from an epidermoid cyst. Additionally, the associated Wallerian degeneration and neuropathic clinical manifestations highlighted the severe secondary effects of chronic spinal cord compression. Immunohistochemical findings supported the epithelial origin of the lesion and complemented the histopathological diagnosis. Nevertheless, histopathological evaluation remains the gold standard for the definitive diagnosis and differentiation of dermoid cysts from other intramedullary lesions.

Data Availability

All the original contributions presented in this study are included in the article/supplementary material. Further inquiries can be directed to the corresponding author.

Author Contributions

Mayara Caroline Rosolem: Conceptualization, Data curation, Formal analysis, Investigation, Writing – original draft, Writing – review & editing. **Pamela Rodrigues Reina Moreira:** Methodology, Investigation, Formal analysis, Writing – review & editing. **Rosemeri de Oliveira Vasconcelos:** Conceptualization, Resources, Supervision, Writing – review & editing. **Gisele Fabrino Machado:** Investigation, Formal analysis, Resources, Writing – review & editing. **Maria Gisela Laranjeira:** Investigation, Formal analysis, Resources, Writing – review & editing.

Conflict of Interest

The authors declare no competing interests.

Generative AI Use Statement

The authors did not use generative artificial intelligence tools or technologies in creating or editing any part of this manuscript.

References

1. Aquino HB, Miranda CCV, Filho CAB, Carelli EF, Borges, G. Congenital dermoid inclusion cyst over the anterior fontanel: report of three cases. Arq Neuropsiquiatr. 2003; 61, 448-452. doi: 10.1590/S0004-282X2003000300022.
2. Barkovich AJ. Congenital anomalies of the spine. In: Pediatric Neuroimaging. 5th ed. Philadelphia: Lippincott Williams & Wilkins; 2011. 1144p.
3. Borges G, Júnior JAM, Carelli EF, Alvarenga M, Castro R, Bonilha, L. Pilonidal cyst on the vault: case report. Arq Neuropsiquiatr. 1999; 57, 273-276. doi: 10.1590/S0004-282X1999000200017.
4. Camacho AA, Laus JL, Valeri V, Valeri FV, Nunes N. Dermoid sinus in a Great Pyrenees dog. J. Vet. Res.

Anim. Sci. 1995; 32, 170-172. doi: 10.11606/issn.1678-4456.bjvras.1994.52105.

5. Carvalho EA, Pontinha TFBS, Oliveira JR, Braga EC, Baldim JA. Cisto dermoide simulando neoplasia retro-retal. Rev. Bras. Coloproctol. 2007; 27, 328-329. doi: 10.1590/S0101-98802007000300013.
6. Castro RAG, Filho ASR, Silva Júnior VV. Dermoid cyst of the anterior fontanelle in adults: case report. Arq Neuropsiquiatr. 200; 65, 170-172. doi: 10.1590/S0004-282X2007000100036.
7. Cashmore RG, Harcourt-Brown TR, Freeman PM, Jeffery ND, Granger N. Clinical diagnosis and treatment of suspected neuropathic pain in three dogs. Aust. Vet. J. 2009; 87(1):45-50. doi: 10.1111/j.1751-0813.2008.00381.
8. Falavigna A, Segatto AC, Salgado K. A rare case of intramedullary lipoma associated with cyst. Arq Neuropsiquiatr. 2001; 59, 112-115. doi: 10.1590/S0004-282X2001000100023.
9. Guidetti B, Gagliardi FM. Epidermoid and dermoid cysts. Clinical evaluation and late surgical results. J. Neurosurg. 1977; 47(1):12–18. doi: 10.3171/jns.1977.47.1.0012.
10. Howard Martin M, Bowles MH. Intracranial dermoid cyst in a dog. J. Am. Vet. Med. Assoc. 1988; 192, 215-216. doi: 10.2460/javma.1988.192.02.215.
11. Kelly DF, Watson WJB. Epidermoid cyst of the brain in the horse. Equine Vet. J. 1976; 8,110-112. doi: 10.1111/j.2042-3306.1976.tb03309.
12. Koestner A, Higgins RJ. Tumors of the nervous system. In: MEUTEN, D.J. Tumors in Domestic Animals. 4 ed., Iowa: Iowa State Press, 2002. p728-730.
13. Kornegay JN, Gorgacz EJ. Intracranial epidermoid cysts in three dogs. Vet. Pathol. 1982; 19, 646-650. doi: 10.1177/030098588201900608.
14. Kulwich BA. Epidermoid cysts in the central nervous system of rats and mice: an incidental finding in toxicity/oncogenicity studies. Vet. Pathol. 1994; 31:475-478. doi: 10.1177/030098589403100413
15. Lee J, Kim M, Kim I, Kim Y, Kim M. Surgical correction of corneal dermoid in a dog: Case report. J. Vet. Sci. 2005; 6, 369-370. doi. 10.4142/jvs.2005.6.4.369.
16. Lunardi P, Missori P. Congenital spinal dermoid and epidermoid tumors. Neurosurg. Rev. 1991; 14(2):111-115. doi: 10.1007/BF00310629.
17. Moore SA. Managing neuropathic pain in dogs. Front. Vet. Sc. 2016; 3:12. doi: 10.3389/fvets.2016.00012.
18. Nobel TA, Nysta M, Skolnik M, Meshorera A. Epidermoid cysts in the central nervous system of mice. J. Comp. Pathol. 1987; 97(3):357-9. doi: 10.1016/0021-9975(87)90101-0.
19. Oh HJ, Eo MY, Sodnom-Ish B, Amponsah EK, Frimpong P, Myoung H, Kim SM. Craniofacial Epidermoid and Dermoid Cysts. J. Craniofac. Surg. 2023; 01; 34 (8): 2405-2409. doi: 10.1097/SCS.0000000000009611.
20. Parrah JD, Moulvi BA, Ansari MM. Short Communication: Surgical management of dermoid sinus in a dog. Intas Polivet. 2014; 15: 133-135.
21. Souza FV, Nogueira RLM, Turatti E, Menezes Júnior JMS, Freitas MR. Cisto dermoide: Relato de caso clínico. Rev. cir. traumatol. buco-maxilo-fac. 2007; 7, p. 37-42.
22. Summers BA, Cummings JF, Lahunta A. Veterinary Neuropathology. St. Louis: Mosby, 1995. 527p.
23. Seong-Ju O, Hwang G, Yun Ec, Lee D, Lee SL, Lee HC, Hwang TS. Ultrasonographic and computed tomographic features of dermoid cyst of the neck in a dog: a case report. J. Vet. Clin. 2024; 41(4): 252-257. doi: 10.17555/jvc.2024.41.4.252.