Braz J Vet Pathol, 2026, vol. 19, e019020
DOI: https://doi.org/10.24070/bjvp.1983-0246.019020

BJVP
Brazilian Journal of Veterinary Pathology
ISSN 1983-0246

Case Report

Malignant melanoma in a lamb: clinical and pathological findings

Márcio Douglas Leal da Silveira[1], Maria Luiza de Barros Gonçalves[2], Caroline da Silva Penha[1], Camila Soares Vasconcelos Rocha[1], Erica Emerenciano Albuquerque[2], Huber Rizzo[2]*, Fabrício Bezerra de Sá[2], Lúcio Esmeraldo Honório de Melo[2]

[1]Professional Health Residency Program – Veterinary Medicine, Department of Veterinary Medicine, Federal Rural University of Pernambuco (UFRPE), Recife, PE, Brazil
[2]Department of Veterinary Medicine, Federal Rural University of Pernambuco (UFRPE), Recife, PE, Brazil

***Corresponding author:** huber.rizzo@ufrpe.br
Submitted: April 7th, 2026. Accepted: May 11th, 2026.

Abstract
Melanoma is a rare neoplasm in small ruminants, particularly in sheep, and is uncommon in young animals. This study describes the clinical, cytological, histopathological, and immunohistochemical findings of a melanoma in a lamb. A three-month-old female sheep presented with a progressively growing mass in the left periauricular region, first observed at 45 days of age. Cytological evaluation revealed atypical cellular proliferation with marked pleomorphism and mitotic figures, suggesting a malignant neoplastic process. Imaging examinations demonstrated increased soft-tissue volume without evidence of bone involvement. Surgical excision was performed for both diagnostic and therapeutic purposes. Histopathological examination revealed a non-encapsulated, densely cellular, infiltrative neoplasm predominantly composed of epithelioid cells, with marked anisocytosis and anisokaryosis, a high mitotic index, intracytoplasmic melanin pigment, and areas of necrosis. Immunohistochemical analysis showed positive immunostaining for S100 and Melan-A, confirming the melanocytic origin of the neoplasm. Despite surgical removal, rapid local recurrence and clinical deterioration were observed, culminating in death within 30 days, indicating aggressive biological behavior and possible metastatic dissemination. This report demonstrates that, although rare in sheep, melanoma can occur in young animals and may progress rapidly, with a poor prognosis, highlighting the importance of an integrated diagnostic approach and its inclusion in the differential diagnosis of cutaneous masses in lambs.

Keywords: cytology, histopathology, immunohistochemistry, sheep, melanocytes, neoplasia.

Introduction

Melanocytic neoplasms are tumors derived from the neoplastic transformation of melanocytes, cells originating from the neural crest and distributed in the skin, mucous membranes, eyes, and meninges (13). In domestic animals, melanoma varies among species, being frequently described in dogs and horses, but considered uncommon in ruminants, particularly in sheep (4, 14). In horses, melanomas are particularly common in gray-coated animals, especially aged horses, suggesting that coat pigmentation and melanocytic biology may influence tumor development (11).

In small ruminants, these tumors are rare and generally reported as sporadic findings. In Brazil, epidemiological surveys have shown a low incidence of melanoma in sheep, reinforcing its rarity in this species (7). However, when present, these neoplasms may exhibit aggressive biological behavior, with high invasive and metastatic potential (6, 10).

The etiopathogenesis of melanoma is multifactorial, involving the interaction between genetic and environmental factors. Ultraviolet radiation is considered a predisposing factor in some species; however, the occurrence of tumors in non-exposed areas suggests the involvement of additional mechanisms independent of solar radiation (14). Furthermore, tumor

progression is associated with dysregulation of cellular pathways involved in proliferation, survival, and cell dissemination (3, 15). Recent studies also demonstrate the involvement of molecular pathways such as NF-κB and TGF-β, as well as cellular processes including apoptosis and autophagy, which directly influence the proliferative and invasive capacity of tumor cells (16).

The clinical and morphological presentation of melanoma in ruminants is heterogeneous, varying in anatomical location, degree of pigmentation, and biological behavior, which may hinder clinical recognition, especially in early stages or in cases with subtle pigmentation (6).

Although melanomas are generally more frequent in adult animals, they have also been described in young individuals, including congenital or early-onset forms, suggesting an association with alterations in melanocytic development (2, 4). In cattle, a different pattern is observed, with a higher occurrence in young animals, possibly associated with developmental disorders (1, 9).

From an anatomopathological standpoint, melanomas are characterized by the proliferation of epithelioid, spindle-shaped, or mixed cells, with variable degrees of pigmentation, cellular pleomorphism, and mitotic activity, often associated with infiltrative growth and areas of necrosis. Morphological variability, including amelanotic forms, may hinder cytological diagnosis, underscoring the importance of correlating histopathology with immunohistochemistry to confirm melanocytic origin (8, 13).

Within this context, this study describes the clinical, cytological, histopathological, and immunohistochemical findings of melanoma in a lamb, contributing to a better understanding of this neoplasm in small ruminants.

Case description

A female sheep, approximately three months old, mixed breed, with a black coat and body weight of 16 kg, was attended at the Large Animal Clinic of the Department of Veterinary Medicine, Federal Rural University of Pernambuco (AGA/DMV/UFRPE), Brazil. The animal originated from a farm located in the municipality of Moreno (8°07′05″ S; 35°05′31″ W), in the Metropolitan Region of Recife, Zona da Mata Sul of Pernambuco, Brazil.

According to the anamnesis, the animals were fed roughage from Brachiaria decumbens, supplemented with hay during dry periods, and a commercial concentrate formulated for sheep. The owner reported that at 45 days of age, the animal developed a swelling at the base of the left ear, initially firm, that progressed toward the frontal bone. An abscess was initially suspected, and drainage was attempted; however, no purulent material was obtained; instead, dark red hemorrhagic fluid was drained. Empirical treatment with dexamethasone and oxytetracycline was instituted, with no clinical improvement and progression of the lesion, which led to referral to the veterinary service at AGA/DMV/UFRPE.

On clinical examination, the animal presented a heart rate of 128 bpm, a respiratory rate of 40 breaths per minute, and a rectal temperature of 39.8 °C. Cardiac auscultation revealed a regular rhythm without murmurs, and no abnormalities were detected on pulmonary auscultation. Digestive system evaluation showed preserved ruminal motility, with six contractions in five minutes. Inspection of the cranial region revealed an expansile mass measuring approximately 9 cm in diameter, with soft to fluctuant consistency in some areas, covered by intact skin, located predominantly in the left periauricular region, with extension toward the periocular and occipital regions (Fig. 1A). Hematological evaluation revealed mild microcytic anemia (hematocrit 25% and MCV 26.32 fL), associated with anisocytosis due to microcytosis, as well as hypoproteinemia (5.5 g/dL), mild leukocytosis due to neutrophilia (12.90 $\times 10^3$/μL), and mild thrombocytosis (840 $\times 10^3$/μL), with the presence of rare activated platelets and platelet microaggregates.

Radiographic evaluation of the skull showed a marked increase in soft-tissue volume in the left periauricular region, with mixed radiopacity and a well-defined expansile appearance, causing displacement of adjacent structures without evidence of bone lysis or proliferation, indicating the absence of bone involvement (Fig. 1B). Ultrasonography suggested content compatible with hematoma or hygroma, with no evidence of abscess formation. Fine-needle aspiration (FNA) was performed, yielding hemorrhagic material, which was submitted for cytological and bacteriological analysis (Fig. 1C).

Cytopathological examination revealed a sample with low to moderate cellularity, composed of a mixed lymphocytic population with atypical mesenchymal cells arranged in pseudoaggregates, showing marked pleomorphism, anisocytosis, anisokaryosis, and mitotic figures, including atypical forms. The background contained abundant hemorrhagic fluid containing numerous erythrocytes, macrophages, and cellular debris (Fig. 2A–B). The findings were suggestive of inflammatory infiltrate associated with atypical neoplastic proliferation and necrosis, and histopathological confirmation was recommended. Bacterial culture showed no microbial growth.

Based on these findings, surgical excision of the mass was performed (Fig. 1D). The procedure was carried out under general inhalation anesthesia, using a protocol with midazolam, morphine, ketamine, and propofol, with maintenance using isoflurane. An elliptical incision was made with a safety margin of approximately 2 cm, followed by dissection and complete removal of the mass.

Macroscopically, the fragments were blackish, irregular, and firm. Microscopically, a non-encapsulated, densely cellular neoplastic proliferation was observed, composed predominantly of pleomorphic epithelioid cells interspersed with fibrovascular stroma. The cells exhibited moderate to abundant, slightly eosinophilic cytoplasm, occasionally containing melanin pigment, and a high nucleus-to-cytoplasm ratio. The nuclei were large, ranging

Braz J Vet Pathol, 2026, vol. 19, e019020
DOI: https://doi.org/10.24070/bjvp.1983-0246.019020

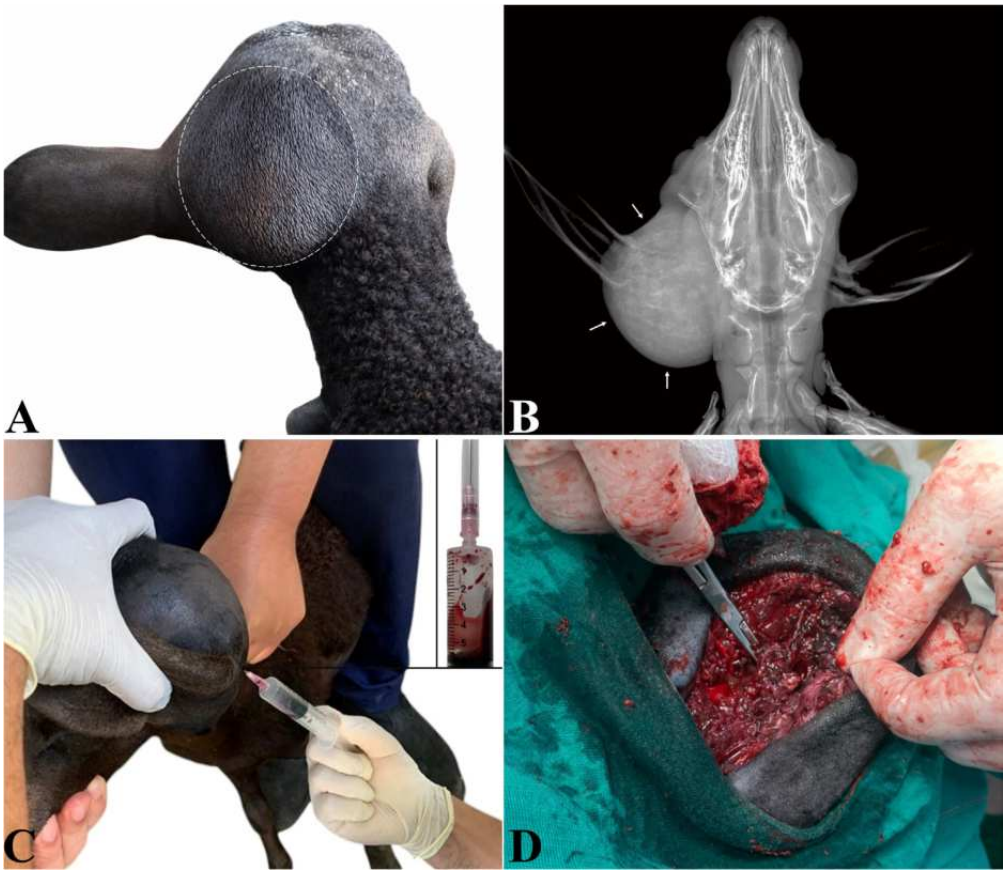

Figure 1. Clinical and imaging evaluation of melanoma in a lamb. (A) Expansile mass in the left cranial region, predominantly involving the left periauricular region, with extension toward the periocular and occipital regions, covered by intact skin (dotted circle). (B) Skull radiographic examination (dorsoventral and lateral projections), demonstrating marked soft tissue enlargement in the left periauricular region, with mass effect and displacement of adjacent structures, without evidence of bone lysis or proliferation (arrows). (C) Fine-needle aspiration (FNA), showing the collection of dark red hemorrhagic fluid. (D) Intraoperative aspect after surgical excision of the mass.

from round to oval, often irregular, with loose chromatin and multiple prominent nucleoli.

Marked cellular and nuclear pleomorphism, anisocytosis, anisokaryosis, macrocytosis, macrokaryosis, aberrant nucleoli, as well as nuclear molding and indentation were observed, with the presence of bi- and multinucleated cells. Mitotic activity was high, with 24 mitotic figures in 10 high-power fields (400×), along with multifocal areas of necrosis, mild mineralization, and apoptotic cells (Fig. 2C–D). Immunohistochemical analysis demonstrated positive cytoplasmic and nuclear immunolabeling for S100 and moderate cytoplasmic immunoreactivity for Melan-A in neoplastic cells, confirming the melanocytic origin of the neoplasm (Fig. 2E–F).

Postoperatively, the animal initially showed satisfactory recovery under analgesic and antimicrobial therapy. However, within less than 30 days, local recurrence with rapid tumor growth was observed. The animal subsequently developed unilateral left exophthalmos, difficulty in food prehension, and head tilt, progressing to death. Necropsy was recommended but not authorized by the owner, preventing the evaluation of possible metastases.

Discussion

The present report describes a melanoma in a lamb with aggressive biological behavior, characterized by rapid growth, high mitotic index, early recurrence, and unfavorable clinical outcome. In sheep, this neoplasm is considered rare, especially in Brazil, where epidemiological surveys indicate a low frequency of melanocytic tumors in this species. In this context, descriptions of cases with atypical presentations, such as in young animals, are relevant for expanding current knowledge of the clinical and biological variability of this neoplasm (7).

The tumor's occurrence at 45 days of age is one of the most relevant aspects of this case. Although melanomas are more frequently described in adult ruminants, they have also been reported in young individuals, including congenital

Braz J Vet Pathol, 2026, vol. 19, e019020
DOI: https://doi.org/10.24070/bjvp.1983-0246.019020

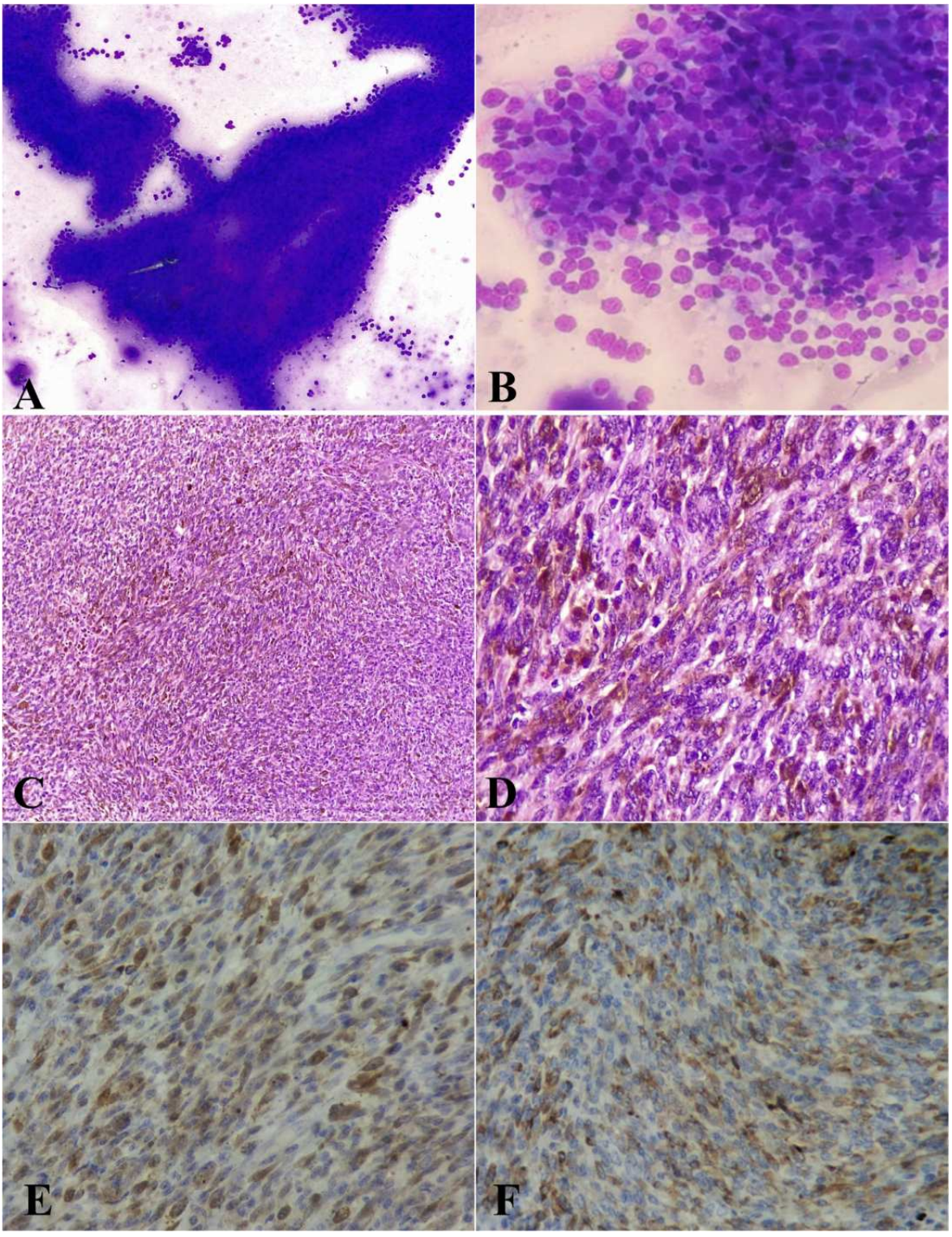

Figure 2. Cytological, histopathological, and immunohistochemical evaluation of melanoma in a lamb. (A) Fine-needle aspiration cytology showing pleomorphic neoplastic proliferation arranged in pseudoaggregates, associated with an eosinophilic matrix, Diff-Quick stain (10×). (B) Cytological detail demonstrating round to oval cells, with indistinct to poorly defined cytoplasm, variable chromatin, and rare pigment granules, Diff-Quick stain (40×). (C) Histopathological examination showing solid proliferation of spindle to epithelioid cells, H&E (10×). (D) Higher magnification demonstrating marked pleomorphism, presence of intracytoplasmic melanin pigment, and atypical mitotic figures, H&E (40×). (E) Positive cytoplasmic and nuclear immunolabeling for S100 in neoplastic cells (40×). (F) Moderate cytoplasmic immunoreactivity for Melan-A in neoplastic cells (40×).

or early-onset forms, suggesting a possible association with alterations in melanocytic development. Among these, Baker's (2) report describing an invasive melanoma in a newborn lamb stands out as one of the few comparable cases. Similarly, the early onset and rapid progression observed in the present case suggest a highly proliferative biological phenotype, possibly related to alterations in the development or regulation of the melanocytic lineage (2, 4).

In the present case, the animal had a black coat, and the lesion developed in a pigmented cranial region. In some species, such as humans, reduced pigmentation and increased exposure to ultraviolet radiation are considered important predisposing factors for melanoma development. Conversely, melanocytic tumors in sheep have also been described in darkly pigmented animals and in anatomical regions not exposed to ultraviolet radiation, suggesting that additional mechanisms independent of solar exposure may be involved in melanocytic transformation (14).

The clinical presentation as an expansile mass in the cranial region is consistent with previous descriptions, in which melanomas may occur at different anatomical locations and exhibit wide morphological and behavioral variability. This heterogeneity, including variations in pigmentation and lesion consistency, may hinder clinical diagnosis. In the present case, the initial suspicion of an abscess and the attempt at drainage highlight this diagnostic challenge, as melanocytic lesions may contain hemorrhage and mimic inflammatory processes (6, 8).

Fine-needle aspiration cytology revealed a mixed cell population, predominantly lymphocytic with atypical mesenchymal cells, which hindered the initial diagnostic interpretation. This finding reinforces that, although cytology is a useful screening tool, its interpretation may be limited in melanocytic tumors due to high morphological variability, including epithelioid, spindle, and amelanotic forms. Additionally, the presence of a hemorrhagic background and necrosis may compromise cytological evaluation, leading to inconclusive or misleading diagnoses (13). Caseous lymphadenitis was considered among the differential diagnoses due to the anatomical location and the species involved; however, the absence of purulent caseous material, the lack of bacterial growth, and cytological and histopathological findings ruled out this condition (5).

Histopathological findings were decisive for diagnosis. The densely cellular neoplastic proliferation, characterized by marked pleomorphism, high mitotic activity (24 mitoses/10 HPF), melanin pigment, and areas of necrosis, supports the diagnosis of malignant melanoma with aggressive behavior. These findings are consistent with reports in small ruminants, in which melanocytic tumors show infiltrative growth and high metastatic potential. The high mitotic index observed in this case further supports the neoplasm's elevated proliferative potential and its association with a poor prognosis (8, 10).

Immunohistochemical confirmation of S100 and Melan-A expression was essential to establish the melanocytic origin of the neoplasm, particularly given the observed morphological variability. These markers show high sensitivity for melanocytic tumors and are especially useful in cases with low pigmentation or atypical morphology (13).

The clinical course, marked by local recurrence within less than 30 days and rapid progression, supports the aggressive behavior of melanoma. In small ruminants, metastatic dissemination to lymph nodes and visceral organs, such as the liver, lungs, and kidneys, has been reported. In the present case, the absence of necropsy prevented confirmation of metastases; however, the clinical signs observed, including unilateral exophthalmos, head tilt, and difficulty in food prehension, strongly suggest involvement of cranial structures or the central nervous system (10, 12).

From a biological standpoint, melanoma aggressiveness is associated with dysregulation of multiple cellular pathways involved in proliferation, survival, and tumor invasion. Recent studies indicate that pathways such as NF-κB and TGF-β, as well as processes related to apoptosis and autophagy, play a central role in melanoma progression. In melanoma, dysregulation of apoptosis-related pathways may impair programmed cell death, allowing neoplastic cells to survive and expand, while autophagy may contribute to tumor adaptation and progression. These mechanisms may explain the rapid growth, invasiveness, and early recurrence observed in this case, further reinforcing the tumor's highly aggressive nature (16).

From a therapeutic perspective, surgical excision remains the main approach; however, it is often not curative in tumors with infiltrative behavior and high proliferative potential. The early recurrence observed reinforces the guarded prognosis of melanoma in small ruminants, especially when diagnosed at advanced stages (12).

Thus, the present report highlights that, although rare, melanoma should be included in the differential diagnosis of cutaneous masses in sheep, including in young animals. The integration of clinical, cytological, histopathological, and immunohistochemical evaluation is essential for accurate diagnosis, particularly given the morphological variability and biological behavior of this neoplasm.

In conclusion, this report demonstrates that, although rare in sheep, melanoma may occur in young animals and exhibit highly aggressive behavior, characterized by rapid growth, early recurrence, and probable systemic dissemination. Its occurrence in a lamb suggests a possible role of factors related to melanocytic development. The integration of clinical, cytological, histopathological, and immunohistochemical findings was essential for diagnosis, highlighting the importance of a comprehensive approach given the variability of these tumors. The clinical outcome reinforces the guarded prognosis and therapeutic limitations, emphasizing that melanoma should be included in the differential diagnosis of cutaneous masses in sheep, even in young animals, particularly in cases with rapid progression and aggressive behavior.

Data Availability

All the original contributions presented in this study are included in the article. Further inquiries can be directed to the corresponding author.

Author Contributions

Márcio Douglas Leal da Silveira: Conceptualization, Data curation, Formal analysis, Investigation, Resources, Methodology, Writing – original draft. **Maria Luiza de Barros Gonçalves**: Investigation, Resources. **Caroline da Silva Penha**: Investigation, Resources. **Camila Soares Vasconcelos Rocha**: Investigation, Resources. **Erica Emerenciano Albuquerque**: Investigation, Resources. **Huber Rizzo**: Data curation, Visualization, Writing – original draft, Writing – review & editing. **Fabrício Bezerra de Sá**: Investigation, Resources. **Lúcio Esmeraldo Honório de Melo**: Conceptualization, Methodology, Supervision. All authors have read and approved the final version of the manuscript.

Conflict of Interest

The authors declare no competing interests.

Generative AI Use Statement

The authors did not use generative artificial intelligence tools or technologies in creating or editing any part of this manuscript.

Funding

The authors received no financial support for this study.

References

1. Babić T, Grabarević Ž, Vuković S, Kos J, Matičić D. Congenital melanoma in a 3-month-old bull calf – a case report. Vet Arh. 2009;79(4):315-20.
2. Baker JR. A case of an invasive melanoma in a new-born lamb. Vet Rec. 1975;97(25-26):496-7.
3. Blacklock KL, van der Weyden L. Advances in understanding spontaneously occurring melanoma in animals. Vet Sci. 2023;10(3):210. doi: 10.3390/vetsci10030210.
4. Breuer W, Hafner-Marx A. Primäres malignes Melanom im Gehirn eines 7 Monate alten Schafs (Ovis aries f. domestica). Tierarztl Prax Ausg G Grosstiere Nutztiere. 2017;45(2):108-11. doi: 10.15653/TPG-160585.
5. Cerqueira RB, Fernandes BP. Linfadenite caseosa em pequenos ruminantes: uma revisão. Rev Bras Buiatria. 2024;2(1):18-39. doi: 10.70061/2763-955X.2025.011.
6. El-Shazly MO, Bolbol AE, Al-Ghasnawi YA. Melanoma in sheep and goats. Egypt J Comp Pathol Clin Path. 1991;4(1):71-83.
7. Macêdo JTSA, Riet-Correa F, Dantas AFM, Simões SVD. Doenças da pele em caprinos e ovinos no semiárido brasileiro. Pesq Vet Bras. 2008;28(12):633-42. doi: 10.1590/S0100-736X2008001200013.
8. Mignacca SA, Capucchio MT, Biasibetti E, Guarneri G, Milone S, Marchisotta A, Amato B, Di Marco Lo Presti V. Three cases of melanoma in small ruminants: clinical symptoms and pathological results. Small Rumin Res. 2015;126:25-7. doi: 10.1016/j.smallrumres.2015.01.016.
9. Miller MA, Weaver AD, Stogsdill PL, Fischer JR, Kreeger JM, Nelson SL, Turk JR. Cutaneous melanocytomas in 10 young cattle. Vet Pathol. 1995;32(5):479-84. doi: 10.1177/030098589503200504.
10. Oryan A, Ghane M, Ahmadi N, Daneshbod Y. Melanoma of unknown primary origin metastasizing to visceral organs in a sheep. Braz J Vet Pathol. 2018;11(1):24-7. doi: 10.24070/bjvp.1983-0246.v11i1p24-27.
11. Pimenta J, Prada J, Cotovio M. Equine melanocytic tumors: a narrative review. Animals. 2023;13(2):247. doi: 10.3390/ani13020247.
12. Rizzo H, Araújo CASC, Silva BHS, Oliveira RAS, Paiva TDL, Dias RFF, Albuquerque PPF, Silva Júnior VA. Melanoma em cabra leiteira. Acta Sci Vet. 2019;47(Suppl 1):453. doi: 10.22456/1679-9216.97757.
13. Smith SH, Goldschmidt MH, McManus PM. A comparative review of melanocytic neoplasms. Vet Pathol. 2002;39(6):651-78. doi: 10.1354/vp.39-6-651.
14. Vala H, Pópulo H, Mesquita JR, Esteves F, Santos C, Soares P, Lopes JM. Melanocytic tumour in a black sheep never exposed to ultraviolet radiation. J Comp Pathol. 2012;146(2-3):160-4. doi: 10.1016/j.jcpa.2011.04.001.
15. van der Weyden L, Brenn T, Patton EE, Wood GA, Adams DJ. Spontaneously occurring melanoma in animals and their relevance to human melanoma. J Pathol. 2020;252(1):4-21. doi: 10.1002/path.5502.
16. Yue F, Zhao Y, Lv Y, Li S, Wang W, Li Y, Wang S, Wang C. Anti-tumor effects of sheep umbilical cord mesenchymal stem cells on melanoma cells. Int J Mol Sci. 2025;26(1):426. doi: 10.3390/ijms26010426.