Braz J Vet Pathol, 2026, vol. 19, e019022
DOI: https://doi.org/10.24070/bjvp.1983-0246.019022

BJVP
Brazilian Journal of Veterinary Pathology
ISSN 1983-0246

Case Report

Gastritis in a llama (*Lama glama*) caused by spontaneous *Baccharis coridifolia* DC. ("mio-mio") poisoning in the Santa Catarina Plateau, Brazil

Anna Laura de Oliveira Cunha[1], Gustavo Willian Pandolfo[1], Stephane Reinhold Dal Molin [1], Maria Augusta Fornara[1], Roseli Lopes da Costa Bortoluzzi[2], Renata Assis Casagrande[1], Claudia Salete Wisser[1]*

[1]Laboratório de Patologia Animal (LAPA), Centro de Ciências Agroveterinárias (CAV), Universidade do Estado de Santa Catarina (Udesc), Lages, SC, Brazil
[2]Herbário Lages da Universidade do Estado de Santa Catarina (LUSC), Centro de Ciências Agroveterinárias (CAV), Universidade do Estado de Santa Catarina (Udesc), Lages, SC, Brazil

*Corresponding author: claudia.wisser@udesc.br
Submitted: April 14th, 2026. Accepted: May 28sh, 2026.

Abstract
This report describes the first known spontaneous case of *B. coridifolia* poisoning in a domesticated llama. In August 2023, the death of a 10-month-old female llama was reported on a farm in the Santa Catarina Plateau, Brazil. The affected llama had been acquired 2 months earlier from Paraná and initially kept with sheep on ryegrass pasture. One day before death, it was moved to a native field heavily invaded with *B. coridifolia*. Clinical signs included polydipsia and muscle tremors, progressing rapidly to death approximately 14 h after the onset of clinical signs. At necropsy, the 1st and 2nd gastric compartments (C1 and C2) contained abundant fibrous ingesta and exhibited mild mucosal congestion. In the 3rd gastric compartment (C3), mild to moderate congestion, predominantly affecting the caudal region, was observed. Histopathology revealed marked diffuse mucosal necrosis with inflammatory infiltrates predominantly composed of neutrophils and macrophages, and mild edema in the aglandular portions of C1 and C2. In C3, mild to moderate congestion was observed. Additional findings included pulmonary congestion and edema, renal congestion, and centrilobular hepatocellular degeneration. Specimens of *B. coridifolia* collected from the property were submitted to the Herbarium Lages of the State University of Santa Catarina (LUSC) for botanical confirmation. The epidemiological, clinical, and pathological findings supported the diagnosis of *B. coridifolia* (mio-mio) toxicosis.This case underscores the importance of proper pasture management and careful monitoring when relocating animals to areas containing known toxic plants.

Keywords: mio-mio, herbivores, South American camelids, toxic plants, third gastric compartment.

Introduction

The llama (*Lama glama*) is one of 4 native South American camelids, along with the alpaca (*Vicugna pacos*), guanaco (*Lama guanicoe*), and vicuña (*Vicugna vicugna*) (20). Historically domesticated, llamas and alpacas play a significant role in the Andean economy due to their production of wool, meat, and artisanal goods (12). Geographically, llamas are most prevalent in Bolivia, Peru, Chile, and Argentina, with increasing captive breeding in Brazil for exhibitions, zoos, and animal production purposes (15, 17).

Physiologically, digestion in camelids is similar to that of ruminants, including regurgitation. However, they differ anatomically by possessing 3 gastric compartments with glandular regions and lacking papillae (12).

Baccharis coridifolia DC., commonly known as "mio-mio," is widely distributed in pastures across Argentina, Uruguay, Paraguay, and Brazil - particularly in the states of

Rio Grande do Sul, Santa Catarina, Paraná, and São Paulo. It is the main plant associated with poisoning cases in southern Brazil, causing gastrointestinal lesions in several domestic species (5, 23).

Spontaneous *B. coridifolia* poisoning has been described in cattle, sheep (19), buffaloes (9), and horses (1). Such cases typically occur when animals originating from areas free of the plant are introduced into infested pastures, or when high-quality forage is scarce (19). To the authors' knowledge, spontaneous *B. coridifolia* poisoning has not previously been reported in llamas or other South American camelids. Therefore, this report aims to describe the epidemiological, clinical, and pathological findings of spontaneous *B. coridifolia* poisoning in a llama in the plateau region of Santa Catarina, Brazil.

Case description

In August 2023, a 10-month-old female llama (*L. glama*) died on a property located in São José do Cerrito, in the plateau region of Santa Catarina, Brazil.

The animal had been acquired, along with a male of the same species, approximately 2 months earlier. Both llamas originated from Saudade de Iguaçu, Paraná, and were kept with a flock of sheep, sharing the same paddock with ryegrass pasture. However, detailed information regarding their management conditions prior to acquisition, including feeding practices and possible previous exposure to *B. coridifolia*, was unavailable. On the day prior to death, the llamas were moved to a native grassland area, where they remained during the day. That evening, upon being gathered, the affected animal exhibited polydipsia. The following morning, it was found in a state of agony, presenting muscle tremors that progressed to death. The average time from onset of clinical signs to death was approximately 14 h. According to the owner, the property had a history of spontaneous *B. coridifolia* poisoning in sheep in previous years, confirmed by necropsy and histopathological examination. The affected sheep were born in areas free of the plant and later transferred to native pasture invaded by *B. coridifolia*.

The llama was sent to the Animal Pathology Laboratory of the State University of Santa Catarina (Udesc) for necropsy and subsequent histopathological evaluation using hematoxylin and eosin (HE) staining.

At necropsy, the animal had a moderate body condition score and showed accumulation of dry feces around the anus. The 1st and 2nd gastric compartments (C1 and C2) contained a large amount of ingesta, predominantly composed of plant fiber, and multifocal areas of superficial epithelial detachment associated with mild congestion were observed in the mucosa of these compartments. However, the gastric contents were not submitted for botanical identification. In the 3rd compartment (C3), mild to moderate congestion was observed, predominantly affecting the caudal region. (Fig.1A). The gastric pH was 6.5. Additionally, the lungs and kidneys were diffusely reddened, and the liver exhibited a mildly prominent lobular pattern.

Histologically, the aglandular portions of the 1st and 2nd gastric compartments showed marked diffuse mucosal necrosis associated with marked diffuse inflammatory infiltrate predominantly composed of neutrophils and macrophages, and mild edema within the lamina propria (Fig. 1B). In the 3rd compartment, mild to moderate congestion was observed. The lungs presented moderate congestion and edema, the kidneys moderate congestion, and the liver moderate multifocal to coalescing hepatocellular degeneration, predominantly in the centrilobular region.

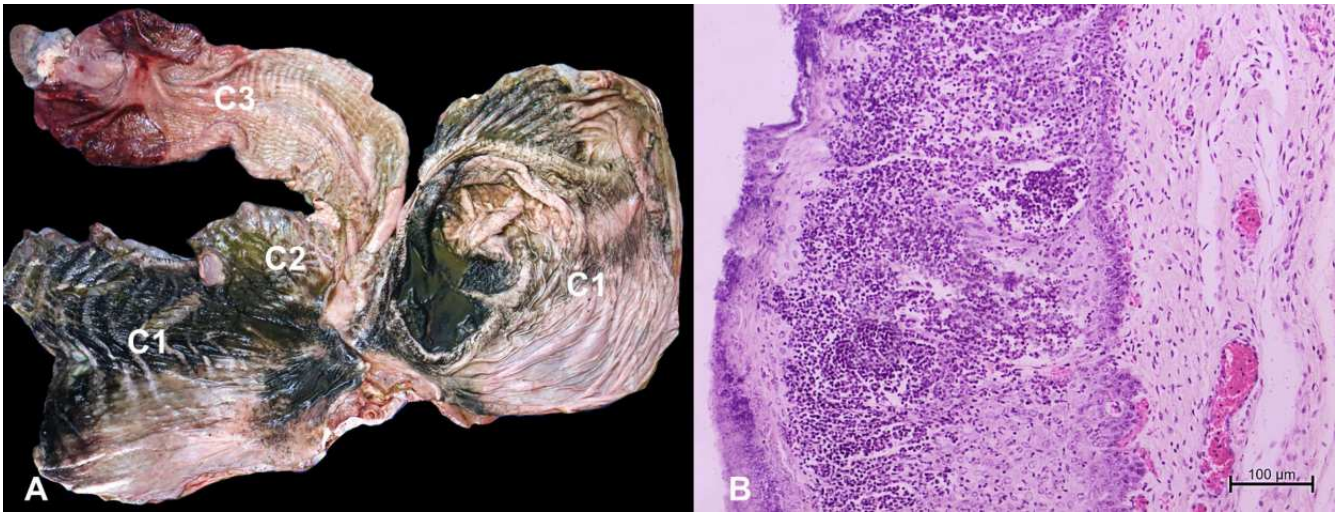

Figure 1. Macroscopic and histological lesions of toxic gastritis in a llama (*Lama glama*) caused by *Baccharis coridifolia*. A- First and second gastric compartments (C1 and C2) contained mild congestion in the mucosa. Third compartment (C3): marked mucosal congestion and mild edema. B- Second compartment (C2): mucosal necrosis with cellular debris and a moderate diffuse inflammatory infiltrate of neutrophils and macrophages.

A population of plants identified as *B. coridifolia* was observed in the native grassland area where the animal had been kept (Fig. 2). A site visit was conducted, and specimens of the plant were collected and sent to the LUSC Herbarium at the Center for Agricultural and Veterinary Sciences (CAV)/ Udesc for botanical identification and species confirmation. The specimen (Wisser, C. S., no. 2), collected on April 30, 2024, was registered in the herbarium under catalog number LUSC 11950 and barcode 011685.

Discussion

B. coridifolia poisoning typically follows an acute clinical course in herbivores, although the progression may vary among species (1, 14, 16, 22). In the present case, the affected llama developed clinical signs shortly after introduction into a pasture invaded by the plant and died approximately 14 h after the onset of clinical signs, consistent with the clinical course previously described in naturally affected herbivores. Although detailed information regarding previous management before acquisition was unavailable, the rapid onset and progression of clinical signs after exposure supports the epidemiological diagnosis of acute *B. coridifolia* poisoning.

The main clinical signs observed included polydipsia and muscle tremors, in addition to dry feces around the anus, similar to findings described in cattle (14). The increased water intake seen in this case is frequently reported in more severe intoxications and can lead to the erroneous assumption that hydration worsens the toxicosis. However, it is now understood that polydipsia is a physiological response to poisoning rather than a factor contributing to the fatal outcome (22).

The necropsy findings observed in the present case are consistent with those previously described in herbivores affected by *B. coridifolia* poisoning, including sheep, cattle, and horses, in which congestion, edema, erosions, and necrosis affecting different gastric compartments are commonly reported (1, 14, 16). In some cases, mesenteric lymph nodes may appear enlarged and edematous (16), which was not observed in the present case.



Figure 2. Pasture where the llamas were placed the day before death. [In detail: *Baccharis coridifolia* specimens confirmed by botanical identification].

Histopathological lesions in *B. coridifolia* poisoning exhibit a relatively consistent pattern among affected species, characterized by degeneration and necrosis of the gastrointestinal epithelium, mucosal and/or submucosal edema, inflammatory infiltrates composed of mononuclear and polymorphonuclear cells, and variable degrees of congestion and hemorrhage throughout the stomach compartments. However, the distribution of lesions within the digestive tract may vary according to the species affected. In sheep and cattle, lesions are predominantly observed in the rumen and reticulum, whereas in horses all gastric regions may be similarly affected (1, 14, 16). The histological findings observed in the present case are consistent with this pathological pattern and support the toxic effects of macrocyclic trichothecenes produced by fungi associated with *B. coridifolia*, which are known to induce epithelial necrosis and severe gastrointestinal injury (11). Variations in lesion severity may be influenced by factors such as ingested dose, duration of exposure, species-specific physiology, and individual susceptibility.

Secondary systemic lesions affecting the lungs, kidneys, and liver have also been reported in herbivores affected by *B. coridifolia* poisoning and are likely associated with acute toxemia, circulatory disturbances, and vascular injury induced by macrocyclic trichothecenes (22, 11). The centrilobular hepatic degeneration observed in the present case may reflect hepatocellular injury associated with hypoxia and systemic toxic effects during the acute clinical course (22).

Like other members of the Camelidae family, llamas are classified as pseudoruminants because they possess 3 gastric compartments functionally analogous to the forestomachs and abomasum of true ruminants (7). These anatomical and physiological similarities may explain the comparable distribution and pattern of gastrointestinal lesions observed in llamas, sheep, and cattle following *B. coridifolia* poisoning. Despite not being true ruminants, llamas appear susceptible to the toxic effects associated with macrocyclic trichothecenes produced by fungi linked to the plant.

For an accurate diagnosis of *B. coridifolia* (mio-mio) poisoning, epidemiological findings, clinical progression, and anatomopathological lesions must be interpreted together (21). Differential diagnoses should include other toxic plants capable of inducing acute gastrointestinal lesions in herbivores. In southern Brazil, important plant-related differentials include *Baccharis megapotamica* var. *megapotamica* and var. *weirii*, *Baccharis vulneraria* Backer, and *Raulinoreitzia tremula*, all of which can induce clinical and pathological findings similar to those caused by *B. coridifolia* (4, 10, 22). In the present case, the epidemiological investigation and botanical identification of the plant present in the pasture, combined with the absence

of other toxic plant species associated with similar lesions, supported the exclusion of these differential diagnoses.

Other toxic and metabolic conditions should also be considered in animals presenting with acute gastrointestinal lesions. Ruminal acidosis may affect the 1st stomach compartment of llamas and is typically associated with markedly reduced gastric pH (4.5-5.0) and excessive intake of concentrate feed (3), which were not observed in the present case. Sodium fluorosilicate poisoning may also cause gastrointestinal hyperemia, hemorrhage, and necrosis following environmental contamination of pastures or water sources by fluoride-containing residues (13). Acute lead arsenate poisoning should likewise be considered because it can produce necro-hemorrhagic and ulcerative lesions in the forestomaches and lymphoid tissues that are indistinguishable from those caused by *B. coridifolia* poisoning in herbivores (18). More recently, ingestion of the pollen beetle *Astylus atromaculatus* has been associated with acute necrotizing gastrointestinal disease in herbivores (6). In the present case, the absence of epidemiological evidence of exposure to toxic contaminants or insect ingestion, together with the identification of *B. coridifolia* in the grazing area and compatible clinicopathological findings, supported the final diagnosis.

Species of the genus *Baccharis*, including *B. coridifolia* and *B. megapotamica*, are widely known for their toxicity, which is attributed to macrocyclic trichothecenes produced by fungi associated with the plants (8, 22, 11). Recent studies have expanded the characterization of these toxins, including the identification of novel malonyl-glucose conjugates in *B. coridifolia* associated with spontaneous poisoning outbreaks in cattle (11). This highlights the significant toxic potential of these plants and reinforces their prominence in endemic areas. The abundant presence of *B. coridifolia* in the native pasture area where the llama was introduced strongly supports ingestion of this plant as the key factor behind the clinical signs and subsequent death.

Prevention of *B. coridifolia* toxicosis relies on careful management of susceptible animals, particularly those newly introduced into pastures invaded by the plant. The risk of poisoning is increased in hungry or stressed animals and in areas with limited forage availability (19). Preventive measures include gradual adaptation to invaded pastures, removal of the plant from grazing areas when feasible, and the provision of adequate forage to reduce plant consumption (2, 19).

This is the first case report of *B. coridifolia* intoxication in a New World camelid and expands current knowledge regarding animal species susceptible to this plant. The clinical signs associated with gross and histological lesions observed in the llama were consistent with those described in other herbivores, supporting the final diagnosis.

Data Availability

All the original contributions presented in this study are included in the article. Further inquiries can be directed to the corresponding author.

Author Contributions

Anna Laura de Oliveira Cunha: Investigation, Data curation, Formal analysis, Writing - original draft preparation. **Gustavo Willian Pandolfo:** Investigation, Writing – review and editing. **Stephane Reinhold Dal Molin:** Investigation, Writing – review and editing. **Maria Augusta Fornara:** Investigation, Writing – review and editing. **Roseli Lopes da Costa Bortoluzzi:** Formal analysis, Writing – review and editing. **Renata Assis Casagrande:** Investigation, Data curation, Formal analysis, Supervision, Writing – review and editing. **Claudia Salete Wisser:** Investigation, Data curation, Formal analysis, Supervision, Writing – review and editing. All authors have read and approved the final version of the manuscript.

Conflict of Interest

The authors declare no competing interests.

Generative AI Use Statement

The authors did not use generative artificial intelligence tools or technologies in creating or editing any part of this manuscript.

Funding

This study was financially supported by the Fundação de Amparo à Pesquisa e Inovação do Estado de Santa Catarina (FAPESC No. 35/2025; Process: 910/2025), the Programa de Apoio à Pós-Graduação maintained by the Coordenação de Aperfeiçoamento de Pessoal de Nível Superior (PROAP/CAPES, Finance Code 001).

References

1. Alda JL, Sallis ESV, Nogueira CEW, Soares MP, Amaral L, Marcolo-Pereira C, Xavier F, Frey JF, Shild AL. Intoxicação espontânea por *Baccharis coridifolia* (Compositae) em equinos no Rio Grande do Sul. Pesq Vet Bras. 2009;29(5):409-14. doi: 10.1590/S0100-736X2009000500009.
2. Almeida MB, Schild AL, Pfister J, Pimentel M, Forster KM, Riet-Correa F. Methods of inducing conditioned food aversion to *Baccharis coridifolia* (mio-mio) in cattle. Cienc Rural. 2013;43(10):1866-71. doi: 10.1590/S0103-84782013001000022.
3. Belknap EB. Medical problems of llamas. Vet Clin North Am Food Anim Pract. 1994;10(2):291-307. doi: 10.1016/s0749-0720(15)30563-6.

4. Costa LS, Cristo TG, Withoeft JA, Bilicki JV, Pisetta NL, Bortoluzzi RLC, Klug CM, Casagrande RA. Spontaneous poisoning by *Baccharis vulneraria* Backer in cattle. Pesq Vet Bras. 2022;42:e06961. doi: 10.1590/1678-5150-PVB-6961.
5. Döbereiner J, Rezende AML, Tokarnia CH. Intoxicação experimental por *Baccharis coridifolia* em coelhos. Pesq Agropec Bras Sér Vet. 1976;11:27-33.
6. García y Santos C, García JA, Dutra F, Livio JM, Corro AC, Cantón G, Escalona J, Capelli A, Matto C, Giannitti F, Uzal FA. *Astylus atromaculatus* (pollen beetle) gastrointestinal disease experimentally reproduced in sheep. Vet Pathol. 2025;62(3):327–331. doi: 10.1177/03009858241309394.
7. Hund A, Wittek T. Abomasal and third compartment ulcers in ruminants and South American camelids. Vet Clin North Am Food Anim Pract. 2018;34(1):35-54. doi: 10.1016/j.cvfa.2017.10.003.
8. Jarvis BB. Macrocyclic trichothecenes from Brazilian Baccharis species: from microanalysis to large-scale isolation. Anal Chem. 1992;3(6):241-9. doi: 10.1002/pca.2800030602.
9. Lértora R, Negrete J *Baccharis coridifolia* poisoning in water buffalo (Bubalus bubalis) in the North of the Province of Corrientes, Argentina. Braz J Vet Pathol. 2015;8(1):1-5. doi: 10.24070/bjvp.1983-0246.008001.
10. Lucioli J, Furlan FH, Mezaroba S, Traverso SD, Gava A. Intoxicação espontânea e experimental por *Eupatorium tremulum* (Asteraceae) em bovinos. Pesq Vet Bras. 2007;27(10):442-5. doi: 10.1590/S0100-736X2007001000010.
11. Machado M, Martínez R, Andres S, Sumarah MW, Renaud JB, Armién AG, Barros CSL, Riet-Correa F, Menchaca A, Schild CO. Poisoning by *Baccharis coridifolia* in early-weaned beef calves: pathological study and new macrocyclic trichothecene identification. Toxins. 2023;15(12):681. doi: 10.3390/toxins15120681.
12. Moreno GR. Artiodactyla – Camelidae Neotropical (Alpaca, Lhama, Guanaco e Vicunha). In: Cubas ZS, Silva JCR, Catão-Dias JL, eds. Tratado de Animais Selvagens – Medicina Veterinária. 2.ed. São Paulo: Roca, 2014. p.1054-70.
13. Panziera W, Schwertz CI, Silva FS, Taunde PA, Pavarini SP, Driemeier D. Intoxicação aguda por fluorsilicato de sódio em bovinos. Acta Sci Vet. 2018;46(Suppl 1):280.
14. Rissi DR, Rech RR, Fighera RA, Cagnini DQ, Kommers GD, Barros CSL. Intoxicação espontânea por *Baccharis coridifolia* em bovinos. Pesq Vet Bras. 2005;25(2):111-4. doi: 10.1590/S0100-736X2005000200008.
15. Rodrigues MGR, Soares FEF, Hiura E, Aguiar AR, Ferraz CM, Lenz D, Barbosa TS, Rangel MCV, Fonseca LA, Lacerda TF, Braga GMAM, Sena FP, Araújo JV, Braga FR. In vitro biological control of strongyles (Strongylida) in llamas (*Lama glama*) coming from a zoo, in southeastern Brazil. Int J Curr Microbiol Appl Sci. 2016;5(5):969-75. doi: 10.20546/ijcmas.2016.504.111.
16. Rozza DB, Raymundo DL, Corrêa AMR, Leal J, Seitz AL, Driemeier D, Colodel EM. Intoxicação espontânea por *Baccharis coridifolia* (Compositae) em ovinos. Pesq Vet Bras. 2006;26(1):21-5. doi: 10.1590/S0100-736X2006000100005.
17. Santos IC, Barbosa LN, Belettini ST, Boscarato AG, Iukava LK, Zaniolo MM, Rubio KAJ, Del Vechio MAC, Santos MC, Gonçalves DD. Resistance profile of bacterial isolates from different llama microbiotas (*Lama glama* Linnaeus 1758). Arq Bras Med Vet Zootec. 2023;75(3):525-30. doi: 10.1590/1678-4162-12805.
18. Schild CO, Giannitti F, Medeiros RMT, Silveira CS, Caffarena RD, Poppenga RH, Riet-Correa F. Acute lead arsenate poisoning in beef cattle in Uruguay. J Vet Diagn Invest. 2019;31(2):307-10. doi: 10.1177/1040638719831413.
19. Schild CO, Oliveira LGS, Miraballes C, Giannitti F, Casaux ML, Aráoz V, Silveira CS, Boabaid FM, Riet-Correa F. *Baccharis coridifolia* poisoning in livestock in Uruguay. Toxicon. 2020;188:5-10. doi: 10.1016/j.toxicon.2020.10.006.
20. Sell R. Lhama. In: Alternative Agriculture Series. Serviço de Extensão da NDSU, Departamento de Economia Agrícola, Universidade Estadual de Dakota do Norte; 1993.
21. Stigger AL, Driemeier D, Pavarini SP, Panziera W, Perosa FF, Paz MC, Barros CSL. Poisoning by Baccharis coridifolia in cattle. Braz J Vet Pathol. 2024;17(Suppl 2):132-5.
22. Tokarnia CH, Brito MF, Barbosa JD, Peixoto PV, Döbereiner J. *Baccharis coridifolia*. In: Plantas Tóxicas do Brasil para Animais de Produção. Rio de Janeiro: Helianthus; 2012. p.95-103.
23. Varaschin MS, Barros CSL, Jarvis BB. Intoxicação experimental por *Baccharis coridifolia* (Compositae) em bovinos. Pesq Vet Bras. 1998;18(2):69-74. doi: 10.1590/S0100-736X1998000200006.