



Case report

Spontaneous renal adenocarcinoma in a Syrian hamster (*Mesocricetus auratus*): frequency, morphological and immunohistochemical findings

Marcele N. de Sousa Trotte¹, Luciana W. Pinto², Belmira F. dos Santos³, Rodrigo C. Menezes⁴, Rogério Tortelly¹

¹ Departamento de Patologia e Clínica Veterinária, Faculdade de Veterinária, Universidade Federal Fluminense, Niterói, RJ, Brazil.

² Serviço de Anatomia Patológica, Instituto de Pesquisa Clínica Evandro Chagas, Fundação Oswaldo Cruz, Rio de Janeiro, Brazil.

³ Centro de Criação de Animais de Laboratório, Fundação Oswaldo Cruz, Rio de Janeiro, Brazil.

⁴ Laboratório de Pesquisa Clínica em Dermatozoonoses em Animais Domésticos, Instituto de Pesquisa Clínica Evandro Chagas, Fundação Oswaldo Cruz, Rio de Janeiro, Brazil.

Corresponding author: Rodrigo C. Menezes, Av. Brasil, 4365, Manguinhos, Rio de Janeiro-RJ, Brazil, CEP: 21045-900. Phone: +55-21-3865-9536. E-mail: rodrigo.menezes@ipecc.fiocruz.br

Submitted June 7th 2010, Accepted August 5th 2010

Abstract

A spontaneous adenocarcinoma occurred in one (0.22%) adult male Syrian hamster out of 443 necropsied from a breeding animal house of the state of Rio de Janeiro, Brazil. Gross inspection showed that the renal neoplasm consisted of a unilateral single white nodule of hard consistency located in the cortex, measuring 5 mm in diameter. Microscopically, the renal epithelial cells were markedly pleomorphic and presented an abundant granular eosinophilic cytoplasm. Cells were cuboidal and mainly formed trabeculae of various widths without a lumen and also formed solid areas. There were necrotic areas and three mitotic figures per 30 high-power fields. No intravascular invasion or metastasis was observed. Positive expression of vimentin and negative expression of cytokeratin 7, pan-cytokeratin and CD10 were observed in the tumor. The histopathology and immunohistochemical profile of the renal tumor suggested the diagnosis of the eosinophilic variant of adenocarcinoma, which was reported for the first time in this species.

Key words: *Mesocricetus auratus*, renal adenocarcinoma, immunohistochemistry, neoplasia

Introduction

Although spontaneous neoplasms are not frequent in hamsters (15, 14) these animals are remarkably susceptible to the experimental induction of a large number of tumors, specially the estrogen-induced renal tumor of the Syrian hamster (ERHT) (8, 11). This tumor represents a useful model to gain insight into the role of estrogens in oncogenic process (4). Recently, a comprehensive study of tumors in domestic Syrian hamsters was performed in Japan and the hematopoietic tumors, including plasmacytomas and lymphomas, were the most common (7). In addition, according to these authors epidemiological studies on tumor prevalence in Syrian hamsters are necessary, as regional differences in tumor incidence and spectrum may be present in this species bred as laboratory or domestic animals. However, no studies

regarding the occurrence of spontaneous neoplasms in Syrian hamsters are available in Brazil.

Case report

This paper reports a rare case of spontaneous renal adenocarcinoma in a Syrian hamster from a series studied in a breeding animal house of the state of Rio de Janeiro, Brazil.

Between November 2002 and December 2006, 443 adult, outbred and conventionally maintained Syrian hamsters (*Mesocricetus auratus*), 161 males and 282 females, ranging from 3 to 12 months, were investigated. They were obtained from the production colonies of the Center for Laboratory Animal Breeding (CECAL), Oswaldo Cruz Foundation (FIOCRUZ), Rio de Janeiro, Brazil. The colony consisted of 72 couples with a mean prolificacy of 8 neonates per female per month. Ten hamsters were maintained in 40.0 x 33.0 x

16.0 cm plastic cages with stainless-steel screen covers and bedding consisting of autoclaved pine shavings. Chow specifically formulated for rodents (Nuvital®; ground whole corn, wheat bran, soy bran, leguminous hay, ground corncob, calcite limestone, bicalcium phosphate, premixed amino acids, vitamins and minerals; Ministry of Agriculture, Colombo, Paraná, Brazil) and filtered water were supplied daily *ad libitum*.

The conditions of the animal room were maintained at a temperature of 18 to 22°C, humidity of 45 to 55%, and ventilation of 10 to 15 changes per hour. The light/dark cycle consisted of 12/12 h with artificial light.

The hamsters were clinically examined at the Health Monitoring Laboratory of the same institution, euthanized in a CO₂ chamber and necropsied for health monitoring. Fragments of all organs were removed from the hamsters and immediately fixed in 10% formalin. This material was then routinely processed for paraffin embedding for histopathology and 5 µm tissues sections were stained with hematoxylin and eosin (HE).

The frequency of neoplasms among this Syrian hamster population was 0.22% (1/443) and only one tumor, located in the left kidney cortex, was identified. The animal did not present clinical signs.

Gross inspection showed that the renal neoplasm consisted of a single unilateral white nodule of hard consistency, measuring about 5 mm in diameter. Microscopically, the renal epithelial cells were markedly pleomorphic and hyperchromatic and presented an abundant granular eosinophilic cytoplasm. The cells were cuboidal and mainly formed trabeculae of various widths without a lumen (Figure 1) and also formed solid areas. There were necrotic areas and an average of three mitotic figures per 30 high-power fields. No intravascular invasion or metastasis was observed.

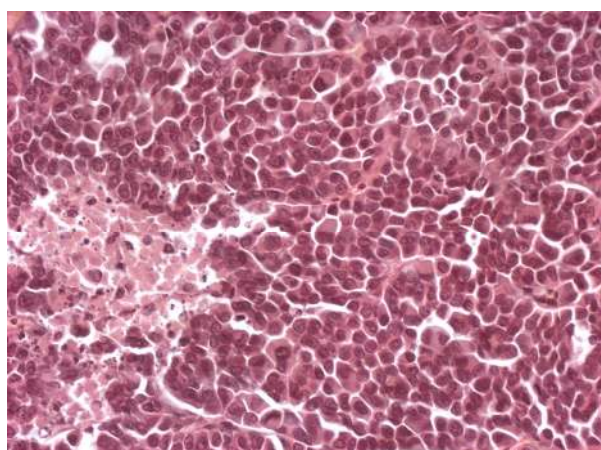


Figure 1. Kidney, adult male Syrian hamster. Renal adenocarcinoma. The cells are cuboidal and form trabeculae of various widths without a lumen, showing marked pleomorphism and an abundant granular eosinophilic cytoplasm. A necrotic area are also observed. H & E. Obj. 40x

Immunohistochemistry was performed in order to evaluate the renal tumor reported. Primary antibodies for vimentin (V9 monoclonal, 1:1,000; ZYMED®, South San Francisco, California), cytokeratin 7 (OV-TL 12/30 monoclonal, 1:250; DAKO®, Carpinteria, California), pan-cytokeratin (AE1/AE monoclonal, 1:400; DAKO®) and CD10 (NCL-CD10-270 monoclonal, 1:200; NOVOCASTRA®, Newcastle, United Kingdom) were used. Sections (5 µm) were cut and mounted on Poly-L-Lysine coated slides, dried, deparaffinized in xylene, and rehydrated in ethanol. Endogenous peroxidase was quenched by 3% hydrogen peroxide diluted in 70% methanol for 20 min. For antigenic retrieval the slides were treated with 10mM citrate buffer (pH 6.0) and incubated in water bath at 37°C for 40 min. The mouse monoclonal antibodies were detected by the avidin-biotin-peroxidase complex (Novostain Super ABC kit Universal, 1:150; NOVOCASTRA®). The antigen-antibody immunoreaction was visualized using 3,3'-diaminobenzidine (DAB, DAKO®). All immunoreactions were carried out at room temperature.

Positive expression of vimentin (Figure 2) and negative expression of cytokeratin 7 (CK7), pan-cytokeratin and CD10 were observed in the tumor. Based on morphological and immunohistochemical features we made the diagnosis of renal adenocarcinoma, favoring the eosinophilic variant according to the World Health Organization histological classification of tumors of the urinary system of domestic animals (10).

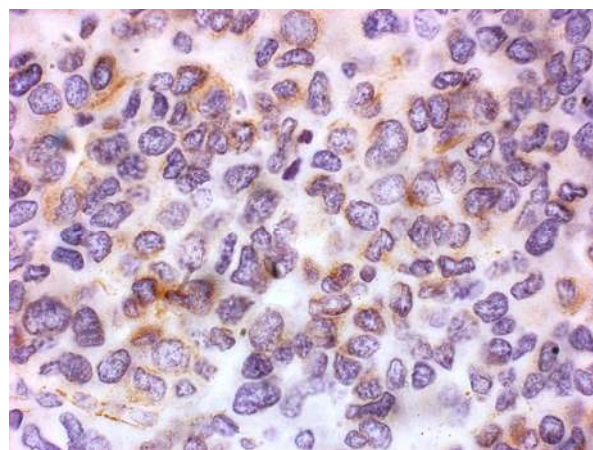


Figure 2. Kidney, adult male Syrian hamster. Renal adenocarcinoma. Note the positive expression of vimentin in the cytoplasm of tumor cells. Immunoperoxidase. Obj. 100x.

The study was approved by the Ethics Committee for the Use of Animals of the institution (CEUA/FIOCRUZ, No. P0044-00).

Discussion

The low prevalence of spontaneous tumors observed in the present study has also been reported by other investigators in Syrian hamsters (15, 13, 14, 7). However, according to these authors, the most

frequently observed neoplasms in the Syrian hamster are lymphomas, plasmacytomas, adenoma of the adrenal gland, polyps and adenocarcinoma of the intestinal tract. These different results were probably related to regional differences and to the older ages of the animals investigated by them, which were between 14 to 28 months and thus more susceptible to tumor occurrence.

The occurrence of spontaneous renal carcinomas in Syrian hamsters has been reported by a few studies (14, 2). Similar to the present results, these authors found a prevalence of less than 1% and considered the renal tumors to be very rare. Adenomas and nephroblastomas are the most frequently reported renal tumors in this animal (13, 12).

Microscopically, the neoplasm observed was similar to the granular eosinophilic variant of renal cell carcinoma described in cattle (6), which was composed of eosinophilic granular epithelial cells and was considered the most common type of renal tumor in those animals. However, corpora amyloidea and hemosiderin described in bovine renal cell carcinomas were not identified in the present case.

Unlike the renal cell carcinomas described in two Siberian hamsters (9), which were classified as papillary-tubular, cystic-papillary-tubular, clear cell and mixed types, in the present study, tubular or papillary pattern, basally located nuclei, pale and vacuolated cytoplasm, oval to polygonal cells and cysts were not observed. However, eosinophilic cytoplasm was found in some neoplastic cells of these renal tumors.

The main differential diagnosis of the eosinophilic cell variant of renal adenocarcinoma is oncocytoma, whose immunohistochemical diagnosis is based on positive immunoreexpression of cytoplasmic cytokeratin, but not vimentin (10). Therefore, the immunohistochemical result in the present case excluded the diagnosis of renal oncocytoma and suggested the classification of the eosinophilic variant of renal adenocarcinoma, which was reported for the first time in the Syrian hamster. The immunohistochemical profile was different from that observed in human cases of RCC, which are positive not only for vimentin, but also for pan-cytokeratin and CD10 (3).

The presence of spontaneous renal carcinoma only in males, as observed in the present study, was not surprising considering its higher frequency in men, male rats, male dogs and male Siberian hamsters (1, 5, 9, 3) suggesting a role of male hormones in the pathogenesis of this neoplasm. What is known about the etiology of hamster renal tumor is that experimentally some steroidal estrogens and the nonsteroidal estrogen diethylstilbestrol induce renal tumors in male hamsters (11, 8). However, the kidney tumor described in this report was microscopically different from the estrogen-induced renal tumor in hamsters, which is originated from interstitial ectopic uterine-like germinal cells and has an embryonal appearance made up of cells of mesenchymal or blastemal and epithelial morphology (11, 4). Therefore,

the eosinophilic variant of renal adenocarcinoma probably has another etiology. In humans with renal cell carcinomas, no excess of estrogens has been reported, and proven etiological factors include environmental carcinogens (tobacco smoking) and lifestyle factors, particularly obesity (3).

Acknowledgements

To Mr. Rodrigo Méxas from the Service of Production and Images Treatment, Oswaldo Cruz Institute/FIOCRUZ, for the technical support with the figures.

References

1. BASKIN GB., DE PAOLI A. Primary renal neoplasms of the dog. *Vet. Pathol.*, 1977, 14, 591-605
2. BUREK J.D., DUPRAT P., OWEN R., PETER CP., VAN ZWIETEN MJ. Spontaneous renal diseases in laboratory animals. *Int. Rev. Exp. Pathol.*, 1988, 30, 231-319.
3. EBLE JN., SAUTER G., EPSTEIN JL., SESTERHENN IA. *World Health Organization classification of tumours. Pathology and genetics of tumours of the urinary system and male genital organs.* Lyon: IARC Press, 2004.
4. HONTZ AE., LI SA., LINGLE WL., NEGRON V., BRUZEK A., SALISBURY JL., LI JJ. Aurora A and B overexpression and centrosome amplification in early estrogen-induced tumor foci in the Syrian hamster kidney: implications for chromosomal instability, aneuploidy, and neoplasia. *Cancer Res*, 2007, 67, 2957-2963.
5. IZUMI K., KITAURA K., CHONE Y., TATE H., NAKAGAWA T., SUZUKI Y., MATSUMOTO K. Spontaneous Renal cell tumors in Long-Evans Cinnamon rats. *Jpn. J. Cancer Res.*, 1994, 85, 563-566.
6. KELLEY LC., CROWELL WA., PUETTE M., LANGHEINRICH KA., SELF AD. A retrospective study of multicentric bovine renal cell tumors. *Vet. Pathol.*, 1996, 33, 133-141.
7. KONDO H., ONUMA M., SHIBUYA H., SATO T. Spontaneous tumors in domestic hamsters. *Vet. Pathol.* 2008, 45, 674-680.
8. LI JJ., LI SA., KLICKA JK., PARSONS JA., LAM LK. Relative carcinogenic activity of various synthetic and natural estrogens in the Syrian hamster kidney. *Cancer Res.*, 1983, 43, 5200-5204.
9. LI X., WARDRIP CL., SEPS SL., PADRID PA. Renal cell carcinoma in two Siberian hamsters (*Phodopus sungorus*). *Contemp. Top. Lab. An. Sci.*, 1998, 37, 70-73.
10. MEUTEN DJ., EVERITT J., INSKEEP W., JACOBS RM., PELETEIRO M., THOMPSON KG. *World Health Organization. Histological classification of tumors of the urinary system of domestic animals,*

Second series, vol. 11. Washington: Armed Forces Institute of Pathology and American Registry of Pathology, 2004.

11. NOGUEIRA E., CARDESA A., MOHR U. Experimental models of kidney tumors. J. Cancer Res. Clin. Oncol., 1993, 119, 190-198.

12. POUR P., ALTHOFF J., SALMASI SZ., STEPAN K. Spontaneous tumors and common diseases in three types of hamsters. J Natl. Cancer Inst., 1979, 63, 797-809.

13. POUR P, MOHR U, ALTHOFF J, CARDESA A, KMOCH N. Spontaneous tumors and common diseases in two colonies of Syrian hamsters. III Urogenital system and endocrine glands. J. Natl. Cancer Inst, 1976, 56, 949-954.

14. VAN HOOSIER GL., TRENTIN JJ. Naturally occurring tumors of the Syrian hamster. Prog. Expl. Tumor Res., 1979, 23, 1-12.

15. YABE Y., KATAOKA N., KOYAMA H. Spontaneous tumors in hamsters: incidence, morphology, transplantation, and virus studies. Gann, 1972, 63, 329-336.